LIBRARY

Date 30 September 1948

Class Mark b. JC 1904-13 Accession No. 34729

LSHTM
001130666X

LONDON SCHOOL OF HYGIENE AND TROPICAL MEDICINE
LIBRARY
30 SEP 1948

Digitized by the Internet Archive
in 2015

https://archive.org/details/b2135327x_0002

ROYAL COMMISSION ON TUBERCULOSIS (HUMAN AND BOVINE).

FINAL REPORT OF THE ROYAL COMMISSION

APPOINTED TO INQUIRE INTO THE RELATIONS OF

HUMAN AND ANIMAL TUBERCULOSIS.

PART II. APPENDIX.

VOLUME II.

Investigation of Viruses obtained from Cases of Lupus.

A. STANLEY GRIFFITH, M.D.

Presented to both Houses of Parliament by Command of His Majesty.

LONDON:
PUBLISHED BY HIS MAJESTY'S STATIONERY OFFICE.
To be purchased, either directly or through any bookseller, from
WYMAN AND SONS, LTD., FETTER LANE, E.C., and 32, ABINGDON STREET, S.W.; or
OLIVER AND BOYD, TWEEDDALE COURT, EDINBURGH; or
E. PONSONBY, LTD., 116, GRAFTON STREET, DUBLIN.

PRINTED BY
DARLING AND SON, LTD., BACON STREET, E.
1911.

[Cd. 5791.] *Price* 4*s.* 3*d.*

GOVERNMENT PUBLICATIONS.

1. **Government Publications** (with the exceptions mentioned in paragraphs 2 to 6) can be bought, either directly or through any bookseller, from—

   WYMAN AND SONS, LTD., Fetter Lane, London, E.C.; or
   OLIVER AND BOYD, Tweeddale Court, Edinburgh; or
   E. PONSONBY, LTD., 116, Grafton Street, Dublin.

   Booksellers, and the accredited agents of Free Public Libraries, are entitled to a discount of 25 per cent. from published prices.

2. **Hydrographical Publications of the Admiralty** are sold by—
   J. D. POTTER, 145, Minories, London, E.C.

3. **Patent Office Publications** are sold at—
   The Patent Office, 25, Southampton Buildings, Chancery Lane, London, W.C.
   (N.B.—Classified Abridgments of Patent Specifications are sold also by Wyman and Sons, Ltd.)

4. **Ordnance Survey** and **Geological Survey Publications** can be purchased from—
   The Director General of the Ordnance Survey, Southampton; or
   The Superintendent, Ordnance Survey, Dublin; or
   Agents in most of the chief towns in the United Kingdom.
   (N.B.—**Small Scale Maps** are, as a rule, procurable at Railway Bookstalls in England and Wales.)

5. The **Journal of the Board of Agriculture** is published monthly by the Board, at 4, Whitehall Place, London, S.W. Price 4*d*.

6. The **London Gazette** is published on Tuesday and Friday evenings by—
   Wyman and Sons, Ltd. Price 1*s*.

The following is a list of some of the more important Parliamentary and Official Publications recently issued:—

Statutes—

Public General Acts, Local and Personal Acts, 1911. In separate Acts, at varying prices.

Army Act—Consolidation—including amendments to 1910. 1*s*.

Public General, Session 1910. With Index, Tables, &c. Cloth. 3*s*.

Index to Local and Personal Acts, 1801–1899. Cloth. 10*s*. Subsequent years may be purchased separately.

Second Revised Edition. 1235–1900. Vols. I. to XX. 7*s*. 6*d*. each.

Statutes in Force. Chronological Table and Index of. 26th Edition. To the end of the Session 10 Edward VII. and 1 Geo. V. (1910). 2 vols. 10*s*. 6*d*.

Interregnum, 1642–1660. *Acts and Ordinances of the.* In 3 vols. (not sold separately). 30*s*.

Acts of the Parliaments of Scotland, 1424 *to* 1707. *Revised Edition.* 10*s*.

Statutory Rules and Orders other than those of a Local, Personal, or Temporary Character. With a List of Statutory Orders of a Local Character arranged in classes; an Appendix of certain Orders in Council &c.; and an Index. Issued in 1890 to 1910. 10*s*. each.

Statutory Rules and Orders revised. Statutory Rules and Orders, other than those of a Local, Personal, or Temporary Character, in force on December 31, 1903. Vols. I. to XIII. 10*s*. each.

Statutory Rules and Orders in force on 31st December, 1909. Index to. 10*s*.

PARLIAMENTARY DEBATES. House of Lords and House of Commons; each daily part 3*d*.; also issued in bound volumes with Index.

MINUTES OF PROCEEDINGS OF THE HOUSE OF LORDS. 1*d*. per 4 pp. Subscription, Session 1911, 30*s*.

VOTES AND PROCEEDINGS OF THE HOUSE OF COMMONS. 1*d*. per 8 pp. Subscription, Session 1911, 30*s*.

HISTORICAL MANUSCRIPTS. Reports of the Royal Commissioners. In course of issue.

NATIONAL INSURANCE AGAINST LOSS OF HEALTH, UNEMPLOYMENT, &c. Bill 198; and amended clauses 1–17. 11½*d*.

Do. Memoranda; Reports of Actuaries, German Insurance, &c. (nine papers). 4*s*. 2½*d*.

COLONIAL IMPORT DUTIES, 1910. [Cd. 5394.] 3*s*. 1*d*.

LIVE STOCK AND AGRICULTURE, SCOTLAND. Report of Committee, with Evidence, &c. [Cd. 5457, 5509.] 1*s*. 4*d*.

POOR RELIEF. Foreign and Colonial Systems. [Cd. 5441.] 3*s*. 9*d*.

ELECTRICITY IN MINES COMMITTEE. Report, Evidence, &c. [Cd. 5498, 5533.] 2*s*. 2*d*.

IRISH FLAX GROWING INDUSTRY COMMITTEE. Report, with Evidence, &c. [Cd. 5502, 5503.] 4*s*. 4*d*.

ACCIDENTS IN PLACES UNDER THE FACTORY ACTS. Report of Committee. [Cd. 5535.] 7*d*.

PILOTAGE. Report of Committee, with Evidence, &c. [Cd. 5571, 5572.] 5*s*. 3*d*.

CANADA TRADE. 1906 to 1910. With map. [Cd. 5591.] 1*s*. 3*d*.

EAST INDIA TRADE. 1905–06 to 1909–10. [Cd. 5608.] 1*s*. 1*d*.

COST OF LIVING IN AMERICAN TOWNS. Report into Working Class Rent, Housing, Wages, &c. [Cd. 5609.] 5*s*. 1*d*.

SMALL HOLDINGS. Report for 1910. [Cd. 5615.] 3½*d*.

LABOUR DEPARTMENT. Directory of Industrial Associations. 1911. [Cd. 5619.] 11*d*.

NETHERLANDS. Proposed New Customs Tariff. [Cd. 5630.] 5*d*.

RAILWAY AGREEMENTS AND AMALGAMATIONS COMMITTEE. Report. [Cd. 5631.] 5½*d*.

EGYPT AND THE SOUDAN. Report on Finances, Administration and Condition. [Cd. 5633.] 10*d*.

FISHERY BOARD, SCOTLAND. 29th Report. 1910. [Cd. 5697.] 1*s*. 7*d*.

FACTORIES AND WORKSHOPS. Report. 1910. [Cd. 5693.] 2*s*. 4*d*.

SWINE FEVER COMMITTEE. Report, Evidence. [Cd. 5671, 5680.] 3*s*. 5*d*.

IMPERIAL EDUCATION CONFERENCE, 1911:—
Report. [Cd. 5666.] 1*s*.
Minutes of proceedings; papers laid, &c. [Cd. 5745, 5746–I, 5746–II.] 7*s*. 3½*d*.

PERSIA. Further Correspondence respecting. [Cd. 5656.] 1*s*. 1*d*.

CENSUS. ENGLAND AND WALES. 1911. Preliminary Report and Tables. [Cd. 5705.] 1*s*. 4*d*.

Do. IRELAND. [Cd. 5691.] 2½*d*.

Do. SCOTLAND. [Cd. 5700.] 10*d*.

FINANCE ACCOUNTS. 1910–11. H.C. 201. 5½*d*.

TUBERCULOSIS—HUMAN AND BOVINE. Final Report of Royal Commission. [Cd. 5761.] 6*d*.

RURAL EDUCATION CONFERENCE. Report, &c. [Cd. 5773, 5774.] 5½*d*.

ROYAL COMMISSION ON TUBERCULOSIS (HUMAN AND BOVINE).

FINAL REPORT OF THE ROYAL COMMISSION

APPOINTED TO INQUIRE INTO THE RELATIONS OF

HUMAN AND ANIMAL TUBERCULOSIS.

PART II. APPENDIX.

VOLUME II.

Investigation of Viruses obtained from Cases of Lupus.

A. STANLEY GRIFFITH, M.D.

Presented to both Houses of Parliament by Command of His Majesty.

LONDON:
PUBLISHED BY HIS MAJESTY'S STATIONERY OFFICE.
To be purchased, either directly or through any Bookseller, from
WYMAN AND SONS, LTD., FETTER LANE, E.C., and 32, ABINGDON STREET, S.W.; or
OLIVER AND BOYD, TWEEDDALE COURT, EDINBURGH; or
E. PONSONBY, LTD., 116, GRAFTON STREET, DUBLIN.

PRINTED BY
DARLING AND SON, LTD., BACON STREET, E.
1911.

[Cd. 5791.] *Price* 4*s.* 3*d.*

34729

INVESTIGATION OF VIRUSES OBTAINED FROM CASES OF LUPUS.

TABLE OF CONTENTS.

	Page
Preface	6
Introduction	7
The Cultural Characters and Pathogenicity of the Cultures Isolated :—	
Cultures :—	
(*a*) Method of obtaining Cultures	8
(*b*) Cultural Characters	8
(*c*) Action of Light Rays on Cultures	9
Pathogenicity of the Cultures :—	
(*a*) Original Virulence	9
For Calves	10
For Rabbits	11
For Rhesus Monkeys	14
For Guinea-pigs	16
For other Species of Animals	18
(*b*) Virulence after Passage	20
General Summary	24
Classification of the Lupus Viruses according to Cultural Characters and Virulence	28
Tabular Summary of the Results of the Passage Experiments	30
Table of Origins	31
Detailed History of each Case and Summaries of Experimental Results	37
Tabular Summaries of Inoculation Experiments :—	
Inoculation Experiments on Calves	71
" " Rabbits	79
" " Rhesus Monkeys	101
" " Guinea-pigs	109
" " Chimpanzee	118
" " Baboon	118
" " Pigs	119
" " Goats	121
" " Horses	122
" " Cats	123
" " Rats	124
" " Mice	125
Tabular Summaries of Feeding Experiments	127

2000. Wts. T.L. 277 & 13670. 12/08. D & S. 32. 27676C.

PAGE

Detailed Description, with Summary, of each of the Passage Experiments :—

Introduction 134

(i) With Virus H. 100. "R.S." 134

(ii) With Virus H. 108. "H.R." 137

(iii) With Virus H. 105. "G.S." 140

(iv) With Virus H. 107. "H.H." 144

(v) With Virus H. 85. "H.B." 147

(vi) With Virus H. 53. "D.H." (*a*) 149

" " " (*b*) 156

(vii) With Virus H. 71. "L.V." (*a*) 159

(viii) With Virus H. 102. "N.H."... 159

(ix) With Virus H. 114. "A.U." 160

(x) With Virus H. 84. "M.S." 160

Charts of the Inoculation Experiments with each Virus and of the Passage Experiments with certain of the Viruses:

Full Post-mortem Notes of all the Larger Animals Inoculated with Original and Passage Cultures: and

Abstracts of the Post-mortem Notes of the Rabbits Inoculated with Passage Cultures ... 163

Plates :—Photographs of some of the Lupus Cultures on Agar and Potato 479

Index to Viruses 481

Index to Animals 482

INVESTIGATION OF VIRUSES OBTAINED FROM CASES OF LUPUS.

PREFACE.

This volume is devoted entirely to the results of the investigation of the tubercle bacilli found in the lesions of *lupus vulgaris*.

This disease is dealt with separately from other kinds of human tuberculosis on account of the great variation in the properties of the tubercle bacilli isolated.

The method of presenting the results is the same as has been used in the first volume of the Appendix (Investigation of Viruses obtained from Cases of Human Tuberculosis other than Lupus). In the beginning there is a general account with tabular summaries of the cultural and pathogenic properties (original and after passage) of the bacilli isolated, then there is a table (The Table of Origins) in which for each of the cases arranged in chronological order are given brief abstracts of the history of the patient and of the result of the investigation of the bacilli obtained. This is followed by a fuller statement of all that has been elucidated in connection with each virus ; this statement includes a detailed history of the patient, the use made of the material, a description of the cultural characters of the bacilli isolated and summaries of the results obtained in the different species of animals by the inoculation of the cultures. After this come the tabular summaries of the inoculation experiments performed on the different species of animals, the experiments with each species being tabulated separately. A detailed account of the passage experiments with divers cultures follows after. Lastly there are the full post-mortem notes of the larger animals grouped together according to the virus used, each set of experiments being preceded by graphic charts on which appear all the animals inoculated with the virus. A series of photographs illustrating the types of growth of lupus cultures is appended.

The pictorial charts exhibiting the lesions produced in calves, pigs, and goats by the lupus viruses are included with other similar charts in a supplementary volume.

A. STANLEY GRIFFITH.

BLYTHWOOD FARM.

July, 1910.

INTRODUCTION.

The cases of human tuberculosis reported upon in the 2nd Interim Report included a single case of lupus, designated H. 53. "D.H.", from which a culture was isolated which differed in its properties from all other tubercle bacilli grown from human tuberculous lesions.

The culture possessed the cultural characters of a bovine tubercle bacillus but was distinguished from bovine tubercle bacilli by its relatively low virulence for the calf, a virulence which was not increased by a single residence of 91 days in the body of the calf. For the rabbit on the other hand the culture had high virulence, but its virulence for this species of animal also was not equal to that of a typical bovine tubercle bacillus.

The result in this case led to the investigation of more cases of lupus with a view to determining whether the tubercle bacilli responsible for this kind of tuberculosis do as a rule vary in their properties from one or the other of the two types of tubercle bacilli which are the cause of other kinds of human tuberculosis.

For the purposes of the investigation material has been obtained from twenty new cases of lupus and in addition fresh material has been obtained from the old case (H. 53) ; also the original culture from the latter has been more fully investigated with reference to its pathogenic properties. The material from one of the new viruses, H. 113. "O.S.", did not cause tuberculosis in guinea-pigs and cultures of it were not obtained.

From the remaining 19 viruses as well as from the fresh material of the old virus cultures have been isolated and tested on artificial media and various species of animals.

In addition to Virus H. 53 opportunity has been afforded in two other cases, H. 71 and H. 110, of investigating material removed from a patient on two different occasions. The interval between the removal of the specimens was $3\frac{7}{12}$ years in the case of H. 53, nearly 2 years in that of H. 71, and 6 months in that of H. 110.

The following list gives in numerical order the designation of the viruses investigated, the age and sex of each patient, the situation of the lupus, and the duration of the disease.

Designation of Virus.	Age and Sex of Patient.	Situation of Lupus.	Duration of Disease.
H. 53. "D.H." (*a*) ...	15 years } female	Hip	From early childhood.
" " (*b*) ...	$18\frac{1}{2}$ years }		
H. 71. "L.V" (*a*) ...	14 years } female	Arm, hand, face, neck and back.	9 years.
" " (*b*) ...	16 years }		
H. 84. "M.S." ...	68 years, female	Cheek	15 years.
H. 85. "H.B." ...	5 years, male	Nose	About 3 months.
H. 91. "H.S." ...	$9\frac{1}{2}$ years, male	Chin	$3\frac{1}{2}$ years.
H. 92. "D.N." ...	$3\frac{3}{4}$ years, female	Cheek	$1\frac{8}{12}$ years.
H. 99. "L.K." ...	8 years, female	Nose, lip, neck	Not known.
H. 100. "R.S." ...	37 years, female	Arm, hand, neck, face	17 years.
H. 101. "E.G." ...	53 years, female	Elbow, arm, cheeks, nose	36 years.
H. 102. "N.H." ...	33 years, female	Arm, face	15 years.
H. 103. "N.S." ...	28 years, female	Leg	24 years.
H. 105. "G.S." ...	15 years, female	Nose, cheek, lip, palate	1 year.
H. 106. "K.R." ...	27 years, female	Elbow, arm, neck, face	About 20 years.
H. 107. "H.H." ...	17 years, male	Elbow, neck, face	8 years.
H. 108. "H.R." ...	$8\frac{1}{2}$ years, male	Arm, face, buttock	5 years.
H. 109. "M.W." ...	5 years, female	Elbow	3 years.
H. 110. "J.B." (*a*)...	10 years } male	Flank, trunk, face	4 years.
" " (*b*)...	$10\frac{1}{2}$ years }		
H. 111. "S.E." ...	17 years, male	Neck	10 years.
H. 112. "B.B." ...	16 years, female	Arm	7–8 years.
H. 113. "O.S." ...	7 years, female	Arm, face, buttock	2 years.
H. 114. "A.U." ...	16 years, female	Neck, nose	15 years.

From the above table it is seen that the ages of the patients varied from $3\frac{3}{4}$ to 68 years ; that six of the patients were males and fifteen females, and that the duration of the disease varied from three months to 36 years. In the third column when several sites are mentioned the first is that from which the material used for investigation was taken.

The method of investigating these viruses was the same as that used for the viruses other than lupus ; in each case a culture of the virus was secured, and its cultural characters and pathogenicity ascertained.

CULTURAL CHARACTERS AND PATHOGENICITY OF THE CULTURES ISOLATED.

CULTURES.

Method of obtaining Cultures.—The lupus nodules or pieces of skin containing the nodules were ground to a pulp in a mortar and emulsified with salt solution. The emulsion, after filtration through muslin, was inoculated into a series of two or three guinea-pigs intraperitoneally. In several instances culture tubes were sown with some of the emulsion of the original material and from two of the viruses (H. 106 and H. 114) a pure culture of tubercle bacilli was thus obtained direct; in other cases the tubes remained sterile or became hopelessly contaminated with other organisms. Microscopical examination showed that acid-fast bacilli were very scanty in the emulsions: one or two only were found after long search in each of six out of the 22 examined.

After the lapse of from three to five weeks one of the guinea-pigs out of each series was killed and if tuberculosis had developed tubes of media were sown from various lesions; the other guinea-pigs were allowed to live longer and when they died or were killed culture tubes were in many instances sown from them also.

The medium used for raising the cultures from the tuberculous tissues was exclusively the egg medium.

From the egg medium the bacilli were transferred to serum, and after subcultivation on the latter for a few generations were tested on various glycerin media.

Cultural characters.—No differences have been observed between different strains of the same virus.

The media used in the study of the cultural characters have been serum (from the ox), glycerin serum, glycerin agar, glycerinated potato and glycerin broth.

On these media cultures of different viruses have exhibited a wide range of variation in their cultural characters.

Some grew like bovine tubercle bacilli, varying in their capacity for growth on the glycerin media within like limits; others grew more luxuriantly and resembled the human tubercle bacillus.

The cultures fall therefore according to their cultural characters into two main divisions, as do the cultures from other kinds of human tuberculosis.

The first division contains the bacilli which grow like bovine tubercle bacilli, and is divided into three classes which correspond to the three into which bovine tubercle bacilli have been divided.

The second division contains cultures which grow luxuriantly like the human tubercle bacillus. Between the members of this division no important differences have been observed in capacity to grow on the differential media. Some of the cultures have appeared to form pigment on serum more readily than others, and on broth some variation in the character of the pellicle has been observed, but on glycerin agar and glycerinated potato the growths produced, though sometimes not until after several trials, have been practically identical for all the viruses in this division.

All the cultures in the second division have grown distinctly better than the most easy-growing in Division I. On serum the cultures in Division II have formed more or less pigment, whereas only one in Division I (H. 91. "H.S." in Class 3) has produced pigmented growths. The differences in cultural luxuriance have, however, been more clearly brought out by the use of media containing glycerin; on glycerin agar and glycerinated potato the members of Division II have in every case produced raised wrinkled pigmented layers distinctly more luxuriant than the greyish-white finely-wrinkled or ground-glass layers on agar or the greyish-white finely-granular layers on potato, the best produced by members of Division I.

Classification of Viruses according to Cultural Characters.

Division I.	Division II.
Class 1.	
H. 110. "J.B." (*a*) and (*b*)	H. 99. "L.K."
H. 105. "G.S."	H. 92. "D.N."
Class 2.	H. 109. "M.W."
H. 85. "H.B."	H. 112. "B.B."
H. 100. "R.S."	H. 71. "L.V." (*a*) and (*b*).
H. 107. "H.H."	H. 101. "E.G."
H. 108. "H.R."	H. 114. "A.U."
Class 3.	H. 103. "N.S."
H. 111. "S.E."	H. 106. "K.R."
H. 53. "D.H." (*a*) and (*b*)	H. 84. "M.S."
H. 91. "H.S."	H. 102. "N.H."

The Action of Light Rays on Cultures of Lupus Tubercle Bacilli.

At the suggestion of Dr. Steegmann I have made some preliminary observations on the effect of exposure to the light rays, used in the treatment of lupus, upon cultures of lupus tubercle bacilli.

The procedures in connection with the preparation of the cultures before exposure were as follows: Petri dishes were nearly filled with bovine serum, which was subsequently coagulated in the serum inspissator; the tubercle bacilli with which the plates were sown were taken from serum cultures and were spread as an emulsion in salt solution over the surface of the serum by means of a camel's hair brush. In order to ensure that the light rays would pass freely from the lens to the bacilli, a lid with a window of quartz was used to cover the dish; the lid was prepared in the following way—a circular opening was cut in the centre of the lid, and this was closed from the inside with a disc of quartz, the cementing material being glazier's putty. During exposure each plate was enclosed in opaque paper, in which was a circular opening corresponding to the window; before incubation of the plates the lids with the quartz windows were replaced by ordinary glass lids, and the plates were sealed with paraffin. The plates were incubated for two months.

Seven experiments were made, three with light from a Finsen, and four with light from a Kromeyer lens.

Experiments 1, 2, and 3. Finsen lens. Exposures—15 minutes (Virus H. 99), 30 minutes (H. 110), 33 minutes (H. 99). The results in these three experiments were similar; there was growth upon the inoculated surface, except upon that part which had been exposed to the rays; in each case there was a circular area devoid of growth, in the first experiment equal in diameter to that of the window, in the second and third experiments slightly larger than that of the window (3 cm. as compared with 2·5 cm.); the serum in these circular areas, except for a narrow zone around the periphery of the area which remained clear, was covered with a dull film, probably of salts, which microscopically showed a few tubercle bacilli.

Experiments 4, 5, 6, and 7. Kromeyer lens. Exposures—1 minute (H. 110), 3 minutes (H. 85), 5 minutes (H. 85), 8½ minutes (H. 85). In experiments 6 and 7 the glass lids of the dishes were without quartz windows. In each case growth appeared around the margins of the inoculated area only, leaving in the centre of the area an irregular sterile patch 6 cm. in greatest diameter.

The experiments show that the growth of the tubercle bacillus is inhibited by the rays both from a Finsen and from a Kromeyer lens, and that the rays from the Kromeyer have greater potency than those from the Finsen.

PATHOGENICITY OF THE CULTURES.

The virulence of the cultures is considered in two sections of which one (*a*) deals with original virulence the other (*b*) with virulence after passage through the animal body.

(*a*) ORIGINAL VIRULENCE.

Cultures from each of the twenty viruses have been tested on the calf, rabbit, monkey and guinea-pig, and cultures from some of the viruses have also been tested on other species of animals. General descriptions of the results of these inoculations are here given for each species, and in the case of the calf, rabbit, monkey and guinea-pig the results with each group of cultures are considered separately.

From each of three viruses (H. 53, 71, and 110), cultures isolated from material removed on two separate occasions have been tested. No differences in virulence were brought out between the different strains of H. 71 or of H. 110. In the case of H. 53 the strains from the second sample of material gave more severe results than that from the first in calves but not in other species of animals.

Calves.

The virulence for the calf of each of the twenty lupus viruses has been tested by the subcutaneous inoculation of culture obtained from the lupus nodules either through the guinea-pig or direct (twice).

Altogether 38 calves have been inoculated ; 26 with the cultures possessing the cultural characters of bovine tubercle bacilli, and 12 with the cultures which grow like human tubercle bacilli.

Division I.—Of the nine viruses in this division only one, H. 110. "J.B." has proved equal in virulence to a bovine virus. Three calves (1483, 1491, 1515) were inoculated each with a different strain of culture, the dose in each case being 50 milligrammes ; one of the strains had been isolated from material taken from the patient six months after that which furnished the other two. The three calves died in periods varying from 17 to 40 days of general tuberculosis which differed in no wise from that set up by bovine tubercle bacilli.

The other eight viruses in this division have exhibited lower virulence than H. 110, and have varied considerably among themselves in their pathogenicity ; a diversity of results has in some instances been produced by the same virus. Seven of the viruses are dealt with in order of virulence ; the eighth ("D.H.") is considered last on account of the differences in the results produced by the (*a*) and (*b*) cultures.

Virus H. 100. "R.S." was inoculated into four calves of which two received 50 and two 100 milligrammes of culture. One of the calves (1523, dose 50 milligrammes) was killed 73 days after inoculation when dying of general tuberculosis ; the lesions in this animal exactly resembled lesions produced by bovine tubercle bacilli. Another calf (1419, dose 50 milligrammes) showed when killed 122 days after inoculation generalised tuberculosis of a not very severe type but obviously progressive in certain regions.

The other two (1547 and 1409), each inoculated with 100 milligrammes of culture were killed in apparent good health in 95 and 119 days and showed generalised tuberculosis retrogressive in character and not severe.

Virus H. 105. "G.S." was inoculated into two calves, of which one (1449) received 48, the other (1405) 92 milligrammes. Both were in apparent good health when killed 130 and 101 days later respectively, and showed generalised tuberculosis, not severe in one, of moderate severity in the other ; the lesions in both cases were retrogressive in character and few bacilli were found in smear preparations made from them.

Virus H. 107. "H.H." produced in two calves (1453 and 1497, doses 50 and 80 milligrammes) in 126 and 104 days slight generalised retrogressive tuberculosis, not much more severe than that which the human tubercle bacillus frequently gives rise to.

Virus H. 108. "H.R." also produced in two calves (1417 and 1421, doses 50 and 88 milligrammes) slight generalised tuberculosis more widespread than in the calves inoculated with H. 107.

Virus H. 85. "H.B."—50 milligrammes of this virus caused slight retrogressive generalised tuberculosis in one calf (1289), while in another (1331) inoculated with 96 milligrammes the tuberculosis was limited to the site of inoculation and nearest gland.

Virus H. 111. "S.E." gave rise in two calves (1429 and 1459), dose 50 milligrammes each, to very slight disseminated tuberculosis similar to that often produced by human tubercle bacilli.

Virus H. 91. "H.S." produced in a calf (1353, dose 50 milligrammes) very slight tuberculosis limited to the site of inoculation and nearest gland.

Virus H. 53. "D.H." (*a*) and (*b*). The original material of virus (*b*) was material removed from the patient $3\frac{1}{12}$ years after that of (*a*).

The first experiments with (*a*) are detailed in the 2nd Interim Report of the Commission, and are summarised on page 38 of this Report : three calves (905, 977, 1001) each of which received 50 milligrammes of culture subcutaneously developed generalised tuberculosis not severe and not fatal within the period of observation. The culture from (*a*) was tested again when it had been in cultivation 688 days ; it produced in two calves (1135 and 1155), dose in each case 50 milligrammes, slight generalised retrogressive tuberculosis very similar to that produced by the first experiments.

The cultures from—(*b*) were inoculated subcutaneously into three calves

(1545, 1507, 1535), each receiving 50 milligrammes. Two died in 52 and 63 days of general tuberculosis ; the third was killed when in apparent good health 103 days after inoculation and found to have slight generalised tuberculosis similar to that which had been produced in several cases by culture—(*a*). The tuberculosis in the two calves which became fatally infected was in certain of its features unlike that which a typical bovine tubercle bacillus would have given rise to within the same periods of time. The lungs presented an appearance familiar in calves fatally infected by intravenous inoculation of tubercle bacilli ; they were extensively hepatised and beset with minute tubercles, not large caseating nodules such as are found in animals which have succumbed to tuberculosis seven to eight weeks after the inoculation of bovine tubercle bacilli. The liver in each case was practically normal, only one minute tubercle being found in one and a few in the other ; in acute bovine infections the liver always contains a number of nodules which on the surface give rise to typical 'mushroomed' growths. The lesions in other parts of the bodies of these calves could not be distinguished from lesions produced by bovine tubercle bacilli.

The—(*b*) cultures of this virus have produced, therefore, more severe disease in the calf than the—(*a*) culture isolated from the patient $3\frac{7}{12}$ years previously.

The lupus viruses which grow like bovine tubercle bacilli have exhibited therefore great variation in virulence for the calf, and have produced in the animals inoculated disease ranging with slight gradations from a rapidly fatal general tuberculosis to tuberculosis limited to the site of inoculation and nearest glands. Summaries of the *post-mortem* notes of these animals are given on pages 72–76.

Division II.—Ten of the eleven cultures in the second division were inoculated subcutaneously, each into one calf, the eleventh was inoculated into two calves ; the doses varied from 43 to 88 milligrammes.

The calves with the exception of one which died prematurely of renal disease remained well, and when killed in periods varying from 95 to 123 days showed only slight disease ; in two cases the disease was confined to the seat of inoculation, one showing merely slight thickening of the skin and subcutaneous tissues ; in four there was besides a local lesion slight retrogressive tuberculosis of the nearest gland ; in six in addition to local disease there was a varying number of scattered minute retrogressive lesions in the internal organs and glands.

The most severely affected of the latter calves (1153, H. 71) had not more severe disease than has often been produced by a typical human tubercle bacillus. The least severely affected of the calves in this group, on the contrary, had less disease ; among the calves inoculated with cultures of human tubercle bacilli there is none in which the gland adjacent to the local lesion was normal ; in this series there are two calves (1457 and 1403, inoculated with Viruses H. 103 and H. 106) with local lesions only, one of which was a patch of fibrous tissue without trace of caseation or calcification, the other the remains of a ruptured abscess.

Rabbits.

Cultures from each of the twenty lupus viruses have been inoculated into a series of rabbits intravenously and subcutaneously ; the doses for the intravenous inoculations were 1·0, 0·1 and 0·01 milligramme (in one case a dose of 9·0 milligrammes, in another 0·001 milligramme was given) ; for the subcutaneous inoculations the doses ranged from 1 to 66 milligrammes, one rabbit at least in each series receiving 10 milligrammes or more.

The results with each division are considered separately.

Division I.—Only one of the nine viruses in this division has proved equal in virulence to a bovine virus. This was H. 110. "J.B." which produced rapidly fatal tuberculosis in the three calves subcutaneously inoculated with it. Seven rabbits inoculated *intravenously*, the doses varying from 1 to 0·01 milligramme, died of miliary tuberculosis in periods varying from 14 to 32 days, the three inoculated with 0·01 milligramme all dying after the same period, 32 days. Twelve rabbits inoculated *subcutaneously* with four different strains of the virus, the doses

ranging from 1 to 50 milligrammes, died in from 25 to 61 days of general tuberculosis indistinguishable from that set up by bovine tubercle bacilli.

The remaining eight viruses have exhibited a varying degree of lower virulence.

Seven of these viruses (H. 100, H. 105, H. 107, H. 108, H. 53 (*a*) and (*b*), H. 85, H. 111) produced fatal general tuberculosis in every rabbit into which they had been *intravenously* inoculated and no marked or constant difference either in the duration or the character of the disease was observed between the different viruses after this mode of inoculation.

The inoculation intravenously of 1 and 0·1 milligramme gave rise in all but three rabbits to general miliary tuberculosis anatomically indistinguishable from that set up by an equivalent dose of bovine tubercle bacilli, but causing death after a slightly longer period ; the duration of life of three of the rabbits inoculated with 0·1 milligramme was considerably prolonged, the animals living 80, 110, and 136 days. The average duration of life of rabbits inoculated intravenously with 0·1 milligramme of bovine tubercle bacilli was 19·6 days.

The delay of fatal result was greatly increased in a still larger proportion of the rabbits intravenously inoculated with 0·01 milligramme (average duration of life after an equivalent dose of bovine tubercle bacilli, 27 days). Of thirteen rabbits inoculated with this dose seven died of general tuberculosis in periods varying from 117 to 174 days, four in from 56 to 78 days and two in 41 and 43 days. The two latter animals were inoculated one with culture from H. 105, the other from H. 53 (*a*), and their early death was possibly due to high individual susceptibility, since other rabbits inoculated with larger doses of these viruses lived longer periods. The tuberculosis in the four which died in from 56 to 78 days closely resembled that produced by the intravenous inoculation of small doses of bovine tubercle bacilli. The tuberculosis in the animals which lived 117 to 174 days was similar anatomically to that in the more acute cases, but the lesions exhibited definitely retrogressive characters. These animals did not die at an early period probably because the tubercles were not so numerous in their lungs and the amount of consolidated lung tissue consequently not so great as in the more acute cases, and their long survival is to be attributed to the arrest in development of the lesions in the great organs, an arrest which has never been observed after the inoculation of bovine tubercle bacilli. In the kidneys of all the rabbits there were signs of repair ; the surface of the kidney was pitted and scarred and in the medulla there were many caseo-purulent streaks and in some cases the pelvis contained caseo-pus : these features are of common occurrence in the kidneys of rabbits intravenously inoculated with the human tubercle bacillus.

In many of the animals there were lesions in almost every region of the body —eyes, joints, intestines, omentum, &c., and in several tubercles were particularly numerous in the areolar tissues, clusters of tubercles being found in the subcutaneous tissues of the groins, axillae, back, &c., and in the subperitoneal tissues.

Abstracts of the post-mortem notes of the animals which lived a long time are given in the tables on pages 80–84.

After *subcutaneous* inoculation one of these seven viruses, H. 100, produced more severe results than the other six ; five rabbits were inoculated with the virus, each receiving 10 milligrammes, and they all died of general tuberculosis in periods varying from 91 to 337 days ; the disease in these animals was anatomically very similar to that set up by bovine tubercle bacilli, but was not so rapidly fatal.

With the other six viruses there has been great variation in the effects produced but in no case were they so severe as those which follow the inoculation of bovine tubercle bacilli.

Though there has been this diversity it is not possible to arrange the viruses in order of rabbit virulence, since the results obtained with individual viruses have been very irregular, in some instances presenting almost the same range of variation as the six collectively (*see* tables of rabbits inoculated with H. 105 and 108 on pages 90–93). The extent to which the rabbits were diseased appeared to depend more upon variations in individual susceptibility than upon differences in virulence or even in dose (compare Rabbits 1894 and 1971, page 91).

Nine of the thirty-five rabbits inoculated with the six viruses were killed, many in good health, after periods varying from 90 to 207 days. Five died of uncomplicated general tuberculosis in from 95 to 346 days. Fourteen died after lengthy periods from intercurrent disease or from unascertained causes ; in the latter cases the tuberculosis was always slight and not sufficient to account for death. The remaining seven rabbits died prematurely, but the majority of these latter lived longer than rabbits inoculated with bovine tubercle bacilli usually do, and in every case the tuberculosis was slight.

The following is a summary of the lesions found in the rabbits inoculated with these six viruses.

The local lesion was usually a thin-walled cyst with caseo-purulent contents similar to that produced by human tubercle bacilli ; sometimes it was firm sometimes ulcerated. The nearest glands were tuberculous in all but one case (1972, H. 105).

Internally the disease in the majority of the animals was slight and was limited to the lungs and kidneys which contained scattered miliary tubercles ; occasionally there were tubercles also in the spleen, liver, and some of the abdominal lymphatic glands. In the more severely affected rabbits the lungs showed, besides discrete tubercles, tuberculous patches in the margins and perhaps on the dorsal borders of the caudal lobes, the type of disease produced resembling that frequently met with after the intravenous inoculation of human tubercle bacilli. The kidneys in a few cases showed on the surface projecting nodules, similar to those produced by bovine tubercle bacilli, which on section penetrated deeply into the kidney substance extending in some cases to the apex of the papilla, and sometimes there was a very large mass with a mulberry-like surface extending to the apex of the papilla as a wedge. In the rest of the cases pits and irregular scars were seen on the surface, caseous tubercles in the cortex, caseous streaks and foci in the medulla and caseo-pus in the pelvis ; occasionally projecting nodules were also seen.

Thus in a very large majority of the cases the tuberculosis produced in rabbits by subcutaneous inoculation of these viruses in the lungs and kidneys closely resembled that set up by human tubercle bacilli and in those cases in which no other than the latter organs were affected the effects produced by the two kinds of bacilli were very similar.

But whereas human tubercle bacilli inoculated subcutaneously have never given rise to disseminated tuberculosis in regions of the rabbit's body other than the lungs and kidneys,* or to fatal tuberculosis, each of the six viruses has produced in at least one of the rabbits subcutaneously inoculated lesions either in joints, testes, eyes, bones, areolar tissues or serous membranes, and five of them have caused fatal tuberculosis.

Subcutaneous inoculation as well as intravenous inoculation demonstrates therefore that the six viruses (H. 105, H. 107, H. 108, H. 53 (*a*) and (*b*), H. 85, H. 111) have higher virulence for the rabbit than the human tubercle bacillus.

The remaining virus of the nine in this division, H. 91. " H.S.", produced very slight disease in four rabbits, displaying lower virulence than an average human tubercle bacillus. The rabbits were killed 235 days after inoculation ; two inoculated intravenously (doses slightly less than 1·0 and 0·1 mg.) showed two or three minute foci in the lungs and no disease elsewhere ; two inoculated subcutaneously (doses 50 and 10 mgs.) showed besides a local lesion in one case some caseo-pus in the pelvis of one kidney and in the other two tubercles in the lungs only.

Division II.—Of the eleven cultures in this division H. 99. " L.K." was the most virulent. Intravenously inoculated it produced in one rabbit, dose 1·0 mg., miliary tuberculosis fatal in 21 days, and in another, dose 0·1 mg., widespread general progressive tuberculosis fatal in 143 days. A rabbit inoculated subcutaneously with 50 milligrammes died in 89 days and showed local tuberculosis, moderately severe tuberculosis of the lungs, very slight tuberculosis of the kidneys and no disease elsewhere† ; another inoculated with 35 milligrammes showed when killed 144 days

* In one or two instances lesions have been found on serous surfaces of rabbits inoculated with human tubercle bacilli.

† The tuberculosis in this animal did not appear to be sufficient to account for death.

later a local lesion, chronic and not severe tuberculosis of the lungs and no disease elsewhere.

The virulence of this virus is not exceptionally high, results as severe have been produced by human tubercle bacilli.

The virulence for rabbits of the other ten viruses in this division was low, the majority exhibiting much lower virulence than an average human tubercle bacillus.

Slight variations in the virulence of these viruses were brought out by intravenous inoculation. Three of the rabbits inoculated intravenously died within four weeks apparently from tuberculosis ; but these results may be ascribed to high individual susceptibility, for other rabbits inoculated with the same virus lived long periods and showed when killed very slight tuberculosis. Excluding these as exceptional reference to the tables shows that four of the viruses (H. 92, H. 109, H. 71, H. 114) gave rise to a mild form of generalised tuberculosis while the others produced either insignificant lesions in the lungs or in the kidneys or in both, or no tuberculosis at all.

After subcutaneous inoculation 16 out of 25 rabbits (all animals which died prematurely are excluded) showed a local lesion only, 3 had besides a local lesion slight disease of the nearest glands, and 4 had in addition to local tuberculosis one or two tubercles in the lungs ; the remaining two which showed very slight generalised tuberculosis had been inoculated with two of the viruses (H. 92 and H. 109), which produced slight general tuberculosis when inoculated intravenously.

Rhesus Monkeys.

The rhesus monkey has been shown to be highly and equally susceptible to the bovine and to the human tubercle bacillus, the inoculation of either kind of bacillus giving rise to rapidly fatal generalised progressive tuberculosis, even in such small doses as 0·0001 milligramme.

In view of this high and equal susceptibility to cultures which vary in virulence for the calf and rabbit so greatly as the bovine and human tubercle bacillus it was not anticipated that a culture with an intermediate degree of virulence for the calf and with moderately high virulence for the rabbit would exhibit low virulence for the monkey.

The production of chronic tuberculosis with the culture from Virus H. 53. " D.H. " (*a*), the first lupus culture tested on the monkey, was therefore unexpected and led to the decision to test all lupus cultures on the monkey whatever their virulence might be for other animals.

The virulence of each of the twenty viruses has accordingly been tested on the rhesus monkey, two or more animals being used for each virus ; the method of inoculation was the subcutaneous and the standard dose 1 milligramme, though smaller and larger doses have in some instances been inoculated. Cultures from six of the viruses have also been used to feed monkeys.

For the experiments only young monkeys have been employed as these are less liable to be suffering from spontaneous tuberculosis than older animals. In only two instances out of the total number of young monkeys imported during the last three years have naturally acquired lesions of tuberculosis been found.

The young rhesus monkey has however as an experimental animal several disadvantages. It very readily under adverse conditions such as exposure to cold (through temporary failure of heating arrangements) or ill-usage from companions falls into a low state of health and dies ; in these cases it has been the exception to find on post-mortem examination pathological changes sufficient to account for death.

Out of 59 monkeys subcutaneously inoculated with lupus cultures 8 have died too soon to yield results of experimental value. 11 have died prematurely but after periods within which animals inoculated with bovine or human tubercle bacilli would have shown severe if not fatal tuberculosis ; these prematurely terminated experiments have been of some value ; though they are no use for comparative purposes they have given some information as to the virulence of a virus.

Of the twenty lupus viruses only three have produced in all the monkeys inoculated the acute and rapidly fatal tuberculosis characteristic of the bovine or human tubercle bacillus. One of these viruses is H. 110. " J.B.", the virus in the first division which exhibited for calves and rabbits the high virulence of the bovine tubercle bacillus. The other two viruses are H. 92. " D.N." and H. 99. " L.K.", both of which are identical in cultural characters and virulence for the calf and rabbit with the human tubercle bacillus

One milligramme of culture of each of these three viruses produced in a monkey acute miliary tuberculosis which was fatal within 39 days; 0·1 and 0·01 milligramme of H. 110 and H. 99 caused severe general tuberculosis in four monkeys which died in from 26 to 53 days.

The remaining viruses in each division showed a varying degree of lower virulence. The results with each division are now considered separately.

Division I.—So many of the monkeys inoculated with the remaining eight viruses in this division have died prematurely that it is not possible to arrange the viruses exactly in the order of their virulence.

H. 105 has yielded the most severe results, two monkeys, each inoculated with 1 milligramme, dying of general tuberculosis in 47 and 56 days.

H. 100 was inoculated into four monkeys, the dose in each case being 1 milligramme; in two the experiment terminated prematurely, another died in 48 days and showed slight disseminated tuberculosis, the fourth died in 86 days of general tuberculosis of no great severity.

H. 107. One monkey inoculated with 1 milligramme died in 50 days of moderately severe general tuberculosis, but in another which died in 49 days from some unascertained cause slight general tuberculosis only was found. Three other monkeys inoculated with this virus died prematurely.

H. 108 produced in one monkey, dose 1 milligramme, general tuberculosis which caused death in 96 days; a fellow monkey died of spontaneous tuberculosis.

H. 53 (*a*). With this virus seven monkeys were inoculated subcutaneously. One inoculated with 10 milligrammes was killed when dying of general miliary tuberculosis in 32 days. Four received each a dose of 1 milligramme; of these one died in 42 days and showed very slight general tuberculosis, another died in 41 days of general tuberculosis moderately severe in the spleen but slight elsewhere, a third killed when ill after 92 days showed general tuberculosis of moderate severity, the fourth died in 105 days from some unascertained cause and showed very slight general tuberculosis. Of the remaining two, one which received 0·1 milligramme and was killed when ill 209 days after inoculation had general tuberculosis severe in the lungs and most of the lymphatic glands, slight in the abdominal organs; the other, dose 0·01 milligramme, died in 51 days, and the only tuberculous lesion found was at the seat of inoculation.

H. 53 (*b*). The experiments with the culture of this virus were unsatisfactory. Four monkeys were inoculated each with 1 milligramme and all died prematurely. Two lived beyond the period when animals inoculated with bovine tubercle bacilli would have succumbed to general tuberculosis and these showed only slight disseminated tuberculosis.

H. 85 proved less virulent than H. 53 (*a*). One monkey inoculated with 10 milligrammes had to be killed after 59 days on account of secondary infection of the local lesion; slight disseminated tuberculosis only was found at the post-mortem examination. Another monkey inoculated with 1 milligramme died of general tuberculosis in 132 days. A third inoculated with 0·1 milligramme was killed when well 97 days later and showed slight general tuberculosis. A fourth inoculated with 0·01 milligramme died in 271 days of chronic general tuberculosis severe in many of the glands but not severe in the organs.

H. 111. One monkey inoculated with 1 milligramme died in 62 days of general tuberculosis, but another inoculated at the same time with 0·1 milligramme remained well and when killed 242 days later showed chronic general tuberculosis.

H. 91. "H.S." proved to be the least virulent of all the viruses in Division I. Two monkeys were inoculated one with 1 milligramme the other with 0·1 milligramme and were killed when in moderately good health 197 and 203 days later respectively; both had general tuberculosis of a chronic type.

Division II.—As stated above, two of the viruses, H. 92 and H. 99, exhibited full virulence for the monkey. Of the remaining nine viruses in this division the most virulent is H. 109 and its virulence falls very little below that of the first two; the conclusion that it has lower virulence is based upon the result in one monkey which died of general tuberculosis 80 days after 0·1 milligramme subcutaneously (no monkey inoculated with 0·1 milligramme of the bovine or the human bacillus has lived longer than 54 days); a monkey inoculated with 1 milligramme died of general tuberculosis in 30 days.

Next come the two viruses H. 112 and H. 101, each of which in doses of 1 milligramme produced fatal general tuberculosis in one monkey and slight disseminated tuberculosis in another; the animals fatally infected with tuberculosis died in 48 and 51 days and those with slight tuberculosis in 45 and 77 days from other causes.

Two monkeys inoculated one with 1 milligramme of H. 71 (*b*) the other with 1 milligramme of H. 106 died in 36 and 40 days and showed slight general tuberculosis insufficient to account for death; the conclusion that these viruses have lower than standard virulence for the monkey is based upon the amount of disease in relation to the duration of life; monkeys inoculated with a typical human tubercle bacillus would have shown within these periods severe general tuberculosis. One of the viruses (H. 71) inoculated in a dose of 0·01 milligramme produced very slight tuberculosis in 48 days.

H. 114 gave rise in two monkeys (dose 1 milligramme) to general tuberculosis ending fatally in 100 and 109 days.

H. 84 and H. 103 appeared to have equal virulence; a monkey inoculated with 1 milligramme of H. 84 died in 110 days, and one inoculated with 1 milligramme of H. 103 died in 111 days, both of chronic general tuberculosis. Another monkey inoculated with 1 milligramme of H. 103 died in 102 days and showed only slight general tuberculosis. H. 84 was inoculated into two other monkeys; one received 10 milligrammes and died in 73 days of general tuberculosis not severe, the other received 0·01 milligramme and showed after 95 days very slight general tuberculosis.

The remaining virus, H. 102, is the least virulent of the viruses in Division II. Three monkeys were inoculated each with 1 milligramme, one died in 55 days and showed very slight general tuberculosis, another died in 156 days of pneumonia and not very severe chronic general tuberculosis, the third died in 183 days of chronic general tuberculosis.

The twenty lupus viruses have exhibited, therefore, a wide range of variation in their virulence for the monkey. Arranged in order of this virulence, beginning with the most virulent, the viruses in each division show a gradual decrease in pathogenic power, the most virulent producing rapidly fatal tuberculosis identical

with that produced by the bovine or the human tubercle bacillus, the least virulent producing chronic tuberculosis in one series fatal only after many months, in the other not fatal within the period of observation. (203 days). The lowest level in the virulence scale was reached by one of the viruses in Division I, H. 91 causing less severe disease than H. 102 the least virulent of the Division II viruses.

Abstracts of the post-mortem notes of all monkeys except those which died of typical acute tuberculosis are given on pp. 102–108 ; for a general description of the lesions produced in acutely infected animals see Vol. I. of this Appendix.

In the chronically infected monkeys the spleen was generally the most severely affected of the chief organs ; in one case one of the lungs was extensively tuberculous, due to direct infection from the enlarged vertebral glands. In several instances caseous nodules were found in the substance of the brain and patches of caseo-necrosis in the bones of the skull ; in one case one eye was tuberculous and disorganised.

Feeding Experiments.—Nine monkeys have been fed with cultures from six viruses. One monkey fed with 10 milligrammes of H. 110 died of general tuberculosis in 30 days. Another fed with 10 milligrammes of H. 100 died in 79 days and showed severe tuberculosis of the intestines and glands of the alimentary tract and slight disseminated tuberculosis.

The monkeys fed with culture from H. 85 (dose in one case 1 milligramme, in the other 0·1 milligramme) succumbed within 116 days to chronic general tuberculosis, severe in the glands of the alimentary tract but not elsewhere.

Two of three monkeys fed with culture from H. 53 died prematurely ; the third (dose 1·0 mg.) was killed when well 294 days after feeding and showed chronic general tuberculosis.

A monkey fed with 1 milligramme of culture from H. 84 was killed when well 139 days later and was found to have general tuberculosis of moderate severity.

A monkey fed with 10 milligrammes of Virus H. 102 died in 73 days of ulcerative colitis and showed slight tuberculosis, limited to small intestine and mesenteric glands.

The five viruses H. 100, H. 85, H. 53, H. 84, and H 102 produced less severe results than H. 110. The results of the feeding experiments are in agreement, therefore, with those obtained by subcutaneous inoculation.

Guinea-pigs.

At least one strain from each of the twenty lupus viruses has been tested on guinea-pigs, intraperitoneally and subcutaneously ; in some instances two different strains of the same virus have been tested.

The doses inoculated have been 1 milligramme and 0·1 milligramme, and in three cases larger doses have been used in addition.

For this species as for others the viruses in each of the two divisions have shown great variations in virulence.

Division I.—Among the nine viruses in this division only one H. 110. "J.B.", has proved equal in virulence to a bovine tubercle bacillus ; three guinea-pigs inoculated intraperitoneally died in from 16 to 21 days, and three inoculated subcutaneously in from 35 to 69 days, of general tuberculosis identical with that set up by the bovine tubercle bacillus.

The other eight viruses have all exhibited lower virulence. Several of the guinea-pigs inoculated with these viruses have died within the maximum period of survival of animals inoculated with bovine tubercle bacilli but in all the disease was less severe than that which the bovine tubercle bacillus habitually produces. In the other guinea-pigs the duration of life was prolonged, in some considerably, when compared with that of guinea-pigs inoculated with equivalent doses of bovine tubercle bacilli, and the disease was not only less acute but was with very few exceptions less severe than in animals infected with bovine tubercle bacilli.

The tuberculosis in most of these animals displayed just those features which distinguish in the majority of instances cases of infection with human from those with bovine tubercle bacilli. These were the less severe implication of the lymphatic glands other than the nearest, the absence, or presence in slight degree, of caseation in tubercles in the lungs and the frequently slighter severity of the tuberculous processes in the liver and spleen.

The latter organs in some instances showed great enlargement and were extensively caseo-necrotic, the liver being very fatty. But in many cases the spleen though enlarged was not necrotic and contained discrete grey nodules or was peppered with grey points ; the liver also in many cases was not at all or only slightly enlarged and contained small irregular yellow foci or minute grey foci. The lungs were usually crepitant and contained tubercles which were grey or only slightly caseous in the centre ; in one case there were caseous nodules and solid caseating patches.

The most constant and striking difference between the tuberculosis produced

by these viruses and that due to the bovine tubercle bacillus was presented by the lymphatic glands. The appearance of these glands, excluding always those adjacent to the site of inoculation, varied with the duration of life of the guinea-pig. In guinea-pigs which died in from three to six weeks some of the lymphatic glands such as the sternal bronchial coeliac or portal showed slight enlargement and perhaps a caseous focus or two, while the others were not enlarged and were free from cascation. In animals which lived rather longer periods of time the lymphatic glands generally were enlarged though not usually to any great extent and some, chiefly those mentioned above, showed caseous patches or foci in the cortices.

In the more chronic cases the glands all over the body were enlarged and very indurated ; they were composed of dense fibroid tissue of a brownish colour, some showed caseous and softened areas, others caseous or calcareous foci, others no sign of cascation or calcification.

Division II.—In this division two of the viruses (H. 99, H. 92) caused in the guinea-pigs inoculated intraperitoneally and subcutaneously fatal general tuberculosis differing in no wise from that produced by the human tubercle bacillus.

The virulence of a third virus, H. 71, closely approximated to, but on the whole was slightly lower than, that of H. 99 and H. 92.

A few of the guinea-pigs inoculated with the remaining eight viruses also died within the time generally taken by human tubercle bacilli to produce fatal general tuberculosis, but in these cases the tuberculosis was not severe, the liver and spleen showing in nearly every case grey tubercles and no necrotic patches and the lymphatic glands slight or no evidence of tuberculosis.

The duration of life of all the other guinea-pigs, both after intraperitoneal and subcutaneous inoculation, exceeded in some instances very considerably the average duration of life of guinea-pigs inoculated with human tubercle bacilli.

Of those inoculated intraperitoneally with the eight viruses (16 in number, one with 10 milligrammes) all but two died within 59 days and showed a mild generalised tuberculosis the characteristic features of which were slight peritoneal disease, absence of large necrotic patches in liver and spleen which contained grey (in the liver sometimes yellowish) foci, and the slight implication of the lymphatic glands many of which in each guinea-pig were normal in size or only a little enlarged and without naked-eye evidence of tuberculosis. Of the two guinea-pigs that remain one (3057, dose 0·1 mg., Virus H. 102) died in 47 days and showed slight disease of the peritoneum, grey points in the liver and a slightly enlarged spleen and no disease elsewhere ; the other (3059) inoculated with 1·0 milligramme of H. 103 showed after 142 days a slightly thickened omentum, a normal spleen, two or three caseo-purulent nodules in the liver, some caseo-pus in the medulla of one kidney, two nodules and a few tubercles in the lungs and a focus or two in the inguinal and the mesenteric glands.

Of those guinea-pigs inoculated subcutaneously (23 in number, two with 10 milligrammes) 2 died in 39 and 40 days, 16 in periods varying from 100 to 257 days and five in 454, 462, 504, 574 and 855 days respectively.

The first two showed general tuberculosis which was less severe than is usually produced by a human tubercle bacillus.

In the series of animals whose duration of life was 100 to 257 days the majority died of general tuberculosis closely resembling the more chronic forms of tuberculosis set up by the human tubercle bacillus (*see* Vol. I. of this Appendix). Unusual results were obtained in three of these guinea-pigs ; one (3032) inoculated subcutaneously with 0·1 milligramme of H. 106 showed after 218 days local tuberculosis only ; in another (2986) inoculated with 1·0 milligramme of H. 84 which died in 256 days the disease was atypical ; there were caseo-purulent foci in the nearest glands, fibrotic changes in the sternal and fibroid tubercles in the portal glands, cirrhosis of the liver with a few greyish-white points in the substance, fluid in the peritoneal and pleural cavities, slight enlargement of the spleen and collapse and fibrosis of the greater part of the lung ; no tubercle bacilli were found in the organs and only one in pus from an inguinal gland. The third (3230) was inoculated with 10 milligrammes of H. 102 and showed atypical disease (*see* page 115).

Four of the five guinea-pigs (3076, 3058, 3056, 3034) which lived long periods of time showed a very chronic and not severe type of general tuberculosis which in three was distinctly retrogressive. In the fifth (2486) which died 855 days after the inoculation of one milligramme of H. 84 the lesions which had been produced in the different organs and glands had undergone fibrosis and were apparently

completely healed ; living tubercle bacilli were demonstrated in the spleen and lung of the guinea-pig.*

The viruses which yielded atypical results were H. 103, H. 106, H. 84, H. 102, and H. 101, and of these H. 106 and H. 102 were the least virulent. H. 109, H. 112, and H. 114 produced moderately severe chronic tuberculosis after subcutaneous inoculations and a mild form of disease after intraperitoneal ; they occupy therefore an intermediate position in the group as regards virulence for the guinea-pig.

The lupus viruses in Division II have shown for the guinea-pig greater variation in virulence than those in Division I. The most virulent virus in Division II, H. 99, was about equal in virulence to the most virulent in Division I, but in Division II virulence fell to a much lower level than in Division I. Two of the viruses in the former division consistently produced slight disease which in one case was limited to the site of inoculation and nearest glands and in others though generalised had become completely arrested. In Division I there were variations in the virulence of the viruses, but all were able to set up fatal progressive general tuberculosis in the guinea-pig.

Other Species of Animals.

Chimpanzees.—A young chimpanzee (9) was cutaneously inoculated with culture from Virus H. 85. "H.B." of Division I ; the skin of the back between the scapulae was scarified with a scalpel over an area five cm. square and 0·01 milligramme of the culture suspended in saline was spread evenly over the scarified area. The scarified area scabbed over and the skin quickly resumed its normal state. An abscess formed in the axilla which burst five months after the inoculation and left a discharging ulcer. The animal died 170 days after inoculation from an unascertained cause ; the skin at the site of inoculation was normal ; there was an ulcerated discharging gland in the right axilla and no sign of disease elsewhere. Two guinea-pigs inoculated with caseo-pus from the ulcer developed tuberculosis ; of two guinea-pigs inoculated with an emulsion of the spleen, one became tuberculous the other remained healthy. Cultures isolated from these guinea-pigs exhibited the cultural characters of the original culture.

Another young chimpanzee (11) was fed with one milligramme of culture from the same virus, H. 85. It was killed when in good health 271 days after it was fed ; the post-mortem examination showed small ulcers in the small intestine, enlargement and caseation of the mesenteric glands, of one pancreatic gland and of an axillary gland, a large caseous nodule in the spleen and one tubercle in the liver. The amount of disseminated disease was slight and much less than has always been produced in this species of animal by an equivalent dose of bovine or of human tubercle bacilli. (The virulence of this virus was low also for the rhesus monkey.)

Baboon.—Baboon 7, a young animal, was inoculated subcutaneously with one milligramme of culture from H. 53. "D.H." (*a*), Division I. It died in 35 days and showed early general miliary tuberculosis insufficient to account for death.

Pigs.—Nine young pigs have been inoculated subcutaneously with culture from the three viruses H. 53 (*a*), H. 85, Division I, and H. 92 of Division II.

Virus H. 53 (*a*) was inoculated into five pigs, two receiving 50 milligrammes, two 10 milligrammes, and one 1 milligramme. One of the pigs (121) inoculated with 50 milligrammes died in 146 days of tuberculous pneumonia ; the abdominal organs were normal but most of the abdominal lymphatic glands as well as the bronchial contained caseous nodules. The other four were killed in apparent good health in periods varying from 123 to 366 days and showed generalised tuberculosis ; the disease was of moderate severity in three, but exhibited retrogressive characters.

H. 85 was inoculated subcutaneously into two pigs one receiving 50 the other 10 milligrammes of culture. The former (115) was killed 307 days later and showed slight generalised retrogressive tuberculosis. The other (117) was killed 268 days after inoculation ; the condition of this animal was very good but the post-mortem examination revealed severe general tuberculosis, the organs and glands containing large nodules which in the organs were caseous and encapsuled and in the glands caseous and softened.

For the pig therefore, as for the calf and rabbit, these two viruses possessing the cultural characters of bovine tubercle bacilli exhibit lower virulence than the bovine tubercle bacillus but higher virulence than the human tubercle bacillus.

---

* Abstracts of the post-mortem notes of all the guinea-pigs mentioned above are given on pages 114 and 115.

H 92, a virus with the cultural characters and virulence of the human tubercle bacillus, was inoculated into two pigs (Nos. 107 and 109) the dose in each case being 50 milligrammes; they were killed after 133 and 159 days respectively and showed slight disseminated tuberculosis; both eyes of one pig and one of the other showed corneal ulceration and panophthalmitis; tubercle bacilli were found in the fluid from the anterior and posterior chambers.

Six young pigs were fed on alternate days during 14 days, each receiving on each occasion the growth from one serum tube; two of the pigs were fed with culture from H. 110, a typical bovine tubercle bacillus, two with culture from H. 100, a bovine culture with slightly less than bovine virulence, and two with culture from H. 102, one of the least virulent of the luxuriantly growing viruses. All the pigs were killed in good health in periods varying from 111 to 146 days. The pigs fed with the typical bovine virus were the most severely affected but both showed slight retrogressive generalised tuberculosis. One of the pigs fed with H. 100 had very slight disseminated retrogressive tuberculosis; in the other the tuberculosis was limited practically to the glands which drain the alimentary tract. Of the two fed with H. 102 one was free from tuberculosis the other showed two tubercles in a submaxillary gland and no sign of disease elsewhere.

Goats.—Four goats have been inoculated subcutaneously with culture from three viruses, H. 53 (*a*), H. 85, Division I, and H. 109 of Division II.

Virus H. 53 was inoculated into two goats, one young the other adult, each receiving 10 milligrammes of culture. The young animal (Goat 65) died in 38 days of general miliary tuberculosis, severe in the lungs which were extensively consolidated. The adult (Goat 67) died in 59 days of general tuberculosis, the disease being more chronic than in goat 65 and most severe in the lungs; parts of the caudal lobes were solid and caseating and showed small cavities, the rest of the lungs being closely beset with calcareous miliary tubercles.

Virus H. 85 was inoculated into Goat 63, a kid, the dose being 10 milligrammes. It was killed when very ill 402 days after inoculation and showed a very severe slowly progressing general nodular tuberculosis.

H. 109, a slightly virulent luxuriantly growing virus, produced in an adult goat (61) in a dose of 1 milligramme a local lesion only.

Horses.—Four yearling colts have been inoculated, two subcutaneously and two intravenously, with culture from two viruses, H. 85, Division I, and H. 92, Division II.

Fifty milligrammes of H. 85 subcutaneously inoculated produced in Horse 5, killed in good health 112 days after inoculation, slight disseminated retrogressive tuberculosis.

One hundred milligrammes of H. 92 inoculated subcutaneously produced in Horse 9, duration of life 136 days, a linear scar at the seat of inoculation, two fibro-calcareous patches in the nearest glands and a few minute retrogressive foci internally.

Of the two horses inoculated intravenously one, Horse 11, which received 10 milligrammes of culture from H. 85 died in 51 days of acute general tuberculosis. There was no definite tubercle formation but tubercle bacilli were very numerous in the tissues and were exceptionally numerous in the mucous membrane of the small intestine (scraping).

The other horse (7) inoculated intravenously received 10 milligrammes of Virus H. 92 and was killed 137 days later, a few retrogressive tubercles were found in the lungs and bronchial glands and one grey tubercle in the liver.

Cats.—Two cats were inoculated, one subcutaneously and one intraperitoneally, each with one milligramme of culture from Virus H. 107, a virus with the cultural characters of a bovine tubercle bacillus; the subcutaneously inoculated animal showed after 99 days local tuberculosis and a few tubercles in the lungs; in the intraperitoneal animal killed after 262 days the tuberculosis was limited to the muscular wall of the abdomen and the omentum. The virulence of this virus has proved low also for the differential animals (calf and rabbit).

A kitten inoculated intraperitoneally with 50 milligrammes of H. 71 (Division II) died in 15 days; there was no naked-eye evidence of tuberculosis internally but tubercle bacilli were fairly numerous in smears made from the lung, spleen, and liver.

Rats.—Six rats were inoculated, five intraperitoneally and one subcutaneously,

with cultures from three of the viruses, H. 53, H. 71, and H. 106 ; the first of these grew like a bovine tubercle bacillus, the other two like a human tubercle bacillus.

The results were in agreement with those obtained with bovine and human tubercle bacilli. All the animals inoculated intraperitoneally became fatally infected and showed numerous tubercle bacilli in the organs but no definite tuberculous lesions.

Mice.—Four were inoculated with culture from H. 92, but all died prematurely.

The results of the inoculation experiments on other species of animals showed therefore that lupus viruses—whether bovine or human in cultural characters—which had less than standard virulence for the calf, rabbit, monkey, and guinea-pig, exhibited also a correspondingly lower degree of virulence for the chimpanzee, pig, goat, horse, and cat.

(*b*) VIRULENCE AFTER PASSAGE.

The investigation of the characters of the cultures obtained from the twenty lupus viruses has shown that these cultures fall readily according to their cultural features into one or other of two divisions ; these divisions correspond culturally to the two groups into which cultures from other parts of the human body have been divided. Animal experiments, however, have demonstrated that few of the cultures possess the virulence of the Group to which culturally they belong.

Of the nine cultures which grow like bovine tubercle bacilli only one (H. 110) has been found to possess the high virulence of the bovine tubercle bacillus. The rest have exhibited lower virulence, six displaying varying degrees of virulence intermediate between that of the bovine and that of the human tubercle bacillus, two having no higher virulence for the calf than a typical human tubercle bacillus. The virulence of these eight cultures was lower for the rabbit than the bovine tubercle bacillus, and for the monkey and guinea-pig than either the bovine or the human tubercle bacillus.

Similarly of the eleven cultures which grow luxuriantly only two can be regarded as possessing the virulence of the human tubercle bacillus ; this statement is based mainly upon the results of the inoculation of monkeys and guinea-pigs, in which only two of the cultures produced disease as severe as that produced by the human tubercle bacillus ; the other nine cultures varied in their virulence for the monkey and guinea-pig, some having very low virulence, others being almost equal in virulence to the human tubercle bacillus. Several of these cultures showed for the calf and rabbit also a grade of virulence lower than that of an average human tubercle bacillus.

In each division corresponding culturally to Groups I and II of the 2nd Interim Report, therefore, the cultures exhibit a wide range of variation in virulence, and form a series in which the virulence of the members composing it gradually diminishes from that typical of the group to a much lower level.

In Division I several of the atypical cultures approximated very nearly to the bovine tubercle bacillus in their virulence for the calf, and others produced in this animal a chronic form of generalised tuberculosis very similar to that which has been set up by small doses of bovine tubercle bacilli.

For these reasons it was thought that the cultures might be bovine tubercle bacilli, which had become attenuated in virulence either before their entry into or as a result of their residence in the human body.

This view, that the cultures are attenuated bovine tubercle bacilli, would get support if the virulence of the cultures were raised to the level of the bovine tubercle bacillus by residence in the animal body.

Cultures from six of the eight atypical bovine viruses, the six which produced in calves more severe disease than the human tubercle bacillus, have therefore been recovered and investigated after varying periods of residence in the body of the calf, and from three of the six after a single residence in other species of animals.

In the passage experiments with two of the cultures (H. 85 and H. 53 (*a*)) the bacilli were passed in one case through one and in the other through two long series of calves before they were finally tested.

In the other cases the bacilli were recovered after a single residence in the calf and tested as to their virulence. It was found that as a result of this single residence the virulence of some of the cultures was increased for the calf and rabbit while that of others was not. In the latter cases the culture, regained from the calf which had been inoculated to test the virulence of the first passage culture, was

inoculated into a third calf, and in some cases the process was repeated for a fourth calf. It happens therefore that in these passage experiments the bacilli were passed from calf to calf in the form of culture and not as in the passage experiments with H. 85 and H. 53 (*a*) in tissue emulsions. The virulence of the passage cultures and the final cultures obtained in each of these experiments was estimated for the calf* and rabbit, and sometimes for the monkey and guinea-pig.

The other animals from which Division I cultures were recovered and tested were the pig, rabbit, and rhesus monkey.

No passage experiments have been made with the cultures which grow like human tubercle bacilli (Division II), but in five instances the culture of a virus has been recovered from an animal (three monkeys, a calf, and a guinea-pig), and tested as to its virulence.

The results of the several passage experiments are given in detail, illustrated in many instances by marginal diagrams, and summarised (*see* pages 133–161). The detailed description is preceded in each case by a summary of the results of the inoculation of the original culture in those species of animals which have been employed to test the virulence of the culture after passage. These are given so that the comparison of the virulence of the passage cultures with that of the original culture may be readily made.

The animals which have been used for testing the virulence of the cultures are the calf, rabbit, monkey, and guinea-pig. The method of inoculating the calves in the passage experiments has been exclusively the subcutaneous method, but for testing the virulence of a culture the intravenous (for the rabbit) and the intraperitoneal (for the guinea-pig) methods have been occasionally employed in addition to the subcutaneous.

General Results of the Passage Experiments.

Observations have been made on the virulence after residence in the animal body of cultures from six of the lupus viruses which grow on artificial media like bovine tubercle bacilli, and from four of the viruses which grow like human tubercle bacilli. The six viruses with the cultural characters of bovine tubercle bacilli were H. 100, H. 108, H. 105, H. 107, H. 85, and H. 53 (*a*) and (*b*). Cultures from each of these viruses have been recovered and tested after varying periods of residence in the body of the calf. In a few instances cultures have been recovered from other species of animals and tested.

Division I.—Virus H. 100. "R.S." The culture was recovered from three of the calves which had been inoculated to test the virulence of the virus; the duration of life of the calves was 122, 119, and 73 days. One of these three strains was tested on the calf, the rabbit, the monkey and the guinea-pig; one on the calf and rabbit; and one on the rabbit only. Fatal general tuberculosis, identical in all respects with that set up by a bovine tubercle bacillus, was produced in every case.

The bacilli had in three separate instances therefore acquired the full virulence of the bovine tubercle bacillus during a single residence in the body of the calf.

The virulence of the culture was also raised for the rabbit to the level of that of a bovine tubercle bacillus by a single residence of 337 days in the body of the rabbit.

Virus H. 108. "H.R."—Three strains of this virus were recovered from two calves which had been inoculated with the original culture and tested as to their virulence.

The single strain from one of the calves exhibited the virulence of the original culture. Of the two strains from the other calf, the one derived from the lung was shown to possess for the calf, rabbit, guinea-pig, and monkey the high virulence of the bovine tubercle bacillus, while the one derived from the mediastinal gland was apparently unchanged in its virulence for these animals; the bacilli had increased in virulence in one part of the body of the calf but not in another. By residence in a second calf the latter strain (mediastinal gland) acquired full bovine virulence for the calf and rabbit.

Virus H. 105. "G.S."—This virus was passed through two series each of four calves, the total duration of residence being 384 and 335 days.

The culture recovered from the final calf of one of the series (*a*) had distinctly higher virulence for the rabbit and the guinea-pig than the original culture, but had not attained the full virulence of a bovine tubercle bacillus. That recovered from

* The final cultures of the H. 105 passage experiment were tested on the rabbit and guinea-pig only

the final calf of series β had slightly higher virulence for the rabbit (but not apparently for the guinea-pig) than the original culture.

The second calf in each series was more severely affected than the first calf, and it appeared that an increase in the virulence of the bacilli had ensued as a result of a single residence in the body of the calf; but the same cultures produced in other species of animals no more severe disease than the original culture, and the cultures regained from the severely affected calves as well as those from subsequent calves did not exhibit (for the calf) higher virulence than the original culture. The more severe results obtained in the second calves were probably due therefore not to increased virulence of the cultures but to greater susceptibility of the particular calves.

The virulence of the other three viruses was not increased for the calf by passage through the body of the calf; nor was it increased for the rabbit, except in the case of Virus H. 53. "D.H." (*a*), of which one calf passage culture displayed a slightly higher virulence for this animal than the original culture (*see* below).

Virus H. 107. "H.H."—This virus was passed through two series of three calves, the total duration of residence being 243 and 201 days. The final culture in each series had no higher virulence for the calf and rabbit than the original culture.

The second calf in one of the series was more severely affected than the first calf, but this severe result may be attributed, as in the case of H. 105, to high susceptibility of the particular calf, since the culture regained from this animal did not exhibit higher virulence than the original culture.

Virus H. 85. "H.B."—This virus was passed through a series of five calves in succession; the second and third calves were inoculated with emulsions of the tuberculous tissues of the preceding calf, the others with culture; the total duration of residence was 496 days. The culture recovered from the liver of the last calf, the most severely affected of the series, displayed no higher virulence for the calf and rabbit than the original culture.

Similarly, after a residence of 271 days in the body of a rhesus monkey the culture of H. 85 was unchanged in virulence for the monkey and the rabbit.

Virus H. 53. "D.H."—Cultures of this virus were obtained on two different occasions from the patient and both were used for passage experiments.

The first culture (H. 53. "D.H." (*a*)) was obtained when the patient, a girl, was 15 years old. When the culture had been in artificial cultivation 1 year and $10\frac{1}{2}$ months two passage experiments in calves were begun with it. The bacilli in these experiments were passed from calf to calf in emulsions of the tuberculous tissues of the preceding animal. The total duration of residence in one series was 429 days, in the other 506 days.

The final cultures and intermediate cultures in both series displayed no higher virulence for the calf than the original culture. For the rabbit the final culture of one series showed a slight but definite increase of virulence for the rabbit, and a final culture of the other series produced in this animal more severe results after subcutaneous, but not after intravenous inoculation, than the original culture.

Cultures of Virus H. 53 (*a*) have also been tested after a single residence in the body of the rhesus monkey. The original culture produced a very chronic form of tuberculosis in most of the monkeys inoculated, and from two of these (duration of life 209 and 294 days) cultures were isolated. These latter cultures had higher virulence for the monkey (four inoculated subcutaneously each with 1 milligramme died of general tuberculosis in from 51 to 78 days) but were not apparently increased in virulence for the rabbit.

The culture of H. 53 (*a*) was also recovered after a single residence (of 225 days) in the the body of the pig and a single residence (of 133 days) in the body of a rabbit following 91 days in a calf; in each case the culture was unchanged in its virulence for the rabbit.

After a residence of 127 days in the bodies of two goats in series the culture of H. 53 (*a*) was not increased in virulence for the calf or rabbit.

The culture used in the above experiments with Virus H. 53 (*a*) had been some time in artificial cultivation when the passage experiments with it began, and it is probable that the increase in virulence of the culture in the two instances recorded represents pathogenicity recovered by the virus during passage equivalent in degree to that of which it had been deprived by artificial cultivation.

The second culture of the virus, designated H. 53. "D.H." (*b*), was obtained from the patient $3\frac{7}{12}$ years after the first. It produced severe and fatal tuberculosis in two out of the three calves inoculated with it, but had not higher virulence for the rabbit than the —(*a*) cultures.

Each of the severely affected calves was the first of a series through which culture —(*b*) was passed.

The third calf of the first series (the second calf having died prematurely) was severely affected, but not more severely than the first calf; the second calf of the other series was more acutely affected than the first, the animal dying of tuberculosis in 39 days. The fourth calf of the first, and the third calf of the second series (the last in each case) developed no more than slight generalised retrogressive tuberculosis similar to that set up by H. 53 (*a*). The total duration of residence in one series was 176 days, in the other 91 days.

The virulence of the culture of H. 53 (*b*) for the rabbit was not increased by either of the calf passages; the final culture of one series produced in fact less severe disease in this animal than the original culture.

The calf passage cultures of Virus H. 53 (*b*) produced in monkeys severe tuberculosis which was not so quickly fatal as after equivalent doses of bovine tubercle bacilli; whether or no the virulence of these passage cultures was greater for the monkey than that of the original culture cannot be stated since all the monkeys inoculated with the latter died prematurely. It is interesting to note however that the virulence for the monkey of these calf passage cultures was practically equal to that of the monkey passage cultures of H. 53. "D.H." (*a*).

The cultural characters of the passage cultures of each of the six viruses, whether altered in virulence or not, were identical with those of the original culture.

Division II.—Four of the luxuriantly growing viruses, the virulence of which was distinctly lower than that of a typical human tubercle bacillus, were tested after a single residence in the animal body.

Virus H. 71. "L.V." (*a*) was unchanged in virulence for the rabbit after residing 95 days in the body of the calf.

Viruses H. 102 "N.H." and H. 114. "A.U." were not increased in virulence for the monkey or guinea-pig after a residence of 156 days and 100 days respectively in the body of the monkey.

Virus H. 84. "M.S."—In the case of this virus the culture recovered from a monkey 139 days after it had been fed with culture had higher virulence than the direct culture and was as virulent for the monkey and guinea-pig as a typical human tubercle bacillus. The culture recovered from a guinea-pig on the other hand after a residence of 855 days had no higher virulence for the guinea-pig, monkey, and rabbit than the original culture.

The recovered cultures in the case of each of the four viruses grew luxuriantly like the original culture.

The following is a summary of the results of the investigation of lupus viruses after residence in the animal body.

Of six viruses with the cultural characters but without the high virulence of bovine tubercle bacilli two were so increased in virulence after animal passage as to be indistinguishable from bovine tubercle bacilli in virulence as well as cultural characters. The virulence of one of these viruses (H. 100) was increased by a single residence in four different animals, three calves and one rabbit (duration of life—122, 119, 73, and 337 days). The virulence of the second virus (H. 108) was increased in one instance by a single residence in the body of the calf (125 days), and in another not until it had been passed through the body of a second calf (duration of life—99 days).

A third virus (H. 105) passed through two series each of four calves showed in one series an increase in virulence (but not to the level of a bovine tubercle bacillus) for the rabbit and guinea-pig, and in the other an increase for the rabbit but not for the guinea-pig; the virulence of these (the fourth passage cultures) was not tested on calves but the third passage cultures produced in these animals no more severe disease than the original culture.

The virulence of the remaining three viruses (H. 53 (*a*) and (*b*), H. 85, and H. 107), was unchanged (except H. 53 (*a*), which showed a slight increase in virulence for the rabbit after passage through the calf, and for the monkey after passage through the monkey), as were also the cultural characters, after residing for periods varying from 91 to 506 days in the body of the calf, and in the case of H. 53 (*a*) in the bodies of the pig, goat, and rabbit.

Three viruses of Division II. (H. 71, H. 102, and H. 114), the original

virulence of which was lower than that of a typical human tubercle bacillus, were unaltered in virulence by animal passage.

Another (H. 84) was apparently increased in virulence by a single residence in the body of a monkey (139 days), the recovered culture exhibiting the virulence for the monkey and guinea-pig of a typical human tubercle bacillus. The same virus was not increased in virulence by passage through a guinea-pig (855 days).

GENERAL SUMMARY.

The cultures of tubercle bacilli isolated from the lupus material have shown considerable variation in their properties.

Of the 20 viruses investigated only three have yielded cultures which are identical both in cultural characters and virulence with one or the other of the two established types of mammalian tubercle bacilli, the cultures from one of the viruses being typically " bovine," from two typically " human."

Of the remaining 17 viruses 8 have grown like bovine tubercle bacilli and 9 like the human tubercle bacillus but none has exhibited the virulence which has been shown to be characteristic of bacilli with such cultural characters.

The characteristics of the two standard types of bacilli in regard to virulence are briefly as follows :—The bovine tubercle bacillus when inoculated subcutaneously produces in young calves (dose 50 milligrammes) in rabbits (dose 10 milligrammes) and in monkeys and guinea-pigs (very small doses) a rapidly fatal general tuberculosis. The human tubercle bacillus on the other hand when inoculated subcutaneously in large doses is unable to produce in calves anything more than slight retrogressive general tuberculosis and never gives rise in rabbits to tuberculosis severe enough to cause death within three months ; for the monkey the human tubercle bacillus is as virulent and for the guinea-pig nearly as virulent as the bovine tubercle bacillus.

The 8 atypical lupus viruses with the cultural characters of the bovine tubercle bacillus proved to be less virulent than the bovine tubercle bacillus not only for the calf and rabbit but also for the monkey and guinea-pig, and the extent to which they thus fell below the standard in virulence varied.

Taking first the results of the inoculations into the calf and rabbit, 6 of the 8 viruses displayed for these animals virulence which was less than that of a bovine tubercle bacillus but greater than that of a human tubercle bacillus, and of these six H. 100 was the most and H. 85 the least virulent.

A feature of interest in connection with these six viruses was the irregularity of the results produced both in the calf and the rabbit by individual viruses.

Of the two viruses that remain, one, H. 111, exhibited for the rabbit but not for the calf higher virulence than the human tubercle bacillus, while the other, H. 91, appeared to be less virulent than the human tubercle bacillus both for the calf and the rabbit.

For the monkey the variations in virulence of the 8 atypical viruses roughly corresponded with those for the calf and rabbit ; and it is specially to be noted that viruses which like H. 100 and H. 105 fell very little below the bovine tubercle bacillus in virulence for the calf and rabbit and were therefore on a much higher level in the bovine and rabbit scale of virulence than the human tubercle bacillus, exhibited distinctly lower virulence for the monkey (and guinea-pig) than the human tubercle bacillus. The virus H. 91 which from the results it produced in the calf and rabbit would have been classed among the human tubercle bacilli was for the monkey the least virulent of the group and caused much less severe effects in this animal than the human tubercle bacillus.

For the guinea-pig the 8 viruses were all less virulent than the bovine tubercle bacillus and no clear gradation in virulence was brought out by this species of animal.

The other 9 lupus viruses with the cultural characters of the human tubercle bacillus all displayed lower virulence than the human tubercle bacillus. The degree to which the virulence fell short of the standard was shown by experiment on the monkey and the guinea-pig to vary widely. As might be expected no marked variations in the virulence of these viruses were brought out by the more resistant animals, the calf and the rabbit, in which ordinarily an average human tubercle bacillus produces when inoculated subcutaneously only slight disease ; the possession of a very low grade of virulence was demonstrated however in several of the viruses by the production in the rabbit of no disease or only slight disease after intravenous inoculation, and in the calf of changes confined to the site of inoculation.

Thus the lupus viruses in each Division, one containing 9 with the cultural characters of bovine tubercle bacilli, the other 11 with the cultural characters of the human tubercle bacillus have presented many grades of virulence ranging from standard to a very low level.

These variations in virulence are represented graphically in the table below. Three scales of virulence are drawn, the first for the calf the second for the rabbit and the third for the monkey.

The viruses possessing the cultural characters of bovine tubercle bacilli are printed in block type on the left side of each scale, those with the cultural characters of the human tubercle bacillus in italics on the right side. The viruses with the highest virulence are placed at the top of each scale, the level of standard virulence for each type of bacillus being indicated by a broad transverse line. The scale for the monkey is shorter than those for the calf and rabbit because the least virulent of the viruses was able to produce progressive tuberculosis in this animal.

Scales of Virulence of the Lupus Viruses for the—



The properties, cultural characters and virulence, of the tubercle bacilli isolated from the lupus nodules, do not appear to have any relation to the age of the patient or to the duration of the lupus in the individual.

In order to ascertain whether the lower than standard virulence of the atypical viruses was stable or unstable, observations have been made on the virulence of several of the viruses after a single residence in, or after passage through the bodies of animals.

In the first Division, six of the eight viruses were tested after residence in the animal body. In two instances (Viruses H. 100 and H. 108) the virulence was increased by residence both in the calf and in the rabbit, the recovered viruses being equal in virulence to a bovine virus. The relationship of these viruses to bovine viruses, which was indicated by their original properties, was by these experiments clearly established.

The virulence of the other viruses (excluding H. 105) was stable, no change resulting from repeated passage of them through the body of the calf.

With H. 105 there was apparently a slight increase in the virulence of the virus during its residence in the fourth animal of one of two series of calves.

Though passage failed to raise the virulence of these viruses, H. 53, H. 85, H. 105, and H. 107, to the level of H. 110, there can be little doubt, judging from their cultural characteristics and the effects they produced in calves and rabbits, that they are bovine viruses which have become degraded in virulence. H. 111 must also be

regarded as a bovine virus. It grows like a bovine tubercle bacillus, and though it produced only a limited retrogressive tuberculosis in the calf it caused progressive tuberculosis in the rabbit. As regards H. 91, if this virus was originally a bovine virus, the only attribute indicating its pedigree is its mode of growth (on which assumption it would follow that cultural characteristics are a more stable quality in the human body than virulence).

In the second Division four of the viruses have been tested after a single residence in the animal body; the virulence of three (H. 71, H. 102, H. 114) was unaltered, while the virulence of the fourth (H. 84) was apparently increased by residence in the body of a monkey. The virulence however of this virus, which was one of the least virulent of the viruses in this Division, was not increased by residence in the body of the guinea-pig; no conclusions, therefore, can be drawn from the single experiment on the monkey. Apart from the decisive proof of identity with the human tubercle bacillus such as would be afforded by the increase to standard virulence as a result of animal passage, the original properties of the viruses in this division sufficiently indicate their close relationship with the human tubercle bacillus; they possess the cultural characters of the human tubercle bacillus, their virulence for the calf and rabbit is low, and they have induced typical tuberculosis in all the monkeys and in the majority of the guinea-pigs inoculated with them, the effects produced in these animals differing from those following the inoculation of human tubercle bacilli only in their lesser severity.

The facts established with regard to the cultural characters and pathogenicity (original and after passage) of these atypical lupus viruses afford strong presumption that we are dealing with attenuated varieties in one case of the bovine tubercle bacillus, in the other of the human tubercle bacillus.

The question now arises—was the attenuation of the lupus bacilli antecedent or subsequent to entry into the individual affected with lupus?

If antecedent to entry then similar atypical forms should be occurring among the animals or the human beings which are the chief sources of human tuberculosis. But although 30 cases of bovine tuberculosis, 59 cases of swine tuberculosis, and 47 cases of pulmonary tuberculosis in human beings have been investigated by the Commission no tubercle bacilli have been obtained from these sources which are identical with any of the atypical varieties obtained from lupus. From the horse however cultures have in two instances been isolated which resemble atypical cultures in the first Division of the lupus series. Both these viruses were proved to be attenuated bovine viruses by the fact that their virulence was, by passage through the calf, raised to the level of that of a bovine tubercle baeillus. It seems unlikely that any of the lupus patients derived their infection from the horse since equine tuberculosis is not of frequent occurrence, while the flesh of horses is not commonly eaten by human beings.

There remains to be considered the possibility of attenuation subsequent to entry into the human body.

No attenuated forms either of the human or the bovine tubercle bacillus have been isolated from human tuberculous lesions other than lupus, though 115 cases, including nearly every variety of tuberculosis, have been examined.

If the attenuation of the lupus bacilli took place in the human body from which they were isolated it would seem that the influences favouring the change are resident in the skin only, or in more marked degree in the skin than in other regions of the body.

To ascertain whether tubercle bacilli do become degraded in virulence by residence in the cutaneous tissues a reinvestigation of the lupus from three of the patients was undertaken.

Material was obtained from one patient (H. 110) six months, from another (H. 71) two years, and from the third (H. 53) $3\frac{1}{2}$ years after the material for the first investigation was removed. It will be remembered that the Virus H. 110 had yielded at that investigation typical bovine, H. 71 slightly attenuated human, and H. 53 attenuated bovine tubercle bacilli.

In the first two cases no difference either in cultural characters or in virulence between the first and second group of cultures was detected; in the third the later obtained culture produced in the calf more severe results than the first but was not apparently more virulent for the rabbit. The cultural characters of the later strain of each of the three cases were identical with those of the first.

Residence in the skin of six months in one case, two years in another, and

$3\frac{7}{12}$ years in a third had not caused any diminution in the virulence of the bacilli or alteration in their cultural characters. It would be interesting to obtain cultures from these cases once more, especially from H. 110, and also from as many as possible of the other cases, and compare their properties with those of the cultures originally isolated.

Though no direct proof that bacilli lose virulence when resident in the skin has been secured, the gradation in virulence of the variants from the standard type, and the absence of similar varieties in the food animals (the cow and the pig†) and in other kinds of human tuberculosis strongly favour the view that it was in the cutaneous tissues of the lupus patients that the degradation in virulence took place.

There remains for consideration the question whether the bacilli of these variant cultures can be regarded as in transitional or intermediate stage of transformation from bovine into human tubercle bacilli.

As the bovine tubercle bacillus differs from the human tubercle bacillus both in cultural characters and virulence, it is permissible to anticipate that a gradual transition from the one type of tubercle bacillus to the other would be marked in its intermediate stages by forms which showed a change in cultural characters alone, in virulence alone, or in both properties simultaneously. And the question arises :—

Do any of the variant cultures stand in an intermediate position between the two types in either or both of these respects ?

First, as regards cultural characters. None of the cultures can be regarded as intermediate in this respect since it has been possible to classify every lupus virus either as a bovine tubercle bacillus or a human tubercle bacillus on the basis of cultural characters alone ; not one was in this sense equivocal. There is, however, the possibility that a bovine tubercle bacillus might have fully acquired the characteristic cultural features of the human tubercle bacillus whilst retaining a virulence that would entitle it to be classified among the bovine tubercle bacilli. But there was not found among the viruses of Division II any example of such a eugonic virulent virus.

Secondly, as regards virulence. Considering first the results in calves and rabbits, animals which have habitually been employed to differentiate between bovine and human tubercle bacilli, an inspection of the table on page 25 shows that there is a series of lupus viruses which in respect of virulence for these animals are intermediate between bovine and human tubercle bacilli ; all these viruses had the cultural characters of bovine tubercle bacilli.

Had the pathogenic powers of these viruses been lowered for the calf and rabbit alone, and not for the monkey and guinea-pig as well, the conclusion would have been inevitable that in these instances we were dealing with cultures which were becoming transformed. But inoculation experiments on monkeys and guinea-pigs, animals equally susceptible to both types of tubercle bacilli, have shown that these viruses were reduced in virulence for these species also ; in fact the nearer their virulence for bovines and rabbits approached that of the human tubercle bacillus, the lower it proved for the monkey and guinea-pig. Thus the apparent bridging of one gap was accompanied by disclosure of another equally broad.

It was to be anticipated that a bovine bacillus in process of transition into a human bacillus would, so long as it remained more virulent than that bacillus for the calf and rabbit, prove equally virulent with that bacillus for the monkey and guinea-pig ; and the circumstance that the lupus viruses in question did not fulfil this condition, that on the contrary they would need to re-acquire full virulence for the monkey and guinea-pig for classification with the typical human virus, precludes me from accepting them as transitional in type.

In my view, and on the facts so far observed, these dysgonic variant viruses are to be regarded as no more than attenuated varieties of the bovine tubercle bacillus just as the eugonic variants are to be regarded as attenuated human tubercle bacilli, and do not stand in any closer relation to the human tubercle bacillus than does the typical bovine tubercle bacillus.

A. Stanley Griffith.

---

† One of the 50 bovine cultures isolated from swine showed a slightly diminished virulence for the calf and rabbit, a virulence which was increased to standard by a single residence in the body of the calf.

CLASSIFICATION OF THE LUPUS VIRUSES ACCORDING TO CULTURAL CHARACTERS AND VIRULENCE.

Designation of Virus.	Age and Sex of Patient.	Duration of Disease.	Situation of Lupus.	Results of the Investigation of the Cultures.	
				Cultural Characters.	Pathogenicity.
H. 110. "J.B." (*a*)	10 years, male.	4 years	Face and trunk	Grow like a bovine tubercle bacillus (Class 1).	The cultures possess the high virulence of the bovine tubercle bacillus for the calf, rabbit, monkey, and guinea-pig.
(*b*)	10½ years	4½ years			
*H. 100. "R.S."	37 years, female.	17 years	Face, neck, arm and hand.	Grow like bovine tubercle bacilli. Class 2.	These cultures vary among themselves in their virulence, H. 85 being the least virulent, but resemble each other sufficiently closely to be included together in one group. Although they grow like bovine tubercle bacilli they have definitely lower virulence for all the species of animals tested. They have produced in calves generalised tuberculosis varying in severity, in some cases progressive and ending fatally, in others retrogressive and not fatal within the period of observation. They have produced in rabbits fatal generalised tuberculosis, the duration of life being longer than after equivalent doses of bovine tubercle bacilli, especially when the culture was inoculated subcutaneously. They have produced fatal general tuberculosis in guinea-pigs, in all but one virus (H. 53. D.H. (*a*)) definitely less severe than that produced by a bovine tubercle bacillus. They have produced generalised progressive tuberculosis in monkeys, varying in severity, but in all cases less severe than that produced by bovine tubercle bacilli.
†H. 105. "G.S."	15 years, female.	1 year	Palate, nose, upper lip and cheek.	Class 1.	
‡H. 53. "D.H." (*b*)	18½ years, female.	From early childhood.	Right hip	Class 3.	
‡H. 107. "H.H."	17 years, male.	8 years	Face, neck and arms.	Class 2.	
*H. 108. "H.R."	8½ years, male.	5 years	Face, arm and buttock.	Class 2.	
†H. 53. "D.H." (*a*)	15 years, female.	From early childhood.	Right hip.	Class 3.	
‡H. 85. "H.B."	5 years, male.	About 3 months	Nose	Class 2.	
H. 111. "S.E."	17 years, male.	10 years	Neck	Grows like a bovine tubercle bacillus (Class 3).	The culture has low virulence for the calf; it has produced fatal tuberculosis in rabbits when inoculated intravenously, chronic tuberculosis not fatal within the period of observation when inoculated subcutaneously. Its virulence for the monkey and guinea-pig is lower than that of the bovine tubercle bacillus.
H. 91. "H.S."	9½ years, male.	3½ years	Chin	Grows like a bovine tubercle bacillus on glycerin media (Class 3). Grows well on serum with the formation of a yellow pigment.	The culture has low virulence for the calf and rabbit, its virulence for the rabbit being even lower than that of a human tubercle bacillus; it has lower virulence for the guinea-pig and much lower virulence for the monkey than the bovine or the human tubercle bacillus.

* These viruses became fully virulent during a single residence in the body of the calf. † These viruses were not increased in virulence for the calf but were slightly increased for the rabbit by passage through the calf. ‡ The virulence of these viruses was not increased by passage.

CLASSIFICATION OF THE LUPUS VIRUSES ACCORDING TO CULTURAL CHARACTERS AND VIRULENCE—*continued.*

Designation of Virus.	Age and Sex of Patient.	Duration of Disease.	Situation of Lupus.	Results of the Investigation of the Cultures.	
				Cultural Characters.	Pathogenicity.
H. 99. "L.K."	8 years, female.	Not known	Upper lip, nose and neck.	Grow luxuriantly on artificial media (Class 4).	These cultures possess the virulence of the human tubercle bacillus for the calf, rabbit, monkey and guinea-pig.
H. 92. "D.N."	3¾ years, female.	1 year 8 months	Cheek		
H. 109. "M.W."	5 years, female.	3 years	Elbows	Grow luxuriantly on artificial media (Class 4).	The virulence of these cultures for the calf and rabbit is low (the results produced in the rabbit by the majority of them were less severe than is generally produced by a human tubercle bacillus); they are grouped together because they have shown a lower virulence for the monkey (results with H. 71 "L.V." inconclusive) and guinea-pig than the preceding group and appear to have higher virulence for these animals than the following group.
H. 112. "B.B."	16 years, female.	7–8 years	Arm		
†H. 71. "L.V." (*a*)	14 years, female.	9 years	Face, neck, back, arm and hand.		
(*b*)	16 years	11 years			
H. 101. "E.G."	53 years, female.	36 years	Cheeks, nose, arm and wrist.		
†H. 114. "A.U."	16 years, female.	15 years	Nose and neck		
H. 103. "N.S."	28 years, female.	24 years	Leg (following tuberculous ulceration of foot).	Grow luxuriantly on artificial media (Class 4).	These cultures have exhibited very low virulence for the calf, producing when inoculated subcutaneously a local lesion only or a local lesion and slight tuberculosis of the nearest glands; their virulence for the rabbit is exceptionally low, slight and retrogressive disease only being produced even after intravenous inoculation. Their virulence for the guinea-pig and monkey is definitely lower than that of the human tubercle bacillus.
H. 106. "K.R."	27 years, female.	About 20 years	Face, ear, neck and arm.		
*H. 84. "M.S."	68 years, female.	15 years	Cheek		
†H. 102. "N.H."	33 years, female.	15 years	Face and arm		

* This virus was not increased in virulence by passage through the guinea-pig, but was apparently increased in virulence by passage through the monkey. † These viruses were not increased in virulence by passage.

TABULAR SUMMARY OF THE RESULTS OF THE PASSAGE EXPERIMENTS.

Designation of Virus.	Classification according to Cultural Characters.	Species of Animal Used.	Number of Animals in the Passage.	Total Duration of Residence.	Effect of Passage on Virulence.
H. 100. "R.S."...	Division I.	Calf	Series α: 1 calf	122 days	Virulence increased to that of a bovine tubercle bacillus.
			Series β: 1 calf	119 days	
			Series γ: 1 calf	73 days	
		Rabbit	1 rabbit	337 days	
H. 108. "H.R."...	Division I.	Calf	Series α: 1 calf	125 days	Virulence increased to that of a bovine tubercle bacillus.
			Series β: 2 calves	224 days	
			1 calf, 1 rabbit	331 days	
			Series γ: 1 calf	101 days	Virulence not increased.
H. 105. "G.S."...	Division I.	Calf	Series α: 4 calves	384 days	Virulence of third passage cultures not increased for the calf. Virulence of fourth passage cultures slightly increased for the rabbit (the calf not tested).
			Series β: 4 calves	335 days	
H. 107. "H.H."...	Division I.	Calf	Series α: 3 calves	243 days	Virulence not increased.
			Series β: 2 calves	201 days	
H. 85. "H.B." ...	Division I.	Calf	5 calves	496 days	Virulence not increased.
		Monkey	1 monkey	271 days	
H. 53. "D.H." (*a*)	Division I.	Calf	Series α: 4 calves	429 days	Virulence not increased for calf, slightly increased for rabbit in one series (β).
			Series β: 4 calves	506 days	
		Goat	2 goats	127 days	Virulence not increased.
		Monkey	Series α: 1 monkey	209 days	Virulence (for the monkey) slightly increased.
			Series β: 1 monkey	294 days	
		Rabbit	1 rabbit	133 days	Virulence not increased.
		Pig	1 pig	225 days	
H. 53. "D.H." (*b*)	Division I.	Calf	Series α: 3 calves	176 days	Virulence not increased.
			Series β: 2 calves	91 days	
H. 71. "L.V." (*a*)	Division II.	Calf	1 calf	95 days	Virulence not increased.
H. 102. "N.H."...	Division II.	Monkey	1 monkey	156 days	Virulence not increased.
H. 114. "A.U."...	Division II.	Monkey	1 monkey	100 days	Virulence not increased.
H. 84. "M.S." ...	Division II.	Monkey	1 monkey	139 days	Virulence increased to that of a human tubercle bacillus.
		Guinea-pig	1 guinea-pig	855 days	Virulence not increased.

The cultural characters of the passage cultures were in each case identical with those of the original cultures.

TABLE OF ORIGINS OF THE LUPUS VIRUSES.

Designation of Virus.	Date of receipt of Virus.	Age and Sex of Patient.	Abstract of Case.	Derivation of Cultures.	Species of Animals Tested.	Cultural Characters and Virulence (for the Calf, Rabbit, Monkey, and Guinea-pig).
H.53. "D.H." (*a*)	Jan. 17, 1905.	15 years, female.	The patient was a girl aged 15 years, suffering from lupus of the right hip. The disease was confined to this situation and had been present for a long time, as long as the patient could remember. There were no symptoms of any constitutional disease. The mother had died of phthisis; the patient had two younger sisters and an elder brother living: the latter was healthy, the former were not robust, but showed no definite symptoms of tuberculosis. On January 17, 1905, an operation was performed, portions of the diseased tissues being scraped away. The scrapings were sent to Blythwood and emulsified; one beaded tubercle bacillus was seen on microscopical examination of the emulsion. The patient was seen one year later. She was then in excellent general health; she was undergoing treatment by Finsen light, and the local condition had much improved.	From the scrapings through the guinea-pig.	Calf. Monkey. Baboon. Rabbit. Guinea-pig. Goat. Pig. Rat. Fowl.	The culture grows like a bovine tubercle bacillus (Class 3); its virulence for the calf and rabbit is lower than that of the bovine tubercle bacillus, but definitely higher than that of the human tubercle bacillus; it is fully virulent for the guinea-pig, and its virulence for the monkey is distinctly lower than that of either the bovine or the human tubercle bacillus.
" " (*b*)	Aug. 17 1908.	18½ years	In July, 1908, the patient was again examined. She was now aged 18½ years, was in good health and well-developed, and had no cough and no physical signs of tuberculosis. The lupus was spreading (the improvement noted in 1906 not having been maintained) and now extended from the upper part of the right thigh almost to the ribs and from the axillary line almost to the median line; there was no sign of it elsewhere. On August 17, 1908, three years and eight months after the previous operation, another operation was performed; various parts of the area affected with lupus were scraped, and a piece of diseased skin (containing new growth) was removed. The scrapings and the piece of skin were sent to Blythwood and there separately emulsified; no tubercle bacilli were seen in either emulsion.	From the scrapings and from the skin, in each case through the guinea-pig.	Calf. Rabbit. Monkey. Guinea-pig.	The culture grows like a bovine tubercle bacillus (Class 3); it produced fatal tuberculosis in two calves inoculated subcutaneously and slight retrogressive tuberculosis in a third; its virulence for the rabbit, monkey and guinea-pig is lower than that of a bovine tubercle bacillus.
H.71. "L.V." (*a*)	July 4, 1906.	14 years, female.	Lupus commenced at the age of five on the neck; subsequently it appeared on the back of the right hand, on the left side of the face, on the right arm, and on the back. The patient had been frequently operated upon. The general health of the patient was good. There was a history of tuberculosis in the family, the father having died of phthisis. On July 4, 1906, small patches of lupus on the posterior internal aspect of the right arm were scraped, and the scrapings sent to Blythwood. Two doubtful tubercle bacilli were found after prolonged microscopical examination of an emulsion made from the scrapings.	From the scrapings through the guinea-pig.	Calf. Rabbit. Guinea-pig. Cat. Rat.	The culture grows luxuriantly (Class 4) and has low virulence for the calf and rabbit; its virulence for the guinea-pig falls slightly below that of the human tubercle bacillus.
" " (*b*)	April 2, 1908.	16 years	On April 2, 1908, nearly two years later, a piece of skin containing small recent lupus nodules was excised from the right arm, and recent nodules around the excised area were scraped. The skin and the scrapings were sent to Blythwood and separately emulsified; no tubercle bacilli were seen in either emulsion on microscopical examination. The girl was in good health and strong; there were no physical signs of tuberculosis in the lungs or elsewhere.	From the skin through the guinea-pig.	Rabbit. Monkey. Guinea-pig.	The cultural characters and virulence for the rabbit and guinea-pig are identical with the preceding strain, for the monkey the virulence is less than that of the human tubercle bacillus.

TABLE OF ORIGINS OF THE LUPUS VIRUSES—*continued.*

Designation of Virus.	Date of receipt of Virus.	Age and Sex of Patient.	Abstract of Case.	Derivation of Cultures.	Species of Animals Tested.	Cultural Characters and Virulence (for the Calf, Rabbit, Monkey, and Guinea-pig).
H. 84. "M.S."	Feb. 25, 1907.	68 years, female.	The disease was of 15 years standing, but had only recently recurred after having been quiescent for years. It now covered the whole of the right cheek; there were no scabs, only superficial nodules. The affected area had previously been scraped two or three times. On February 25 it was curetted and cauterised; the scrapings were sent to Blythwood and made into an emulsion in which no tubercle bacilli could be found. The wounds healed quickly, but two months after the operation a few fresh "apple-jelly" nodules were visible at the edge of the skin affected.	From the scrapings through the guinea-pig.	Calf. Rabbit. Monkey. Guinea-pig.	The culture grows luxuriantly (Class 4); it has low virulence for the calf and rabbit, and its virulence for the guinea-pig is lower and for the monkey much lower than that of the human tubercle bacillus.
H. 85. "H.B."	April 17, 1907.	5 years, male.	The patient, a boy aged five years, developed lupus of the nose in the winter of 1906–1907. The father had died of phthisis and (?) Bright's disease in January 1905; there was no other history of tuberculosis in the family. The child was breast-fed until he was 21 months old. On April 17, 1907, the lupus was scraped; the scrapings were sent to Blythwood and emulsified; no tubercle bacilli were found in the emulsion. The boy was examined in July 1908. The nose was then much better, but the lupus was spreading in a nodular form over the upper lip, the left side of the face, and on to the chin; there were no physical signs of tuberculosis, and the boy was in good general health.	From the scrapings through the guinea-pig.	Calf. Rabbit. Monkey. Chimpanzee. Guinea-pig. Goat. Pig. Horse. Fowl.	The culture grows like a bovine tubercle bacillus (Class 2); its virulence for the calf and rabbit is lower than that of H. 53 D.H. (a) and only slightly higher than that of the human tubercle bacillus; its virulence for the monkey and guinea-pig is lower than that of either the bovine or the human tubercle bacillus.
H. 91. "H.S."	Sept. 10, 1907.	9½ years, male.	The patient, a child aged 9½ years, was brought up partly on cows' milk. There was no history of tuberculosis in the family. When nearly six years old he got enlarged glands under his chin. These were removed, but a sore came in the scar, and other glands in the same region became enlarged; the sore did not heal, but became larger, and a lupus nodule developed in it. On September 10, 1907, the lesion with some surrounding skin was excised and sent to Blythwood. No tubercle bacilli or other micro-organisms were seen in an emulsion made from it. Two months after the operation the glands had become small and hard, and there had been no recurrence of the lupus. A year after the operation the child was again examined; the scar was healed and the adjacent glands were smaller: the boy's general health was good, and there were no physical signs of tuberculosis.	From the nodule through the guinea-pig.	Calf. Rabbit. Monkey. Guinea-pig. Fowl.	The culture grows on glycerin media like a bovine tubercle bacillus (Class 3); on serum it forms pigmented layers. The culture has low virulence for the calf and rabbit, and its virulence for the guinea-pig is lower and for the monkey much lower than that of the human tubercle bacillus.
H. 92. "D.N."	Sept. 10, 1907.	3¾ years, female.	The patient was a girl aged 3 years 9 months. A sore came on her cheek when she was 25 months old and remained without healing, spreading slightly, until it was removed by operation on September 10, 1907. The material removed—a lupus nodule with attached skin—was sent to Blythwood; no tubercle bacilli were found in an emulsion made from it. The child had been breast-fed alone for 12 months, then had other foods added. Two uncles had died of 'consumption,' but the child had not been living in connection with either of these relations, and there was no other history of tuberculosis in the family. The child was examined in August, 1908, nearly a year after the operation. The scar was quite healed, the child was in good health and showed no physical signs of tuberculosis.	From the nodule through the guinea-pig.	Calf. Rabbit. Monkey. Guinea-pig. Pig. Horse. Mouse. Fowl.	The culture grows luxuriantly (Class 4); it has low virulence for the calf and rabbit and is fully virulent for the monkey and guinea-pig.

H. 99. "L.K."	Feb. 7, 1908.	8 years, female.	A case of lupus in a girl aged 8 years. There was a patch of lupus on the upper lip and on the neck there was a patch of ulcerating lupus 9 cm. in diameter; there was also a recent nodule on the nose. The duration of the disease was not known. The general health of the girl had always been good, and there was no history of tuberculosis in the family. On February 6, 1908, an operation was performed, the recent nodule being excised from the nose. This was sent to Blythwood, and one tubercle bacillus was seen in an emulsion made from it.	From the nodule through the guinea-pig.	Calf. Rabbit. Monkey. Guinea-pig.	The culture grows luxuriantly, it has low virulence for the calf and high virulence for the monkey and guinea-pig. It produced in rabbits rather more severe disease than is usually produced by the human (Group II.) tubercle bacillus.
H. 100. "R.S."	Feb. 7, 1908.	37 years, female.	The lupus started 17 years previously as a small spot on the upper lip under the nose, which was scraped; about one year later it appeared on the right side of the nose, and then spread to the face; there was now (February 1908) extensive lupus of the face, front of neck, and right arm, and the patient had lost a finger. The lupus had been scraped 39 times, the last occasion having been two years ago. The general health of the patient had always been good and there were no physical signs of tuberculosis; her father died ten years ago of phthisis. On February 6 an operation was performed, a large piece of skin being excised from the right arm. This was sent to Blythwood; no tubercle bacilli were seen in an emulsion made from it.	From the skin through the guinea-pig.	Calf. Rabbit. Monkey. Guinea-pig. Pig. Fowl.	The culture grows like a bovine tubercle bacillus (Class 2). Its virulence for the calf and rabbit is slightly lower than that of the bovine tubercle bacillus and for the monkey and guinea-pig lower than that of either the bovine or the human tubercle bacillus.
H. 101. "E.G."	Feb. 7, 1908.	53 years, female.	The disease commenced at the age of 17 with a spot on the right cheek; it remained quiescent for eight years, then spread gradually over both cheeks and the nose, becoming worse after confinements. Four years ago a spot came on the back of the left wrist, and patches of lupus subsequently developed on the left arm. The general health of the patient had been good and there were no physical signs of tuberculosis; there was no history of tuberculosis in the family. On February 6 an operation was performed, a small piece of diseased skin being excised from the left elbow. This was sent to Blythwood; no tubercle bacilli were seen in an emulsion made from it.	From the skin through the guinea-pig.	Calf. Rabbit. Monkey. Guinea-pig.	The culture grows luxuriantly (Class 4) and has low virulence for the calf and rabbit; its virulence for the monkey and guinea-pig is lower than that of the human tubercle bacillus.
H. 102. "N.H."	Feb. 7, 1908.	33 years, female.	The lupus was of 15 years' duration in a woman aged 33 years; it had spread all over the face, and part of the nose was gone; there were two patches on the left arm. The patient had been scraped many times and had had X Ray treatment. Her mother had "consumptive bowels;" there was no other family history of tuberculosis. On February 6 an operation was performed, a large piece of diseased skin being excised from the left arm. This was sent to Blythwood; no tubercle bacilli were seen in an emulsion made from it. The patient was seen in July 1908. She was in perfect health except for the lupus, and there were no physical signs of tuberculosis.	From the skin through the guinea-pig.	Calf. Rabbit. Monkey. Guinea-pig. Pig.	The culture grows luxuriantly (Class 4) and has low virulence for the calf and rabbit; its virulence for the monkey and guinea-pig is much lower than that of the human tubercle bacillus. (This culture is the least virulent of all the lupus cultures.)

TABLE OF ORIGINS OF THE LUPUS VIRUSES—*continued.*

Designation of Virus.	Date of receipt of Virus.	Age and Sex of Patient.	Abstract of Case.	Derivation of Cultures.	Species of Animals Tested.	Cultural Characters and Virulence (for the Calf, Rabbit, Monkey, and Guinea-pig).
H. 103. "N.S."	Feb. 7, 1908.	28 years, female.	A case of tuberculous ulceration of the right foot with lymphatic obstruction of 24 years duration in a woman aged 28 years. There were many scattered lupoid nodules about the right leg below the knee. The patient had never been strong and had suffered from tuberculous osteitis; the forefinger of the left hand had been amputated; as a child she attended hospital for abscesses in the right thigh and the right side of the rectum. The patient's father died of consumption, two of her mother's uncles and one paternal uncle also died of consumption, and one sister is stated to have died of "consumption" when 15 months old. One step-brother was now attending Brompton Hospital and another was stated to have died of consumption. On February 6 an operation was performed, a large piece of skin containing the nodules being excised from the outer side of the leg just below the knee. This was sent to Blythwood; part of it was made into an emulsion, in which no tubercle bacilli could be found; a portion was tough and leathery and could not be emulsified. The patient was seen in September 1908. She was a thin delicate-looking woman. The wound left by the operation was quite healed; other wounds over the ankle were still open. There was dulness over the right apex of the lung with increased vocal resonance, and the patient had occasional cough and night sweats.	From the skin through the guinea-pig.	Calf. Rabbit. Monkey. Guinea-pig.	The culture grows luxuriantly and has low virulence for the calf and rabbit; its virulence for the monkey and guinea-pig is lower than that of the human tubercle bacillus.
H. 105. "G.S."	Feb. 14, 1908.	15 years, female.	The disease was of 12 months duration in a girl aged 15 years. The palate, nose, upper lip and right cheek were affected. There had been no treatment until February 14, 1908, when an operation was performed, nodules being excised from the tip of the nose and the right cheek. The material removed was sent to Blythwood; no tubercle bacilli were found in an emulsion made from it. The girl had always been well, and she showed no physical signs of tuberculosis; her maternal uncle and an aunt had died of consumption, but her immediate relations were healthy.	From the nodules through the guinea-pig.	Calf. Rabbit. Monkey. Guinea-pig.	The culture grows like a bovine tubercle bacillus (Class 1). Its virulence for the calf and rabbit is lower than that of the bovine tubercle bacillus, but definitely higher than that of the human tubercle bacillus. For monkeys the culture is slightly less virulent, and for guinea-pigs much less virulent, than either the human or the bovine tubercle bacillus.
H. 106. "K.R."	Feb. 14, 1908.	27 years, female.	The disease started about 20 years previously, a spot appearing first on the nose, then another under the lower lip. The lupus now extended all over the face, neck, and right ear, and on the right arm there were lupus nodules from the shoulder to the elbow, chiefly on the extensor surface. The patient had previously been scraped fourteen times. On February 14 a piece of skin containing lupus nodules was excised from the elbow. It was sent to Blythwood; no tubercle bacilli were seen in an emulsion made from it. The patient was in very good general health and there was no physical signs of tuberculosis in the lungs. Her mother died young of phthisis; there was no other history of tuberculosis in the family.	From the skin, direct, and through the guinea-pig.	Calf. Rabbit. Monkey. Guinea-pig. Rat. Fowl.	The culture grows luxuriantly and has low virulence for the calf and rabbit; its virulence for the monkey and guinea-pig is lower than that of the human tubercle bacillus.

H. 107. "H.H."	Feb. 14, 1908.	17 years, male.	The disease was of 8 years standing in a boy aged 17 years. It commenced as a small spot on the left cheek in front of the ear, then spread to the neck and the face, then on to the arms and elbows; the face is now (1908) very severely affected. The general health of the patient had always been good and he showed no physical signs of tuberculosis; there was no history of tuberculosis in the family. On February 14 an operation was performed, a piece of skin showing a large ulcerated nodule being removed from the right elbow. The material removed was sent to Blythwood; no tubercle bacilli were seen in an emulsion made from it.	From the skin through the guinea pig.	Calf. Rabbit. Monkey. Guinea-pig. Cat. Fowl.	The culture grows like a bovine tubercle bacillus (Class 2). Its virulence for the calf and rabbit is lower than that of the bovine tubercle bacillus, but definitely higher than that of the human tubercle bacillus; its virulence for the monkey and guinea-pig is lower than that of either the bovine or the human tubercle bacillus.
H. 108. "H.R."	Feb. 14, 1908.	8½ years, male.	Lupus of 5 years' duration in a boy aged 8½ years. It began on the right cheek and gradually spread; it was now all over the face and right arm and right buttock. The general health of the child had always been good and he showed no physical signs of tuberculosis; there was a history of tuberculosis in the family; the maternal grandfather died of consumption, and the father was believed to have died from the same cause. On February 14 a piece of skin containing lupus nodules was excised from the right arm, and the material removed was sent to Blythwood. One acid-fast bacillus (? a tubercle bacillus) was seen in an emulsion made from it.	From the skin through the guinea-pig.	Calf. Rabbit. Monkey. Guinea-pig. Fowl.	This culture resembles H. 107 H.H. in cultural characters and virulence.
H. 109. "M.W."	Mar. 17, 1908.	5 years, female.	The disease was of 3 years' duration in a girl aged 5 years. It commenced on the left elbow, and had recently spread to the right elbow. An operation was performed on March 17, the lupus on the right elbow (a fresh growth never previously treated) being excised. The tissue removed—a piece of skin containing lupus nodules—was sent to Blythwood; no tubercle bacilli were seen in an emulsion made from it. The child was breast-fed for two years and had never been strong; she did not look well, and had a cough; the cervical glands were enlarged; there were no physical signs of tuberculosis in the chest. There was a history of tuberculosis in the family, the father's sister and the mother's brother having died of "consumption."	From the skin through the guinea-pig.	Calf. Rabbit. Monkey. Guinea-pig. Goat. Fowl.	The culture grows luxuriantly and has low virulence for the calf and rabbit, and high virulence for the monkey; for the guinea-pig the virulence is lower than that of the human tubercle bacillus.
H. 110. "J.B." (*a*)	Mar. 17, 1908.	10 years, male.	The disease was of 4 years' duration in a boy aged 10 years. There were two patches of lupus on the face and many isolated patches on the trunk. The child had never been strong, but had had no serious illness; he showed no traces of tuberculous disease other than the lupus; there was no history of tuberculosis in the family. On March 17, 1908, an operation was performed, a fresh growth of lupus, which had never before been treated, being removed from the right flank; it had appeared one month before the operation. The tissue excised—a piece of skin containing lupus nodules—was sent to Blythwood; no tubercle bacilli were seen in an emulsion made from it.	From the skin through the guinea-pig.	Calf. Rabbit. Monkey. Guinea-pig. Goat. Pig.	The culture grows like a bovine tubercle bacillus (Class 1), and has the same high virulence for the calf, rabbit, monkey, and guinea-pig.
" " (*b*)	Sept. 25, 1908.	10½ years	On September 25, six months after the previous operation, a piece of skin containing lupus nodules was excised from the right thigh. The material excised was sent to Blythwood; no tubercle bacilli was seen in an emulsion made from it. The boy was now well-grown and healthy-looking, and was quite well except for the lupus.	From the skin through the guinea-pig.	Calf. Rabbit. Guinea-pig.	The culture is identical in cultural characters and virulence with the culture isolated from this case six months previously.

TABLE OF ORIGINS OF THE LUPUS VIRUSES—*continued.*

Designation of Virus.	Date of receipt of Virus.	Age and Sex of Patient.	Abstract of Case.	Derivation of Cultures.	Species of Animals Tested.	Cultural characters and Virulence (for the Calf, Rabbit, Monkey and Guinea-pig).
H. 111. "S.E."	Mar. 17, 1908.	17 years, male.	The disease commenced 10 years previously on the upper part of the neck on the right side. There were now two patches, one on the upper, the other on the lower part of the neck; the latter appeared 9 months ago. The boy had never had any serious illness, he was now a well-grown lad in good health and showed no physical signs of tuberculosis. There was a definite history of tuberculosis on the mother's side. On March 17, 1908, a portion of fresh growth from the patch on the upper part of the neck was removed by operation. The tissue excised—a piece of skin containing lupus nodules, one ulcerated—was sent to Blythwood. One (?) tubercle bacillus was seen in an emulsion made from it.	From the skin through the guinea-pig.	Calf. Rabbit. Monkey. Guinea-pig.	The culture grows like a bovine tubercle bacillus (Class 3); it has low virulence for the calf, and for the rabbit its virulence is intermediate between that of the bovine and that of the human tubercle bacillus. The virulence for the monkey is much lower, and for the guinea-pig slightly lower than that of either the bovine or the human tubercle bacillus.
H. 112. "B.B."	April 30, 1908.	16 years, female.	The disease was of between 7 and 8 years' duration in a girl aged 16 years. There was a large patch of typical non-ulcerative slightly verrucous lupus on the posterior aspect of the right upper arm; there was no lupus anywhere else. On April 30 a piece of skin containing lupus nodules was excised from the right upper arm; this was sent to Blythwood; in an emulsion made from it one tubercle bacillus was seen. The patient had been a weakly child, but had had no serious illness; she was now a well-grown girl and looked well; there were no physical signs of tuberculosis. There was family history of tuberculosis, the patient's mother having died of phthisis.	From the skin through the guinea-pig.	Calf. Rabbit. Monkey. Guinea-pig.	The culture grows luxuriantly (Class 4), and has low virulence for the calf and rabbit; its virulence for the monkey and guinea-pig is slightly lower than that of the human tubercle bacillus.
H. 113. "O.S."	April 30, 1908.	7 years, female.	The disease was of two years' duration in a child of seven. There was a patch on the right cheek showing some ulceration, a small patch below the left angle of the mouth, two patches on the right arm and two on the right buttock. The general health of the child had always been good; her maternal grandfather died of consumption; there was no other history of tuberculosis in the family. On April 30, 1908, a piece of diseased skin was removed from the right upper arm; the material excised was sent to Blythwood and an emulsion was made from it; no tubercle bacilli were seen in a smear preparation of the emulsion.	Guinea-pigs inoculated with the emulsion made from the diseased skin did not develop tuberculosis, and culture tubes sown with the emulsion remained sterile.		
H. 114. "A.U."	April 30, 1908.	16 years, female.	The lupus was of about 15 years standing in a girl aged 16 years and was confined to the face and neck. There was a patch on the front of the nose, another rather warty in type on the left side of the neck, and a small patch on the nose at the lower border of the septum. The general health of the patient had been good. There was no family history of tuberculosis. On April 30, 1908, a piece of skin containing lupus nodules was removed by operation from the right side of the neck. The material excised was sent to Blythwood; in an emulsion made from it no tubercle bacilli were seen.	From the skin, direct, and through the guinea-pig. (The direct culture only was tested as to its virulence).	Calf. Rabbit. Monkey. Guinea-pig.	The culture grows luxuriantly (Class 4), and has low virulence for the calf and rabbit; its virulence for the monkey and guinea-pig is lower than that of the human tubercle bacillus.

DETAILED HISTORY OF EACH CASE AND SUMMARIES OF EXPERIMENTAL RESULTS.

VIRUS H 53. "D.H." (*a*).

LUPUS.

First Operation, January 17, 1905.

Original material—Diseased skin removed by operation.

HISTORY OF PATIENT.

The patient, a girl aged 15 years, was admitted to the infirmary on November 14, 1904, suffering from lupus.

Family History.—The mother died of phthisis, the father of a broken blood-vessel (haemoptysis ?) ; two sisters, aged 13 and 10 years, were stated to be not robust and to suffer from enlarged tonsils and adenoid disease, but to show no definite symptoms of tuberculosis. There was one brother, aged 17, who was healthy.

Clinical History.—The patient had had lupus all her life as far as she could remember, but always in one place, namely, the right hip. She had been treated for a long time at a hospital previous to her admission to the infirmary. There were no signs of any constitutional disease.

Operation.—An operation was performed on January 17, 1905, portions of the diseased tissue being scraped away. This material was sent to Blythwood and there made into an emulsion which was used for injecting two guinea-pigs. Microscopical examination of the emulsion showed a single beaded tubercle bacillus.

Subsequent History.—The patient was seen one year later and was then in excellent general health. She was undergoing treatment by Finsen light, and the local condition had much improved.

CULTURES.

A culture was obtained from one of the guinea-pigs inoculated with the original material.

The culture was found by Dr. Cobbett to grow well on the differential media, but not so well as a typical human tubercle bacillus.

It was placed by Dr. Eastwood in his Grade III on a level with the easy-growing bovine viruses B IX, X, and XI.

SUMMARY OF INOCULATION EXPERIMENTS: THE FULL DETAILS OF WHICH ARE GIVEN IN THE APPENDIX TO THE SECOND INTERIM REPORT, VOL. II., PAGES 882–896.

(*a*) With original material.

Guinea-pigs.—Two guinea-pigs, Nos. 1482 and 1483, were inoculated intraperitoneally with an emulsion of all the material available. They were killed after 46 and 69 days respectively and showed slight tuberculosis.

(*b*) With culture.

Calves.—Three calves, Nos. 905, 977, and 1001 were inoculated subcutaneously each with 50·0 mg. of culture derived from the original material through guinea-pig 1482.

Calf 905, killed when well after 91 days, showed a scar at the seat of inoculation, and the adjacent prescapular gland was enlarged caseo-necrotic and partly calcareous. The lungs were extensively mottled with angular translucent patches sometimes confluent, finely speckled with opaque points, and showed also an occasional calcareous focus. There were numerous tuberculous foci in the small intestine. Most of the lymphatic glands contained caseous or calcareous tubercles or foci.

Calf 977 was killed after 90 days. The local tumour was fibro-calcareous and partly softened, the adjacent prescapular gland was fibro-calcareous. There was a small number of small tubercles in the lungs and spleen, calcareous tubercles in the thoracic and portal glands (numerous), and in many other lymphatic glands (scanty). There was a tubercle in one suprarenal, and two in the small intestine.

Calf 1001 was killed after 91 days. There was a small local lesion, and the adjacent prescapular gland was calcareous ; a very few minute tubercles were seen in the lungs and spleen ; in several of the lymphatic glands there was an occasional calcareous focus.

Rabbits.—Two series of rabbits were inoculated intraperitoneally with various doses, from 10·0 to 0·1 mg., of culture derived from the original material. One died in 18 days of early tuberculosis complicated by cysticercosis ; another (dose 1·0 mg.) died in 46 days, and showed tuberculous peritonitis and slight tuberculosis of lungs and kidneys, not sufficient to account for death ; the remaining five died of uncomplicated general tuberculosis in from 14 to 74 days.

Guinea-pigs.—Four guinea-pigs were inoculated intraperitoneally with culture derived from the original material, two with 1·0 mg., and two with 0·1 mg. All died of general tuberculosis in from 13 to 34 days.

Rat.—One rat was inoculated intraperitoneally with 100·0 mg. of culture derived from the original material ; it died 258 days later. Tubercle bacilli were numerous in the organs ; small tubercles were visible in the omentum and there was a group of tuberculous foci in one kidney.

PASSAGE EXPERIMENTS.

Inoculations with culture derived from the prescapular gland of Calf 905.

Calves.—Four calves were subcutaneously inoculated, two, Nos. 979 and 993, with 50·0 mg. and two, Nos. 973 and 975, with 10·0 mg.

No. 979 was killed after 103 days and showed tuberculosis limited to the site of inoculation and adjacent gland.

No. 993 was killed when in good health after 88 days. It showed a large softened local tumour and a large fibro-caseous prescapular gland. The lungs contained a moderate number of small whitish tubercles ; the spleen was packed with caseating tubercles. Several tubercles were seen in the suprarenals and some in the small intestine. All the lymphatic glands contained caseous or calcareous tubercles, some being severely affected.

No. 975 was killed after 88 days and showed tuberculous lesions very similar to those of Calf 993. The tubercles in the spleen were less numerous and the lymphatic glands were on the whole less severely affected than in the latter animal, and No. 975 showed in addition a number of minute foci in the liver and one or two in the kidneys.

No. 973 was killed after 88 days. There was a small local abscess ; the adjoining glands were caseo-calcareous. There was a moderate number of small tubercles in the spleen and the thoracic and mesenteric glands were slightly affected.

Rabbits.—Three rabbits were inoculated intraperitoneally, the doses being 1·0, 0·1, and 0·01 mg. They died in 46, 63, and 131 days respectively and showed general tuberculosis ; in the last case however the amount of disease was scarcely sufficient to account for death.

REINVESTIGATION OF THE VIRUS.

Introduction.

The experiments summarised above showed that the culture obtained from a case of lupus was unlike any that had up to that time been isolated from the human body. It resembled a bovine tubercle bacillus in its manner of growth on artificial media—being classed by Dr. Eastwood in his Grade III in which were many bovine cultures—and in its virulence for rabbits, but was distinctly less virulent for calves than the bovine tubercle bacillus.

The virulence of the culture had been tested only on calves, rabbits, and guinea-pigs, and in the latter two species by one method alone, the intraperitoneal.

Since the culture exhibited such exceptional features it was considered to be important to ascertain its virulence not only for rabbits and guinea-pigs by other methods than the intraperitoneal but also for other species of animals.

These experiments are summarised below.

The most interesting fact observed in connection with them is the low virulence of the culture for monkeys compared with that possessed by the bovine or by the common human tubercle bacillus.

The intravenous and intraperitoneal inoculation of the culture into rabbits has resulted in every case in fatal generalised tuberculosis, but the duration of life has been consistently longer than after similar inoculations with bovine tubercle bacilli. This lower virulence towards rabbits was brought out more strikingly by the subcutaneous method of inoculation; rabbits inoculated subcutaneously with a large dose of culture often survived for a considerable length of time and on post-mortem examination showed a much less severe form of tuberculosis than that produced by the bovine tubercle bacillus.

The subcutaneous inoculation of rabbits has shown therefore that there is not the marked difference in virulence towards calves from that towards rabbits which the first experiments had led one to suppose; the virulence of the culture towards rabbits as well as towards calves falls distinctly below that of the bovine tubercle bacillus.

CULTURES.

The culture derived from Guinea-pig 1482, when its reinvestigation was begun in January, 1907, had been in artificial cultivation 22 months.

In order to ascertain whether any change had taken place in the cultural characters of the organism during this period, the culture was tested by me on the differential media.

On glycerin-serum growth was better than on serum alone and was whitish slightly wrinkled and irregular in thickness. On glycerin-agar dry greyish-white patches showing a fine wrinkling were quickly formed; these slowly became more opaque and granular, but at the end of two months had attained only a moderate thickness.

On potato in two cases growth was rather scanty; in another at the end of a fortnight there was only a thin grey haze; this gradually increased in thickness and in a month was greyish-white, unequal in thickness, granular and showed some raised yellowish warty outgrowths; growth steadily continued and at the end of nine weeks there was an abundant raised yellowish highly wrinkled layer equal to the best produced by a typical human tubercle bacillus.

The surface of broth quickly became covered with a greyish translucent membrane containing thicker whitish patches; the membrane soon broke up and sank.

With the exception of that on potato the growths were not better than those obtained when the culture was first tested.

INOCULATION EXPERIMENTS.

(a) With the strain of culture derived from the original material through Guinea-pig 1482.

Calves.—Two calves, Nos. 1135 and 1155, were inoculated subcutaneously each with 50·0 mg. of the culture, after 688 days artificial cultivation.

Calf 1135 was killed after 79 days and showed a caseous and partly softened mass surrounded by a fibro-caseo-calcareous zone at the seat of inoculation, fibro-caseo-calcareous masses in the left prescapular gland, scattered gritty foci in the thoracic glands and one tubercle in each suprarenal. A guinea-pig inoculated with an emulsion of the spleen became tuberculous.

Calf 1155 was killed after 136 days. There was a fibro-caseo-calcareous tumour at the seat of inoculation, and the left prescapular and prepectoral glands were caseous and softening. In the lungs and spleen small scattered nodules with grey margins and caseo-calcareous sometimes softened centres were seen. There was a single tubercle in the left suprarenal, and two or three calcareous foci in Peyer's patches. Moderately numerous calcareous or caseous and softened tubercles and nodules were seen in nearly every lymphatic gland in the body.

Two calves, Nos. 1395 and 1391, were inoculated intravenously with 5·0 mg. and 1·0 mg. respectively of the culture after 1124 days artificial cultivation.

Calf 1395 died in 21 days. The lungs were extensively consolidated and packed with minute tubercles; the thoracic glands were enlarged, firm and greyish red. The liver was large and packed with just visible grey points; a few tubercles were visible in the kidneys. Tubercle bacilli were numerous in smears from the lung and various glands, scanty in smears from the abdominal organs.

Calf 1391 was killed when dying after 40 days. The lungs were extensively consolidated and closely beset with minute grey tubercles. There were a few small greyish tubercles in the heart and liver and one in each suprarenal, and fairly numerous small grey tubercles in the kidneys. The thoracic and portal glands showed early caseation. Tubercle bacilli were very numerous in the lung, scanty or absent in smears from liver, spleen, and precrural gland, moderately numerous in a smear from a mesenteric gland.

Pigs.—Three young pigs (aged 5 months) were inoculated subcutaneously with the culture after 723 days artificial cultivation. No. 85 received 50·0 mg., No. 87 10·0 mg., and No. 89 1·0 mg.

Pig 85 was killed when in good health after 366 days. There were scattered caseous nodules in the subcutaneous tissues at the seat of inoculation; the adjacent inguinal glands were large and caseous. The lung was expanded and evenly beset with caseous nodules with thick fibrous capsules. The spleen contained scattered dry caseo-calcareous nodules with thin grey capsules; fairly numerous encapsuled nodules were seen in the liver; there were three in each kidney. Caseous gritty nodules were seen in most of the lymphatic glands.

Pig 87 was killed when in good health after 227 days. There were several small thin walled cysts (and one large one 2 cm. in diameter), containing softened caseous material in the neighbourhood of the site of inoculation. The adjacent inguinal and ventral mediastinal glands were enlarged and composed of mortary caseous substance in a thin capsule. The lungs were fuller and firmer than normal, and showed fairly numerous small caseous softened nodules with thin fibrous capsules, and a number of grey tubercles; here and there, chiefly in the anterior halves of the lungs, irregular solid patches composed of fibroid tissue with soft caseous tubercles were also seen. The liver and spleen showed a moderate number of small encapsuled caseo-calcareous nodules; there was one in the left kidney. A small yellow tubercle was seen in the thymus. Most of the lymphatic glands contained one or more small caseous or calcareous nodules.

Pig 89 was killed when in good health 123 days after inoculation. There were many caseo-purulent nodules (several ulcerated) in the subcutaneous tissues of the abdomen, the majority being grouped round a linear cicatrix which marked the site of inoculation. The adjacent glands contained softened caseous nodules. The lungs collapsed normally, and were moderately closely beset with hard nodules, varying in diameter from 1 to 10 mm.; a few were caseous throughout, the majority fibrous with caseous or calcareous foci. The liver showed sparsely scattered small nodules with fibrous margins and caseous or caseo-calcareous centres. The spleen was similar, and contained also a large softened caseous nodule 1 cm. in diameter. Many of the lymphatic glands contained softened caseous nodules or tubercles, the thoracic, portal, and several coeliac glands being severely affected.

Two young pigs, each 12½ weeks old, Nos. 121 and 119, were inoculated subcutaneously with the culture after 1069 days artificial cultivation.

Pig 121, which received 50·0 mg., died in 146 days. There were several small dry ulcers at the seat of inoculation, and a mass of caseous tubercles and nodules in the subcutaneous tissues; the adjacent glands were much enlarged and caseous throughout. The lungs did not collapse; the lung tissue was firm and congested, and resembled pancreas, the lobules being composed of solid greyish tissue, homogeneous anteriorly, but showing yellow and then caseous centres in the posterior parts of the lung. A few lobules were extensively caseated and showed small cavities. Very little crepitant lung tissue remained. The bronchial glands were enlarged and contained caseous nodules, small and in places confluent. The abdominal organs were free from tubercles. Most of the abdominal lymphatic glands contained caseous nodules, sometimes confluent.

Pig 119, which received 10·0 mg., was killed when fat and well after 225 days. There was a fibro-caseo-calcareous mass at the seat of inoculation, and the adjacent glands were enlarged and composed of similar substance. The lungs contained moderately numerous calcareous tubercles up to a millet seed in size, and there were two in the spleen; four grey tubercles were seen in the liver. The bronchial and portal glands were beset with calcareous tubercles; the mesenteric glands contained a varying number, and some were calcareous throughout. A few other lymphatic glands were affected. Between the pericardium and the heart which were adherent, there were three or four fibro-calcareous tubercles.

Goats.—Goat 65 (kid, 5 months old) was inoculated subcutaneously with 10·0 mg. of the culture after 1069 days artificial cultivation. Two months later an adult goat, No. 67, was inoculated subcutaneously with an equivalent dose.

Goat 65 died in 38 days. There was an infiltrating caseo-necrotic local tumour; the left prescapular gland was caseated almost throughout, and other adjacent glands contained caseous tubercles and nodules. The lungs were extensively consolidated and beset with miliary caseating tubercles. The thoracic glands were enlarged and caseating. The Malpighian bodies of the spleen were well marked, and a few had yellow centres. There were a very few grey tubercles in the liver, kidneys, and suprarenals, and grey foci and occasional miliary tubercles in the mesenteric and coeliac glands.

Goat 67 died in 59 days and showed similar post-mortem appearances—severe tuberculosis of the lungs and very slight tuberculosis of the abdominal organs and glands.

Baboons.—Baboon 7 was inoculated subcutaneously with 1·0 mg., and baboon 5 fed with 1·0 mg., of the culture after 968 days artificial cultivation.

Baboon 7 died in 35 days. There was an irregular ulcer at the seat of inoculation. Two left axillary glands were enlarged caseous and softened; other glands adjacent contained caseous tubercles and foci. The lungs contained sparsely scattered shotty caseating tubercles up to 1 mm. in diameter; smaller tubercles were seen in the liver and spleen, greyish in colour and sparsely distributed. The cause of death was not apparent.

Baboon 5 died 70 days after feeding. The alimentary tract and the glands connected with it were normal. In the lungs there were eight hard nodules with fibrous margins and softened yellow centres, and in one of the bronchial glands half a dozen yellow softened foci. There was no tuberculosis elsewhere; the cause of death was not apparent. A luxuriantly growing culture was isolated from the lung, and there is little doubt that the tuberculosis in this animal had arisen spontaneously.

Rhesus Monkeys.—The following table gives a list of monkeys inoculated subcutaneously with the culture on several different occasions:—

Duration of Artificial Cultivation of Culture.	Number of Monkey.	Dose.	Duration of Life.
817 days	103	10·0 mg.	Died 23 days.
902 „	109	10·0 mg.	Killed (dying) 32 days.
723 „	93	1·0 mg.	Died 105 days.
817 „	101	1·0 mg.	Died 42 days.
902 „	111	1·0 mg.	Died 41 days.
1069 „	137	1·0 mg.	Killed (very ill) 92 days.
1069 „	135	0·1 mg.	Killed (very ill) 209 days.
1069 „	129	0·01 mg.	Died 51 days.

Monkey 103 died prematurely in 23 days, and showed local tuberculosis only.

Monkey 109 was killed when dying after 32 days, and showed general tuberculosis, severe in the spleen. There was a large local ulcer, and the adjacent glands were much enlarged caseous and softened. The lungs and kidneys contained very sparsely scattered opaque whitish tubercles, the liver fairly numerous similar tubercles; the spleen was closely beset with softened caseous tubercles. Three abdominal glands were extensively caseous and softened, a few other glands contained one or more caseous tubercles.

Monkey 93 died in 105 days. There was a collapsed cyst at the seat of inoculation, and the adjacent glands were caseous and softened. In the lung, liver, and left kidney there were one or more small tubercles; the lung contained also a pea-sized caseous nodule. Many of the lymphatic glands showed varying degrees of caseation; the ventral mediastinal glands were as large as thrushes' eggs and must have caused the difficulty of respiration noticed during life.

Monkey 101 died prematurely in 42 days, and showed very slight generalised tuberculosis.

Monkey 111 died in 41 days and showed generalised tuberculosis. There was an infiltrating caseous local tumour, and the adjacent glands were enlarged caseous and softened. The lungs contained half a dozen, the kidneys four, and the liver a few, small grey tubercles. The spleen was not enlarged, but was closely beset with soft caseous miliary tubercles. Two or three of the lymphatic glands showed an occasional tubercle.

Monkey 137 was killed when very ill after 92 days and showed general tuberculosis. There was an ulcerated caseous local tumour, and the adjacent glands were caseous and softened. The lungs contained scattered grey nodules and a patch of firm grey tissue on one caudal lobe. The spleen was enlarged and contained a moderate number of small caseous and softened nodules; there were five in the liver, one in a suprarenal body, and a dozen in the kidneys; half a dozen were seen in the subcutaneous tissues of the body, and a varying number in most of the lymphatic glands.

Monkey 135 was killed when very ill after 209 days and showed general tuberculosis, severe in the lungs. There was a caseous non-ulcerated local lesion. The axillary, vertebral, and thoracic glands were very greatly enlarged, caseous, and softened. The lungs were closely beset with grey tubercles confluent in the central parts; many caseous nodules and areas also were seen in the anterior lobes. There was one tubercle in the spleen, a few in the kidneys; four ulcers in the

intestine ; and varying degrees of caseation were seen in many abdominal glands.

Monkey 129 died prematurely in 51 days. There was a small breaking-down caseous local tumour and no tuberculosis elsewhere.

The following table gives a list of the monkeys fed with the culture on two occasions :—

Duration of Artificial Cultivation.	Number of Monkey.	Dose.	Duration of Life.
902 days	113	10·0 mg.	Died 20 days
902 „	115	1·0 mg.	Died 22 days
1069 „	131	1·0 mg.	Killed 294 days

Monkeys 113 and 115 died prematurely in 20 and 22 days respectively, and showed no tuberculosis.

Monkey 131 was killed when well after 294 days and showed general tuberculosis. The majority of the glands of the alimentary tract were slightly enlarged and showed varying degrees of caseation ; the bronchial splenic and portal glands were similar. There were several small ulcers and two over 1 cm. in diameter in the large intestine. One lobe of the lung was fibroid with caseous patches ; elsewhere there were a few shotty tubercles. The spleen contained a moderate number of irregular softened caseous nodules, the liver a number of muco-purulent cysts, a caseous nodule, and a few small tubercles, the kidneys four tubercles. In the omentum about three dozen caseous nodules were seen.

Rabbits.—The following table gives a list of rabbits inoculated with the culture ; four series in all were inoculated on different occasions.

Duration of Artificial Cultivation of Culture.	Number of Rabbit.	Dose.	Duration of Life.
	Intravenous.		
594 days	955	1·0 mg.	Died 22 days
688 „	1093	0·1 mg.	Died 33 days
1069 „	1715	1·0 mg.	Died 23 days
1069 „	1714	0·01 mg.	Died 66 days
1124 „	1804	0·1 mg.	Died 40 days
1124 „	1805	0·01 mg.	Died 131 days
1124 „	1806	0·001 mg.	Died 106 days
	Intraperitoneal.		
594 days	953	1·0 mg.	Died 45 days
594 „	954	0·1 mg.	Died 90 days
	Subcutaneous.		
594 days	956	10·0 mg.	Killed 90 days
594 „	957	10·0 mg.	Died 346 days
594 „	958	1·0 mg.	Died 76 days
688 „	1094	10·0 mg.	Died 312 days
688 „	1095	10·0 mg.	Died 86 days
1069 „	1716	10·0 mg.	Died 7 days
1069 „	1717	10·0 mg.	Died 84 days

All the rabbits inoculated intravenously died of general tuberculosis. The two which received 1·0 mg. died in 22 and 23 days, those which received 0·1 mg. in 33 and 40 days ; two which received 0·01 mg. died in 66 and 131 days, and one which received 0·001 mg. died in 106 days.

The two rabbits which received 1·0 mg. and 0·1 mg. intraperitoneally died of general tuberculosis in 45 and 90 days respectively.

Rabbit 956 (10·0 mg. subcutaneous) was killed after 90 days and showed slight tuberculosis. There was a very large caseous and softened local tumour and the axillary glands were large and caseous. The lungs were crepitant and contained not very numerous grey tubercles, the larger definitely caseous, and two irregular grey caseating patches in one anterior lobe. The bronchial glands showed a few caseous foci. In each kidney there were a few grey tubercles. One epididymus contained a caseous nodule, the other half-a-dozen caseous tubercles. There was no tuberculosis elsewhere.

Rabbit 957 (10·0 mg. subcutaneous) died in 346 days of general tuberculosis. There was a baggy tumour at the seat of inoculation composed of two cysts, one containing turbid fluid, the other caseo-pus. The lungs were crepitant and contained small scattered caseous nodules with grey margins. There were caseous tubercles on the pleura, and grey tubercles on the omentum. The left kidney contained a few grey tubercles and a grey wedge-shaped nodule based on a scar ; the right showed similar tubercles and a very large scar surmounting groups of wedge-shaped grey nodules with caseous extremities. There were a few caseous tubercles in several abdominal glands. Both eyes were almost completely disorganized by tuberculous lesions, and the lachrymal glands were enlarged and extensively caseous.

Rabbit 958 died in 76 days : the cause of death was not determined. There was a thin-walled cyst containing caseo-pus at the seat of inoculation, and the adjacent axillary gland showed a large cavity containing fluid and caseous flakes. In the lungs and kidneys there were one or two grey tubercles.

Rabbit 1094 died in 312 days of chronic general tuberculosis. There was a fibrous-walled ulcerated local tumour containing dry caseous substance : the adjacent scapular gland was a thin-walled cyst filled with caseo-pus. The lungs contained scattered caseo-purulent gritty nodules and small fibrous tubercles, and the thin ventral margin of one lobe was dense caseous and gritty. There were a very few little tubercles in the kidneys. Under the fascia of one kneejoint there was a granulation tissue tumour containing caseous foci, and under the tendon of the quadriceps there was a caseous nodule. The wall of the appendix and the termination of the ileum contained a number of caseous gritty tubercles.

Rabbit 1095 died in 86 days of pseudo-tuberculosis. There was a very large ulcerated caseous tumour at the seat of inoculation ; continuous with it there was a similar but smaller tumour which probably included the left axillary gland. A pectoral gland contained small caseous patches, and a right axillary gland was caseous. There was no tuberculosis elsewhere. The organs showed pseudo-tuberculous lesions.

Rabbit 1716 died in seven days of cellulitis of the back.

Rabbit 1717 died in 84 days and showed chronic general tuberculosis, death being due probably to septic absorption from the local lesion. The latter was very large caseous and rather foul smelling, and the skin over it was replaced by a dry scab. The scapular glands were occupied by softened caseous nodules. The lungs were crepitant and contained not very numerous caseous tubercles ; there was a moderate number in the kidneys. The liver contained sparsely scattered greyish-white tubercles. There were a few caseous tubercles in the mesentery and meso-colon.

Guinea-pigs.—Four guinea-pigs were inoculated with the culture after 688 days artificial cultivation, two intraperitoneally (doses 1.0 and 0·1 mg.) and two subcutaneously (doses 1·0 and 0·1 mg.). The two former died of general tuberculosis in 18 and 38 days respectively, the two latter in 63 and 75 days.

Fowls.—The following table gives a list of fowls inoculated with the culture :—

Duration of Artificial Cultivation of the Culture.	Number of Fowl.	Dose.	Duration of Life.
	Intravenous.		
688 days	21	50·0 mg.	Died 12 days
,,	19	10·0 mg.	Died 14 days
,,	23	1·0 mg.	Killed 114 days
1069 days	85	10 0 mg.	Died 207 days
	Intraperitoneal.		
723 days	31	50·0 mg.	Killed 170 days
,,	29	10·0 mg.	Killed 169 days
,,	27	1·0 mg.	Died 98 days
	Subcutaneous.		
723 days	35	50·0 mg.	Killed 172 days
,,	33	10·0 mg.	Killed 172 days

Fowls 21 and 19 died in 12 and 14 days respectively of acute tuberculosis. No. 21 showed the spleen much enlarged and ruptured and the liver pale ; other organs appeared normal. Tubercle bacilli were seen in smears from the marrow and a kidney, and were numerous in smears from the lung, spleen, and liver. No. 19 showed the spleen enlarged and ruptured, the liver rather pale, with foci of congestion ; other organs appeared normal. Tubercle bacilli, in clumps and singly, were moderately numerous in smears from the lung and spleen ; tubercle bacilli were seen also in smears from the liver and kidney, but none were seen in the marrow.

Fowl 23 was killed after 114 days and showed a grey spot in the liver (smear, no tubercle bacilli), and a minute greyish-white point on the spleen ; otherwise the bird was perfectly healthy.

Fowl 85 died in 207 days ; there was no sign of tuberculosis anywhere in the body.

Fowl 31 was killed after 170 days and showed no tuberculous lesions.

Fowl 29 was killed after 169 days and showed two small tubercles with opaque centres and grey margins in the liver, in a smear from one of which numerous tubercle bacilli were seen. There was no sign of disease elsewhere.

Fowl 27 died in 98 days and showed no tuberculous lesions.

Fowl 35 was killed after 172 days. In the subcutaneous tissues at the seat of inoculation there was a thin sheet of tough yellow substance surrounded by a thin wall of fibrous tissue. There was no tuberculosis elsewhere.

Fowl 33 was killed after 172 days. In the muscle at the seat of inoculation there was a firm patch of moderate size composed of fibroid tissue containing tough caseo-necrotic tracts. There was no tuberculosis elsewhere.

Rat.—One rat, No. 57, was inoculated intraperitoneally with 50·0 mg. of the culture ; it died 122 days later. The omentum was slightly thickened and contained a caseous tubercle, and there was a caseous nodule near the right suprarenal body. The organs appeared normal ; but tubercle bacilli were numerous in smears from the spleen and liver, and very numerous in the lung.

(*b*) With the Strain of Culture derived from the Prescapular Gland of Calf 905.

Rabbits.—Six rabbits were inoculated with the culture after 361 days artificial cultivation ; two intravenously, Nos. 1055 and 1056, doses 1·0 and 0·1 mg. ; two intraperitoneally, Nos. 1057 and 1058, doses 10·0 and 1·0 mg. ; and two subcutaneously, Nos. 1059 and 1060, doses 10·0 and 1·0 mg.

The two rabbits inoculated intravenously died of general tuberculosis in 19 and 29 days ; and those inoculated intraperitoneally died in 17 and 104 days, also of general tuberculosis.

Of the two subcutaneous rabbits, 1059 died in 133 days of severe chronic general tuberculosis. There was a small ulcerated caseous local tumour, and around it were numerous caseous nodules. The axillary glands were slightly enlarged and partly caseous ; the tracheal glands were similar. The lungs were moderately closely beset with caseous nodules sometimes confluent. The spleen contained fairly numerous caseous tubercles, the liver opaque whitish specks. The kidneys contained grey and caseous tubercles and caseous streaks ; in one there was also a caseous nodule. One knee-joint was swollen and contained a mucinous substance in which were greyish-white flakes. In the subcutaneous tissues of the groin and the subperitoneal tissues near the vertebral column there were numerous small caseous nodules.

The other subcutaneous rabbit, 1060, was killed after 223 days, and showed chronic general tuberculosis. There was a thin-walled cyst containing caseo-pus and the adjacent scapular gland was enlarged and caseous. The lungs contained fairly numerous grey tubercles, some with caseous centres, and a few grey patches with caseous foci ; the margins here and there were solid ; around the margins were numerous loosely attached caseous nodules of various sizes. On the left costal pleura there were numerous patches of reddish vegetations containing caseous tubercles, also a few grey tubercles and a caseous nodule. The kidneys contained scattered grey translucent nodules.

SUMMARY.

The material investigated was from a case of lupus in a girl aged 15 years. A culture was raised from a guinea-pig inoculated with scrapings from the diseased skin.

The culture grows moderately well on artificial media, but not better than the more easy-growing bovine tubercle bacilli which it closely resembles.

It is virulent for rabbits by intravenous and intraperitoneal inoculation, and has caused fatal general tuberculosis when inoculated subcutaneously, the duration of life however being much prolonged as compared with that of rabbits inoculated with bovine tubercle bacilli. It produces typical tuberculosis in guinea-pigs. It has produced generalised tuberculosis in the calf in all cases retrogressive. It produced in a goat and a kid —each after 10·0 mg. subcutaneous—fatal general tuberculosis.

It has produced general tuberculosis in five pigs, in one case severe and causing death in 146 days ; in the remaining four animals the disease was not fatal within the period of observation, in one case 12 months.

Its most interesting property is its lower virulence for the rhesus monkey than that possessed either by the bovine tubercle bacillus or the common human tubercle bacillus ; fatal general tuberculosis, indistinguishable from that set up by the bovine and human tubercle bacillus has been produced in these animals, but the duration of life was much longer.

Virulence after passage.

The virulence of the virus was not increased for the calf by passage through two series of four calves, but showed in one case a slight increase in virulence for the rabbit. It was slightly increased in virulence for the monkey by residence in the bodies of monkeys. It was not increased in virulence by passages through the goat, pig, and rabbit.

VIRUS H. 53. "D.H." (*b*).

LUPUS.

Second Operation, August 17, 1908.

Original material—Lupus scrapings and a piece of excised skin.

HISTORY OF PATIENT

(*continued from January, 1905, the date of the previous operation.*)

The patient a girl aged 15 years at the time of the operation in 1905, was examined one year later. She was then in excellent general health ; she was undergoing treatment by Finsen light, and the local condition (the lupus was confined to the right hip) had much improved.

On July 15, 1908, the girl was again seen. She was now aged 18½ years and had grown a great deal during the previous two and half years. The disease was spreading (the improvement noted in 1906 not having been maintained) and now extended from the upper part of the right thigh almost to the ribs and from the axillary line almost to the median line ; there was no sign of it elsewhere.

The girl was in good health and well developed, and had been two years in service ; she had no cough and no physical signs of tuberculosis.

Operation.—On August 17, 1908, three years and eight months after the previous operation, another operation was performed ; various parts of the area affected with lupus were scraped, and a piece of diseased skin (containing new growth) was removed from the neighbourhood of the anterior superior spine of the ilium. The material removed was sent to Blythwood.

Experimental use made of material received at Blythwood.—Two emulsions were made, one from the scrapings, and the other from the piece of skin.

Both these emulsions were examined microscopically and no tubercle bacilli were found. Three guinea-pigs were inoculated with the first emulsion and two with the second.

CULTURES.

Cultures were obtained from three of the guinea-pigs, Nos. 3215, 3216, and 3218, inoculated with the original material ; the two former were inoculated with the scrapings the latter with the skin.

The three strains exhibited identical cultural characters. Growth on serum was thin, grey, and uniform ; on glycerin serum it was two or three times as thick as on serum, greyish-white and not uniform.

On agar greyish ground-glass layers were formed.

On potato thin greyish or greyish-white granular layers were produced, or thin grey glazed layers in which subsequently discrete whitish colonies developed.

The surface of broth was soon covered with a translucent membrane like tissue paper which quickly became moist and sank.

INOCULATION EXPERIMENTS.

(*a*) With the original material.

Guinea-pigs.—Three guinea-pigs, Nos. 3215, 3216, and 3217, were inoculated intraperitoneally with an emulsion of the scrapings, and two, Nos. 3218, 3219, intraperitoneally with an emulsion of the piece of skin.

Nos. 3215 and 3216 were killed after 25 and 36 days respectively, and showed early general tuberculosis ; No. 3217 died in 172 days of chronic general tuberculosis ; No. 3218 was killed after 85 days, and showed moderately severe general tuberculosis ; No. 3219 died of chronic general tuberculosis in 190 days.

(*b*) With culture.

Calves.—Calf 1507 was inoculated subcutaneously with 50·0 mg. of culture derived from the original material through Guinea-pig 3215. It was killed when moribund after 63 days, and showed general tuberculosis.

Calves 1535 and 1545 were inoculated subcutaneously each with 50·0 mg. of culture derived from the original material through Guinea pig 3216.

Calf 1535 was killed when well after 103 days, and showed slight generalised tuberculosis ; Calf 1545 died in 52 days of general tuberculosis.

Rhesus Monkeys.—Monkeys 265 and 267 were inoculated subcutaneously each with 1·0 mg. of culture derived from the original material through Guinea-pig 3216.

Monkey 265 died in 14 days, and showed a small local lesion only. Monkey 267 died in 33 days, and showed slight generalised tuberculosis. The cause of death was not apparent in either case.

Monkeys 289 and 291 were subsequently inoculated subcutaneously each with 1·0 mg. of the same strain of culture.

They died in 35 and 34 days respectively, apparently from cold. One showed local tuberculosis and tubercle bacilli in the organs, the other local tuberculosis and a few disseminated lesions.

Rabbits.—Four rabbits were inoculated intravenously with the culture derived from Guinea-pig 3215.

Three (doses 1·0 and 0·1 mg.) died of general miliary tuberculosis in 25 to 36 days, the fourth (dose 0·01 mg.) died of general tuberculosis in 136 days.

Five rabbits were inoculated, three intravenously and two subcutaneously, with the culture derived from Guinea-pig 3216.

Two intravenous rabbits (1·0 and 0·1 mg.) died of general miliary tuberculosis in 20 and 24 days ; the third (0·01 mg.) died of general tuberculosis in 70 days. The subcutaneous rabbits (10·0 mg. each) died prematurely in 44 and 56 days, and showed slight general tuberculosis.

Two more rabbits were subsequently inoculated subcutaneously with this culture. One (dose 5·0 mg.) died in 81 days and showed slight generalised tuberculosis, the cause of death was not apparent ; the other (dose 1·0 mg.) was killed after 201 days, and showed local tuberculosis and slight tuberculosis of the lungs.

Five rabbits were inoculated, three intravenously and two subcutaneously, with the culture derived from Guinea pig 3218.

They all died of general tuberculosis, the three intravenous animals (doses 1·0, 0·1, and 0·01 mg.) in from 25 to 80 days, the two subcutaneous rabbits (doses 10·0 mg. each) in 95 and 111 days.

Guinea-pigs.—Two guinea-pigs were inoculated, one intraperitoneally and one subcutaneously, each with 0·1 mg. of the culture derived from Guinea-pig 3216.

They died of general tuberculosis in 39 and 82 days.

Two guinea-pigs were inoculated, one intraperitoneally and one subcutaneously, each with 0·1 mg. of the culture derived from Guinea-pig 3218.

One died in 23 days and showed general tuberculosis, not severe ; the other died prematurely in 7 days, the cause of death was not apparent.

SUMMARY.

The material investigated was from a case of lupus in a girl aged 18½ years. Material from this girl had been received for investigation 3½ years before (*see* H. 53. "D.H." (*a*)).

The culture grows moderately well on artificial media, but not better than the more easy-growing bovine tubercle bacilli which it closely resembles.

It has produced fatal tuberculosis in two calves inoculated subcutaneously, and slight retrogressive tuberculosis in a third.

Its virulence for the rabbit, monkey, and guinea-pig is lower than that of a bovine tubercle bacillus.

Virulence after passage.

The virus was not increased in virulence by passage through two series of (three and two) calves.

VIRUS H. 71. "L.V." (*a*).

LUPUS.

First Investigation.

First Operation, July 4, 1906.

Original material—The material received was scrapings from lupus.

HISTORY OF PATIENT.

The patient was a girl aged fourteen years admitted to hospital for lupus.

The disease commenced at the age of five on the neck ; it was then seen on the back of the right hand, afterwards on the left side of the face and on the back ; at one time (when a child) the lupus extended right round her neck.

The child was under treatment at one hospital for seven years ; the lupus did not heal ; in January 1904 she came to another institution ; the lesions were scraped, and the patient left healed. In June 1904 she was treated again, the disease having recurred on arms and face.

Two years later (in June 1906) she was again admitted ; there were patches of lupus on right shoulder, arm, and chin. An operation was performed on July 4, 1906, a number of small patches on the posterior internal aspect of the right arm being thoroughly scraped with Volkmann's Spoon. On July 16, the wounds were healing.

The father died of phthisis : there was no other history of tuberculosis in the family. The mother was alive and suffered from heart disease and fits ; the girl's three brothers were well ; her sisters were also well.

An emulsion was made from the scrapings received on July 4, 1906, and used to inoculate two guinea-pigs and one rabbit. Four smears made from it were examined microscopically ; in one of them two doubtful tubercle bacilli were found.

CULTURES.

A culture was obtained from each of the two guinea-pigs inoculated with the original material.

Both strains have identical cultural characters.

On glycerin-serum they produced a thick opaque finely wrinkled growth, with a slight creamy tinge, much more abundant than on serum alone.

On glycerin-agar in a fortnight a thick wrinkled cream-coloured growth was produced which increased in thickness on further incubation.

Growth on potato was very luxuriant and was heaped up, warty or nodular and pigmented.

On glycerin broth and on the gelatine medium the pellicles formed were uniform moderately thick and wrinkled, and contained small warty yellow patches.

INOCULATION EXPERIMENTS.

(*a*) With the original material.

One rabbit (919) and two guinea-pigs (1937–1938) were inoculated intraperitoneally with an emulsion of the scrapings.

The rabbit was killed after 128 days, and showed no tuberculous lesions ; the guinea-pigs were killed after 50 and 76 days respectively, and were found to be tuberculous.

(*b*) With culture.

Calves.—Two calves, Nos. 1153 and 1163, were inoculated subcutaneously with culture derived from guinea-pig 1937, each receiving 50·0 milligrammes.

Calf 1153 was killed in good health 95 days after inoculation and showed a firm tumour composed mainly of thickened skin, a fibro-calcareous patch and a few calcareous tubercles in the prescapular gland, calcareous patches in the thoracic glands, and calcareous foci in many abdominal glands ; a very few glassy tubercles were seen in the lungs.

Calf 1163 also remained in good health throughout the experiment and when killed 95 days after inoculation showed a cystic tumour, fibro-calcareous nodules with softened caseous patches in the nearest glands, and a dozen glassy tubercles in the lungs.

Rabbits.—A series of rabbits was inoculated (two intravenously, two intraperitoneally, and two subcutaneously) with culture at the same time as the calves. One which received 10·0 mg. intraperitoneally died after 50 days of tuberculous peritonitis and general tuberculosis ; the remaining five were killed after 188 days and showed a varying amount of slight generalised tuberculosis.

Guinea-pigs.—Four guinea-pigs were inoculated, two subcutaneously and two intraperitoneally, doses 1·0 and 0·1 milligramme ; all died of general tuberculosis in periods varying between 32 and 86 days.

Rats.—Two rats were inoculated, one intraperitoneally and one subcutaneously with 50·0 milligrammes of culture each. The former died of acute tuberculosis in 28 days. The latter died after 70 days ; localised tuberculosis only was found and the cause of death was not apparent.

SUMMARY.

A culture, derived from a case of widespread lupus in a girl aged 14, grows luxuriantly on all media containing glycerin, has low virulence for calves and rabbits, and is slightly less virulent for the guinea-pig than the human tubercle bacillus.

Virulence after passage.

The virus was not increased in virulence by residence in the body of the calf.

VIRUS H. 71. "L.V." (*b*).

LUPUS.

Second Investigation.

Second Operation, April 2, 1908.

Original material—The material received was scrapings and lupus nodules removed by operation.

HISTORY OF PATIENT (*continued*).

On April 1, 1908, nearly two years after the last operation (on July 4, 1906), the girl, now aged 16 years, was admitted to hospital. The lupus was now on the right arm and left shoulder, round the front of the neck under the chin, and in other places.

On April 2, 1908, an operation was performed ; a piece of skin containing small recent lupus nodules was excised from the right arm, and other recent nodules around this patch were scraped.

The material removed was sent to Blythwood : separate emulsions were made from the piece of skin and the scrapings, and inoculated into guinea-pigs : no tubercle bacilli were found in either emulsion.

General Condition of Patient on June 30, 1908.—The girl is now in good health and is strong; she has no cough and no physical signs in the lungs or elsewhere.

CULTURES.

A culture was obtained from one of the tuberculous lymphatic glands of Guinea-pig 3021.

The cultural characters of this strain were identical with those of the first strains investigated (*see* H. 71. "L.V." (*a*)).

On glycerin serum growth was pigmented and much better than on serum.

On glycerin-agar a thick creamy highly-wrinked continuous layer was produced.

On glycerin-potato a similar cream-coloured highly-wrinkled raised layer was quickly formed.

The surface of glycerin-broth became covered with a creamy-white wrinkled membrane, some portions being very dense and leathery.

INOCULATION EXPERIMENTS.

(*a*) With the original material.

Guinea-pigs.—Two guinea-pigs, Nos. 3019 and 3020, were inoculated intraperitoneally with an emulsion made from the scrapings, and two, Nos. 3021 and 3022, intraperitoneally with an emulsion made from the piece of skin.

Guinea-pig 3019 died in 18 days, of a subacute infection (?), and showed no sign of tuberculosis. Guinea-pig 3021 was killed after 37 days and showed a hempseed-sized caseating nodule in the omentum, two or three small tubercles (one caseous) in the spleen, and a dense and caseous coeliac gland the size of a pea; other organs and glands were normal.

Guinea-pig 3020 was killed after 324 days, and showed chronic general tuberculosis; and 3022 died of general tuberculosis in 279 days.

(*b*) With culture.

Rhesus Monkeys.—Two rhesus monkeys Nos. 193 and 195 were inoculated subcutaneously with culture derived from the original material through Guinea-pig 3021.

No. 195 which received 1·0 mg. died in 36 days and showed general tuberculosis, not severe and not sufficient to account for death.

No 193 which received 0·01 mg. died in 48 days probably as the result of cold. There was a small ulcer at the seat of inoculation and the adjacent glands were slightly enlarged caseous and softened. The lung contained four grey tubercles; the spleen five and the liver two small caseous nodules; and there were a few minute caseous foci in a pancreatic gland.

Rabbits.—A series of five rabbits was inoculated with the culture derived from Guinea-pig 3021, three intravenously and two subcutaneously.

One intravenous rabbit (dose 1·0 mg.) died in four days; the cause of death was not apparent.

The remaining intravenous rabbits were killed after 161 days. One (dose 0·1 mg.) showed two or three minute tubercles in one lung, and a small tubercle with a caseous centre in one kidney; the other (dose 0·01 mg.) showed about 18 reddish grey nodules up to a split pea in size and containing caseous points in the lungs, and one small tubercle in each kidney.

The two subcutaneous rabbits were killed after 161 days. One (dose 66·0 mg.) had a fibrous-walled cyst with caseous contents at the seat of inoculation, caseo-calcareous lesions in the adjacent scapular glands, and a single calcareous tubercle in the lungs; the other (dose 10·0 mg.) showed a cyst filled with caseo-pus at the seat of inoculation, and no sign of tuberculosis elsewhere.

Guinea-pigs.—Two guinea-pigs, Nos. 3147 and 3148, were inoculated one intraperitoneally and one subcutaneously, each with 1·0 mg. of culture derived from Guinea-pig 3021. They died of general tuberculosis in 30 and 71 days.

SUMMARY.

The culture investigated was obtained from lupus nodules from the right arm of a girl aged 16. Material from this girl had been received for investigation two years before (see H 71. "L.V." (*a*)).

The cultural characters of the organism and its virulence for rabbits and guinea-pigs were found to be identical with those of the first strains investigated. The culture has also been tested on two rhesus monkeys; the animals died prematurely in from five to seven weeks, but the slight amount of disease produced showed that the virus had lower virulence for this species than either the bovine or the human tubercle bacillus.

VIRUS H. 84. "M.S."

LUPUS.

Original material—The material received was scrapings from lupus nodules.

HISTORY OF PATIENT, AND DESCRIPTION OF MATERIAL RECEIVED AT BLYTHWOOD.

The patient, a woman aged 68 years, was admitted to the infirmary on February 19, 1907. The lupus was of 15 years standing, but had only recently recurred after having been quiescent for years. The patient had previously been scraped two or three times.

The lupus now covered the whole of the right cheek from the orbit to the lower margin of the inferior maxilla and from the nose to the ear. There were no scabs, only superficial nodules.

On February 25, 1907, the affected area was curetted and cauterised with Paquelin's cautery.

The scrapings were sent to Blythwood and were emulsified and inoculated into two guinea-pigs and a rabbit. Microscopical examination of the emulsion failed to show any tubercle bacilli.

The wounds left after the operation healed quickly. On April 25, 1907, the face looked very much better; there was no ulceration, but a few fresh nodules of "apple-jelly" deposit were visible at the edge of the skin affected.

CULTURES.

Cultures were obtained from two of the guinea-pigs inoculated with the original material.

Each of the strains produced on glycerin-serum a thick creamy wrinkled layer.

On glycerin-agar and potato the growths were thick, creamy and highly wrinkled.

On broth a greyish-white opaque finely wrinkled pellicle was formed; it was not quite uniform in thickness, some parts being denser than others and tinged a faint yellow.

INOCULATION EXPERIMENTS.

(*a*) With original material.

Guinea-pigs.—Four guinea-pigs (2276–2279) were inoculated intraperitoneally with the emulsion of the scrapings. The first killed after 25 days showed tuberculosis of the omentum and spleen only; the second killed after 61 days showed chronic general tuberculosis; the third was healthy when killed after 85 days; the fourth also killed after 85 days showed slight tuberculosis.

Rabbit.—Rabbit 1191, inoculated intraperitoneally with the same emulsion, was killed after 93 days and showed slight tuberculosis of the omentum only.

(*b*) With culture.

Calf.—Calf 1273 was inoculated subcutaneously with 50·0 mg. of culture derived from the original material through guinea-pig 2277. It was killed 89 days later and showed a cyst with caseo-purulent contents at the seat of inoculation, two large caseo-calcareous masses in the adjacent prescapular gland, and no tuberculosis elsewhere.

Rhesus Monkeys.—Monkey 117 was inoculated subcutaneously with 10·0 mg., Monkey 143 subcutaneously with 1·0 mg., and Monkey 141 subcutaneously with 0·01 mg. of culture derived from the original material through guinea-pig 2277.

Monkey 117 died in 73 days and showed general tuberculosis not severe and apparently insufficient to account for death.

Monkey 143 died in 110 days of chronic general tuberculosis.

Monkey 141 died in 95 days and showed local tuberculosis with a few disseminated lesions. The large intestine showed extensive non-tuberculous ulceration which was probably the cause of death.

Monkey 145 was fed with 1·0 mg. of culture derived from guinea-pig 2277. It was killed when in good health 139 days later and showed general progressive tuberculosis of moderate severity.

Rabbits.—Two series of rabbits were inoculated with varying doses of culture derived from the original material through the guinea-pig, intravenous, intraperitoneal, and subcutaneous inoculations being made in each case.

One rabbit inoculated intravenously died in eight days; the organs and glands appeared healthy. Another died after 100 days and showed one tubercle in each kidney only; the cause of death was not determined.

Two rabbits inoculated subcutaneously died four and eight days after inoculation; in one the cause of death was not determined, in the other it was pseudo-tuberculosis.

The remaining four rabbits (one intravenous, two intraperitoneal, and one subcutaneous) were killed, two 100 days, and two 147 days after inoculation, and showed very slight tuberculosis of a chronic type.

Two intravenous rabbits (doses 9·0 mg. and 1·0 mg.) and one subcutaneous rabbit (dose 56·0 mg.) were subsequently inoculated with the original culture.

One intravenous rabbit (dose 1·0 mg.) was killed after 334 days and showed chronic general tuberculosis. The lungs contained scattered grey tubercles and a few miliary caseous tubercles, and the tip of one caudal lobe was caseous and gritty. The kidneys showed pits and scars on the surface, and in the cortex and medulla scattered caseo-calcareous nodules mostly the size of millet-seeds. The right knee- and ankle-joints were swollen and contained caseo-pus; the left knee-joint showed early caseation of the synovial membrane. Two vertebral glands were enlarged and caseous. Other organs and glands were normal.

The other died in 329 days and showed slight tuberculosis of the lungs and kidneys and severe tuberculosis of the lachrymal glands and a testicle.

The subcutaneous rabbit was killed after 344 days, and showed a thin-walled cyst with caseo-purulent contents at the seat of inoculation only.

Guinea-pigs.—Four guinea-pigs were inoculated with the culture derived from guinea-pig 2277, two intraperitoneally and two subcutaneously, the doses in each case being 1·0 and 0·1 mg.

The two intraperitoneal animals died after 50 and 59 days of general tuberculosis, one subcutaneous animal died in 257 days of chronic general tuberculosis, the other died in 855 days and showed general healed tuberculosis.

A second series of guinea-pigs was inoculated six months later, the same culture being used. Two were inoculated intraperitoneally and two subcutaneously, the doses as before being 1·0 and 0·1 mg. All died in from 18 to 40 days, and showed general tuberculosis less severe than is usually produced by a human Group II. bacillus.

Two more guinea-pigs were afterwards inoculated subcutaneously, each with 1·0 mg. of the same culture. They died of tuberculosis in 223 and 256 days respectively.

SUMMARY.

Cultures of tubercle bacilli were isolated from two guinea-pigs inoculated with lupus nodules taken from a woman aged 68 years.

Both strains grow luxuriantly on media containing glycerin and one has been shown to possess only slight virulence for the calf and rabbit.

The culture has a lower virulence for the guinea pig and a much lower virulence for the rhesus monkey than is usual for slightly virulent human tubercle bacilli.

Virulence after passage.

The virus was apparently increased in virulence for the monkey and guinea-pig by passage through the monkey, but was not increased in virulence for the guinea-pig, monkey, or rabbit by passage through the guinea-pig.

VIRUS H. 85. "H.B."

LUPUS.

Original material—Scrapings from lupus.

HISTORY OF PATIENT AND DESCRIPTION OF MATERIAL RECEIVED AT BLYTHWOOD.

The patient, a boy aged five years, was admitted to the infirmary in April, 1907, for lupus of the nose.

The child was breast-fed until he was 21 months old. He had ophthalmia when two weeks old; has had measles; and had bronchitis and whooping-cough, followed by ophthalmia, when three years old.

A swelling was noticed in the right groin, and one in the left elbow, when the child was four years old. In October, 1906, he went to Margate, and returned in March, 1907, with lupus of the nose.

Family History.—The father died in January, 1905, aged 36, of phthisis and (?) Bright's disease. There were ten other children, five of whom died within a week of birth. One sister aged 7 had an "abscess in the neck" when two years old.

Operation.—On April 17, 1907, the lupus was scraped. The scrapings were sent to Blythwood, and were emulsified and inoculated into four guinea-pigs. Microscopical examination of the emulsion failed to show any tubercle bacilli.

Present state, July 13, 1908.—The nose is now much better, but the lupus is spreading in a nodular form over the upper lip, the left side of the face, and on to the chin; a few very small glands can be felt on each side of the neck; there are no physical signs in the lungs.

CULTURES.

Cultures were obtained from two of the guinea-pigs inoculated with the original material, namely, guinea-pigs 2363 and 2365.

Both strains have been tested on the differential media, and have given practically identical results.

On serum the growths were after many subcultures (in one case 25) thin grey and uniform with a dry glazed surface, and when scraped together were moist and readily emulsified.

On glycerin-serum growth was whiter moister and two or three times as thick as on serum.

Very poor growths have been obtained on glycerin-agar; on one tube five weeks after inoculation there was a patchy grey haze in which numerous minute filmy grey colonies were seen; these coalesced in places, but did not become raised.

On potato, a thin moist grey layer quickly formed; this did not subsequently increase appreciably in thickness, but in one case became studded with raised yellowish colonies up to a pin's head in size, and in two others developed one or two raised yellow colonies.

The surface of small bottles of broth was soon covered with a greyish-white uniform and not very thick membrane, which quickly became moist and sank. On a flask containing 200·0 cc. of broth a very good growth was obtained, little inferior to those produced by the more easy-growing human tubercle bacilli; the pellicle was moderately thick greyish-white with a finely granular or warty wrinkled surface, and a creamy tinge in the more wrinkled parts.

INOCULATION EXPERIMENTS.

(*a*) With the original material.

Guinea-pigs.—Four guinea-pigs, Nos. 2363 to 2366, were inoculated intraperitoneally with an emulsion of the scrapings.

Two died, each after one day, of pseudo-tuberculosis; the others, Nos. 2363 and 2365, were killed after 42 and 51 days respectively and showed slight general tuberculosis.

(*b*) With culture.

Calves.—Two calves were inoculated subcutaneously, No. 1331 with 96·0 mg. of culture derived from the original material through guinea-pig 2365 and No. 1289 with 50·0 mg. of culture derived from the original material through guinea-pig 2363. The former was killed after 90 days and showed a small fibrous-walled cyst at the seat of inoculation, two calcareous patches in the left prescapular gland, and no tuberculosis elsewhere.

The latter was killed after 94 days; there was a cyst at the seat of inoculation; the prescapular gland was partly dense and caseous, partly calcareous; the thoracic ileo-colic and portal glands contained calcareous patches and nearly all the other lymphatic glands in the body contained calcareous or caseous tubercles in varying number. There was one tubercle in the lung, moderately numerous miliary tubercles in the spleen, one in a suprarenal body and a few small ones in the Peyer's patches of the small intestine.

One calf, No. 1373, was inoculated intravenously with 10·0 mg. of culture derived from guinea-pig 2365.

It was killed when dying 28 days later. The lungs were almost entirely red firm airless and speckled with indefinite and irregular greyish foci; in the crepitant lobules no tubercles were seen. The thoracic glands were enlarged and firmer than normal. Tubercle bacilli were numerous in the organs and glands.

Horses.—Two yearling colts were inoculated, one (No. 5) subcutaneously with 50·0 mg. of culture derived from the original material through guinea-pig 2363, the other (No. 11) intravenously with 10·0 mg. of the culture derived from guinea-pig 2365.

No. 5 was killed when well after 112 days. There was a patch of fibrous tissue at the seat of inoculation; in the left prescapular region there were two large glands filled with caseo-pus and many smaller caseous glands; one left cervical gland was large and caseous, another contained a caseous nodule. Sparsely scattered small grey tubercles were seen in the lungs, spleen and liver.

No. 11 died in 51 days of acute general tuberculosis. The lungs were closely beset with tubercles up to 2 mm. in diameter, and a large part was consolidated, and the thoracic glands were much enlarged and caseated. Whitish tubercles up to 1 mm. were fairly numerous in the medulla of each kidney. The portal, coeliac and other abdominal glands were enlarged and caseated. Tubercle bacilli were swarming in the organs and glands.

Goat.—Goat 63 was inoculated subcutaneously with 10·0 mg. of the culture derived from guinea-pig 2363. It was killed when very ill after 402 days and showed severe chronic general tuberculosis.

Pigs.—Two pigs were inoculated subcutaneously with the culture derived from guinea-pig 2363. No. 115 received 50·0 mg. and No. 117 10·0 mg.

Pig 115 was killed when in good health after 307 days and showed slight general tuberculosis, apparently retrogressive. There was a fibro-calcareo-caseous lesion at the seat of inoculation in the abdominal wall, and the adjacent inguinal gland was large and caseated; other glands adjacent to the tumour were calcareous. The lungs contained fairly numerous small calcareous nodules, the spleen two caseo-calcareous tubercles. The bronchial and portal glands contained calcareous nodules; the mesenteric glands were much enlarged and caseo-calcareous; other abdominal glands contained caseo-calcareous nodules and patches. Three glands in the throat contained each one or more caseo-calcareous nodules.

Pig 117 was killed after 268 days when apparently in good health and showed severe chronic general tuberculosis. At the seat of inoculation in the abdominal wall there was a nodular tumour composed of caseous encapsuled nodules, and there were similar nodules in the adjacent tissues; the adjacent glands were much enlarged caseous and gritty. The lungs were closely beset with caseous encapsuled nodules and showed also numerous small tubercles. The spleen contained a number of similar caseous nodules the largest over 1 cm. in diameter and a few caseous tubercles. The liver was closely beset with similar caseous nodules. There were four tubercles in each kidney. The left testicle contained an encapsuled caseous nodule and there was a smaller nodule in the tunica vaginalis. The thymus contained a caseous nodule. Nearly all the lymphatic glands in the body contained a varying number of softened caseous nodules; the bronchial, portal, coeliac, iliac, and many mesenteric glands were practically caseous throughout.

Chimpanzees.—Chimpanzee 9 was cutaneously inoculated with 0·01 mg. of the culture derived from guinea-pig 2365; (the skin between the shoulders was scarified with a scalpel over an area 5·8 by 4·5 cm. and the culture applied). Chimpanzee 11 was fed with 1·0 mg. of the culture. Both were young animals.

Chimpanzee 9 died 170 days after inoculation, after an illness lasting a few days only. There was no tuberculosis at the seat of inoculation. In the right axilla there was an ulcer with caseo-purulent floor (which had developed out of an ulcerating caseous gland). Other axillary glands were normal, and there was no tuberculosis elsewhere. The cause of death was not apparent.

Chimpanzee 11 was killed when in good health after 271 days, There was a focus of yellow pus in one tonsil; about two dozen small ulcers were seen in the lower half of the small intestine, the majority shallow and without caseation. There was a large mass composed of enlarged caseous and softened glands in the anterior end of the mesentery, elsewhere the mesenteric glands were separate and about sixteen of them were caseous and softened. One pancreatic gland was similar. In the spleen there was a mass (1 cm.) composed of aggregated caseous nodules. One axillary gland was caseous. There was a tubercle in the liver and two on the serous surface of the small intestine.

Rhesus Monkeys.—Three monkeys, 123, 121, and 119, were inoculated subcutaneously with the culture derived from guinea-pig 2365, in doses of 1·0 mg., 0·1 mg., and 0·01 mg. respectively.

Monkey 153 was inoculated subcutaneously with 10·0 mg. of the culture derived from guinea-pig 2365.

Monkeys 125 and 127 were fed, the one with 1·0 mg. and the other with 0·1 mg., of the culture derived from guinea-pig 2365.

Monkey 123 died in 132 days. There was a flat caseous patch at the seat of inoculation; many axillary cervical and vertebral glands were enlarged caseous and softened, others contained caseous tubercles. The lungs were crepitant and showed a moderate number of small grey nodules, some with caseous centres. The spleen was much enlarged and

closely beset with softened caseous nodules up to a pea in size. The liver contained a few small caseous and softened nodules; there were two in the right kidney. The bronchial and several abdominal glands contained one or two caseous tubercles each.

Monkey 121 was killed when well after 97 days. At the seat of inoculation there was a cyst containing caseous substance and watery fluid. One right axillary gland was much enlarged and consisted of a cyst with caseo-purulent contents, and one vertebral gland was enlarged and caseous. Each lung contained about forty small translucent tubercles and a few larger ones with caseous centres. A few caseo-purulent tubercles were seen in the portal and pancreatic glands, and a few foci (containing very numerous T.B.) in one or two mesenteric glands. The Malpighian bodies of the spleen were conspicuous, and a few T.B. were seen in a smear from one.

Monkey 119 died in 271 days of general tuberculosis. The local lesion consisted of two caseous and softened masses. The right axillary cervical and inguinal glands were greatly enlarged caseous and softened; the vertebral glands adjacent to the tumour formed a large caseous and softened mass. The bronchial and several abdominal glands showed varying degrees of caseation, some being much enlarged and caseous throughout. There were four caseous softenod nodules in the lung and twenty in the spleen of various sizes, the largest 1·5 cm. in diameter. In the liver there was a moderate number of submiliary grey tubercles and one larger one. There was a caseous tubercle in the small intestine.

Monkey 153 was killed when ill after 59 days. There was a large foul ulcer at the seat of inoculation, and the adjacent glands contained caseous patches and nodules. The lungs were crepitant and contained sparsely scattered grey tubercles, and there were two minute tubercles in the right kidney. Tubercle bacilli were numerous in a smear from the spleen.

Monkey 125 died in 116 days. One submaxillary and one pharyngeal gland were enlarged caseous and softened. About a dozen caseous nodules and tubercles were seen in the small intestine, some of which were ulcerated, and there was one in the large intestine. All the mesenteric, nine colic, and one rectal glands were enlarged and caseous. The spleen contained one softened caseous nodule, the liver nine or ten caseo-purulent cysts (the largest the size of a pea). The lungs contained nine dense caseous nodules up to 1 cm. in diameter. Three thoracic glands were caseous.

Monkey 127 was killed when dying after 115 days. One submaxillary gland was caseous and softened. The glands in the anterior part of the mesentery formed a large caseous and softened mass; two only in the posterior part were affected. One ileo-colic, many colic, and three rectal glands were caseous or contained caseous nodules. There were several firm caseous nodules along the mesenteric veins. There was no tuberculous ulceration of the intestine. The spleen contained six caseous and softened nodules; there were three or four miliary caseous tubercles in the lung.

Rabbits.—Four rabbits were inoculated with the culture derived from guinea-pig 2363; two intravenously (doses 1·0 and 0·1 mg.), one intraperitoneally (dose 1·0 mg.), and one subcutaneously (dose 10·0 mg.); afterwards another rabbit was inoculated subcutaneously with 40·0 mg.

One intravenous rabbit died in 11 days of psorospermosis, and showed in the left lung, which was dark red in colour, very numerous small grey tubercles; the right was normal except a portion of one lobe which was dark red and contained similar tubercles. The other intravenous rabbit died in 39 days of general miliary tuberculosis.

The intraperitoneal rabbit died in 41 days of general miliary tuberculosis.

One subcutaneous rabbit (10·0 mg.) was killed after 153 days. At the seat of inoculation there was an aggregation of caseous nodules and two scapular glands were caseo-calcareous. The lungs were crepitant and contained each a dozen or more caseous nodules up to 8 mm. in diameter. One kidney showed a caseous tubercle. The other subcutaneous rabbit which received 40·0 mg. died in 157 days. There was a large local tumour containing dry caseous substance, and caseous gritty nodules in the scapular and axillary glands. The glands at the entrance to the thorax were much enlarged and closely beset with caseous gritty tubercles. The lungs contained sparsely scattered small caseous tubercles. There were scattered tubercles in the kidneys and the calyces of the left contained caseo-pus.

Four series of rabbits were inoculated with the culture derived from guinea-pig 2365; in all eight were inoculated intravenously in doses of 1·0 mg. and 0·1 mg. and in one case 0·01 mg.; one intraperitoneally in a dose of 10·0 mg., and four subcutaneously in doses of 10·0 mg. (two), 16·0 mg., and 20·0 mg.

Five intravenous rabbits died in 16, 21, 31, 38, and 48 days respectively of general tuberculosis; one died in 10 days of causes other than tuberculosis and showed early tuberculosis of the lungs and spleen; another died in 110 days of general tuberculosis; and the rabbit inoculated with 0·01 mg. died in 117 days, also of general tuberculosis.

The intraperitoneal rabbit died in 35 days of general tuberculosis.

One subcutaneous rabbit (20·0 mg.) died in 34 days and showed a caseous tumour broken-down in the centre, an enlarged and caseous scapular gland, an occasional small tubercle in the lung, one tubercle in the spleen, a few pits but no tubercles on the surface of the kidneys and caseous foci in tho ventral mediastinal glands.

Two inoculated each with 10·0 mg. died in 49 and 96 days, death in each case being apparently due to secondary infection of the local lesion. The former showed a large caseous ulcer, caseous nodules in the nearest glands, small grey tubercles in the lungs (which were crepitant), scattered miliary tubercles in the kidneys, and some small tubercles in the liver and spleen; one thoracic gland had a caseous patch.

The latter showed a large cyst filled with foul-smelling caseo-pus, with a small opening in the skin covered with dried discharge. The left scapular gland contained two caseo-purulent nodules; the lungs were crepitant and contained sparsely scattered grey tubercles. There was no tuberculosis elsewhere.

The remaining subcutaneous rabbit (dose 16·0 mg.) was killed after 72 days. There was a large foul ulcerated tumour at the seat of inoculation; the adjacent glands were much enlarged and caseo-purulent; the lungs were crepitant and contained very sparsely scattered miliary tubercles; each kidney contained about half-a-dozen submiliary caseous tubercles.

Guinea-pigs.—Two guinea-pigs were inoculated each with 1·0 mg. of the culture derived from guinea-pig 2363, one intraperitoneally, the other subcutaneously. They died of general tuberculosis, the former in 26 days, the latter in 140 days.

Three series of guinea-pigs were inoculated with the culture derived from guinea-pig 2365; six animals were inoculated, three intraperitoneally (doses 1·0 mg., 1·0 mg., and 0·1 mg.), and three subcutaneously (with equivalent doses). The former died of general tuberculosis in 14, 17, and 40 days respectively; the latter died of general tuberculosis in 56, 86, and 123 days respectively.

Fowls.—Two fowls were inoculated intravenously with the culture derived from guinea-pig 2365, one with 10·0 mg., the other with 1·0 mg. They were killed after 146 days and showed no sign of tuberculosis; a guinea-pig inoculated with an emulsion of the spleen of one however died of tuberculosis.

SUMMARY.

The culture was obtained from a case of lupus in a child aged five years.

On the ordinary test media it does not grow so well as H 53. D.H., but has a rather lower virulence for calves, pigs, and rabbits.

It produces fatal tuberculosis in rabbits when inoculated intravenously or intraperitoneally, but the duration of life is much longer than in rabbits inoculated with equivalent doses of bovine tubercle bacilli. By subcutaneous inoculation the virulence of the virus for the rabbit appears to be only slightly higher than that of the common human tubercle bacillus.

For calves the culture has a much lower virulence than the bovine tubercle bacillus, but a higher virulence than the slightly-virulent human tubercle bacillus.

It has produced severe generalised tuberculosis in the goat and pig not fatal within the period of observation.

The culture is slightly virulent for the horse by subcutaneous inoculation. It is not virulent for fowls.

Its virulence for the guinea-pig is lower than that of the bovine tubercle bacillus. For the rhesus monkey also it has lower virulence than that possessed by the bovine tubercle bacillus; fatal general tuberculosis has been produced in this species of animal, but the duration of life was much prolonged.

Virulence after passage.

This virus was not increased in virulence by passage through a series of 5 calves, or by a single residence in the body of a monkey.

VIRUS H. 91. "H.S."

LUPUS.

Original material—Lupus nodule with attached skin removed by operation.

HISTORY OF PATIENT.

The patient was a child aged 9½ years. He was brought up on barley water and cow's milk, and sometimes Nestlé's milk. He was one of twins.

There was no history of tuberculosis in the family. The maternal grandparents were both living. The mother was one of 12 children, of whom seven others were living; one died aged 41 years of Bright's disease, one was deformed from birth and died when nine years old, one died as a baby with bronchitis, and one died of diphtheria when a baby. The paternal grandparents were both living. The father was one of 5 children, all living and well.

When 5½ years old the child had measles, and then got enlarged glands under his chin. These were removed, but a sore came in the scar and other glands in the same region became enlarged. The sore did not heal but became larger, and a lupus nodule developed in it. This, after it had been present for 18 months, was excised on September 10, 1907.

The material excised—a lupus nodule with skin attached—was sent to Blythwood, where it was made into an emulsion and inoculated into three guinea-pigs. Microscopical examination of the emulsion failed to show any tubercle bacilli or other micro-organisms.

November 20, 1907. There has been no recurrence since the operation; the glands have become small and hard.

Present state, August 27, 1908.—The child is now in good health, and has no cough and no physical signs. The scar is quite healed, but in the region of the scar there are two small glands. His mother states that these are getting smaller; no glands are to be felt anywhere else.

CULTURES.

A culture was obtained from the pyloric gland of Guinea-pig 2590.

On bovine serum it produced good growths with a yellow pigment; on the same serum with the addition of 5 per cent. glycerin the growths were similar in amount and appearance.

On some tubes of agar an almost uniform grey ground-glass layer showing in places fine wrinkling was formed; on another tube the layer was appreciably thicker, though somewhat more patchy, greyish-white and more definitely wrinkled with raised slightly pigmented ridges where the culture was more thickly sown; on the condensation water there was a grey translucent pellicle with yellow patches.

On potato at the end of a month there was only a thin dull grey layer which in two cases on continued cultivation showed no further increase; in three others however in the 5th or 6th weeks colonies were seen developing in the grey layer; these grew slowly and some attained the size of a pin's head; the surface of one potato became closely covered with colonies which in places became aggregated together forming warty greyish-yellow patches.

At the end of three months only three quarters of the surface of a flask of broth (200·0 cc.) was covered; the membrane was grey and translucent and resembled fairly thick tissue paper; it was moist and beginning to sink at the margins.

The pellicle on litmus milk in the same time was much thicker; it completely covered the surface, was greyish white and finely wrinkled, and contained several denser yellowish patches.

INOCULATION EXPERIMENTS.

(*a*) With the original material.

Three guinea-pigs, Nos. 2589, 2590, and 2591, were inoculated intraperitoneally with an emulsion made from the original material. One killed after 30 days showed one tubercle in the omentum only; another killed after 49 days had very slight tuberculosis of the omentum and a pyloric gland only; the third killed after 92 days was healthy.

(*b*) With culture.

Calf.—One calf, No. 1353, was inoculated subcutaneously with 50·0 mg. of culture derived from the original material through guinea-pig 2590. It was killed 119 days later and showed a cyst containing caseo-pus at the seat of inoculation and half a dozen small caseo-calcareous nodules in the adjacent gland only.

Rhesus Monkeys.—Two monkeys, Nos. 139 and 133, were inoculated subcutaneously with 1·0 mg. and 0·1 mg. respectively of culture derived from the original material through guinea-pig 2590.

Monkey 139 was killed when in moderately good health after 197 days. There were several caseous nodules at the seat of inoculation and the neighbouring glands were much enlarged caseous and softened. There were three small tubercles in the lungs, eight softened caseous nodules in the spleen, and three muco-purulent cysts in the liver. Many of the lymphatic glands contained caseous nodules. Behind the right eyeball there was a large caseo-purulent swelling and the eye was disorganized and filled with caseo-pus; another caseous nodule was situated just below the orbital ridge. There were four caseous nodules on the frontal bones of the skull, the bone below each being necrosed. Five yellow caseous nodules and one soft grey nodule were seen on the pons.

Monkey 133 was killed when in apparent good health after 203 days. At the seat of inoculation there was a group of caseous nodules and the neighbouring glands were much enlarged caseous and softened; the thoracic and abdominal glands were enlarged and extensively caseous. The lungs contained a moderate number of yellow nodules with grey margins, the spleen twenty small caseous nodules, the kidneys less than a dozen similar nodules. There were two or three muco-purulent cysts, pea-sized

caseous nodules, and miliary tubercles in the liver. There were several ulcers in the intestine which showed no caseation. There was a caseous nodule in the grey matter of the gyrus fornicatus; and six areas of caseo-necrosis in the bones of the skull.

Rabbits.—Four rabbits were inoculated with varying doses of the culture derived from guinea-pig 2590, one intravenously, one intravenously and partly subcutaneously, and two subcutaneously. All were killed when well 235 days later.

The intravenous rabbit (0·1 mg.) showed two minute transparent tubercles in the lung only.

One subcutaneous rabbit (50·0 mg.) showed a caseo-purulent cyst at the seat of inoculation and some whitish caseo-pus in the calyces of one kidney; the other (10·0 mg.) showed a healed ulcer at the seat of inoculation and two tubercles in the lungs, one the size of a millet seed and caseo-calcareous, the other small and grey.

The remaining rabbit (1·0 mg.) showed a small collection of caseo-pus around the vein at the seat of inoculation and three minute greyish foci in the lungs.

Fowls.—Two fowls were inoculated intravenously each with 10·0 mg. of the culture derived from guinea-pig 2590.

They were killed 239 days later. One showed no sign of tuberculosis; the other showed early tuberculosis of the intestines, liver, and spleen (spontaneous).

Guinea-pigs.—Four guinea-pigs were inoculated with the culture derived from guinea-pig 2590, two intraperitoneally (doses 1·0 and 0·1 mg.) and two subcutaneously (doses 1·0 and 0·1 mg.). The former died in 19 and 21 days and showed early general tuberculosis, the latter died in 40 and 73 days and showed general tuberculosis, not severe.

Two guinea-pigs were subsequently inoculated subcutaneously each with 1·0 mg. of the culture; they died of general tuberculosis in 24 and 55 days.

SUMMARY.

The culture investigated was obtained from a case of lupus in a boy aged 9½ years.

On glycerin media it grows like the more easy-growing bovine tubercle bacilli, but on serum it produces moderately thick pigmented layers.

It has low virulence for the calf and rabbit, is less virulent for the guinea-pig and much less virulent for the monkey than the human or the bovine tubercle bacillus.

VIRUS H. 92. "D.N."

LUPUS.

Original material—A lupus nodule with attached skin, removed by operation.

HISTORY OF PATIENT.

The patient was a girl aged 3 years 9 months. A sore came on her cheek when she was 25 months old, and remained without healing, and was spreading slightly, until it was removed by operation on September 10, 1907.

The material removed (a lupus nodule with attached skin), was sent to Blythwood, where it was emulsified and inoculated into three guinea-pigs. Microscopical examination of the emulsion failed to show any tubercle bacilli or other micro-organisms.

November 20, 1907. There has been no recurrence since the operation.

Family history.—The child was breast fed alone for 12 months, and then had other foods added. There were five other children living and healthy; another died a few days after birth. The maternal grandparents were both living, the mother was one of four children, of whom two others were living and well; one died aged 27 of "consumption." The paternal grandmother, aged 56 years, died last Christmas of "congestion of the lungs"; the grandfather was still alive, aged 64 years. The father was one of seven children, of whom six were living; one died last June of "consumption" and tuberculosis of the throat, aged 27. This child had not been living in connection with either of the two relations who had died.

Present state, August 21, 1908.—The child is in good health, the scar quite healed; there is no cough, no enlarged glands, and no physical signs of tuberculosis.

CULTURES.

Cultures were obtained from two of the guinea-pigs, Nos. 2592 and 2593, inoculated with the original material. Both strains have been tested on the differential media.

On glycerin-serum in each case a much thicker growth was obtained than on serum alone, the growths on both media being pigmented.

On glycerin-agar, in one case a thick creamy-yellow wrinkled layer was obtained; with the other strain (G.P. 2593) the results were unsatisfactory, the best growth obtained being grey translucent and finely wrinkled.

On glycerin-potato very good growths were obtained, the G.P. 2593 strain producing very thick raised creamy-yellow wrinkled layers.

The surface of broth in each case became covered with a membrane, thick yellow and highly wrinkled or warty near the serum, greyish-white or creamy-white finely wrinkled and of moderate thickness elsewhere.

INOCULATION EXPERIMENTS.

(*a*) With original material.

Guinea-pigs.—Three guinea-pigs, Nos. 2592, 2593, and 2594, were inoculated intraperitoneally with an emulsion made from the original material. The two former were killed after 49 days and showed early general tuberculosis, the third died in 240 days of chronic general tuberculosis.

(*b*) With cultures.

Calves.—One calf, No. 1317, was inoculated subcutaneously with 50·0 mg., and another, No. 1377, intravenously with 10·0 mg. of culture derived from the original material through guinea-pig 2592.

Calf 1317 died in 26 days of renal disease. There was a caseo-necrotic tumour at the seat of inoculation and the left prescapular and one left cervical glands were largely composed of a network of caseous tissue in a translucent matrix. Some minute foci were seen in the lungs and liver (smears from each organ showed a few T.B.). One yellow focus was seen in a portal gland. T.B. were seen in a smear from a thoracic gland which was slightly congested; none was seen in smears from the spleen and kidney.

Calf 1377 died in 32 days of tuberculosis. The lungs were consolidated, and minute grey tubercles were seen everywhere throughout the organs. The thoracic glands were enlarged and beset with grey tubercles. Numerous minute grey granules (early tubercles) were seen on the endocardium. A few grey foci were seen on the surface of the liver and scattered grey foci in the kidneys. Tubercle bacilli were moderately numerous in the organs and in all the glands examined.

Pigs.—Two young pigs, Nos. 107 and 109, were inoculated subcutaneously each with 50·0 mg. of culture derived from the original material through guinea-pig 2592.

Pig 107 was killed after 133 days. There was a small scar at the seat of inoculation and scattered caseous tubercles in the subcutaneous tissues. A right inguinal and a ventral mediastinal gland were enlarged caseous and softened. In the lungs there were numerous indefinite greyish foci in places forming small patches (smear, a few T.B.). The bronchial glands and two or three glands in the neck contained scattered soft whitish foci. Two small caseous nodules were seen in one suprarenal body. There was an opening in the cornea of each eye and the whole eye was disorganized; there was no definite tuberculosis, but tubercle bacilli were found in the fluid from the anterior chamber.

Pig 109 was killed after 159 days. There were scattered caseous nodules in the subcutaneous tissue at the seat of inoculation, three of which had ulcerated; the adjacent inguinal and ventral mediastinal glands were enlarged and caseous; one precrural gland contained caseous nodules, and one submaxillary gland showed three caseous tubercles. In the lung two caseous tubercles were seen. There was an opening in the cornea of the right eye and the whole eye was disorganized; tubercle bacilli were found in smears from the anterior and posterior chambers; the posterior chamber was filled with yellow tenacious pus.

Horses.—Two yearling colts were inoculated with culture derived from the original material through guinea-pig 2592; No. 9 received 100·0 mg. subcutaneously, and No. 7 10·0 mg. intravenously.

Horse 9 was killed when well after 136 days. There was a linear scar at the seat of inoculation, and two left prescapular glands contained each a small fibro-calcareous patch. In the lung one small grey gritty nodule was seen, and one bronchial gland showed a calcareous tubercle; in one ileo-colic gland there were a few foci. No tubercle bacilli were found in smears from several of the lesions.

Horse 7 was killed when well after 137 days. The lungs were crepitant and showed small translucent grey tubercles, numerous in the posterior third of the caudal lobes, scanty in the anterior lobes. In the bronchial glands there were a few calcareous foci, and in the liver one grey translucent tubercle.

Rhesus Monkey.—One rhesus monkey, No. 177, was inoculated subcutaneously with 1·0 mg. of culture derived from the original material through guinea-pig 2593.

The monkey died in 39 days of general tuberculosis.

Rabbits.—Two series of rabbits were inoculated with the culture derived from guinea-pig 2592. Four animals in all were inoculated intravenously in doses of 1·0 and 0·1 mg. and one subcutaneously in a dose of 10 0 mg.

One intravenous rabbit died in 55 days of cellulitis, and showed in the lungs scattered grey tubercles slightly caseous in the centre, and some thin caseous patches in the margins; there were no visible tubercles elsewhere.

A second intravenous rabbit died in 183 days. There was a group of thin-walled glands containing muco-pus in the neck, a very few caseo-calcareous tubercles in the lung, and one or more caseous tubercles in each kidney. The right knee joint was tuberculous.

A third died in 188 days. The lungs showed four calcareo-caseous tubercles, the bronchial glands discrete calcareous tubercles, the left kidney two caseating tubercles, and the right kidney several caseous streaks and caseo-pus in the calyces. The cause of death was not apparent.

The fourth was killed after 208 days and showed general tuberculosis (?) spontaneous.

The subcutaneous rabbit was killed after 258 days and showed several small cysts with thin purulent contents and small caseous nodules at the seat of inoculation, and two soft caseous patches in the adjacent gland; there was no tuberculosis elsewhere.

A series of rabbits was inoculated subcutaneously with the culture derived from guinea-pig 2593; one received 50·0 mg., another 22·0 mg.

The former was killed after 258 days and showed a tumour at the seat of inoculation filled with thick caseo-pus, and no tuberculosis elsewhere. The latter died in 208 days and showed a large caseous and softened local tumour, scapular glands enlarged but not caseous, a small caseous patch at the tip of each cephalic lobe of the lung and a caseous streak in one kidney; the cause of death was not determined.

Guinea-pigs.—Two series of guinea-pigs were inoculated with the culture derived from guinea-pig 2592. Three in all were inoculated subcutaneously and one intraperitoneally, the dose in each case being 1·0 mg.

One subcutaneous guinea-pig died in one day; the cause of death was not apparent. The two others died in 46 and 58 days of general tuberculosis, and the intraperitoneal guinea-pig died in 20 days, also of general tuberculosis.

Three guinea-pigs were fed daily with the culture derived from guinea-pig 2592 for five days; each received about 1·0 mg. per day. They died of general tuberculosis in 36, 126, and 148 days.

Fowls.—Two fowls were inoculated intravenously with the culture derived from guinea-pig 2593, one receiving 50·0 mg., the other 33·0 mg.

Both were killed after 206 days; the former showed one small greyish-white tubercle in the liver and no tuberculosis elsewhere, the other was entirely free from tuberculosis.

Mice.—Four mice were inoculated with the culture derived from guinea-pig 2592, two intraperitoneally (dose 10·0 mg. each), and two subcutaneously (dose 50·0 mg. each).

The former two died twenty-four hours after inoculation; the cause of death was not apparent in either case.

One subcutaneous mouse died in 10 days. In the subcutaneous tissues at the seat of inoculation there was a quantity of granular purulent substance and the skin was in one place ulcerated. The adjacent inguinal gland was surrounded by pus and was in an early state of caseation Smears from the lung, liver, and kidney showed tubercle bacilli in scattered clumps; none was seen in a smear from the spleen. The other subcutaneous mouse died in 26 days. There was a clean local ulcer 1 cm. in diameter and the left inguinal gland appeared slightly enlarged. There was no sign of tuberculosis in the organs but smears from the spleen and liver showed scattered tubercle bacilli.

SUMMARY.

From a case of lupus in a child aged 3¾ years a culture was obtained, which grows well on artificial media, is slightly virulent for the calf, pig, horse, and rabbit, and is fully virulent for the rhesus monkey and guinea-pig.

VIRUS H. 99. "L.K."

LUPUS.

Original material—A lupus nodule removed by operation.

HISTORY OF PATIENT AND DESCRIPTION OF MATERIAL RECEIVED AT BLYTHWOOD.

The patient was a girl aged 8 years. She was admitted to hospital on January 31, 1908, suffering from lupus.

The duration of the disease was not known; it was said to have begun on the nose and to have spread to the skin under the chin. The child had always been healthy except for the lupus. There was no history of tuberculosis in the family; the mother was alive, the father dead—the cause of death was not known.

When admitted to hospital there was a patch of lupus on the upper lip, and the neck just below the jaw and parallel to it was marked by a broad irregular patch of ulcerating lupus measuring about 9 cm. from side to side; there was also a recent nodule on the nose.

On February 6, 1908, an operation was performed, the nodule on the upper lip being excised. The material removed—a small piece of skin containing a lupus nodule—was sent to Blythwood, and was emulsified and inoculated into guinea-pigs.

Microscopical examination of the emulsion showed one tubercle bacillus, long slightly curved and uniformly stained.

Present condition.—September, 1908. The child is stated to be in excellent general health and to have no other symptoms of tuberculosis.

CULTURES.

Cultures were isolated from two of the guinea-pigs inoculated with the original material, two strains being raised from each animal. All the strains have been tested and good growths identical with those produced by the most easy-growing human tubercle bacilli have been obtained in each case on one or more of the various media employed.

On serum the growths were abundant and pigmented; on glycerin-serum growth was in some cases similar to that on serum, in others rather more luxuriant.

On glycerin-agar thick uniformly-wrinkled creamy layers were formed.

On potato the growths were very luxuriant wrinkled or warty and deeply pigmented.

The growths on broth were not so satisfactory as, or consistent with, the growths on the solid media; in two instances the surface of the broth became covered with a grey translucent membrane containing opaque whitish and not very thick patches.

Better growths were obtained on gelatine; in one case the whole surface became covered with uniform wrinkled greyish-yellow membranes, in another the membrane was grey and translucent and showed creamy wrinkled patches.

INOCULATION EXPERIMENTS.

(*a*) With the original material.

Guinea-pigs.—Three guinea-pigs, 2926, 2927, and 2928, were inoculated intraperitoneally with an emulsion made from the original material.

No. 2926 died in 32 days, and 2928 in 28 days, both of early general tuberculosis; No. 2927 was killed after 28 days and showed tuberculous lesions similar to the others.

(*b*) With culture.

Calf.—Calf 1401 was inoculated subcutaneously with 50·0 mg. of culture derived from the original material through guinea-pig 2927. It was killed 120 days later and showed local tuberculosis and scattered calcareous foci in the mesenteric and colic glands only.

Rhesus Monkeys.—Three rhesus monkeys, Nos. 147, 149, and 151, were inoculated with culture derived from the original material through the guinea-pig, the doses being 1·0 mg., 0·1 mg., and 0·01 mg. They died of general tuberculosis in 34, 50, and 36 days respectively.

Rabbits.—Five rabbits were inoculated with the culture derived from guinea-pig 2927—three intravenously in doses of 1·0, 0·1, and 0·01 mg. and two subcutaneously in doses of 50·0 and 35·0 mg.

One intravenous rabbit died of general tuberculosis in 21 days. The second died in 143 days and showed on the dorsal surfaces of the lungs irregular thin greyish-yellow tracts, and elsewhere on the surface scattered caseous tubercles and a few caseous nodules, and in the substance sparsely scattered tubercles; the thin margins of the organ were caseating. In the kidneys there were numerous caseous tubercles up to a hemp seed in size and there was one tubercle in the spleen. The kneejoints, mammary gland, eyes and lachrymal glands were tuberculous. The third rabbit died of psorospermosis the day after inoculation.

One subcutaneous rabbit died in 89 days. There was a very large caseous and softened local tumour; the adjacent glands were enlarged caseous and softened. The lungs were rather closely beset with fibro-caseous nodules. There were one or two caseous foci in the kidneys. The spleen was enlarged but showed no tubercles.

The other subcutaneous rabbit was killed after 144 days. There was an ulcerated caseo-fibrous local lesion; the adjacent glands were normal. The lungs showed on the dorsal borders greyish-yellow caseous patches, and patches in the thin margins, and on the surfaces scattered caseous gritty tubercles, and a few grey nodules. There was no tuberculosis elsewhere.

Guinea-pigs.—Two guinea-pigs were inoculated each with 1·0 mg. of culture derived from guinea-pig 2927, one intraperitoneally the other subcutaneously. They died of general tuberculosis in 16 and 27 days respectively

Parrot.—Parrot 13 was cutaneously inoculated with the culture derived from guinea-pig 2928. The skin at the root of the beak was scarified with a knife dipped in a suspension of culture.

It died in 250 days of general miliary tuberculosis. There was no lesion at the seat of inoculation.

SUMMARY.

From a case of lupus in a girl aged 8 years, a culture was isolated which grows well on artificial media, is virulent for monkeys and guinea-pigs and slightly virulent for the calf. The results obtained in the rabbits were rather more severe than are usually obtained with viruses which grow luxuriantly.

VIRUS H. 100. "R.S."

LUPUS.

Original material—A large piece of skin containing lupus nodules removed by operation.

HISTORY OF PATIENT AND DESCRIPTION OF MATERIAL RECEIVED AT BLYTHWOOD.

The patient was a woman aged 37 years, who was admitted to hospital six years ago, in December 1902.

The disease started 17 years ago as a small spot on the upper lip under the nose, which was scraped;

about one year later it appeared on the right side of the nose, and then spread to the face. There is now (February, 1908) extensive lupus of the face, front of neck, and right arm, and the patient has lost a finger. The lesions have been scraped 39 times in all, the last scraping having been made two years ago. Twelve years ago the patient was treated with injections of tuberculin for 11 weeks, but it upset her health.

The general health of the patient has been good.

The father died 10 years ago from phthisis; there was no other family history of tuberculosis. Five brothers and one sister were alive and well.

On February 6, 1908, a large piece of skin containing lupus nodules was removed by operation from the right arm.

It was sent to Blythwood, emulsified, and inoculated into three guinea-pigs. Microscopical examination of the emulsion failed to show tubercle bacilli.

Present condition.—The patient was seen on July 6, 1908. She stated that she was in perfect health except for the lupus. There was no cough, and there were no physical signs of tuberculosis.

CULTURES.

Cultures were obtained from two of the guinea-pigs inoculated with the original material; from each guinea-pig two cultures were isolated.

All the strains have exhibited identical cultural characters.

On serum growth even after long subculture was thin grey and uniform, and when scraped together with a platinum spatula, moist and easy to emulsify.

Growth on glycerin-serum was two or three times as thick as on serum, greyish-white not uniform in thickness and occasionally finely wrinkled.

On glycerin-agar a thin patchy grey haze or ground-glass layer was produced in two or three weeks; in the majority of tubes sown this was the only development, but in some towards the end of the third week minute colonies were observed with a hand lens on the inoculated surface; these slowly increased in size and fresh crops appeared, so that at the end of two or three months the surface of the agar was studded with raised colonies varying in size up to perhaps 1·5 mm. in diameter; these were raised rounded whitish and shiny, and many had a central umbilication; there were also some flat grey filmy colonies.

The results on potato were similar to those on agar; there was to begin with a thin grey layer in which subsequently, *i.e.*, in about the fourth week, colonies began to grow; in one case these colonies were so numerous that the initial thin grey layer was converted into a slightly raised greyish-white granular layer; in most of the tubes however the colonies were not so numerous, and at the end of two or three months the potato showed a thin grey layer studded with a varying number of discrete raised whitish colonies; the majority of these colonies were little masses with a nodular outline, but some were cylindrical and stood straight up or were bent over to form in one or two cases perfect hoops.

The surface of broth in a six ounce medicine bottle quickly became covered with a thin grey almost transparent membrane, mottled in some cases with denser whitish patches, which soon became moist and sank.

On a flask of broth containing 200·0 cc. growth at first was very slow, a small opaque nodular patch only being produced after many weeks incubation; then active multiplication set in, the surface was soon covered, and at the end of four months there was a moderately dense greyish-white wrinkled and in places warty membrane, with some thin grey patches at one margin; the whole pellicle subsequently sank.

INOCULATION EXPERIMENTS.

(*a*) With the original material.

Guinea-pigs.—Three guinea-pigs, Nos. 2929, 2930, 2931, were inoculated intraperitoneally with an emulsion made from the original material.

No. 2929 was killed after 33 days, and showed a few small transparent tubercles in the omentum and caseous foci in the pyloric and portal glands; there was no tuberculosis elsewhere.

No. 2931 died in 51 days. The omentum contained scattered translucent tubercles, there was a caseous focus in a coeliac and in a portal gland; a few necrotic foci were present in the liver, and the spleen was slightly enlarged and beset with grey tubercles. There was no tuberculosis elsewhere in the body.

No. 2930 died in 62 days, and showed slight general tuberculosis.

(*b*) With culture.

Calves.—Calf 1419 was inoculated subcutaneously with 50·0 mg. of culture derived from guinea-pig 2929 inoculated with the original material. It was killed when in fairly good condition 122 days later, and showed chronic progressive general tuberculosis.

The tumour at the seat of inoculation was fibro-caseo-calcareous with caseo-pus in a central cavity and infiltrated the subjacent muscles. The adjacent prescapular and prepectoral glands were fibro-caseo-calcareous throughout. The lungs contained a moderate number of fibro-caseo-calcareous or softened nodules up to a pea in size, and about half a dozen larger nodules up to 1·5 cm. in diameter.

The spleen and the left suprarenal each contained one caseous gritty nodule. The liver showed a large prominent nodular mass composed of gritty fibro-caseous substance, surrounded by smaller nodules and tubercles; elsewhere small grey tubercles and a few scattered nodules were seen. Nearly all the lymphatic glands were affected and showed varying degrees of caseation and calcification.

Calves 1547 and 1523 were also inoculated subcutaneously with the culture derived from guinea-pig 2929; the former received 100·0 mg., the latter 50·0 mg.

Calf 1547 was killed when well after 95 days and showed slight generalised tuberculosis; Calf 1523 died of general tuberculosis in 73 days.

Calf 1409 was inoculated subcutaneously with 100·0 mg. of culture derived from guinea-pig 2931, inoculated with the original material. It was killed after 119 days, and showed a collapsed cyst at the seat of inoculation, and caseo-calcareous tracts and discrete nodules and tubercles in the adjacent prescapular gland. The lungs contained moderately numerous irregular translucent grey nodules from 1 to 4 mm. in diameter, homogeneous throughout (a smear preparation showed T.B.). Two thoracic glands contained each a few calcareous foci and small caseo-calcareous nodules; the others contained one or two calcareous grains. There was a caseous tubercle in a portal gland, another in a mesenteric gland; a second mesenteric gland contained an irregular caseo-calcareous nodule.

Rhesus Monkeys.—Monkey 163 was inoculated subcutaneously with 1·0 mg. of culture derived from guinea-pig 2929. It died 86 days later, and showed general tuberculosis, not severe.

There was a fibrous-walled cyst containing caseo-pus at the seat of inoculation, and several of the adjacent glands were slightly enlarged caseous and softened. The lungs contained fairly numerous grey tubercles, the larger with opaque centres. The omentum showed half a dozen caseous tubercles, the spleen a moderate number of softened caseous nodules, the liver three caseous tubercles, the kidneys over a dozen small tubercles each. The thoracic and the portal glands contained caseous tubercles, and one gastric gland a caseous focus.

Monkey 207 was inoculated subcutaneously with 1·0 mg. of culture derived from guinea-pig 2931. It died in 26 days.

There was a collection of caseo-pus at the seat of inoculation, and several of the adjacent glands were enlarged caseous and softened. One bronchial gland contained a caseous tubercle, and there was a similar tubercle in the spleen. Other organs and glands were normal. Death was the result of cold.

Monkeys 255 and 257 were subsequently inoculated subcutaneously each with 1·0 mg. of culture derived from guinea-pig 2931.

Monkey 257 was killed after 25 days on account of the development of a gangrenous condition of the upper lip and gum. There was a caseous and softened tumour at the seat of inoculation and no tuberculosis elsewhere.

Monkey 255 died in 48 days and showed slight disseminated tuberculosis; the cause of death was not apparent.

Pigs.—Two pigs, Nos. 133 and 135, each 16 weeks old, were fed every other day for a fortnight—seven

times in all—with the culture derived from guinea-pig 2931. They received the growth from two serum cultures between them on each occasion.

Pig 133 was killed after 114 days and showed slight disseminated tuberculosis. The submaxillary, mesenteric (much enlarged) and ileo-colic glands were all occupied to a greater or less extent by caseo-calcareous tissue. The liver contained scattered grey tubercles with minute calcareous centres; seven were seen in the lungs. The portal coeliac and one colic glands contained one or more caseo-calcareous tubercles. The intestines and other organs were normal.

Pig 135 was killed after 146 days; the submaxillary and most of the mesenteric glands contained caseous gritty nodules which shelled out of normal-looking gland tissue: a few small tubercles were seen in three ileo-colic and colic glands; there was a minute calcareous focus in the liver.

Rabbits.—A series of five rabbits was inoculated with the culture derived from guinea-pig 2929, three intravenously and two subcutaneously. One intravenous rabbit (dose 0·1 mg.) died in 17 days of acute tuberculosis, another (dose 1·0 mg.) died in 22 days of general miliary tuberculosis; the third (dose 0·01 mg.) died in 174 days of general tuberculosis. The subcutaneous rabbits (doses 10·0 mg. each) died in 163 and 337 days of general tuberculosis.

Two rabbits were subsequently inoculated subcutaneously, each with 10·0 mg. of the same culture. They died of general tuberculosis in 133 and 145 days.

A series of four rabbits was inoculated with the culture derived from guinea-pig 2931, three intravenously and one subcutaneously.

One intravenous rabbit (dose 1·0 mg.) died in 21 days of general miliary tuberculosis; the two others (doses 0·1 and 0·01 mg.) died in 40 and 78 days respectively of general tuberculosis.

The subcutaneous rabbit (dose 10·0 mg.) died in 91 days of general tuberculosis.

Guinea-pigs.—A series of four guinea-pigs was inoculated with the culture derived from Guinea-pig 2929, two intraperitoneally and two subcutaneously.

The intraperitoneal guinea-pigs (doses 1·0 and 0·1 mg.) died of general tuberculosis in 30 and 43 days; one subcutaneous guinea-pig (dose 0·1 mg.) died in 192 days, the other (dose 1·0 mg.) in 284 days, both of general tuberculosis.

Fowls.—Two fowls, Nos. 121 and 119, were inoculated intravenously with the culture derived from guinea-pig 2931; the former received 10·0 mg., the latter 1·0 mg.

Fowl 121 was killed accidentally after two days; the organs and glands were healthy. Fowl 119 was killed after 171 days; the lungs contained scattered tubercles some grey others greyish yellow up to 0·75 mm. in diameter, and the liver showed one minute grey focus. There was no tuberculosis elsewhere.

SUMMARY.

The cultures investigated were obtained from a case of lupus of 17 years standing in a woman aged 37.

The cultural characters of the organism are identical with those of bovine tubercle bacilli which grow with most difficulty on artificial media.

Its virulence however for calves and rabbits is lower than that of the bovine tubercle bacillus, but higher than that of the human tubercle bacillus, *e.g.*, it has produced in a young calf in a dose of 50·0 mg. generalised progressive tuberculosis not fatal within the period of observation, and in rabbits it has caused fatal general tuberculosis by intravenous and subcutaneous inoculation.

For monkeys and guinea-pigs the culture is less virulent than either the human or the bovine tubercle bacillus.

Virulence after passage.

The virus acquired the full virulence of a bovine tubercle bacillus for the calf, rabbit, monkey, and guinea-pig by a single residence in the bodies of each of three calves and a rabbit.

VIRUS H. 101. "E.G."

LUPUS.

Original material—A small piece of skin containing lupus nodules removed by operation.

HISTORY OF PATIENT AND DESCRIPTION OF MATERIAL RECEIVED AT BLYTHWOOD.

The patient was a woman aged 53 years, admitted to hospital (as an out-patient) on March 19, 1906.

The disease commenced at the age of 17 with a spot on the right cheek: it remained quiescent for 8 years and then spread gradually over both cheeks and the nose, becoming worse after confinements.

Four years ago a spot came on the left wrist and patches of lupus subsequently developed on the left arm.

The patient had been previously treated at various hospitals. Her general health had been good.

There was no family history of tuberculosis. The father was living (aged 85 years), the mother had died of bronchitis; seven brothers and five sisters were alive and well.

On February 6, 1908, an operation was performed, a small piece of diseased skin being removed from the left elbow. [The disease had first appeared here 18 months previously.]

The material removed was sent to Blythwood: it was emulsified and two guinea-pigs were inoculated with the emulsion. No tubercle bacilli were seen in a smear preparation made from the emulsion.

Present condition.—The patient was seen on July 6, 1908. She was in good health except for the lupus, and there were no physical signs of tuberculosis in the chest or elsewhere.

CULTURES.

Cultures were obtained from the omentum and pyloric gland of guinea-pig 2932. The culture tubes sown from the omentum and pyloric gland of guinea-pig 2933 remained sterile.

The two strains from guinea-pig 2932 produced on serum pigmented layers of moderate thickness; on glycerin-serum growth was much more abundant, pigmented a deep yellow, finely wrinkled and ridged or warty on the surface.

On agar in two cases a greyish white layer showing fine yellow wrinkles was produced; the condensation water was covered in one case with a thick creamy wrinkled pellicle.

On potato the growths varied; some were moderately thick greyish-white and finely wrinkled, the wrinkles having a creamy colour; another was equal in thickness almost to the best obtained with a Group II organism and was creamy and highly wrinkled.

Growth on broth has not been satisfactory; out of a number of broth bottles sown only one had the surface well covered, the pellicle in this case being thin grey and translucent and broken up.

INOCULATION EXPERIMENTS.

(a) With the original material.

Guinea-pigs.—Two guinea-pigs, Nos. 2932 and 2933, were inoculated intraperitoneally with an emulsion made from the original material.

One (No. 2933) died in 31 days and showed slight tuberculosis of the omentum and the omental gland, the other (No. 2932) died in 49 days and showed tuberculosis of the omentum and the pyloric gland. The cause of death was not apparent in either case.

(b) With culture.

Calf.—Calf 1447 was subcutaneously inoculated with 50·0 mg. of culture derived from guinea-pig 2932 inoculated with the original material.

It was killed after 123 days and showed a small firm tumour composed mainly of thickened skin; the left prescapular gland contained three, and the left prepectoral one, peasized caseous and softened nodules. There was no tuberculosis elsewhere.

Rhesus Monkeys.—Monkey 173 was inoculated subcutaneously with 1·0 mg. of the culture derived from guinea-pig 2932. Subsequently two more monkeys (Nos. 209 and 211) were inoculated each with 1·0 mg. of this culture.

Monkey 173 died in 77 days. There was a small ulcer at the seat of inoculation. Two vertebral and one cervical glands were enlarged, caseous and softened. One small partly caseous axillary gland was adherent to the skin which was ulcerated at this point, another contained a caseous nodule. Half-a-dozen miliary caseous tubercles were seen in the lungs. There was no sign of tuberculosis elsewhere and nothing was found to account for the death of the animal.

Monkey 209 died in 24 days of pneumonia. There was a thin-walled cyst containing caseo-pus at the seat of inoculation, an early caseous focus in each of two axillary glands and one early tubercle in the liver and one in the spleen.

Monkey 211 died in 51 days of severe general tuberculosis.

Rabbits.—Five rabbits were inoculated with the culture derived from guinea-pig 2932, three intravenously and two subcutaneously.

Another rabbit was subsequently inoculated subcutaneously with a large dose of culture from guinea-pig 2932.

One intravenous rabbit (dose 1·0 mg.) died in 24 days of early general tuberculosis. The others (dose 0·1 mg. each) were killed after 144 days; one showed one calcareous tubercle and some indefinite grey foci in the lungs, and a few grey translucent nodules in each kidney; the other showed some minute grey points of doubtful origin in the lungs, and a few yellow foci with grey margins in the kidneys.

One subcutaneous rabbit (dose 10·0 mg.) died prematurely in 27 days and showed a local lesion only; the other (dose 20·0 mg.) was killed after 144 days and showed a thin-walled cyst filled with caseo-pus at the seat of inoculation, calcareous foci in the nearest gland, and a pea-sized fibrous-walled nodule containing cavities filled with muco-pus in the lung (T.B.).

The third subcutaneous rabbit (dose 57·0 mg.) was killed after 160 days and showed a small caseous local lesion and no tuberculosis elsewhere.

Guinea-pigs.—Three guinea-pigs were inoculated with the culture derived from guinea-pig 2932, one intraperitoneally (dose 0·1 mg.), the others subcutaneously (doses 1·0 mg. and 0·1 mg.).

The intraperitoneal guinea-pig died in 35 days of general tuberculosis; one subcutaneous guinea pig died in 119 days of general tuberculosis, the other died in 454 days of chronic general tuberculosis.

SUMMARY.

The culture investigated was obtained from a case of widespread lupus in a woman aged 53.

The culture exhibits the cultural characters of the common human tubercle bacillus and has low virulence for the calf and rabbit. For the monkey and guinea-pig the virulence is lower than that of either the bovine or the human tubercle bacillus.

VIRUS H. 102. "N.H."

LUPUS.

Original material—A large piece of diseased skin removed by operation.

HISTORY OF PATIENT AND DESCRIPTION OF MATERIAL RECEIVED AT BLYTHWOOD.

The patient was a woman aged 33 years, admitted to hospital on January 15, 1908.

The disease was of 15 years' duration and had now spread all over the face, part of the nose having gone; there were also two patches on the left arm. The patient had been scraped many times at various institutions and had had X-ray treatment.

Her mother had "consumptive bowels"; there was no other family history of tuberculosis. The father died of pleurisy and heart disease at 73; two sisters and one brother were alive and well; seven died in infancy.

The general health of the patient had always been good.

On February 6, 1908, an operation was performed, a large piece of diseased skin being removed from the left arm. This was sent to Blythwood, and was emulsified and inoculated into three guinea-pigs. Microscopical examination of the emulsion failed to show tubercle bacilli.

Present condition.—On July 6, 1908, the patient was seen; she stated that she was in perfect health except for the lupus; she had no cough, and there were no physical signs in the chest.

CULTURES.

A culture was obtained from one of the guinea-pigs, No. 2934, inoculated with the original material.

It produced on serum uniform dry greyish-white layers which when scraped together with a platinum spatula exhibited a faint yellow pigment.

On glycerin-serum growth was more abundant than on serum, dry wrinkled and cream coloured.

On agar an abundant highly-wrinkled creamy continuous layer was formed.

On potato moderately thick greyish-white finely wrinkled layers with a creamy tinge were produced.

The surface of broth became covered with a wrinkled membrane, partly opaque dense and yellowish, partly grey and translucent.

INOCULATION EXPERIMENTS.

(a) With the original material.

Guinea-pigs.—Three guinea-pigs, Nos. 2934, 2935, and 2936, were inoculated intraperitoneally with the emulsion made from the original material.

No. 2936 died in 22 days probably from enteritis and showed two translucent grey tubercles in the omentum only.

No. 2934 was killed after 41 days and showed one tubercle in the omentum and a yellow focus in the pyloric gland which was slightly enlarged; there was no tuberculosis elsewhere.

No. 2935 was killed after 382 days, and showed slight chronic general tuberculosis.

(b) With culture.

Calf.—Calf 1423 was inoculated subcutaneously with

43·0 mg. of culture derived from guinea-pig 2934 inoculated with the original material.

It was killed 107 days later, and showed a fibrous-walled cyst containing caseo-pus and watery fluid at the seat of inoculation and a small calcareous patch in the adjacent prescapular gland only.

Rhesus Monkeys.—Three monkeys were inoculated subcutaneously each with 1·0 mg. of the culture derived from guinea-pig 2934.

Monkey 169 died prematurely in 55 days; the cause of death was not apparent. The tumour at the seat of inoculation was composed of breaking-down caseous substance enclosed in a thin fibrous wall; one axillary and one vertebral gland contained caseous tubercles. There was one tubercle in the lung, one in the liver and one in the spleen.

Monkey 213 died of pneumonia in 156 days and showed chronic general tuberculosis. There was an aggregation of softened caseous nodules at the seat of inoculation, and the adjacent glands were much enlarged caseous and softened. The lungs contained scattered caseous and softened nodules with thin fibrous walls and one mass (1 cm.) composed of aggregated nodules. The spleen contained about twenty softened caseous nodules, in the kidneys there were two or three, in the liver about twenty were seen. There was a caseating nodule and a softened caseous area (2·5 cm.) in the brain. Several of the bronchial glands were much enlarged caseous and softened.

Monkey 215 died in 183 days of severe chronic general tuberculosis. There was an ulcerated and caseous lesion at the seat of inoculation, and the adjacent glands were much enlarged, caseous, and softened. The costal pleura was covered with caseating tuberculous plaques, and a small area (5 mm.) of the diaphragm was thickened and entirely caseous. The lungs contained scattered firm caseous nodules. The spleen was enormously enlarged, and composed of large softened caseous nodules; the liver and kidneys contained a moderate number of caseous nodules, and the former showed also scattered miliary tubercles. The bronchial and many of the abdominal glands showed varying degrees of caseation and softening. Two caseous nodules were seen in the muscles.

Pigs.—Two pigs, Nos. 137 and 139, each 16 weeks old, were fed on alternate days for a fortnight—seven times in all—with the culture derived from guinea-pig 2934. They received between them on each occasion the growth from two serum cultures.

Pig 137 was killed after 112 days; there was a small grey tubercle, and an encapsuled nodule containing mortary substance in the liver (smears, no T.B.), and no sign of tuberculosis elsewhere.

Pig 139 was killed after 144 days; two caseo-calcareous tubercles were found in one submaxillary gland; there was no tuberculosis elsewhere.

Rabbits.—Two series of rabbits were inoculated with the culture derived from guinea-pig 2934. In the first series, three animals were inoculated intravenously, and two subcutaneously (with small doses). In the second series two rabbits were inoculated subcutaneously (with large doses).

The three intravenous rabbits were each killed after 139 days. One (dose 1·0 mg.) showed a small fibrous wedge and half-a-dozen caseous foci in one kidney and two caseous foci in the other, and no disease elsewhere; another (dose 0·1 mg.) showed one grey tubercle with a calcareous centre in one kidney only; the third (dose 0·01 mg.) showed no sign of tuberculosis.

One subcutaneous rabbit (dose 1·0 mg.) died prematurely in 15 days and showed a small local lesion only; another (dose 1·0 mg.) was killed after 139 days and showed a small thin-walled cyst filled with caseo-pus at the seat of inoculation only.

One of the subcutaneous rabbits of the second series died in 10 days of an acute infection; the other (dose 50·0 mg.) was killed after 160 days and showed a local lesion and one small tubercle in the lung only.

Guinea-pigs—Two series of guinea-pigs were inoculated with the culture derived from guinea-pig 2934. In the first series one animal was inoculated intraperitoneally and two subcutaneously; in the second series two guinea-pigs were inoculated, one subcutaneously and one intraperitoneally, with large doses.

The intraperitoneal guinea-pig of the first series (dose 0·1 mg.) died in 47 days. The omentum contained scattered tubercles, the peritoneum was normal, there were two tubercles on the meso-colon. The spleen was enlarged and showed enlargement of the Malpighian bodies and exceedingly numerous indefinite grey points; the liver showed fairly numerous minute grey foci. Other organs and the glands appeared normal.

The subcutaneous guinea-pigs of the 1st series (doses 1·0 and 0·1 mg.) died in 504 and 462 days respectively of chronic general tuberculosis.

The intraperitoneal guinea-pig of the second series (dose 10·0 mg.) died in 45 days of general tuberculosis, the subcutaneous in 145 days of chronic general tuberculosis.

Parrot.—Parrot 15 was cutaneously inoculated with the culture derived from guinea-pig 2934. The skin behind the right ear was scarified with a knife dipped in a turbid suspension of culture. It was killed 522 days later and showed general tuberculosis. There was no local lesion.

SUMMARY.

The culture investigated was obtained from a case of lupus of the face and left arm in a woman aged 33 years. The culture exhibits the cultural characters of the common human tubercle bacillus and has low virulence for the calf and rabbit. For the monkey and guinea-pig the virulence is much lower than that of the human tubercle bacillus. This culture is the least virulent of all the lupus cultures.

Virulence after passage.

The virus was not increased in virulence by residence in the body of a monkey.

VIRUS H. 103. "N.S."

LUPUS.

Original material—A large piece of diseased skin removed by operation.

HISTORY OF PATIENT AND DESCRIPTION OF MATERIAL RECEIVED AT BLYTHWOOD.

The patient was a woman aged 28 years admitted to hospital on February 6, 1908.

The disease was of 24 years' duration. There were tuberculous ulcers on the right foot with lymphatic obstruction, and many scattered lupoid nodules about the right leg below the knee.

Family history.—The patient's father died of consumption; two of her mother's uncles died of consumption; one paternal uncle died of consumption. One sister is stated to have died of "consumption" when 15 months old. One step-brother was now attending Brompton Hospital and another was stated to have died of consumption.

General health of the patient.—The patient had never been strong and had suffered from tuberculous

osteitis ; as a child she attended a hospital for abscesses in the right thigh and the right side of the rectum.

Operation.—On February 6, 1908, an operation was performed, a large piece of skin containing lupus nodules being excised from the outer side of the leg just below the knee.

The diseased skin was sent to Blythwood : a portion of it was emulsified and inoculated into two guinea-pigs, the rest was very tough and leathery and could not be emulsified ; it was inserted in a pocket under the skin of a guinea-pig. The emulsion was examined microscopically ; no tubercle bacilli were seen in it.

Present condition of patient, September 5, 1908.—The patient is a thin delicate-looking woman. The wound left by the operation is quite healed ; other wounds over the ankle are still open. No cervical glands can be felt. There is dulness over the right apex of the lung with increased vocal resonance, and the patient has occasional cough and night sweats.

CULTURES.

Cultures were obtained from two of the guinea-pigs inoculated with the original material ; a direct culture failed.

The two strains showed identical characters on the differential media.

On serum they produced thick pigmented layers ; on glycerin-serum growth was better than on serum.

On glycerin-agar a creamy warty layer, irregularly heaped up and in places wrinkled, was produced.

On potato growth was thick heaped up wrinkled and warty and of a creamy-yellow colour deepening with age.

The surface of broth became covered with a uniform moderately thick greyish-white wrinkled membrane, the raised wrinkled parts having a yellowish colour.

Growth on glycerin-gelatine was similar in type to that on broth.

INOCULATION EXPERIMENTS.

(*a*) With the original material.

Guinea-pigs.—Two guinea-pigs, Nos. 2938 and 2940, were inoculated intraperitoneally with an emulsion made from the original material. The former was killed after 33 days and showed a few transparent tubercles in the omentum only ; the latter was killed after 45 days and showed early tuberculosis confined to the abdomen.

A small piece of the diseased skin was inserted in a pocket under the skin of the abdomen of a guinea-pig, No. 2937. It died in 49 days. There was a small ulcer in the skin of the abdomen through which the piece of skin probably escaped ; the adjacent glands were normal, and there was no sign of tuberculosis in the abdomen or thorax. The cause of death was not apparent.

(*b*) With culture.

Calf.—Calf 1457 was inoculated subcutaneously with 88·0 mg. of culture derived from the original material through guinea-pig 2940. It was killed after 107 days ; there was a small tumour at the seat of inoculation composed of thickened skin and a subcutaneous mass of fibroid tissue in which there was a very small cavity containing caseo-pus ; a funnel-shaped depression in the skin communicated with the cavity. There was no tuberculosis elsewhere.

Rhesus Monkeys.—Monkeys 171 and 217 were inoculated subcutaneously each with 1·0 mg. of culture derived from the original material through guinea-pig 2938.

Monkey 171 died in 111 days of general tuberculosis. There was a shallow ulcer at the seat of inoculation and the majority of the left cervical and axillary glands were greatly enlarged and caseo-purulent ; the left vertebral glands formed a lobulated thin walled tumour 4 cm. in length projecting into the thorax, filled with caseo-pus. The left lung was enlarged firm dark red and airless and caseating almost throughout, the right was crepitant and contained scattered shotty tubercles. In the spleen there was a moderate number of softened caseous nodules, in the liver three tubercles, in the kidneys a moderate number of miliary grey tubercles with caseous centres. Most of the lymphatic glands contained caseous tubercles or nodules.

Monkey 217 died in 102 days and showed slight generalised tuberculosis ; death was probably due to cold. There was an ulcer with caseo-necrotic floor at the seat of inoculation and the adjacent glands were moderately enlarged caseous and softened ; 4 glands in the thorax and a pancreatic gland were similarly affected. The spleen contained scattered grey miliary tubercles and about half-a-dozen caseous tubercles were seen in each kidney. The mesenteric glands contained scattered caseous tubercles. T.B. were seen in a smear from the mucous membrane of the small intestine.

Rabbits.—Two rabbits were inoculated intravenously each with 1·0 mg. of culture derived from the original material through guinea-pig 2940.

One died from injuries in 13 days ; the lungs were crepitant and contained fairly numerous minute glassy tubercles ; there was no tuberculosis elsewhere. The other was killed after 160 days. The lungs contained scattered grey miliary tubercles with minute opaque centres, the kidneys a moderate number of small caseous tubercles and a few caseous streaks.

A series of four rabbits (two intravenous and two subcutaneous) was inoculated with the culture derived from the original material through guinea-pig 2938.

One intravenous rabbit (dose 1·0 mg.) died in 22 days of general tuberculosis. The lungs were composed practically throughout of reddish grey solid tissue containing scattered caseous foci. The liver, spleen, and kidneys were speckled with small grey tubercles or foci ; the bronchial glands were enlarged and contained small caseous patches.

The other (dose 0·1 mg.) was killed after 138 days. There were a few small tubercles and a caseous nodule in the lungs and about a dozen grey nodules with slight caseation in the kidneys ; each mammary gland was a little enlarged and contained in the ducts thick caseo-purulent substance.

The two subcutaneous rabbits (doses 31·0 and 10·0 mg.) were killed after 138 days and showed each a thin walled cyst with caseo-purulent contents at the seat of inoculation and no tuberculosis elsewhere.

Guinea-pigs.—Two guinea-pigs were inoculated, one intraperitoneally, the other subcutaneously, with the culture derived from the original material through guinea-pig 2940. Each received 1·0 mg. They died of general tuberculosis in 46 and 129 days respectively.

Four guinea-pigs were inoculated with the culture derived from the original material through guinea-pig 2938, one intraperitoneally and three subcutaneously.

The intraperitoneal guinea-pig (dose 1·0 mg.) died in 142 days and showed very slight general tuberculosis insufficient to account for death. One subcutaneous animal (dose 10·0 mg.) died in 106 days of general tuberculosis, another (dose 1·0 mg.) in 134 days of general tuberculosis ; the third (dose 1·0 mg.) in 193 days of general tuberculosis.

SUMMARY.

Cultures were obtained through the guinea-pig from lupus nodules excised from the leg of a woman aged 28 years.

The cultures grow luxuriantly on artificial media ; they have low virulence for the calf and rabbit, and lower virulence for the guinea-pig and the rhesus monkey than the human tubercle bacillus.

VIRUS H. 105. "G.S."

LUPUS.

Original material—Lupus nodules removed by operation.

HISTORY OF PATIENT AND DESCRIPTION OF MATERIAL RECEIVED AT BLYTHWOOD.

The patient, a girl aged 15 years, was admitted to hospital on February 14, 1908.

The disease was of 12 months' duration, and had not been previously treated: it commenced as pimples on the nose and then spread to the right cheek: it was now confined to the nose, upper lip, right cheek, and palate.

Previous history.—The girl had had measles, whooping-cough, &c., but in other respects had always been well.

Family history.—There was a history of tuberculosis on the mother's side, the patient's maternal uncle and an aunt having died of consumption. The mother herself, aged 49, was well; nothing was known concerning the father. The patient's brother and three sisters were healthy.

Operation.—On February 14 an operation was performed, nodules being excised from the tip of the nose and the right cheek.

The tissue removed was sent to Blythwood: it was emulsified and inoculated into two guinea-pigs. Microscopical examination of the emulsion failed to show any tubercle bacilli.

Present condition, July 23, 1908.—The face is certainly better; the girl is in good health and feels strong and well. There is no cough and there are no enlarged glands or other physical signs of tuberculosis.

CULTURES.

Cultures were obtained from the omentum, pyloric gland and sternal gland of guinea-pig 2950; the colonies produced on all the egg tubes were numerous, and even after two months incubation were filmy transparent and clearly visible only by reflected light.

Subcultures on serum were thin grey and uniform; on glycerin serum no growth was visible during the first 10 days or so, towards the end of the second week discrete colonies began to appear, and at the end of a month the surface was covered with grey colonies confluent in places but mainly discrete.

On glycerin-agar no growth has been obtained.

On potato a thin uniform grey layer was first formed; in this in the third week whitish points became visible; these grew slowly, and at the end of two and a-half to three months the thin grey layer was studded with colonies ranging up to a pin's head in size; the larger colonies had a creamy tinge, the smaller ones were greyish-white.

Growth on broth was poor and consisted in one case of a few thin grey translucent or greyish-white islands, many of which finally sank, and in another of a thin translucent grey membrane showing greyish-white streaks and patches, which after three months incubation covered only about a quarter of the surface.

INOCULATION EXPERIMENTS.

(*a*) With original material.

Guinea-pigs.—Two guinea-pigs, Nos. 2950 and 2951, were inoculated intraperitoneally with an emulsion made from the original material. No. 2950 was killed after 36 days and showed early general tuberculosis: No. 2951 died in 247 days of chronic general tuberculosis.

(*b*) With culture.

Calves.—Calf 1449 was inoculated subcutaneously with 48·0 mg., and Calf 1405 subcutaneously with 92·0 mg., of culture derived from guinea-pig 2950 inoculated with the original material.

Calf 1449 was killed when in good health after 130 days, and showed slight general tuberculosis.

At the seat of inoculation there was a cyst filled with caseous masses and watery fluid; the left prescapular gland was three parts caseous and softened; other glands in the neighbourhood contained caseous nodules. The lungs showed very sparsely scattered minute tubercles and two larger ones, one caseous, the other calcareous. There were six calcareous tubercles in the spleen and one in the liver, and three fibro-calcareo-caseous nodules on the omentum. Numerous soft yellow foci were seen in the intestines. All the lymphatic glands in the body contained caseous or calcareous nodules usually numerous and occasionally confluent.

Calf 1405 was killed when in good health after 101 days, and showed general tuberculosis not apparently progressive. There was a dense caseous mass surrounded by fibroid tissue at the seat of inoculation, and the adjacent glands were caseous and slightly calcareous. The lungs contained fairly numerous fibro-calcareous tubercles; the thoracic glands were much enlarged and calcareo-caseous. The spleen was very large and packed with caseo-calcareous nodules; the liver and kidneys contained scattered tubercles; the suprarenal bodies showed each half-a-dozen caseo-calcareous nodules. There were two grey tubercles in the heart, caseous tubercles in the pharynx, calcareous tubercles in the tonsils, and several raised pink areas some ulcerated in the trachea. The intestines contained numerous small ulcers and half-a-dozen caseous tubercles. All the lymphatic and haemo lymph glands in the body except those already mentioned contained calcareous tubercles more or less numerous.

Rhesus Monkeys.—Three monkeys were inoculated subcutaneously with the culture derived from guinea-pig 2950.

Monkeys 175 and 205, dose 1·0 mg. each, died of general tuberculosis in 47 and 56 days respectively.

Monkey 203, dose 0·1 mg., was killed accidentally after 17 days and showed local tuberculosis only.

Rabbits.—Two series of rabbits were inoculated with the culture derived from guinea-pig 2950. In the first series three rabbits were inoculated intravenously and two subcutaneously; in the second series two rabbits were inoculated subcutaneously.

One intravenous rabbit (dose 0·1 mg.) died in 31 days, another (dose 1·0 mg.) in 40 days, and the third (dose 0·01 mg.) in 41 days; all of general miliary tuberculosis.

The two subcutaneous rabbits of the first series were killed after 152 days and showed progressive general tuberculosis; in one (dose 10·0 mg.) there was a very large cyst filled with caseo-pus at the seat of inoculation; the lungs were crepitant and contained scattered tubercles, caseous nodules, and caseating patches; the liver showed two tubercles, and the kidneys moderately numerous grey nodules the majority with caseous centres. In the other (dose 1·0 mg.) there was a thin-walled cyst filled with caseo-pus at the seat of inoculation; the lungs did not collapse and were filled with caseous nodules irregular in outline and in many cases confluent, and the kidneys showed in the cortices a moderate number of small grey nodules and three very large fibro-caseous projecting nodules.

One subcutaneous rabbit of the second series (dose 10·0 mg.) died in 162 days (probably from nasal obstruction) and showed generalised progressive tuberculosis; the other (dose 10·0 mg.) died in 111 days and showed slight general tuberculosis insufficient to account for death.

Guinea-pigs.—Three guinea-pigs were inoculated with the culture derived from guinea-pig 2950, one intraperitoneally (dose 0·1 mg.), the others subcutaneously (doses 1·0 mg. and 0·1 mg.).

The intraperitoneal guinea-pig died of general tuberculosis in 31 days. The subcutaneous guinea-pigs died in 188 and 138 days of general tuberculosis.

SUMMARY.

The culture investigated was obtained from a case of lupus of the face in a girl aged 15 years.

The cultural characters of the organism are identical with those of bovine tubercle bacilli which grow with most difficulty on artificial media.

Its virulence however for calves and rabbits is lower than that of the bovine tubercle bacillus, but higher than that of the human tubercle bacillus, *e.g.* it has produced in a calf, in a dose of 92·0 mg. subcutaneously, severe generalised tuberculosis not fatal within the period of observation, and in rabbits it has caused generalised progressive tuberculosis, fatal after intravenous inoculation, not fatal within the period of observation after subcutaneous inoculation.

For monkeys the culture is slightly less virulent, and for guinea-pigs much less virulent, than either the human or the bovine tubercle bacillus.

Virulence after passage.

The virus was not increased in virulence for the calf by passage through two series each of three calves. Cultures from a fourth calf in each series were more virulent for the rabbit than the original culture (the calf not tested).

VIRUS H. 106. "K.R."

LUPUS.

Original material—A piece of skin containing lupus nodules removed by operation.

HISTORY OF PATIENT AND DESCRIPTION OF MATERIAL RECEIVED AT BLYTHWOOD.

The patient was a woman aged about 27 years (not sure of her age), admitted to hospital on February 14, 1908.

The disease started about 20 years previously, a spot appearing on the nose, followed by another under the lower lip. The lupus now extended all over the face, neck, and right ear, and on the right arm there were patches from the neck to the elbow, chiefly on the outer side. The disease appeared on the arm after a burn, which the patient states "never really healed."

The lesions had been scraped 14 times in all previous to the present operation.

General Health.—The general health of the patient had always been good.

Family History. — The mother died young of phthisis, the father was dead, cause unknown. There was no other history of tuberculosis.

On February 14 an operation was performed, lupus nodules being excised from the right elbow.

The material removed (a piece of skin containing lupus nodules) was sent to Blythwood. An emulsion was made from it and examined microscopically ; no tubercle bacilli were found.

Two guinea-pigs were inoculated with the emulsion.

Present condition, September 5, 1908.—The patient states that she is in very good health ; she has no cough and looks well ; some enlarged glands can be felt on the right side of the neck ; there are no physical signs in the lungs.

CULTURES.

A culture was obtained direct from the original material, three colonies appearing on an egg tube ; each of these colonies was separately subcultivated and tested on the differential media.

Cultures were also obtained from two of the guinea-pigs inoculated with the original material.

All the strains exhibited identical cultural characters.

On serum they grew well with the formation of an orange-yellow pigment ; on glycerin-serum growth was more luxuriant and as on serum deeply pigmented.

On glycerin-agar a thick creamy-yellow wrinkled continuous layer was formed.

On potato growth was abundant raised wrinkled or warty and pigmented.

On broth a moderately thick uniformly wrinkled greyish-white membrane with a few yellow patches was produced.

Growth on glycerin-gelatine was similar in type to that on broth.

INOCULATION EXPERIMENTS.

(*a*) With the original material.

Guinea-pigs.—Two guinea-pigs, Nos. 2952 and 2953, were inoculated intraperitoneally with an emulsion made from the original material. The former was killed after 36 days, and showed very slight early tuberculosis ; the latter died in 49 days of early general tuberculosis.

(*b*) With culture.

Calf.—Calf 1403 was inoculated subcutaneously with 50·0 mg. of culture derived from one of the guinea-pigs, No. 2952, inoculated with the original material. It was killed 112 days later, and showed no tuberculosis ; there was a small tumour at the seat of inoculation composed of thickened skin and a small subcutaneous mass of fibroid tissue showing no caseation or calcification, and all the organs and glands were normal.

Rhesus Monkeys.—Two monkeys were inoculated subcutaneously with the culture derived from guinea-pig 2952 ; No. 155 received 1·0 mg. and No. 157 0·01 mg.

The latter died in 4 days and showed no tuberculosis ; the cause of death was not apparent.

The former died in 40 days and showed early general tuberculosis insufficient to account for death, which was brought about probably by cold. There was a prominent infiltrating caseo-necrotic tumour at the seat of inoculation and the adjacent axillary cervical and vertebral glands were enlarged, caseous and softened. The lungs contained sparsely scattered small translucent grey tubercles, the spleen a moderate number of small grey tubercles, the liver a few minute tubercles on the surface, and each kidney two grey tubercles. Other organs and glands were normal with the exception of the portal gland which showed two greyish foci.

Rabbits.—A series of five rabbits was inoculated with the culture derived from guinea-pig 2952, three intravenously and two subcutaneously.

One intravenous rabbit died in two days ; the cause of death was not determined.

Another (dose 0·1 mg.) died in 22 days ; the lungs were crepitant and contained fairly numerous glassy grey miliary tubercles ; the liver showed sparsely scattered greyish-white foci, the kidneys scattered grey submiliary tubercles, and the spleen was a little enlarged soft and red.

The third intravenous rabbit (dose 1·0 mg.) was killed after 160 days. Both kidneys showed depressed scars on the surface, and one a grey tubercle. In the medulla of each there were a few soft yellow foci and greyish tubercles. There was no tuberculosis elsewhere.

The two subcutaneous rabbits (doses 50·0 mg. and 20·0 mg.) showed each a large cyst filled with caseo-pus at the seat of inoculation, and no tuberculosis elsewhere.

A series of rabbits was inoculated (two intravenously and one subcutaneously) with the culture obtained directly from the original material. All were killed when well after 143 days.

One intravenous rabbit (dose 0·1 mg.) showed three or four grey nodules with caseous centres in the kidneys only, the other (dose 0·01 mg.) one small fibro-caseo-calcareous nodule in the lung only; the subcutaneous rabbit (dose 50·0 mg.) showed a group of thin-walled cysts with caseo-purulent contents at the seat of inoculation and no tuberculosis elsewhere.

Guinea-pigs.—Three guinea-pigs were inoculated with the culture derived from guinea-pig 2952, one intraperitoneally and two subcutaneously.

The intraperitoneal animal (dose 1·0 mg.) died in 45 days and showed general tuberculosis, not severe.

One subcutaneous guinea-pig (dose 0·1 mg.) died in 218 days and showed at the seat of inoculation a healed ulcer and a small collection of caseo-pus in the subcutaneous tissues adjacent; the nearest glands were moderately large and filled with caseo-pus. There was no tuberculosis elsewhere and the cause of death was not apparent.

The other (dose 1·0 mg.) died in 574 days of chronic general tuberculosis.

Fowls.—Two fowls were inoculated intravenously with the culture derived directly from the original material; No. 105 received 50·0 mg. and No. 103 10·0 mg.

Fowl 103 died in 45 days, apparently from some secondary infection, and showed only half-a-dozen translucent grey tubercles in the lung; T.B. were seen in smears from the spleen. Fowl 105 was killed after 129 days and showed no tuberculous lesions; numerous colonies however appeared on two egg tubes sown with an emulsion of the spleen.

Rat.—Rat 61 was inoculated intraperitoneally with 55·0 mg. of culture derived directly from the original material. It died in 141 days; the omentum was thickened and contained fibro-caseous nodules and there were a few tubercles with yellow centres on the peritoneum. There were no visible lesions elsewhere, but tubercle bacilli were numerous all over the body.

SUMMARY.

Cultures were obtained direct and through the guinea-pig from lupus nodules excised from the right elbow of a woman aged 27 years.

The cultures grow luxuriantly on artificial media and have low virulence for the calf and rabbit. For the monkey and guinea-pig the virulence is lower than that of the human tubercle bacillus.

VIRUS H. 107. "H.H."

LUPUS.

Original material—A piece of skin showing a large lupus nodule removed by operation.

HISTORY OF PATIENT AND DESCRIPTION OF MATERIAL RECEIVED AT BLYTHWOOD.

The patient was a youth aged 17 years, admitted to hospital on January 29, 1903.

The disease commenced eight years previous to admission (in 1903) as a small spot on the left cheek in front of the ear, and spread gradually to the neck and face and then to both arms and elbows; the face is now (1908) very severely affected.

The patient had been treated at another institution in 1897.

The general health of the patient had always been good.

There was no family history of tuberculosis. The mother died of cancer. The father was dead (cause unknown); two brothers and four sisters were alive and well.

An operation was performed on February 14, 1908, a piece of skin containing a large ulcerated nodule being removed from the right elbow.

The material removed was sent to Blythwood, and was made into an emulsion; three guinea-pigs were inoculated with the emulsion; no tubercle bacilli could be found in a smear preparation made from it.

Present condition, July 24, 1908.—The patient is a small ill-developed lad; he feels strong and well and up to his work; there are no physical signs in the chest and no enlarged glands.

CULTURES.

Cultures were obtained from the spleen, portal gland, and a sternal gland of a guinea-pig, No. 2955, inoculated with the original material; the colonies on the primary (egg) tubes were very numerous, filmy, transparent, with a slightly raised rounded centre and ranged up to about 1 mm. in diameter.

On the test media the three strains were identical.

They produced on serum thin grey uniform layers, on glycerin-serum rather thicker greyish-white layers.

On glycerin-agar growth after five to six weeks incubation was thin dry grey and somewhat patchy and showed slightly raised ribbed ridges where the culture had been most thickly planted; then colonies began to appear and at the end of ten weeks the initial grey layer was closely studded with raised whitish colonies up to a small pin's head in size.

On potato a thin uniform grey layer was first produced and this subsequently became studded with raised colonies ranging in size up to a small pin's head, the majority whitish, some with a creamy tinge.

The surface of broth in one case became covered with a thin uniform translucent membrane resembling thin tissue paper, speckled with whitish foci; in another case only half the surface was covered with a thin translucent membrane mottled with slightly denser greyish-white areas; in other cases a few filmy grey islands only were produced.

INOCULATION EXPERIMENTS.

(*a*) With the original material.

Guinea-pigs.—Three guinea-pigs, Nos. 2954, 2955, 2956, were inoculated intraperitoneally with an emulsion made from the original material.

No. 2954 died in two days of an acute infection; No. 2955 was killed after 38 days and showed very slight tuberculosis; No. 2956 died in 169 days of general tuberculosis.

(*b*) With culture.

Calf.—Calf 1453 was inoculated subcutaneously with 50·0 mg. of culture derived from the original material through guinea-pig 2955. It was killed after 126 days. There was a small fibro caseous lesion at the seat of inoculation; the left prescapular gland was occupied by three fibrous-walled cysts containing caseo-pus. In the lungs there were four pea-sized caseo-purulent nodules and four fibro-calcareous tubercles, in the omentum one caseo-purulent nodule,

in the liver three pea-sized fibro caseo-calcareous nodules, and in the spleen seven similar but smaller nodules.

Calf 1497 was inoculated subcutaneously with 80·0 mg. of the culture derived from guinea-pig 2955.

It was killed after 104 days. There was a collapsed cyst at the seat of inoculation and the adjacent glands were caseo-calcareous. Small scattered grey tubercles were seen in the heart, there were two tubercles in the lungs and one in a suprarenal; the thoracic glands showed scattered caseo-calcareous tubercles and foci. The small intestine was studded with raised patches in some of which yellow foci were seen and showed also here and there a caseous focus, and each mesenteric gland contained a few caseo-calcareous tubercles. One portal gland contained a few calcareous grains.

Rhesus Monkeys.—Monkey 167 was inoculated subcutaneously with 1·0 mg. of the culture derived from guinea-pig 2955.

It died in 92 days of spontaneous tuberculosis, arising in the alimentary tract; a culture isolated from the mesenteric glands grew luxuriantly on the test media and was quite different from the culture inoculated.

Monkeys 219 and 221 were subsequently inoculated subcutaneously each with 1·0 mg. of the culture derived from guinea-pig 2955. They died, apparently as a result of cold, 20 and 26 days after inoculation, and showed—one a small local lesion only, the other a local lesion and two miliary grey tubercles in the spleen.

Since Monkeys 219 and 221 had died prematurely, a series of three monkeys was inoculated subcutaneously each with 1·0 mg. of the culture derived from guinea-pig 2955.

Monkey 249 died in 13 days and showed a local lesion only; the cause of death was not apparent.

Monkey 247 died in 49 days and showed slight generalised tuberculosis; the cause of death was not apparent.

Monkey 251 died in 50 days and showed general tuberculosis of moderate severity.

There was an ulcer at the seat of inoculation and the adjacent glands were moderately enlarged and showed varying degrees of caseation. The lungs were crepitant and contained fairly numerous tubercles, the larger with caseous centres. The spleen was slightly enlarged and contained moderately numerous small caseous nodules. The liver contained a few opaque tubercles, the kidneys a moderate number. There were a few caseous tubercles and minute grey tubercles on the omentum, mesocolon, and mesentery, and one caseous tubercle in the small intestine. The interbronchial and several abdominal glands contained one or more caseous tubercles.

Rabbits.—A series of six rabbits was inoculated with the culture derived from guinea-pig 2955; four animals were inoculated intravenously, and two subcutaneously.

One intravenous rabbit (dose 1·0 mg.) died of early general tuberculosis in eighteen days; another (dose 0·1 mg.) in 21 days; the two remaining rabbits (doses 0·01 mg. each), died of general tuberculosis in 142 and 149 days.

One subcutaneous rabbit (dose 10·0 mg.) died of injuries in 38 days, and showed early slight general tuberculosis; the other (dose 10·0 mg.) died in 49 days and showed early general tuberculosis; there was a very large ulcerated caseous local lesion and caseous patches in the adjacent glands; the lungs contained sparsely scattered tubercles the larger caseous in the centre, the bronchial glands caseous foci, the kidneys a few caseous tubercles, the spleen a single tubercle.

Two more rabbits were subsequently inoculated subcutaneously each with 10·0 mg. of the culture derived from guinea-pig 2955. One died of injuries in 18 days, and showed local tuberculosis only; the other died of chronic general tuberculosis in 165 days.

Guinea-pigs.—Four guinea-pigs were inoculated with the culture derived from guinea-pig 2955, two intraperitoneally (doses 1·0 and 0·1 mg.) and two subcutaneously (doses 1·0 and 0·1 mg.). The intraperitoneal guinea pigs died of general tuberculosis in 28 and 98 days respectively; one subcutaneous guinea-pig died in 116 days of general tuberculosis, the other died in 171 days and showed general tuberculosis, death being immediately due to pseudo-tuberculosis of the mesenteric glands.

Cats.—Cat 49 was inoculated intraperitoneally with 1·0 mg., and Cat 51 subcutaneously with 1·0 mg. of the culture derived from guinea-pig 2955.

Cat 49 was killed after 262 days; there was a flat mass of tough caseated tissue in the muscles of the abdominal wall, and in the omentum a mass of fatty tissue embedded in which were softened caseo-calcareous nodules up to a hempseed in size; there was no tuberculosis elsewhere.

Cat 51 died in 99 days and showed a small clean-cut local ulcer without caseation or thickening of the surrounding tissues, a pea-sized caseous nodule in the adjacent inguinal gland and small caseous areas in a manubrial gland, and a few miliary grey tubercles and indefinite foci in the lungs. The cause of death was not apparent.

Fowls.—Two fowls were intravenously inoculated each with 10·0 mg. of culture derived from guinea-pig 2955.

No. 143 died in 30 days; there were no visible lesions, but tubercle bacilli were numerous in the organs. No. 141 died in 32 days of acute tuberculosis. The lungs were congested and oedematous, but showed no tubercles; the liver was pale and finely speckled with minute grey points; the spleen showed fairly numerous minute grey foci; there was a pin-head sized yellow concretion (smear, T.B.) in the pelvis of one kidney. Smears from the lung, liver, and spleen showed numerous T.B.; a smear from the kidney substance showed a few T.B.

SUMMARY.

The culture investigated was obtained from a case of widespread lupus in a youth aged 17 years.

On the test media the culture exhibits the cultural characters of a bovine tubercle bacillus resembling those which grow rather better than the most dysgonic.

Its virulence however for calves and rabbits is lower than that of the bovine tubercle bacillus, but higher than that of the human tubercle bacillus; it produced in two calves inoculated subcutaneously with 50·0 mg. and 80·0 mg. generalised tuberculosis not severe and not fatal within the period of observation, and it has produced fatal generalized tuberculosis in rabbits both after intravenous and subcutaneous inoculations, but the duration of life was much longer than after equivalent doses of bovine tubercle bacilli.

The culture is less virulent for the monkey and guinea-pig than the bovine tubercle bacillus.

Virulence after passage.

The virus was not increased in virulence by passage through two series of (three and two) calves.

VIRUS H. 108. "H.R."

LUPUS.

Original material—A piece of skin containing lupus nodules removed by operation.

HISTORY OF PATIENT AND DESCRIPTION OF MATERIAL RECEIVED AT BLYTHWOOD.

The patient was a boy aged 8½ years, admitted to hospital on January 15, 1907.

The disease began on the right cheek five years ago, and gradually spread; it was now (February, 1908) all over the face, right arm, and right buttock.

The general health of the child had always been good.

Family history.—The maternal grandfather died of consumption, and the father is believed to have died from the same cause. A brother and a sister are alive and well. The mother has disappeared.

Operation.—On February 14, 1908, a piece of skin containing lupus nodules was excised from the right arm. This was sent to Blythwood and made into an emulsion, with which two guinea-pigs and a rabbit were inoculated. Microscopical examination of the emulsion showed one doubtful tubercle bacillus and a few other organisms.

Present condition, August 31, 1908.—The boy is fairly well-grown; he has a slight cough; there are no enlarged glands and no physical signs of tuberculosis in the chest or abdomen.

CULTURES.

Cultures were obtained from the pyloric and portal glands of guinea-pig 2957; the colonies on the egg tubes were very numerous, and remained small filmy and almost transparent even after many weeks in the incubator.

On serum the growths were thin uniform and grey, and when scraped together were whitish moist and easily emulsified.

On glycerin-serum the growths were two or three times as thick as on serum, greyish-white and not so uniform, the thicker parts in one case having a creamy tinge.

On glycerin-agar all that was produced in the first few weeks was a thin patchy grey layer; at the end of the third week minute colonies became visible; these increased slowly in size, fresh ones appeared, and at the end of two months the surface was studded with greyish-white raised colonies the largest not 1 mm. in diameter, in places aggregated together to form greyish-white granular patches.

On potato the results were similar to those on agar; a thin uniform grey layer was quickly formed which subsequently underwent little increase in thickness; in this layer, after three to four weeks' incubation, minute whitish colonies appeared; these grew slowly, and at the end of two months the largest was about the size of a small pin's head.

The surface of broth quickly became covered though not completely with thin filmy grey islands many of which sank.

INOCULATION EXPERIMENTS.

(*a*) With original material.

Rabbit.—Rabbit 1732 was inoculated intravenously with an emulsion made from the original material. It died in seven days of septic cellulitis.

Guinea-pigs.—Two guinea-pigs, Nos. 2957 and 2958, were inoculated intraperitoneally with the emulsion made from the original material.

No. 2957 was killed after 38 days and showed early general tuberculosis; No 2958 died in 181 days of general tuberculosis complicated by pseudo-tuberculosis.

(*b*) With culture.

Calves.—Calf 1417 was inoculated subcutaneously with 50·0 mg. and Calf 1421 subcutaneously with 88·0 mg. of culture derived from guinea-pig 2957, inoculated with the original material.

Calf 1417 was killed when in good health after 125 days and showed slight general tuberculosis. The local lesion was a small patch of fibrous tissue surmounted by thickened skin showing a scar. The left prescapular gland was mainly composed of breaking down caseous gritty substance. In the lungs there were a few minute glassy tubercles and a small fibro-caseous nodule, in the spleen seven caseous gritty tubercles and in the liver eight tubercles with minute calcareous centres. Nearly all the lymphatic glands in the body contained caseous and caseo-calcareous tubercles or nodules, some being severely affected.

Calf 1421 was killed after 101 days. There was a small local lesion composed of fibroid tissue and thickened skin and the left prescapular gland was mainly occupied by a caseo-calcareous mass. The thoracic glands contained calcareous foci, discrete and in groups. In the spleen there was a moderate number of small tubercles with calcareo-caseous centres. One or two tubercles were seen in the liver, in the small intestine and in several abdominal glands.

Rhesus Monkey.—Monkey 165 was inoculated subcutaneously with 1·0 mg. of culture derived from guinea-pig 2957. It died in 96 days of general tuberculosis.

The tumour at the seat of inoculation was composed of dense caseous substance surrounded by a zone of fibroid tissue. The adjacent glands were enlarged and to a varying extent caseous and softening. A considerable part of the lung tissue was red and hepatised; the rest was congested. The parenchyma contained fairly numerous small grey tubercles some with minute caseous centres. The spleen showed a moderate number of small caseous and softened nodules, the liver sparsely scattered grey tubercles the majority with caseous centres, the kidneys a moderate number of miliary caseous tubercles and a few grey ones. Many of the lymphatic glands contained one or more caseous tubercles or patches.

Rabbits.—A series of five rabbits was inoculated with the culture derived from guinea-pig 2957, three intravenously and two subcutaneously. Subsequently two more rabbits were inoculated subcutaneously with the culture.

One intravenous rabbit (dose 1·0 mg.) died in 21 days of general tuberculosis; the lungs were very closely beset with small confluent tubercles, the liver and kidneys showed fairly numerous grey foci, the spleen was enlarged and showed enlargement of the Malpighian bodies and just visible grey points. Another intravenous rabbit (dose 0·1 mg.) died in 136 days of general tuberculosis, and the third (dose 0·01 mg.) was killed when ill after 155 days and showed general miliary tuberculosis.

One subcutaneous rabbit (dose 10·0 mg.) died in 90 days of general tuberculosis; there was a large caseous ulcerated local lesion; the lungs were crepitant and contained miliary tubercles not very caseous, the spleen showed a dozen small caseous tubercles, the kidneys numerous firm caseating nodules in the cortex (some projecting from the surface) and caseous tubercles in the medulla; there were caseous tubercles in the lymphatic glands and tubercles in the marrow of the ribs.

Another subcutaneous rabbit (dose 10·0 mg.) was killed when ill after 155 days and showed slight chronic general tuberculosis; there was a small fibro-caseous local lesion; the lungs were crepitant and contained scattered caseous tubercles and nodules and the thin margin of one lobe was caseous; there were a few small tubercles in the bronchial glands and a few caseous tubercles and streaks in the kidneys.

One subcutaneous rabbit of the second series (dose 10·0 mg.) died in 85 days and showed slight general tuberculosis; death was probably due to the local lesion becoming septic. The other died in 159 days and showed local tuberculosis and slight retrogressive tuberculosis of the lungs and kidneys. Death was due to other causes.

Guinea-pigs.—A series of four guinea-pigs was

inoculated with the culture derived from guinea-pig 2957, two intraperitoneally (doses 1·0 mg. and 0·1 mg.) and two subcutaneously (with equivalent doses). The two intraperitoneal guinea-pigs died of general tuberculosis in 34 and 44 days; one subcutaneous guinea-pig died in 82 days, the other in 159 days, both of general tuberculosis.

Fowls.—One fowl (No. 109) was inoculated intravenously with 10·0 mg., another (No. 107) perivenously with 1·0 mg., of culture derived from guinea-pig 2957.

Fowl 109 died in 28 days of early general tuberculosis. The lungs were dark and showed moderately numerous minute greyish-yellow foci, not definite tubercles; the liver was large and soft and showed numerous whitish moss-like foci, the spleen too was large and soft and minute translucent tubercles with opaque centres were seen with a hand-lens. The kidneys were enlarged and showed numerous minute grey points. Tubercle bacilli were numerous in smears from lung, spleen, and liver, none was seen in two smears from the kidney.

Fowl 107 was killed after 126 days. There was a cord-like thickening composed of fibro-necrotic gritty substance along the vein at the seat of inoculation, and no sign of tuberculosis elsewhere.

SUMMARY.

The culture investigated was obtained from a case of widespread lupus in a boy aged 8½ years.

On the test media the culture exhibits the cultural characters of a bovine tubercle bacillus, resembling those which grow rather better than the most dysgonic.

Its virulence, however, for calves and rabbits is lower than that of the bovine tubercle bacillus, but higher than that of the human tubercle bacillus; it produced in two calves inoculated subcutaneously with 50·0 mg. and 88·0 mg. generalised tuberculosis not severe and not fatal within the period of observation, and it has produced fatal generalized tuberculosis in rabbits both after intravenous and subcutaneous inoculation, but the duration of life was much longer than after equivalent doses of bovine tubercle bacilli.

The culture is virulent for monkeys and guinea-pigs, but less virulent than either the human or the bovine tubercle bacillus.

Virulence after passage.

The virus acquired the full virulence of a bovine tubercle bacillus, in one instance by a single residence in a calf and in another not until it had been passed through the body of a second calf.

VIRUS H. 109. "M.W."

LUPUS.

Original material—Lupus nodules removed by operation.

HISTORY OF PATIENT AND DESCRIPTION OF MATERIAL RECEIVED AT BLYTHWOOD.

The patient was a girl aged five years who was admitted to hospital on March 5, 1908.

The lupus was of three years duration: it commenced on the left elbow and had recently spread to the right elbow.

The child had been breast-fed for two years. She had never been strong; had had whooping cough, measles, and some ulceration of the eyes, and suffered from an abscess in the back of the neck 18 months previously.

Family history.—The father and mother and three other children were alive and well; one child died of congestion of the lungs. The father's sister and mother's brother died of consumption.

Operation.—On March 17, 1908, a patch of lupus was removed from the right elbow; it was a fresh growth which had never been treated. The material excised—a piece of skin containing lupus nodules—was sent to Blythwood: it was emulsified and inoculated into three guinea-pigs. No tubercle bacilli were seen in a smear preparation made from the emulsion.

Present condition.—August 14, 1908. The child does not look well and has a cough, but is fairly well-grown. The cervical glands are enlarged; there are no physical signs of tuberculosis in the chest.

CULTURES.

Cultures were obtained from the portal and coeliac glands of guinea-pig 3002.

Early generations on serum were thin grey and uniform; after several subcultures fairly good growths with a slight creamy tinge were obtained; on glycerin-serum growth was more abundant drier and definitely cream-coloured, the layer was irregular in thickness and had a slightly wrinkled surface.

On glycerin-agar in the seventh generation moderately thick greyish-white finely wrinkled layers with a creamy tinge were produced; later on a thick creamy continuous highly wrinkled layer was obtained.

The growths on potato were abundant creamy-yellow raised and wrinkled.

The surface of broth was covered in three weeks with a membrane which was partly dense creamy wrinkled and warty and partly thin and grey.

On gelatine a moderately thick creamy-white warty reticulated membrane was formed which covered in six weeks nearly the whole surface.

INOCULATION EXPERIMENTS.

(*a*) With the original material.

Guinea-pigs.—Three guinea-pigs, Nos. 3002, 3003, 3004, were inoculated intraperitoneally with an emulsion made from the original material.

Guinea-pig 3003 died in 26 days and showed no obvious signs of tuberculosis; the cause of death was not apparent.

Guinea-pig 3004 died in 43 days of a subacute infection and showed no definite tuberculosis.

Guinea-pig 3002 was killed in 36 days and showed early general tuberculosis.

(*b*) With culture.

Calf.—Calf 1437 was inoculated subcutaneously with 47·0 mg. of culture derived from guinea-pig 3002 inoculated with the original material. It was killed after 106 days and showed a fibrous-walled cyst with caseo-purulent contents at the seat of inoculation, scattered caseous foci in the left prescapular gland, and two small nodules one caseous the other calcareous in a cervical gland.

Goat.—Goat 61 was subcutaneously inoculated with 1·0 mg. of culture derived from guinea-pig 3002.

It was killed 197 days later and showed three small caseo-purulent nodules with fibrous walls at the seat of inoculation, and no tuberculosis elsewhere.

Rhesus Monkeys.—Monkeys 187 and 197 were inoculated subcutaneously with 1·0 mg., and Monkey 185 subcutaneously with 0·1 mg., of culture derived from the original material through guinea-pig 3002.

Monkey 187 died three days after inoculation and

showed no tuberculous lesions; the cause of death was not apparent.

Monkey 197 died in 30 days of acute general tuberculosis.

Monkey 185 died in 80 days and showed general tuberculosis of moderate severity—the spleen was enlarged and very closely beset with caseous nodules, there were small scattered tubercles in the lungs and liver (none in the kidneys), and most of the lymphatic glands contained caseous tubercles or nodules.

Rabbits.—A series of six rabbits was inoculated with the culture derived from guinea-pig 3002, four intravenously and two subcutaneously; subsequently two more rabbits were inoculated subcutaneously.

One intravenous rabbit (dose 1·0 mg.) died in 15 days of early general tuberculosis; another (dose 0·01 mg.) died in 18 days of (?) gastritis and showed slight tuberculosis of the lungs and kidneys; a third (dose 0·1 mg.) was killed after 145 days and showed two caseo-calcareous nodules and sparsely scattered grey tubercles in the lungs, two or three tubercles in each kidney and sparsely scattered caseous gritty tubercles in the muscles; the fourth (dose 0·01 mg.) killed after 145 days had one minute tubercle in the lung only.

The two subcutaneous rabbits of the first series (dose 1·0 mg. each) were killed after 145 days and each showed a lesion at the seat of inoculation and no sign of tuberculosis elsewhere.

The two subcutaneous rabbits of the second series (doses 50·0 mg. and 10·0 mg.) were killed after 144 days; the former showed a caseous and softened local lesion, a dozen caseo-fibrous nodules in the lungs, a few tubercles on the mediastinal pleura and two grey tubercles in one kidney; the latter showed a thin-walled cyst with thick caseous contents at the seat of inoculation, and no tuberculosis elsewhere.

Guinea-pigs.—A series of four guinea-pigs was inoculated with the culture derived from guinea pig 3002, two intraperitoneally and two subcutaneously.

The intraperitoneal guinea-pigs (doses 1·0 and 0·1 mg.) died of general tuberculosis in 24 and 53 days respectively; one subcutaneous animal (dose 1·0 mg.) died in 136 days and showed chronic general tuberculosis, not very severe, the other died of general tuberculosis in 176 days.

Fowl.—Fowl 113 was inoculated intravenously with 1·0 mg. of the culture derived from guinea-pig 3002. It was killed 102 days later and showed no sign of tuberculosis.

SUMMARY.

The culture investigated was obtained from a case of lupus of the right and left elbows in a child aged 5 years.

The culture exhibits the cultural characters of the human tubercle bacillus and has low virulence for the calf and rabbit and high virulence for the monkey. For the guinea-pig the virulence is lower than that of the human tubercle bacillus.

VIRUS H. 110. "J.B." (*a*).

LUPUS.

First Investigation.

Original material—Lupus nodules removed by operation.

HISTORY OF PATIENT AND DESCRIPTION OF MATERIAL RECEIVED AT BLYTHWOOD.

The patient, a boy aged 10 years, was admitted to hospital on March 5, 1908, suffering from lupus.

The disease was of four years' duration; it had first appeared on the face, then on the left shoulder, then on the left thigh, last on the body; there were now two patches on the face and many isolated patches on the trunk. The child had never been strong but had had no serious illness. He was breast-fed for 10 months, after that he had cow's milk, which was stated to have been always boiled, then he had ordinary diet and unboiled milk.

The physician in charge of the case stated that he could find in the child no traces of tuberculous disease other than the lupus He had small discrete hard enlarged glands in both posterior triangles of the neck, which were possibly the result of bad teeth.

There was no family history of phthisis; the father and mother were alive and well; four other children are well.

On March 17, 1908, a patch of lupus was excised from the right flank; it was a fresh growth which had appeared one month before the operation.

The material removed—a piece of skin containing lupus nodules—was sent to Blythwood. It was emulsified and inoculated into three guinea-pigs. No tubercle bacilli were seen in a smear made from the emulsion.

CULTURES.

Cultures were obtained from the pyloric and portal glands of guinea-pig 3006 and the omentum of guinea-pig 3007; the colonies produced on the egg tubes were very numerous and very minute and formed an almost uniform layer, which was discernible only by reflected light.

On the differential media the strains from the two guinea-pigs gave identical results.

On serum the growth was thin grey and uniform; on glycerin-serum there was no growth until the third week, when the surface became covered with minute discrete colonies, confluent in places.

No growth has been obtained on agar.

On potato in three weeks a thin greyish-white finely granular layer was produced, which increased a little in thickness on further incubation and showed a thin spreading grey margin; with a hand-lens the granular part of the growth was seen to be composed of closely aggregated colonies.

Growth on broth was very scanty, only a few thin greyish islands being produced.

INOCULATION EXPERIMENTS.

(*a*) With the original material.

Guinea-pigs.—Three guinea-pigs, Nos. 3005, 3006, and 3007, were inoculated intraperitoneally with an emulsion made from the original material. They died of tuberculosis in 94, 35, and 27 days respectively.

(*b*) With culture.

Calves.—One calf, No. 1483, was inoculated subcutaneously with 50·0 mg. of culture derived from guinea-pig 3006, inoculated with the original material. It died of general tuberculosis in 40 days.

A second calf, No. 1491, was inoculated with 50·0 mg. of culture derived from guinea-pig 3007, inoculated with the original material. It died in 17 days of acute general tuberculosis.

Rhesus Monkeys.—Three monkeys Nos. 183, 181, and 179, were inoculated subcutaneously with the culture derived from guinea-pig 3007, the doses being 1·0 mg., 0·1 mg., and 0·01 mg. They died of general tuberculosis in 30, 26, and 53 days respectively.

One monkey, No. 253, was fed with 10·0 mg. of culture derived from guinea-pig 3007. It died of general tuberculosis in 30 days.

Pigs.—Two pigs, Nos. 129 and 131, each 16 weeks old, were fed on alternate days for a fortnight—seven times in all—with the culture derived from guinea-pig 3007. They received between them on each occasion the growth from two serum cultures.

Pig 129 was killed when well after 111 days, and showed slight retrogressive general tuberculosis. Caseous or calcareous tubercles were seen in all the Peyer's patches in the small intestine and there were two small tubercles in the large intestine. The mesenteric glands were greatly enlarged and composed of caseous gritty substance; the other glands of the alimentary tract showed varying degrees of caseation. The lungs contained scattered tubercles, the larger with caseo-calcareous centres, the spleen one calcareous tubercle, the liver a moderate number of grey tubercles with calcareous centres. Two thoracic and most of the remaining abdominal glands showed varying degrees of caseation.

Pig 131 was killed after 145 days and showed slight disseminated tuberculosis. There were half a dozen caseo-calcareous tubercles in each tonsil. Four submaxillary and the mesenteric glands were slightly enlarged and almost entirely replaced by caseo-calcareous patches. One submaxillary, one pharyngeal, the ileo-colic and colic glands, and several other abdominal glands, contained a varying number of discrete calcareo-caseous nodules or tubercles. The lungs contained three grey tubercles, the liver sparsely scattered grey tubercles.

Rabbits.—Two rabbits were inoculated subcutaneously with the culture derived from guinea-pig 3006, in doses of 5·0 and 1·0 mg. They died of general tuberculosis in 41 and 44 days respectively.

Two series of rabbits were inoculated with the culture derived from guinea-pig 3007. In all eight animals were inoculated, four intravenously in doses varying from 0·01 mg up to 1·0 mg. and four subcutaneously in doses varying from 8·0 mg. up to 33·0 mg. All the rabbits died of general tuberculosis, the intravenous animals in from 17 to 32 days, the subcutaneous animals in from 30 to 61 days.

Guinea-pigs.—Four guinea-pigs were inoculated with the culture derived from guinea-pig 3007, two intraperitoneally (doses 1·0 and 0·1 mg.) and two subcutaneously (doses 1·0 and 0·1 mg.). They died of general tuberculosis in from 17 to 69 days.

SUMMARY.

The cultures isolated from two guinea-pigs inoculated with lupus nodules from the right flank of a boy aged 10 years suffering from widespread lupus are identical in every respect with the bacillus of bovine tuberculosis.

They possess the cultural characters of those bovine tubercle bacilli which grow with most difficulty on glycerin media, and are highly virulent for the calf, rabbit, guinea-pig, and monkey.

VIRUS H. 110. "J.B." (*b*).

LUPUS.

Second Investigation.

Second Operation, September 25, 1908.

Original material—Lupus nodules removed by operation.

HISTORY OF PATIENT (*continued from March 17, 1908*) AND DESCRIPTION OF MATERIAL RECEIVED AT BLYTHWOOD.

On August 14, 1908, five months after the previous operation, the boy was examined. He was now well-grown and healthy-looking and was always well except for the lupus; there were very small cervical glands on both sides, and some small inguinal glands in the left groin; there was no cough and there were no physical signs in the chest.

On September 25, 1908, six months after the previous operation, a piece of skin containing lupus nodules was excised from the right thigh. The patch of lupus was of old standing.

The material excised was sent to Blythwood; it was a piece of skin measuring about 2·5 by 2 cm. containing lupus nodules. The whole was emulsified; in a smear preparation from it no tubercle bacilli were seen, but there were some blue-staining organisms; three guinea-pigs and a rabbit were inoculated with the emulsion.

CULTURES.

Cultures were obtained from the original material through guinea-pigs 3289 and 3290.

The cultural characters of the strains were identical with those of the strains isolated from this case (*See* H. 110. J.B. (*a*)) six months previously.

INOCULATION EXPERIMENTS.

(*a*) With the Original Material.

Guinea-pigs.—Three guinea-pigs, Nos. 3288, 3289, and 3290, were inoculated intraperitoneally with an emulsion of the skin. No. 3290 was killed after 23 days and showed early general tuberculosis, Nos. 3289 and 3288 died of general tuberculosis in 44 and 86 days respectively.

Rabbit.—Rabbit 2018 was inoculated intravenously with the same emulsion; it died of general tuberculosis in 89 days.

(*b*) With Culture.

Calf.—Calf 1515 was inoculated subcutaneously with 50·0 mg. of culture derived from the original material through guinea-pig 3290. It was killed when dying of general tuberculosis in 34 days.

Rabbits.—A series of five rabbits was inoculated with the culture derived from the original material through guinea-pig 3290; three animals were inoculated intravenously in doses of 0·01 to 1·0 mg. and two subcutaneously (dose 10·0 mg. each). They all died of general tuberculosis, the former in from 14 to 32 days, the latter in 35 and 49 days.

A series of four rabbits was inoculated with the culture derived from the original material through guinea-pig 3289; the animals were inoculated subcutaneously, two with 50·0 mg. and two with 10·0 mg. They all died of general tuberculosis in from 25 to 36 days.

Guinea-pigs.—Two guinea-pigs were inoculated with the culture derived from the original material through guinea-pig 3290, one intraperitoneally and one subcutaneously, each receiving 0·1 mg. They died of general tuberculosis in 16 and 37 days respectively.

SUMMARY.

The cultures isolated from two guinea-pigs inoculated with lupus nodules from the right thigh of a boy aged 10½ years were identical with the cultures obtained from the same case six months previously; they possess the cultural characters of those bovine tubercle bacilli which grow with most difficulty on glycerin media, and have high virulence for the rabbit; one of the strains has also been shown to possess high virulence for the calf and guinea-pig.

VIRUS H. 111. "S.E."

LUPUS.

Original material—Lupus nodules removed by operation.

HISTORY OF PATIENT AND DESCRIPTION OF MATERIAL RECEIVED AT BLYTHWOOD.

The patient was a youth aged 17 years, admitted to hospital on March 5, 1908.

There were two patches of lupus on the right side of the neck, the upper one appeared ten years ago after measles, the lower one 9 months ago. There was no lupus anywhere else.

The patient's general health was good ; he had never had any serious illness, but was a delicate baby and suffered from rickets. He had been brought up on cow's milk.

Family history.—A maternal uncle died of phthisis ; another maternal uncle died of tubercle in the throat, some cousins on the mother's side also died of tuberculosis.

Operation.—On March 17, 1908, an operation was performed, a piece of skin containing lupus nodules (one ulcerated) being removed from the upper patch on the neck ; it was a portion of fresh growth which had never been treated.

The material excised was sent to Blythwood ; it was made into an emulsion which was inoculated into three guinea-pigs. A smear preparations made from the emulsion showed one (?) tubercle bacillus.

Present condition.—The patient is now (September 4, 1908) a well-grown lad in good health ; there are no physical signs in chest, no enlarged glands, no cough.

CULTURES.

Cultures were obtained from the omentum and a splenic lymphatic gland of guinea-pig 3009 ; the latter strain only has been tested on the differential media.

On serum it produced thin grey uniform layers ; on glycerin-serum growth was moist moderately thick but not uniform, the thicker parts having a creamy tinge.

On agar on one tube a patchy greyish ground-glass layer the thicker parts of which were slightly wrinkled was quickly produced ; the growth attained its maximum in about three weeks and then became moist. On another tube a similar but rather thinner layer was formed ; in this layer in the second month discrete colonies began to appear ; at the end of the third month the surface was studded with minute greyish-white colonies.

On potato at the end of a month on each of two tubes there was a greyish-white not very thick layer which with a hand lens was seen to be composed of closely aggregated colonies ; in one case the margins of the growth became slightly heaped up and definitely granular, otherwise there was no further increase.

The surface of a bottle of broth was nearly covered in a fortnight with a whitish moist pellicle of moderate thickness ; before the end of another fortnight the pellicle had sunk to the bottom of the broth ; parts of it resembled coarse lace, others were denser and had a creamy tinge.

INOCULATION EXPERIMENTS.

(*a*) With the original material.

Guinea-pigs.—Three guinea-pigs, Nos. 3008, 3009, 3010, were inoculated intraperitoneally with an emulsion made from the original material ; No. 3010 died in 13 days apparently from a subacute infection, No. 3008 was killed after 36 days and showed no tuberculosis, No. 3009 was killed also after 36 days and showed slight tuberculosis of the omentum coeliac gland and spleen.

(*b*) With culture.

Calves.—Two calves, Nos. 1429 and 1459, were inoculated subcutaneously each with 50·0 mg. of culture derived from the original material through guinea-pig 3009.

Calf 1459 was killed when dying of urethral obstruction in 92 days and showed slight tuberculosis. There was a thin-walled cyst at the seat of inoculation filled with thick caseo-pus, and the left prescapular gland was three parts occupied by softening caseo-necrotic substance ; the thoracic, mesenteric and ileo-colic glands contained scattered caseous tubercles ; each suprarenal body contained three or four caseous gritty tubercles, and in three Peyer's patches there were altogether ten small nodules some slightly gritty.

Calf 1429 was killed when well after 98 days. There was a thick fibrous walled cyst filled with breaking down caseous substance at the seat of inoculation, and the adjacent prescapular gland was composed almost entirely of softened caseous substance in a fibrous capsule. The thoracic glands contained a few calcareous grains ; one pharyngeal gland contained two caseous nodules, the other and one submaxillary gland contained each a caseous tubercle.

Rhesus Monkeys.—Two monkeys, Nos. 189 and 191, were inoculated subcutaneously with the culture derived from guinea-pig 3009.

Monkey 189 (dose 1·0 mg.) died in 62 days and showed general tuberculosis, severe in the spleen.

Monkey 191 (dose 0·1 mg.) was killed when well after 242 days, and showed chronic general tuberculosis. There was a small healing ulcer at the seat of inoculation, and a walnut-sized caseo-purulent mass in the left axilla. One vertebral gland was much enlarged caseous and softened, another contained a caseous focus. The lungs contained seven caseous nodules up to 3 mm. in diameter and a few grey miliary tubercles ; the liver showed scattered greyish-white foci ; the spleen was slightly enlarged and contained a moderate number of caseous and softened nodules the largest 1 cm. in diameter, several of which projected prominently from the surface. One bronchial and one mesenteric gland contained each a caseous tubercle. In the left parietal bone of the skull there was a patch of caseo-necrosis, and in the brain there was a softened caseous nodule 1·5 cm. in diameter.

Rabbits.—A series of five rabbits was inoculated with the culture derived from guinea-pig 3009, three intravenously and two subcutaneously.

Two more rabbits were subsequently inoculated subcutaneously with the culture.

The three intravenous rabbits (doses 1·0, 0·1, and 0·01 mg.) died of general tuberculosis in 32, 26 and 56 days respectively.

One subcutaneous rabbit (dose 10·0 mg.) died in 136 days apparently of an internal hernia. There was a large thin-walled cyst at the seat of inoculation and the adjacent scapular gland was caseous. The lungs contained fairly numerous tubercles the majority grey and minute, also a grey and caseating patch. There were two or three caseous tubercles in the bronchial glands and the spleen, and a moderate number of tubercles with caseous centres in the kidneys.

The other (dose 8·0 mg.) was killed after 207 days ; there was a softened caseous mass at the seat of inoculation ; the scapular gland contained two calcareous foci and a small cyst ; there were three tubercles on the pleura and half-a-dozen in the kidneys. Other organs and glands were normal.

One subcutaneous rabbit of the second series (dose 2·0–3·0 mg.) died in 138 days of general tuberculosis.

The other (dose 10·0 mg.) was killed after 167 days and showed chronic general tuberculosis, not severe and not obviously progressive.

Guinea-pigs.—Four guinea-pigs were inoculated with the culture derived from guinea-pig 3009 (two intraperitoneally (doses 1·0 and 0·1 mg.) and two subcutaneously (doses 1·0 and 0·1 mg.). They all died of general tuberculosis, the intraperitoneal animals in 23 and 79 days, the subcutaneous animals in 124 and 100 days respectively.

SUMMARY.

The culture investigated was obtained from a case of lupus of the neck in a youth aged 17 years, who had had the disease ten years.

The culture exhibits the cultural characters of the easy growing bovine tubercle bacilli (Class 3).

It has low virulence for the calf, and for the rabbit its virulence is intermediate between that of the bovine and that of the human tubercle bacillus Its virulence for the rhesus monkey is much lower and for the guinea-pig slightly lower than that of either the bovine or the human tubercle bacillus.

VIRUS H. 112. "B.B."

LUPUS.

Original material—Lupus nodules removed by operation.

HISTORY OF PATIENT AND DESCRIPTION OF MATERIAL RECEIVED AT BLYTHWOOD.

The patient was a girl aged 16 years, admitted to hospital for lupus.

There was a large patch of typical non-ulcerative very slightly verrucous lupus on the posterior aspect of the right upper arm ; there was no lupus anywhere else on the body. The duration of the disease was between 7 and 8 years.

There was a family history of tuberculosis, the mother having died of phthisis. The father was alive and well ; there were four sisters, all well ; one sister died in infancy.

The patient had been a weakly child, but had had no serious illness.

On April 30, 1908, an operation was performed, a piece of diseased skin being excised from the right upper arm. The material excised—a piece of skin containing lupus nodules—was sent to Blythwood ; the skin was so tough that it was impossible to emulsify it completely. One tubercle bacillus was found on microscopical examination of the emulsion made from the material, and three guinea-pigs were inoculated with the emulsion.

Present condition.—The patient is now (Aug. 24, 1908) a well grown, well-developed girl, and looks strong ; there is no cough, and there are no physical signs in the chest or abdomen, and no enlarged glands. The lupus itself is improving.

CULTURES.

Cultures were obtained from two of the guinea-pigs, Nos. 3040 and 3042, inoculated with the original material.

On serum both strains grew well with the formation of a rich yellow pigment. On glycerin-serum strain No. 2 produced a moderately thick yellow layer with a wrinkled surface ; in the case of the other strain the growths on serum and glycerin serum were about equal.

On glycerin-agar both strains produced very luxuriant highly-wrinkled creamy-white layers.

On glycerin-potato in one case (strain No. 1) a thick creamy wrinkled and warty layer was formed ; in the other the growths were yellow and granular, and not so thick as in the first case.

On broth one of the strains (No. 1) produced a greyish-white semi-translucent wrinkled membrane which covered the surface completely and attained its maximum thickness in two or three weeks ; on further incubation the surface of the membrane became studded with raised colonies. The other strain produced a moderately thick creamy-white uniform wrinkled membrane which covered the whole surface of the broth and climbed up the sides of the flask.

INOCULATION EXPERIMENTS.

(*a*) With the original material.

Guinea-pigs.—Three guinea-pigs, Nos. 3040, 3041, and 3042, were inoculated intraperitoneally with an emulsion of the original material. No. 3041 died in 10 days and showed no sign of tuberculosis. No. 3042 was killed after 25 days ; there was a grey tubercle in the omentum, a yellow focus in one of the sternal glands, and the pyloric gland was enlarged and congested. No. 3040 was killed after 39 days and showed early general tuberculosis.

(*b*) With culture.

Calf.—Calf 1427 was inoculated subcutaneously with 50·0 mg. of culture derived from guinea-pig 3042 inoculated with the original material.

It was killed after 99 days. There was a tumour at the seat of inoculation composed of softened caseous substance in a fibrous wall, and the adjacent prescapular gland contained two fibro-caseo-calcareous patches ; several of the thoracic glands showed each a few small calcareous tubercles. There was no tuberculosis elsewhere.

Rhesus Monkeys.—Two monkeys, Nos. 199 and 201, were inoculated subcutaneously each with 1·0 mg. of culture derived from guinea-pig 3042.

Monkey 199 died in 45 days as a result of exposure to cold, and showed very slight generalised tuberculosis. There was a firm caseated local tumour, one axillary gland was partly caseous, and several vertebral glands showed each a minute caseous focus or two. A very few minute grey tubercles were seen in the lungs, and a moderate number of small grey tubercles in the spleen, the larger with yellowish centres. A pancreatic gland showed two whitish foci.

Monkey 201 died in 48 days of general tuberculosis.

Rabbits.—A series of six rabbits was inoculated with the culture derived from guinea-pig 3042, four intravenously and two subcutaneously.

One intravenous rabbit (dose 1·0 mg.) died in 99 days. The lungs were crepitant, and showed sparsely scattered small grey tubercles. Each kidney showed on the surface numerous greyish miliary tubercles and a few cicatricial patches ; greyish tubercles with calcareous centres and streaks were seen in the medulla, and in one of the calyces there was caseo-pus. The cause of death was not apparent.

The other three intravenous rabbits (doses, 0·1, 0·01, and 0·01 mg.) were killed after 146 days, and showed no tuberculosis.

The two subcutaneous rabbits (dose 10·0 mg. each) were killed after 146 days, and each showed a cyst containing caseo-pus at the seat of inoculation and no tuberculosis elsewhere.

Guinea-pigs.—A series of four guinea-pigs was inoculated with the culture derived from guinea-pig 3042, two intraperitoneally and two subcutaneously.

One intraperitoneal guinea-pig (dose 1·0 mg.) died in 22 days, and showed early slight general tuberculosis ; the other (dose 0·1 mg.) was accidentally killed after 23 days, and showed early general tuberculosis.

The subcutaneous animals (doses 1·0 and 0·1 mg.) died of general tuberculosis in 100 and 141 days respectively.

SUMMARY.

The culture investigated was obtained from a case of lupus of the arm in a girl aged 16 years.

The culture exhibits the cultural characters of the human tubercle bacillus, and has low virulence for the calf and rabbit. For the monkey and guinea-pigs its virulence appears to be slightly lower than that of the human tubercle bacillus.

VIRUS H. 113. "O.S."

LUPUS.

Original material—A very small piece of diseased skin removed by operation.

HISTORY OF PATIENT AND DESCRIPTION OF MATERIAL RECEIVED AT BLYTHWOOD.

The patient was a girl child aged seven years admitted to hospital on March 19, 1908, for lupus.

The lupus was of two years duration and had commenced on the face. There was now a patch on the right cheek showing some ulceration, a small patch below the left angle of the mouth, two patches on right upper arm, and two on the right buttock.

The general health of the child had always been good.

Family History.—The maternal grandfather died of consumption; there was no other history of tuberculosis in the family. The father and mother and four brothers and sisters were healthy.

Operation.—On April 30, 1908, a piece of diseased skin was removed from the right upper arm. It was sent to Blythwood, and emulsified; no tubercle bacilli were seen in a smear preparation made from the emulsion; two guinea-pigs were inoculated with it.

Of these two guinea-pigs one died in 12 days and showed no obvious signs of tuberculosis; the cause of death was not determined; the other was killed after 35 days and found to be perfectly healthy.

Culture tubes were sown with the emulsion of the original material; these remained sterile.

Present state, August 29, 1908.—The cervical glands are slightly enlarged on both sides of neck, especially the right. There is some slight discharge from the ears. The child looks well, but is rather small for her age. There are no physical signs in the chest. The child presented signs of vermin on the body and in the hair, which may account for the enlarged cervical glands.

SUMMARY.

A small piece of diseased skin from a case of lupus in a child aged 7 years, removed by operation, was used for investigation. Two guinea-pigs inoculated with an emulsion made from the skin did not develop tuberculosis, and culture tubes sown with the emulsion remained sterile. Microscopical examination of the emulsion failed to show tubercle bacilli.

VIRUS H. 114. "A.U."

LUPUS.

Original material—Lupus nodules removed by operation.

HISTORY OF PATIENT AND DESCRIPTION OF MATERIAL RECEIVED AT BLYTHWOOD.

The patient was a girl aged 16 years, admitted to hospital on April 9, 1908.

The lupus was of about 15 years standing. There was a patch affecting the front of the nose, another patch rather warty in type on the left side of the neck, with adjacent scars, and a small patch on the nose at the lower border of the septum. The lupus commenced on the neck, and appeared afterwards on the nose.

The general health of the patient had been good. She had "lumps in the neck" three years ago which did not break; they were not excised and were present now.

Family History.—The father and mother were alive and well; three brothers died young, one from meningitis after a fall, two from bronchitis; one brother was living.

Operation.—On April 30, 1908, an operation was performed, a patch of lupus being excised from the right side of the neck.

The material removed, a piece of skin measuring 2·5 by 1 cm. in area, containing lupus nodules, was sent to Blythwood; an emulsion was made from it, but the skin was so tough that it was impossible to break the whole of it up.

Three guinea-pigs were inoculated with the emulsion; it was examined microscopically but no tubercle bacilli were found in it.

Present condition.—The patient is now (June 21, 1908) in very good health. There are some small glands in the neck; no physical signs in the chest or abdomen. The disease shows signs of improvement.

CULTURES.

Cultures were obtained directly from the original material, one colony growing on one of the two egg tubes sown, and from two of the guinea-pigs (3045 and 3046) inoculated with the original material.

Each of the strains has been tested on the differential media and one or other has grown luxuriantly.

The growths on serum were pigmented. On glycerin-serum a creamy wrinkled layer was produced.

On glycerin-agar a very luxuriant creamy highly-wrinkled membrane was obtained with one of the strains.

The results on potato were irregular; many tubes were sown and the growths varied from a thin greyish or greyish-yellow finely wrinkled or warty layer to a creamy-yellow warty layer of moderate thickness, the best growth being slightly inferior to the average growths produced by the other viruses included in Class IV.

On broth the best growth obtained was moderately thick greyish-white and wrinkled with a creamy tinge.

INOCULATION EXPERIMENTS.

(*a*) With the Original Material.

Guinea-pigs.—Three guinea-pigs, Nos. 3045, 3046, 3047, were intraperitoneally inoculated with an emulsion made from the original material.

No. 3047 died in 3 days and showed no sign of tuberculosis; the cause of death was not apparent. No. 3045 was killed after 27 days and showed no sign of tuberculosis, and No. 3046 was killed after 39 days and showed two tubercles in the omentum and slight tuberculosis of the pyloric gland.

(*b*) With Culture.

Calf.—Calf 1467 was inoculated subcutaneously

with 50·0 mg. of culture derived from the original material. It was killed after 107 days; the local tumour consisted mainly of thickened skin in which there was a cavity filled with caseo-pus, and the adjacent prescapular and prepectoral glands contained two caseous nodules each; there were sparsely-scattered translucent grey foci in the lungs, and no tuberculosis elsewhere.

Rhesus Monkeys.—Two monkeys, Nos. 223 and 225, were inoculated subcutaneously each with 1·0 mg. of culture derived from the original material.

Monkey 225 died in 100 days and showed general tuberculosis severe in the spleen; exposure to cold was the immediate cause of death.

Monkey 223 died in 109 days of general miliary tuberculosis.

Rabbits.—Three rabbits were inoculated intravenously and two subcutaneously with culture derived from the original material.

One intravenous rabbit (dose 1·0 mg.) died in 93 days. The lungs contained a moderate number of caseous tubercles some confluent up to 3 mm. in diameter; there were three small caseous tubercles in one bronchial gland and a small yellow tubercle in the liver; both kidneys showed a few small tubercles and many minute translucent depressions on the surface, and one contained also half a dozen caseous tubercles in the medulla and a soft caseous nodule in the pelvis. A few tubercle bacilli were seen in a smear from the spleen, which appeared normal. The other intravenous rabbits (dose 0·01 mg. each) were killed after 112 days; one showed a caseous tubercle and two or three grey foci in the lungs and no tuberculosis elsewhere, the other sparsely scattered grey tubercles and three caseous nodules in the lungs and one grey tubercle in one kidney.

One subcutaneous rabbit (dose 10·0 mg.) died in 42 days and showed a cyst with caseous contents at the seat of inoculation and one grey tubercle in the lung and no tuberculosis elsewhere.

The other (dose 10·0 mg.) was killed after 112 days and showed three softened caseous nodules at the seat of inoculation, one caseous nodule and three small tubercles in the lungs and no tuberculosis elsewhere.

Guinea-pigs.—Four guinea-pigs were inoculated, two intraperitoneally and two subcutaneously each with 1·0 mg. of culture derived from the original material.

The intraperitoneal guinea-pigs died of general tuberculosis in 33 and 36 days respectively (the latter animal received a little of the dose subcutaneously). The subcutaneous guinea-pigs died in 139 and 256 days of general tuberculosis.

SUMMARY.

The culture investigated was obtained directly from lupus nodules excised from the neck of a girl aged 16; the disease was of about 15 years' standing.

The culture exhibits the cultural characters of the human tubercle bacillus and has low virulence for the calf and rabbit; its virulence for the monkey and guinea-pig is lower than that of the human tubercle bacillus.

Virulence after passage.

The virus was not increased in virulence by residence in the body of a monkey.

TABULAR SUMMARIES.

INOCULATION EXPERIMENTS ON CALVES.

CALVES INOCULATED WITH CULTURES FROM LUPUS VIRUSES.

SUBCUTANEOUS INOCULATIONS.

Virus.	Immediate Source of Culture.	Total Duration of Artificial Cultivation.	Dose in Milli-grammes.	Number of Calf.	Weight in Kilos.		Duration of Life.	Result.
					Initial.	Final.		
(a) With the cultures which grow like bovine tubercle bacilli.								
H. 110. "J.B." (a)	Original material through G.P. 3006.	90 days	50·0 mg.	1483	48·95	35·38	Died 40 days	Severe general tuberculosis.
	Original material through G.P. 3007.	98 days	50·0 mg.	1491	47·60	39·91	Died 17 days	General miliary tuberculosis.
H. 110. "J.B." (b)	Original material through G.P. 3290.	59 days	50·0 mg.	1515	91·15	72·11	Killed 34 days (when dying).	Severe general tuberculosis.
H. 100. "R.S."	Original material through G.P. 2929.	69 days	50·0 mg.	1419	45·80	61·67	Killed 122 days (when fairly well).	Generalised progressive tuberculosis. The tumour at the seat of inoculation was fibro-caseo-calcareous, with caseo-pus in a central cavity, and infiltrated the subjacent muscles. The adjacent prescapular and prepectoral glands were fibro-caseo-calcareous throughout. The lungs contained a moderate number of fibro caseo-calcareous or caseous and softened nodules up to a pea in size, and about half-a-dozen larger nodules up to 1·5 cm. in diameter. The spleen and the left suprarenal body contained each one caseous gritty nodule. The liver showed a large prominent nodular mass composed of gritty fibro-caseous substances surrounded by smaller nodules and tubercles; elsewhere small grey tubercle and a few scattered nodules were seen. Nearly all the lymphatic glands were affected showing varying degrees of caseation and calcification.
	Original material through G.P. 2931.	148 days	100·0 mg.	1409	98·40	136·90	Killed 119 days	Slight retrogressive generalised tuberculosis. There was a collapsed cyst at the seat of inoculation and caseo-calcareous patches in the adjacent prescapular gland. The lungs contained moderately numerous irregular translucent grey nodules from 1 to 4 mm. in diameter, homogeneous throughout (smear, T.B.). Two thoracic glands contained each a few calcareous foci and small caseo-calcareous nodules; the others contained one or two calcareous grains. There was a caseous tubercle in a portal gland, another in a mesenteric gland; a second mesenteric gland showed a caseo-calcareous nodule.
	Original material through G.P. 2929.	320 days	50·0 mg.	1523	54·42	53·51	Killed 73 days (when dying).	General tuberculosis.
		,,	100·0 mg.	1547	52·61	90·25	Killed 95 days	Generalised tuberculosis, not severe and not obviously progressive. At the seat of inoculation there was an ulcerated tumour composed of a caseous and softening mass enclosed in a fibrous capsule. The adjacent prescapular gland was almost entirely composed of dense caseous substance. The lungs contained scattered nodules ranging up to a pea in size, the larger ones were caseous and softened and many of the smaller were calcareous. The thoracic glands contained scattered caseous or calcareous tubercles. Yellow caseous

								miliary tubercles were seen in the small intestine. Most of the abdominal glands and the glands of the neck and throat, and several of the peripheral glands, contained a varying number of caseous or calcareo-caseous nodules or tubercles.
H. 105. "G.S." ...	Original material through G.P. 2950.	60 days	48·0 mg.	1449	59·41	94·34	Killed 130 days	Generalised tuberculosis, not severe and not obviously progressive. At the seat of inoculation there was a cyst filled with caseous masses and watery fluid; the left prescapular gland was three-parts caseous and softened; other glands in the neighbourhood contained caseous nodules. The lungs showed very sparsely scattered minute tubercles and two larger ones, one caseous the other calcareous. There were six calcareous tubercles in the spleen and one in the liver, and three fibro-calcareo-caseous nodules on the omentum. Numerous soft yellow foci were seen in the intestine. All the lymphatic glands in the body contained caseous or calcareous nodules, usually numerous and occasionally confluent.
	"	144 days	92·0 mg.	1405	88·00	99·30	Killed 101 days (when well).	Generalised tuberculosis, severe but not apparently progressive. There was a dense caseous mass surrounded by fibroid tissue at the seat of inoculation, and the adjacent glands were caseous and slightly calcareous. The lungs contained fairly numerous fibro-calcareous tubercles; the thoracic glands were much enlarged and calcareo-caseous. The spleen was very large and packed with caseo-calcareous nodules; the liver and kidneys contained scattered tubercles; the suprarenal bodies showed each half-a-dozen caseo-calcareous nodules. There were two grey tubercles in the heart, caseous tubercles in the pharynx, calcareous tubercles in the tonsils, and several raised pink areas some ulcerated in the trachea. The intestines contained numerous small ulcers and half-a-dozen caseous tubercles. All the lymphatic and haemo-lymph glands in the body, except those already mentioned, contained calcareous tubercles more or less numerous.
H. 53. "D.H." (*b*)	Original material through G.P. 3215.	63 days	50·0 mg.	1507	74·39	58·05	Killed 63 days (when moribund).	General tuberculosis.
	Original material through G.P. 3216.	120 days	50·0 mg.	1535	58·96	109·30	Killed 103 days	Slight generalised tuberculosis. There was a thin-walled abscess at the seat of inoculation filled with caseo-pus and caseous masses. The adjacent prescapular gland was dense and caseous. The lungs showed under the pleura a very few minute calcareous tubercles and grey foci; the spleen contained scattered calcareous tubercles. In the Peyer's patches of the small intestine there were about a dozen small purulent or calcareous lesions some ulcerated, and in the mucous membrane of the intestines were several small ulcers with raised thickened margins. The mammary tissue was normal, but tubercle bacilli were seen in pus from one of the milk sinuses. Nearly all the lymphatic glands of the body were affected and contained a varying number of tubercles, usually calcareous, occasionally caseous.
	"	"	50·0 mg.	1545	49·89	38·55	Died 52 days	General tuberculosis.
H. 107. "H.H."	Original material through G.P. 2955.	63 days	50·0 mg.	1453	90·71	104·77	Killed 126 days	Slight generalised tuberculosis. Small fibro-caseous local lesion; the left prescapular gland was occupied by three fibrous-walled cysts containing caseo-pus. In the lungs there were four pea-sized caseo-purulent nodules and four fibro-calcareous tubercles, in the omentum one caseo-purulent nodule, in the liver three pea-sized fibro-caseo-calcareous nodules, and in the spleen seven similar but smaller nodules. With the exception of the prescapular gland all the lymphatic glands of the body were normal.

CALVES INOCULATED WITH CULTURES FROM LUPUS VIRUSES—*continued.*

SUBCUTANEOUS INOCULATIONS—*continued.*

Virus.	Immediate Source of Culture.	Total Duration of Artificial Cultivation.	Dose in Milligrammes.	Number of Calf.	Weight in Kilos.		Duration of Life.	Result.
					Initial.	Final.		
H. 107. "H.H."—*continued.*	Original material through G.P. 2955.	170 days	80·0 mg.	1497	79·37	94·79	Killed 104 days	Slight generalised tuberculosis. There was a collapsed cyst at the seat of inoculation. and the adjacent glands were caseo-calcareous. Small scattered grey tubercles were seen in the heart, there were two tubercles in the lungs, and one in a suprarenal; the thoracic glands showed scattered caseo-calcareous tubercles and foci. The small intestine was studded with raised patches, in some of which yellow foci were seen, and showed also here and there a caseous focus; each mesenteric gland contained a few caseo-calcareous tubercles; one portal gland contained a few calcareous grains.
H. 108. "H.R."	Original material through G.P. 2957.	57 days	50·0 mg.	1417	46·25	59·41	Killed 125 days	Slight generalised tuberculosis. The local lesion was a small patch of fibrous tissue and thickened skin showing a scar. The left prescapular gland was mainly composed of breaking-down caseous gritty substance. In the lungs there were a few minute glassy tubercles and a small fibro-caseous nodule, in the spleen seven caseous gritty tubercles, and in the liver eight tubercles with minute calcareous centres. Nearly all the lymphatic glands in the body contained caseous and caseo-calcareous tubercles or nodules, some being severely affected; the long mediastinal gland contained in addition a firm caseating nodule 1 cm. in diameter.
	"	170 days	88·0 mg.	1421	92·07	117·45	Killed 101 days	Slight disseminated tuberculosis. Small local lesion composed of fibroid tissue and thickened skin; the left prescapular gland was mainly occupied by a caseo-calcareous mass. The thoracic glands contained calcareous foci discrete and in groups. In the spleen there was a moderate number of small tubercles with calcareo-caseous centres. One or two tubercles were seen in the liver, in the small intestine, and in several abdominal glands.
H. 53. "D.H." (*a*)	Original material through G.P. 1482.	259 days	50·0 mg.	905	64·40	70·29	Killed 91 days	Slight generalised tuberculosis. There was a depressed scar at the seat of inoculation in the skin over a small subcutaneous fibro-caseo-calcareous patch; the adjacent glands were enlarged and partly caseo-necrotic, partly calcareous. The lungs were extensively mottled with angular grey fibrous patches, sometimes confluent, finely speckled with opaque points; an occasional calcareous focus was also seen. The thoracic glands contained calcareous grains. Numerous caseous foci were seen in the Peyer's patches of the small intestine. All the mesenteric and coeliac glands contained calcareous foci, and one mesenteric gland showed also a fibro-calcareous nodule. Two minute calcareous foci were seen in the portal glands. Nearly all the peripheral lymphatic glands contained one or more caseo-fibrous and partly softened tubercles, some rather large.

	"	438 days	50·0 mg.	977	96·55	103·41	Killed 90 days	Slight generalised tuberculosis. There was a prominent local tumour composed of fibro-calcareous tissue partly broken down into caseo-purulent matter; the adjacent glands were almost entirely fibro-calcareous. There was a small number of glassy tubercles in the lung, and an occasional small tubercle in the spleen; numerous calcareous tubercles were seen in the thoracic and portal glands, and there was an occasional calcareous or caseous tubercle in most of the other lymphatic glands. Two calcareous foci were seen in the small intestine and one in a suprarenal.
	"	"	50·0 mg.	1001	71·21	81·18	Killed 91 days	Very slight retrogressive generalised tuberculosis. At the seat of inoculation there was a depressed sinus leading into a patch of fibro-calcareous tissue. The adjacent prescapular gland was extensively calcareous, the prepectoral caseo-necrotic and partly calcareous. About half-a-dozen minute tubercles with calcareous centres were seen in the lungs and a similar number in the spleen; in several of the lymphatic glands there was an occasional calcareous focus.
	"	688 days	50·0 mg.	1135	95·70	118·35	Killed 79 days	Local tuberculosis, with a few disseminated lesions. There was a caseous and partly softened mass surrounded by a fibro-caseo-calcareous zone at the seat of inoculation. More than half the left prescapular gland was composed of fibro-calcareo-caseous tissue. There were scattered gritty foci in the thoracic glands, and one tubercle in each suprarenal.
	"	"	50·0 mg.	1155	120·64	166·0	Killed 136 days	Slight generalised tuberculosis. There was a depressed scar and a small firm fibroid tumour at the seat of inoculation; the adjacent glands were largely caseous and softened. In the lungs there were small scattered nodules up to 4 or 5 mm. in diameter, with grey or fibrous margins and caseo-calcareous sometimes softened centres. The pleura contained scattered caseo-calcareous tubercles up to a hemp seed in size. Moderately numerous softened and caseous or caseo-calcareous tubercles and nodules were seen in nearly every lymphatic gland in the body. One miliary tubercle was seen in the left suprarenal, and there calcareous foci in the small intestine.
H. 85. "H.B."	Original material through G.P. 2363.	83 days	50·0 mg.	1289	62·13	93·43	Killed 94 days	Slight generalised tuberculosis. There was a cyst with caseo-purulent contents at the seat of inoculation. The prescapular gland was partly dense and caseous, partly calcareous. The thoracic, ileo-colic and portal glands contained calcareous patches; nearly all the other glands in the body contained a varying number of calcareous or caseous tubercles. There was one tubercle in the lung, moderately numerous miliary tubercles in the spleen, and one in a suprarenal; and there were a few small tubercles in the Peyer's patches.
	Original material through G.P. 2365.	189 days	96·0 mg.	1331	64·40	85·26	Killed 90 days	Local tuberculosis. There was a small fibrous-walled cyst with caseo-purulent contents at the seat of inoculation. The left prescapular gland was very slightly enlarged, and contained two calcareous patches. There was no tuberculosis elsewhere.
H. 111. "S.E."	Original material through G.P. 3009.	91 days	50·0 mg.	1429	63·95	105·22	Killed 98 days	Local tuberculosis with a few disseminated lesions. There was a fibrous-walled cyst containing breaking down caseous substance at the seat of inoculation: the left prescapular gland was composed of similar substance in a fibrous capsule. The thoracic glands contained sparsely scattered calcareous grains. One submaxillary, one precrural, and two pharyngeal glands each contained one or two caseous tubercles.

CALVES INOCULATED WITH CULTURES FROM LUPUS VIRUSES—*continued.*

SUBCUTANEOUS INOCULATIONS—*continued.*

Virus.	Immediate Source of Culture.	Total Duration of Artificial Cultivation.	Dose in Milli-grammes.	Number of Calf.	Weight in Kilos.		Duration of Life.	Result.
					Initial.	Final.		
H. 111. "S.E."—*continued.*	Original material through G.P. 3009.	91 days	50·0 mg.	1459	45·80	56·69	Killed 92 days (when dying of urethral obstruction).	Very slight generalised tuberculosis. There was a thin-walled cyst containing caseo-pus at the seat of inoculation; the substance of the left prescapular gland was largely replaced by caseo-necrotic substance softening at the margins. The thoracic, several mesenteric, and two ileo-colic glands contained scattered miliary caseous tubercles, the portal glands three minute tubercles, the suprarenal bodies three or four caseous gritty tubercles each; three Peyer's patches of the small intestine contained from one to six small yellowish nodules, some slightly gritty.
H. 91. "H.S." ...	Original material through G.P. 2590.	82 days	50·0 mg.	1353	45·35	74·39	Killed 119 days	Local tuberculosis. There was a cyst containing caseo-pus at the seat of inoculation and half-a-dozen small caseo-calcareous nodules in the adjacent gland only.
(*b*) With the cultures which grow luxuriantly.								
H. 99. "L.K." ...	Original material through G.P. 2927.	28 days	50·0 mg.	1401	48·50	82·99	Killed 120 days	Local tuberculosis with a few disseminated lesions. Flattened fibro-calcareous lesion at seat of inoculation. The left prescapular gland contained a fibro-caseo-calcareous patch; one prepectoral gland was fibro caseo-calcareous throughout. Several mesenteric and ileo-colic glands contained scattered calcareous tubercles and foci.
H. 92. "D.N." ...	Original material through G.P. 2592.	64 days	50·0 mg.	1317	46·25	42·18	Died 26 days (Renal disease).	Local tuberculosis with a few disseminated lesions. There was a flat caseo-necrotic local lesion. The left prescapular and one cervical glands were largely composed of caseous strands in a translucent matrix. Some minute foci were seen in the lungs and liver (smears showed a few T.B.). There was one yellow focus in a portal gland. The thoracic glands were congested and oedematous; a smear from one of them showed T.B.
H. 109. "M.W."	Original material through G.P. 3002.	50 days	47·0 mg.	1437	61·67	79·80	Killed 106 days	Local tuberculosis. There was a fibrous-walled cyst with caseo-purulent contents at the seat of inoculation; the left prescapular gland showed scattered caseous foci, and one cervical gland two small nodules one caseous the other calcareous.
H. 112. "B.B." ...	Original material through G.P. 3042.	63 days	50·0 mg.	1427	83·01	109·30	Killed 99 days	Local tuberculosis with a few disseminated lesions. Fibro-caseous lesion at seat of inoculation; two small fibro-caseo-calcareous patches in the left prescapular gland; and a few small calcareous tubercles in several thoracic glands.

H. 71. "L.V." (*a*)	Original material through G.P. 1937.	78 days	50·0 mg.	1153	71·21	126·09	Killed 95 days	Slight retrogressive generalised tuberculosis. At the seat of inoculation there was a small firm fibroid mass covered by greatly thickened skin and containing a cavity filled with caseo-pus; the adjacent prescapular gland contained a fibro-calcareous patch and a few calcareous tubercles and grains; the left prepectoral was mainly composed of fibro-calcareous tissue. There were calcareous patches in the thoracic glands and calcareous foci in many of the abdominal glands. The lungs showed half-a-dozen transparent tubercles.
	"	"	50·0 mg.	1163	83·46	134·26	Killed 95 days	Local tuberculosis, with a few minute tubercles in lungs. The local tumour was a cyst composed of caseo-purulent substance surrounded by a thin fibrous wall. The nearest glands contained fibro-calcareous nodules with caseous patches entirely softened. A dozen glassy tubercles were seen in the lungs.
H. 101. "E.G."	Original material through G.P. 2932.	56 days	50·0 mg.	1447	51·25	83·91	Killed 123 days	Local tuberculosis. The local lesion consisted of greatly thickened skin and a small patch of fibrous tissue; the left prescapular gland contained three and the left prepectoral one pea-sized caseous and softened nodules. There was no tuberculosis elsewhere.
H. 114. "A.U." ...	Original material	144 days	50·0 mg.	1467	96·60	124·72	Killed 107 days	Local tuberculosis with a few disseminated lesions. The tumour at the seat of inoculation consisted mainly of thickened skin in which there was a cavity filled with caseo-pus, and the adjacent prescapular and prepectoral glands contained two caseous nodules each; there were sparsely scattered translucent grey foci in the lungs, and no tuberculosis elsewhere.
H. 103. "N.S."...	Original material through G.P. 2940.	58 days	88·0 mg.	1457	53·51	91·16	Killed 107 days	Local lesion only. The local lesion was composed of thickened skin and a subcutaneous mass of fibroid tissue in which there was a very small cavity containing caseo-pus; a funnel-shaped depression in the skin communicated with the cavity. There was no tuberculosis elsewhere.
H. 106. "K.R." ...	Original material through G.P. 2952.	38 days	50·0 mg.	1403	53·97	95·70	Killed 112 days	No tuberculosis. At the seat of inoculation there was a tumour composed of very thick skin and a small subcutaneous mass of fibroid tissue showing neither caseation or calcification. The left prescapular gland was normal in size and appearance.
H. 84. "M.S." ...	Original material through G.P. 2277	102 days	50·0 mg.	1273	59·86	87·53	Killed 89 days	Local tuberculosis. At the seat of inoculation there was a cyst with caseo-purulent contents; the left prescapular gland contained two large caseo-calcareous masses; there was no tuberculosis elsewhere.
H. 102. "N.H."	Original material through G.P. 2934.	62 days	43·0 mg.	1423	52·15	78·47	Killed 107 days	Local tuberculosis. There was a fibrous-walled cyst containing caseo-pus and watery fluid at the seat of inoculation and a small calcareous patch in the prescapular gland only.

CALVES INOCULATED WITH CULTURES FROM LUPUS VIRUSES—*continued.*

INTRAVENOUS INOCULATIONS.

Virus.	Immediate Source of Culture.	Total Duration of Artificial Cultivation.	Dose in Milli-grammes.	Number of Calf.	Weight in Kilos.		Duration of Life.	Result.
					Initial.	Final.		
H. 53. "D.H." (*a*)	Original material through G.P. 1482.	1,124 days	5·0 mg.	1395	66·20	58·96	Died 21 days	Acute general tuberculosis.
	"	"	1·0 mg.	1391	62·13	47·60	Killed 40 days (when dying).	General tuberculosis.
H. 85. "H.B." ...	Original material through G.P. 2365.	273 days	10·0 mg.	1373	48·05	38·10	Killed 28 days (when dying).	General tuberculosis.
H. 92. "D.N." ...	Original material through G.P. 2592.	114 days	10·0 mg.	1377	51·25	39·46	Died 32 days	General tuberculosis.

INOCULATION EXPERIMENTS ON RABBITS.

RABBITS INOCULATED WITH CULTURES FROM LUPUS VIRUSES.

INTRAVENOUS INOCULATIONS.

Virus.	Immediate Source of Culture.	Total Duration of Artificial Cultivation.	Dose in Milli-grammes.	Number of Rabbit.	Weight in Grammes.		Duration of Life.	Result.
					Initial.	Final.		
(*a*) With the cultures which grow like bovine tubercle bacilli.								
H. 110. "J.B." (*a*)	Original material through G.P. 3007.	59 days	1·0 mg.	1904	2,700	2,020	Died 17 days	Acute miliary tuberculosis.
			0·1 mg.	1905	1,600	1,250	Died 21 days	General miliary tuberculosis.
			0·01 mg.	1906	1,600	1,300	Died 32 days.	General miliary tuberculosis.
			0·01 mg.	1907	1,700	1,320	Died 32 days	General miliary tuberculosis.
H. 110. "J.B." (*b*)	Original material through G.P. 3290.	59 days	1·0 mg.	2087	1,900	1,650	Died 14 days	General tuberculosis.
			0·1 mg.	2088	1,250	900	Died 20 days	General miliary tuberculosis.
			0·01 mg.	2089	1,850	1,320	Died 32 days	General miliary tuberculosis.
H. 100. "R.S."	Original material through G.P. 2929.	69 days	1·0 mg.	1866	1,500	1,110	Died 22 days	General miliary tuberculosis.
			0·1 mg.	1867	1,150	1,220	Died 17 days	Acute tuberculosis.
			0·01 mg.	1868	1,250	1,550	Died 174 days	General tuberculosis. The lungs contained a moderate number of caseous tubercles and several caseous nodules, and the margins in many places showed firm caseous patches. The spleen contained moderately numerous calcareous tubercles; in the kidneys there were scattered caseous tubercles and caseous streaks, and one calyx contained caseo-pus. There were two or three tubercles in the bronchial glands, in one lumbar gland, and on the mesentery.
	Original material through G.P. 2931.	148 days	1·0 mg.	1974	1,600	1,280	Died 21 days	General miliary tuberculosis.
			0·1 mg.	1975	1,550	910	Died 40 days	General miliary tuberculosis.
			0·01 mg.	1976	1,250	1,550	Died 78 days	General tuberculosis.
H. 105. "G.S."	Original material through G.P. 2950.	60 days	1·0 mg.	1890	1,300	830	Died 40 days	General miliary tuberculosis.
			0·1 mg.	1891	1,250	760	Died 31 days	General miliary tuberculosis.

			0·01 mg.	1892	1,250	800	Died 41 days	General tuberculosis.
H. 53. "D.H." (*b*)	Original material through G.P. 3215.	63 days	1·0 mg.	2065	2,000	1,660	Died 27 days	General miliary tuberculosis.
			0·1 mg.	2066	1,950	1,550	Died 36 days	General miliary tuberculosis.
			0·1 mg.	2067	1,720	1,170	Died 25 days	General miliary tuberculosis.
			0·01 mg.	2068	1,970	1,700	Died 136 days	General tuberculosis. The caudal lobes of the lungs were extensively caseo-calcareous and contained many small cavities partly filled with caseo-calcareous substance; the anterior lobes were beset with caseo-calcareous tubercles often confluent; the larger bronchi were filled with muco-pus. There were moderately numerous calcareo-caseous tubercles in the spleen. The kidneys showed numerous grey tubercles, and nodules with caseous foci, on the surface, and caseous streaks in the medulla; the calyces of one were filled with caseo-pus. Both testicles were enlarged and extensively caseated, and there were numerous caseous nodules on and in the epididymis and along the cord and vessels. Scattered caseous nodules were seen on the peritoneum. The appendix showed moderately numerous caseous tubercles (smear, T.B.). The bronchial portal and coeliac glands contained caseo-calcareous patches or tubercles; one lachrymal and some of the peripheral glands contained caseous nodules.
	Original material through G.P. 3216.	120 days	1·0 mg.	2122	1,800	1,420	Died 20 days	General miliary tuberculosis.
			0·1 mg.	2123	2,450	1,590	Died 24 days	General miliary tuberculosis.
			0·01 mg.	2124	1,500	1,150	Died 70 days	General tuberculosis.
	Original material through G.P. 3218.	94 days	1·0 mg.	2169	2,020	1,350	Died 25 days	General miliary tuberculosis.
			0·1 mg.	2170	1,950	1,200	Died 80 days	General tuberculosis.
			0·01 mg.	2171	1,500	1,200	Died 43 days	General tuberculosis.
H. 107 "H.H."	Original material through G.P. 2955.	63 days	1·0 mg.	1897	1,000	750	Died 18 days	Early general tuberculosis.
			0·1 mg.	1898	870	690	Died 21 days	General miliary tuberculosis.
			0·01 mg.	1899	870	800	Died 142 days	General tuberculosis. The lungs were closely beset with miliary tubercles with calcareo-caseous centres, for the most part discrete. The liver showed indefinite grey foci throughout. The spleen was enlarged and closely beset with caseo-calcareous tubercles. The cortices of the kidneys were closely beset with grey tubercles with caseous or calcareous centres, the medullae showed a few caseous streaks and foci, and the calyces contained caseo-pus. The bronchial glands showed caseo-calcareous patches; the iliac and coeliac glands contained calcareous tubercles, and one mesenteric gland contained a caseous nodule. A few caseous tubercles were seen in the areolar tissues of the groin and the subperitoneal tissues of the lumbar regions.

RABBITS INOCULATED WITH CULTURES FROM LUPUS VIRUSES—*continued.*

INTRAVENOUS INOCULATIONS—*continued.*

Virus.	Immediate Source of Culture.	Total Duration of Artificial Cultivation.	Dose in Milli-grammes.	Number of Rabbit.	Weight in Grammes.		Duration of Life.	Result.
					Initial.	Final.		
H. 107. "H.R."—*continued.*	Original material through G.P. 2955.	63 days	0·01 mg.	1900	950	850	Died 149 days	General tuberculosis. The lungs were crepitant and showed a moderate number of miliary tubercles, the majority caseous, and a group of caseous gritty nodules. The bronchial glands were calcareo-caseous. The spleen was slightly enlarged and closely beset with minute calcareous tubercles, and contained also one caseo-calcareous nodule. There were a few doubtful foci in the liver. Each kidney showed scars on the surface, scattered miliary caseous tubercles in the cortex, and more numerous caseous tubercles and a few streaks in the medulla; the pelvis of the right was distended with caseo-pus. There were two or three caseous tubercles in the mesenteric glands. There were two caseous nodules situated on the left eyeball at the inner aspect of the cornea, one ulcerated; there was a caseous ulcer also at the centre of the cornea, and a nodular projecting caseous swelling nearly 2 cm. in diameter extended on the inner side of the eyeball from the margin of the cornea to the optic nerve. The left lachrymal gland contained a caseous gritty nodule. The right eye was normal.
H. 108. "H.R."	Original material through G.P. 2957.	57 days	1·0 mg.	1871	1,300	920	Died 21 days	General tuberculosis.
			0·1 mg.	1872	950	950	Died 136 days	Severe general tuberculosis. The lung tissue was extensively replaced by caseating patches and nodules; the anterior lobes were reddish-grey and solid and the posterior parts of the caudal lobes were almost entirely caseous. The bronchial glands were much enlarged and extensively caseous. On the heart there was a cluster of three small caseous tubercles, loosely attached. The liver contained scattered grey tubercles; the spleen was much enlarged and closely beset with caseous tubercles. The kidneys were enlarged, the cortices were closely beset with caseous tubercles, and there were several large grey wedge-shaped partly caseous nodules extending deeply into the medullae which showed also caseous tubercles and streaks; the calyces were filled with caseo-pus. Most of the lymphatic glands contained caseous tubercles, and there were a few caseous tubercles in the subperitoneal tissues of the lumbar regions.
			0·01 mg.	1873	1,000	1,450	Killed 155 days (when ill).	General tuberculosis. The lungs contained scattered miliary caseous tubercles, and the thin margins of the anterior lobes were solid and composed of caseous gritty patches in a grey matrix; several bronchi in the caudal lobes were dilated and contained caseo-pus. On the pleurae and diaphragm there were a number of flattened caseous growths, some loosely attached. The bronchial glands contained caseous tubercles. The spleen was enlarged and contained fairly numerous miliary caseous gritty tubercles; the liver showed a moderate number of

								caseous tubercles with grey margins. Each kidney contained large wedge-shaped nodules projecting slightly on the surface, on section they were grey with caseous striae terminating at the papillae; there were cicatricial patches on the surface of each kidney and caseo-pus was seen in one calyx. There were two large caseating nodules in the wall of the stomach, and fairly numerous grey miliary tubercles on the mesentery and meson-colon. One inguinal gland was beset with caseous tubercles, and there was a caseous focus or two in the mesenteric glands.
H. 53. "D.H." (*a*)	Original material through G.P. 1482.	594 days	1·0 mg.	955	3,300	1,870	Died 22 days	Acute general tuberculosis.
	"	688 days	0·1 mg.	1093	1,070	1,420	Died 33 days	General miliary tuberculosis.
	"	1,069 days	1·0 mg.	1715	2,670	1,900	Died 23 days	General miliary tuberculosis.
			0·01 mg.	1714	2,800	1,930	Died 66 days	General tuberculosis.
	"	1,124 days	0·1 mg.	1804	1,940	1,200	Died 40 days	General miliary tuberculosis.
			0·01 mg.	1805	1,470	1,030	Died 131 days	General miliary tuberculosis. The lungs were crepitant and contained a moderate number of miliary caseous tubercles; the thin margins of all the lobes were caseous. The bronchial glands contained caseous tubercles. The spleen contained a moderate number of submiliary caseous tubercles. Each kidney showed pits and scars and a few caseous tubercles on the surface and fairly numerous caseous tubercles and streaks in the medulla. There was some caseo-pus in one knee-joint. One suprarenal body contained a caseous tubercle.
			0·001 mg.	1806	840	880	Died 106 days	General tuberculosis. The lungs were composed of firm caseous areas with a thin margin of grey tissue; between the areas there was a small amount of crepitant lung tissue. The bronchial glands contained small caseous patches. The liver showed a moderate number of submiliary grey tubercles. In the cortex of each kidney there were moderately numerous miliary caseous tubercles with grey margins; on section many extended into the medulla as caseous streaks. The spleen was much enlarged and very closely beset with caseous slightly gritty nodules confluent around the margins. The peripheral and abdominal lymphatic glands contained caseous nodules, and there were caseous tubercles in the marrow of the ribs and here and there in the subcutaneous tissues.
H. 85. "H.B."	Original material through G.P. 2363.	83 days	1·0 mg.	1474	1,400	1,100	Died 11 days	Death was caused by psorospermosis of the liver. The left lung was dark red and showed very numerous small grey miliary tubercles; the upper part of the cephalic lobe of the right lung was similar but the rest of the lung was crepitant and showed no tubercles. There was no sign of tuberculosis elsewhere.
	Original material through G.P. 2365.	98 days	0.1 mg.	1473	1,850	1,600	Died 39 days	General miliary tuberculosis.
			1·0 mg	1495	2,700	2,200	Died 21 days	Acute general tuberculosis.
	"	189 days	0·1 mg.	1496	2,720	1,600	Died 48 days	General tuberculosis.
			1·0 mg.	1591	2,190	1,520	Died 31 days	General miliary tuberculosis.
	"	218 days	0·1 mg.	1592	1,190	870	Died 38 days	General miliary tuberculosis.

RABBITS INOCULATED WITH CULTURES FROM LUPUS VIRUSES—*continued.*

INTRAVENOUS INOCULATIONS—*continued.*

Virus.	Immediate Source of Culture.	Total Duration of Artificial Cultivation.	Dose in Milli-grammes.	Number of Rabbit.	Weight in Grammes.		Duration of Life.	Result.
					Initial.	Final.		
H. 85. "H.B."—*continued.*	Original material through G.P. 2365.	309 days	1·0 mg.	1651	2,370	1,850	Died 16 days	Early general tuberculosis.
			1·0 mg.	1822	1,570	1,310	Died 10 days	Early tuberculosis of lungs and spleen. Death apparently from haemorrhage during parturition.
			0·1 mg.	1823	1,470	650	Died 110 days	General miliary tuberculosis. The lungs were collapsed; the posterior parts of the caudal lobes were solid and fibro-caseous, and the thin margins were caseating; the tips and margins of the anterior lobes were reddish grey with caseous foci; the rest of the lungs were crepitant and contained caseous miliary tubercles. The bronchial glands were enlarged caseous and softened. The spleen contained one minute tubercle. The capsules of the kidneys were adherent, and the cortices severely scarred; they contained numerous miliary caseous tubercles and caseous streaks. The mesenteric and portal glands were caseous. In the subperitoneal tissues of the lumbar regions there were very numerous closely aggregated caseous miliary tubercles enveloped in fibrous tissue; there were similar but not so numerous tubercles in the loose areolar tissues of the neck, axillae, groins, pubis, around the uterus and in the ligaments, in the omentum and on the mesentery and pleura; the tissues of the back showed very large aggregations.
			0·01 mg.	1824	1,870	1,120	Died 117 days	General tuberculosis. The lungs were crepitant and showed discrete grey tubercles mostly subpleural, and a few large thin caseating patches; in the thin margins there were firm caseating patches not continuous. The bronchial glands were normal. There were several grey nodules with caseous centres on the surface of the left ventricle. The kidneys showed on the surface scars, fairly numerous caseous tubercles, and some grey nodules with caseous foci formed by aggregated tubercles; many tubercles extended into the substance, some to the apex of the papillae, as soft caseous streaks. There were several caseous tubercles in the subperitoneal tissues of the lumbar region. The alveoli of the mammary glands contained caseo-purulent substance (smear, T.B. numerous).
H. 111. "S.E."	Original material through G.P. 3009.	51 days	1·0 mg.	1916	1,700	1,060	Died 32 days	General miliary tuberculosis.
			0·1 mg.	1917	2,350	1,720	Died 26 days	General miliary tuberculosis.
			0·01 mg.	1920	1,250	900	Died 56 days	General miliary tuberculosis.

H. 91. "H.S."	Original material through G.P. 2590.	82 days	1·0 mg.	1688	1,020	3,100	Killed 235 days	The inoculation was partly perivenous; around the vein at the seat of inoculation there was a small collection of caseo-pus. Two or three minute foci of a doubtful nature were seen in the lungs. There was no sign of tuberculosis elsewhere.
			0·1 mg.	1687	1,350	1,950	Killed 235 days	There were two minute transparent tubercles in the lungs, and no sign of tuberculosis elsewhere.

(*b*) With the cultures which grow luxuriantly.

H. 99. "L.K."	Original material through G.P. 2927.	28 days	1·0 mg.	1811	2,950	2,450	Died 21 days	General tuberculosis.
			0·1 mg.	1812	2,670	1,250	Died 143 days	Chronic general tuberculosis. On the dorsal surfaces of the lungs there were thin greyish-yellow tracts, and elsewhere on the surface scattered caseous tubercles and a few caseous nodules, and in the substance sparsely scattered tubercles; the thin margins of the lungs were solid and caseating. There were numerous caseous tubercles up to a hemp seed in size in the cortices of the kidneys and caseous streaks in the medullae; the surfaces showed some large scars; there was caseo-pus in the calyces of one. The spleen contained a small caseous gritty tubercle (smear, no T.B.). There were numerous small caseous tubercles in the peritoneal tissues around the kidneys, a few in the omentum and in the loose areolar tissues of the axillae and groins. The mammary glands were caseous and the knee joints were tuberculous. There were two caseous ulcers at the corneo-sclerotic junction of the left eye, and many greyish-white miliary tubercles in the iris of the right eye; each lachrymal gland contained a caseous nodule
			0·01 mg.	1813	670	690	Died 1 day	Coccidiosis of the liver.
H. 92. "D.N."	Original material through G.P. 2592.	64 days	1·0 mg.	1630	1,470	970	Died 183 days	Slight chronic general tuberculosis. The lungs contained about eight small caseo-calcareous tubercles. There were four miliary caseous tubercles in the left kidney and one in the right, which also showed two or three scars on the surface. In the neck between the maxillae there were four large thin-walled glands filled with muco-pus (T.B. numerous). Over the right patella there was a small caseous and softened mass, the bone under which was necrosed, and there was early tuberculosis of the synovial membrane of the knee-joint.
			0·1 mg.	1631	1,300	1,150	Died 188 days	Slight chronic general tuberculosis. The cause of death was not apparent. The lungs contained four calcareo-caseous miliary tubercles; the bronchial glands contained discrete calcareous tubercles. In one kidney there were two caseating tubercles; in the other there were several short caseous streaks, and the calyces were filled with caseo-pus.
	,,	114 days	1·0 mg.	1739	2,920	2,300	Died 55 days	Death from cellulitis. The lungs showed on the surface scattered grey tubercles slightly caseous in the centre, and in the margins here and there thin caseous patches. There were no visible tubercles elsewhere, but the spleen was enlarged.
			1·0 mg.	1740	3,220	2,090	Killed 208 days	General tuberculosis. The appearance of some of the lesions was unusual, suggesting infection with a virulent bacillus, and a dysgonic culture quite different from the culture inoculated was isolated from the kidney.

RABBITS INOCULATED WITH CULTURES FROM LUPUS VIRUSES—*continued.*

INTRAVENOUS INOCULATIONS—*continued.*

Virus.	Immediate Source of Culture.	Total Duration of Artificial Cultivation.	Dose in Milli-grammes.	Number of Rabbit.	Weight in Grammes.		Duration of Life.	Result.
					Initial.	Final.		
H. 109. "M.W."	Original material through G.P. 3002.	50 days	1·0 mg.	1910	1,070	900	Died 15 days	Early general tuberculosis.
			0·1 mg.	1911	1,090	2,470	Killed 145 days	There were a few grey tubercles and two small caseo-calcareous nodules in the lungs, two or three small tubercles and one fibrous patch in the kidneys, and sparsely scattered caseous (some gritty) tubercles in the muscles.
			0·01 mg.	1912	1,090	2,270	Killed 145 days	There was one minute grey tubercle in the lungs and no sign of disease elsewhere.
			0·01 mg.	1913	890	1,000	Died 18 days	Death appeared to be due to gastritis. There were a few small greyish-white tubercles in the lungs, and a moderate number of yellowish-white tubercles on the surface of each kidney, and no tuberculosis elsewhere.
H. 112. "B.B."	Original material through G.P. 3042.	63 days	1·0 mg.	1940	2,250	2,000	Died 99 days	Slight general tuberculosis. The cause of death was not apparent. The lungs contained sparsely scattered small tubercles, many glassy, others with opaque centres. Each kidney showed on the surface a few cicatricial patches and numerous grey miliary tubercles with minute opaque sometimes gritty centres, and greyish tubercles with calcareous centres in the medulla; there was caseo-pus in a calyx of one kidney.
			0·1 mg.	1941	2,350	2,200	Killed 146 days	No tuberculosis.
			0·01 mg.	1942	1,850	2,400	Killed 146 days	No tuberculosis.
			0·01 mg.	1943	1,650	2,470	Killed 146 days	No tuberculosis.
H. 71. "L.V." (*a*)	Original material through G.P. 1937.	78 days	1·0 mg.	992	1,460	1,700	Killed 188 days	Slight chronic general tuberculosis. Two small tubercles were seen in the lungs. The kidneys contained numerous grey miliary tubercles and some caseous streaks and foci, and showed on the surface the usual depressed scars; the calyces of the right were distended with caseo-pus. The right testicle (greatly enlarged) was composed of caseo-purulent substance.
			0·1 mg.	993	1,450	2,250	Killed 188 days	Chronic general tuberculosis. There were numerous thin-walled caseo purulent nodules the largest the size of a starling's egg in the lung. Each kidney contained several grey miliary tubercles, and the pelvis of the left was filled with caseo-pus; numerous little pits were seen on the surfaces. Caseo-calcareous tubercles were sparsely scattered in the muscles, and collections of caseo-pus were found under the aponeurosis of the muscles of the right tibia and femur near the knee-joint, and in one testicle.
H. 71. "L.V." (*b*).	Original material through G.P. 3021.	63 days	1·0 mg.	1925	1,150	1,550	Died 4 days	There was no sign of disease. The cause of death was not apparent.

			0·1 mg.	1926	1,450	2,620	Killed 161 days	There were two or three minute tubercles in the lungs, and a small tubercle with a caseous centre in one kidney ; there was no tuberculosis elsewhere.
			0·01 mg.	1927	1,300	2,320	Killed 161 days	In the lungs there were about eighteen reddish-grey nodules up to a split-pea in size containing caseous points, and each kidney contained a minute tubercle ; there was no disease elsewhere.
H. 101. "E.G."	Original material through G.P. 2932.	56 days	1·0 mg.	1885	1,250	990	Died 24 days	Early general tuberculosis.
			0·1 mg.	1886	1,050	1,920	Killed 144 days	The lungs showed one calcareous tubercle and a number of indefinite grey foci. Each kidney showed in the medulla a few grey translucent nodules, and there were two scars on the surface of one. There was no tuberculosis elsewhere.
			0·1 mg.	1887	1,050	1,950	Killed 144 days	Minute grey points of doubtful nature were just visible in the lungs. In the medulla of each kidney there were a few yellow foci surrounded by translucent grey tissue ; a grey streak with yellow softened foci was seen in the cortex of one. There was no tuberculosis elsewhere.
H. 114. "A.U."	Original material	144 days	1·0 mg.	2008	2,320	1,420	Died 93 days	General tuberculosis, not severe. The right lung was crepitant and showed on the surface about thirty discrete soft caseous tubercles and a few nodules composed of confluent tubercles ; a few tubercles were seen on section. The left lung showed similar but less numerous tubercles. One bronchial gland contained three small caseous tubercles. A small yellow tubercle (smear, T.B.) was seen in the liver. The kidneys showed on the surface many minute translucent depressions and a few small yellowish tubercles ; about half a dozen caseous tubercles were seen in the medullae and in the pelvis of one there was caseo-pus. The spleen appeared normal, but a smear from the substance showed T.B.
			0·01 mg.	2009	2,300	2,650	Killed 112 days	There was one caseous miliary tubercle and two or three doubtful grey foci in the lungs, and no disease elsewhere.
			0·01 mg.	2010	2,620	2,600	Killed 112 days	There were sparsely scattered grey miliary tubercles and three small caseous nodules in the lungs, and a grey miliary tubercle in one kidney ; there was no tuberculosis elsewhere.
H. 103. "N.S."	Original material through G.P. 2938.	70 days	1·0 mg.	1881	2,000	1,650	Died 22 days	Acute general tuberculosis. The lungs were composed practically throughout of reddish-grey solid tissue containing scattered caseous foci. The bronchial glands contained small caseous patches. The spleen (enlarged) and kidneys were speckled with submiliary grey tubercles, the liver was speckled with grey foci.
			0·1 mg.	1882	2,200	3,000	Killed 138 days	There was a small caseous nodule and a few submiliary tubercles with caseous centres in the lungs. The kidneys contained altogether about a dozen small grey nodules with slight caseation, and showed one or two small scars on the surface. Each mammary gland was a little enlarged, and contained thick caseo-purulent substance in the ducts (smear, a few T.B.).
	Original material through G.P. 2940.	36 days	1·0 mg.	1840	1,920	1,750	Killed 160 days	The lungs contained scattered grey miliary tubercles, the kidneys a number of caseous tubercles in the cortex and a few caseous streaks in the medulla. There was no tuberculosis elsewhere.
			1·0 mg.	1841	1,500	1,000	Died 13 days	The lungs showed fairly numerous minute glassy tubercles. There was no tuberculosis elsewhere. Death was due to injuries.
H. 106. "K.R."	Original material	9 days	0·1 mg.	1857	1,250	2,850	Killed 143 days	There were three or four grey miliary tubercles with caseous centres in the medulla of each kidney, and a small scar on the surface of one ; there was no disease elsewhere.

RABBITS INOCULATED WITH CULTURES FROM LUPUS VIRUSES—*continued.*

INTRAVENOUS INOCULATIONS—*continued.*

Virus.	Immediate Source of Culture.	Total Duration of Artificial Cultivation.	Dose in Milli-grammes.	Number of Rabbit.	Weight in Grammes.		Duration of Life.	Result.
					Initial.	Final.		
H. 106. "K.R."—*continued.*	Original material	91 days	0·01 mg.	1858	1,200	2,150	Killed 143 days	There was a casco-calcareous nodule the size of a split pea in the lung, and no disease elsewhere.
	Original material through G.P. 2952.	38 days	1·0 mg.	1835	2,700	2,950	Killed 160 days	Both kidneys showed depressed scars on the surface. and one a grey tubercle; in the medulla of each there were a few yellow foci and greyish tubercles. There was no disease elsewhere.
			0·1 mg.	1836	1,520	1,250	Died 22 days	The lungs were a little congested and oedematous, and contained fairly numerous glassy miliary tubercles. The spleen was a little enlarged and soft, the liver contained a few greyish foci, and the kidneys scattered grey submiliary tubercles.
			0·01 mg.	1837	1,200	1,020	Died 2 days	The cause of death was not apparent.
H. 84. "M.S."	Original material through G.P. 2277.	62 days	1·0 mg.	1358	1,290	770	Died 8 days	The organs and glands appeared healthy. The cause of death was not apparent.
			0·1 mg.	1359	1,200	2,750	Killed 147 days	There was a calcareo-caseous nodule the size of a millet-seed and two or three greyish-white tubercles in the lungs, a yellow focus in one kidney, and no tuberculosis elsewhere.
	,,	102 days	1·0 mg.	1414	1,500	1,760	Died 100 days	There was a minute yellow tubercle in each kidney, and no tuberculosis elsewhere. The cause of death was not apparent.
	,,	266 days	1·0 mg.	1683	1,370	1,500	Killed 334 days	Chronic general tuberculosis. The lungs contained scattered grey tubercles and a few miliary caseous tubercles, and the tip of one caudal lobe was caseous and gritty. The kidneys showed pits and scars on the surface, and in the cortex and medulla scattered caseo-calcareous nodules mostly the size of millet-seeds. The right knee- and ankle-joints were swollen and contained caseo-pus; the left knee-joint showed early caseation of the synovial membrane. Two vertebral glands were enlarged and caseous. Other organs and glands were normal.
	,,	366 days	9·0 mg.	1834	2,200	1,650	Died 329 days	The lungs contained sparsely scattered submiliary grey tubercles. The kidneys showed on the surfaces scattered caseous tubercles and a few scars; in the medullae a few caseous foci (and in one a caseous nodule). One testicle was enlarged and showed softened caseous nodules, the epididymis was more extensively caseous. The lachrymal glands were enlarged caseous and softened.
H. 102. "N.H."	Original material through G.P. 2934.	62 days	1·0 mg.	1876	1,200	2,450	Killed 139 days	There were two caseous foci in the medulla of the left kidney, and half-a-dozen in that of the right; the latter also contained in the cortex a small fibrous wedge. There was no tuberculosis elsewhere.
			0·1 mg.	1877	1,050	2,400	Killed 139 days	In the medulla of one kidney there was a grey tubercle with a calcareous centre. There was no tuberculosis elsewhere.
			0·01 mg.	1878	1,050	3,770	Killed 139 days	No tuberculosis.

(*a*) With the cultures which grow like bovine tubercle bacilli.

H. 110. "J.B." (*a*)	Original material through G.P. 3007.	59 days	10·0 mg.	1909	1,470	1,320	Died 59 days	General tuberculosis.
			8·0 mg.	1908	1,850	1,430	Died 61 days	General tuberculosis.
	,,	98 days	33·0 mg.	1932	1,750	1,620	Died 30 days	General miliary tuberculosis.
			10·0 mg.	1933	1,600	1,400	Died 53 days	General tuberculosis.
	Original material through G.P. 3006.	90 days	5·0 mg.	1934	1,250	1,140	Died 41 days	General tuberculosis.
			1·0 mg.	1935	1,000	1,120	Died 44 days	General tuberculosis.
H. 110. "J.B." (*b*)	Original material through G.P. 3290.	59 days	10·0 mg.	2090	1,350	1,050	Died 35 days	General tuberculosis.
			10·0 mg.	2091	1,700	1,400	Died 49 days	General tuberculosis.
	Original material through G.P. 3289.	85 days	50·0 mg.	2143	1,120	870	Died 28 days	General tuberculosis.
			50·0 mg.	2144	1,000	820	Died 25 days	General tuberculosis.
			10·0 mg.	2141	1,300	1,050	Died 36 days	General tuberculosis.
			10·0 mg.	2142	1,320	1,200	Died 30 days	General tuberculosis.
H. 100. "R.S."	Original material through G.P. 2929.	69 days	10·0 mg.	1869	1,100	2 550	Died 337 days	General tuberculosis. There was a caseous ulcer, and the nearest glands were enlarged and caseous throughout. The lungs were very large and composed practically throughout of caseous coalescing masses with grey margins. The kidneys showed a moderate number of raised grey nodules up to a hempseed in size slightly caseous in the centre. There were a few flat caseous growths on the pleura and one on the heart.
			10·0 mg.	1870	900	970	Died 163 days	General tuberculosis. There was an ulcerated caseous local lesion with discrete nodules in the tissues around, and the nearest glands contained caseous nodules. The pleura was extensively covered with flat caseous growths, the diaphragm was uniformly thickened and caseating, and there was a large mass of caseating substance between the heart and the spinal column. The lungs were adherent to the chest wall and were crepitant; they contained fairly numerous caseous tubercles, a few caseous nodules and some red solid areas with caseous foci; there were caseous areas in the thin margins. The kidneys showed a moderate number of small caseous nodules, the spleen three calcareous tubercles, the omentum numerous tubercles, and one mesenteric gland a caseous nodule.

RABBITS INOCULATED WITH CULTURES FROM LUPUS VIRUSES—*continued.*

SUBCUTANEOUS INOCULATIONS—*continued.*

Virus.	Immediate Source of Culture.	Total Duration of Artificial Cultivation.	Dose in Milli-grammes.	Number of Rabbit.	Weight in Grammes.		Duration of Life.	Result.
					Initial.	Final.		
H. 100. "R.S."—*continued.*	Original material through G.P. 2929.	320 days	10·0 mg.	2127	1,400	1,300	Died 133 days	General tuberculosis. The local lesion was large nodular caseous and softened. The nearest glands were enlarged and beset with caseous nodules. The lungs showed on the surface extensive patches of confluent caseous nodules and elsewhere more or less discrete nodules ; similar nodules less numerous and all discrete were seen in the depth. Moderately numerous tubercles were seen on the surface of the kidneys the larger ones (2 mm.) caseous, and a caseous streak or two was seen on section. The tracheal glands were enlarged and oedematous and one contained caseous tubercles.
			10·0 mg.	2128	1,350	1,150	Died 145 days	General tuberculosis. The local lesion was a partially emptied caseous abscess discharging pus. The adjacent glands were caseous. The lungs were very large and composed of large yellow caseous coalescing masses with small areas of congested crepitant lung tissue in between. The tracheal glands were partly caseous. In the cortex of each kidney there was a moderate number of nodules up to a small pea in size, the larger grey with caseous centres, the smaller translucent. On the pleurae there were several firm flattened caseating nodules. A few caseous tubercles were seen in the areolar tissues.
	Original material through G.P. 2931.	148 days	10·0 mg.	1977	1,300	1,220	Died 91 days	General tuberculosis. There was a thin-walled cyst at the seat of inoculation and the nearest glands were enlarged caseous and gritty. The lungs were extensively consolidated being composed of grey coalescing areas containing small yellow caseous patches ; only a small amount of crepitant lung tissue remained. There were two flat grey nodules on the heart and a few small caseous patches in the bronchial glands. The cortices of the kidneys were closely beset with projecting grey nodules up to a hemp seed in size showing slight central caseation. The spleen and liver were normal.
H. 105. "G.S."	Original material through G.P. 2950.	60 days	10·0 mg.	1893	1,100	2,300	Killed 152 days	Chronic progressive general tuberculosis. There was a very large thin-walled cyst filled with creamy caseo-pus at the seat of inoculation, and the right scapular gland was enlarged and occupied by softened caseous nodules. The lungs were crepitant and contained scattered grey tubercles the larger with caseous centres and a few irregular caseous nodules with grey margins ; a few caseating patches were seen in the thin margins of the lungs. The kidneys contained in the cortex moderately numerous grey nodules the majority with caseous centres ; some extended into the medulla as caseous streaks. There were a few small tubercles on the pleura, and two tubercles in the liver.

			1·0 mg.	1894	1,050	2,320	Killed 152 days	General progressive tuberculosis. There was a thin-walled cyst containing curdy caseo-pus at the seat of inoculation; the right scapular gland was partly caseo-calcareous. The lungs were filled with firm irregular caseous slightly gritty nodules with grey margins in many places confluent; the intervening lung tissue was crepitant. The kidneys showed a moderate number of grey nodules up to a hemp seed in size some projecting on the surface, and also three very large projecting wedge-shaped nodules composed of grey tissue with caseous streaks. There was one tubercle on the pericardium and one on the pleura.
	"	144 days	10·0 mg.	1971	1,750	1,250	Died 162 days	Local tuberculosis and tuberculosis of lungs and kidneys. Death probably from nasal obstruction. There was a small caseous local lesion, and one scapular gland was slightly enlarged and caseous. The lungs were crepitant and contained moderately numerous discrete miliary caseous tubercles and a number of irregular caseating masses, and portions of the anterior lobes were solid and caseating. The kidneys showed on the surfaces large slightly depressed reddish areas, in the cortices a moderate number of caseating tubercles were seen; one kidney showed also on section two wedge-shaped caseous areas extending to the apex of a papilla.
			10·0 mg.	1972	1,470	1,150	Died 111 days	Slight general tuberculosis, insufficient to account for death. There was a thin-walled cyst at the seat of inoculation. The nearest glands appeared normal. The lungs showed some small caseous patches in the margins and scattered tubercles some grey, others caseous, elsewhere. Each kidney contained a single grey tubercle. The right elbow-joint showed early tuberculosis.
H. 53. "D.H." (*b*)	Original material through G.P. 3216.	120 days	10·0 mg.	2125	1,320	1,220	Died 56 days	There was a large caseous and softened local lesion, and the nearest gland showed caseous patches. Part of the anterior lobes of the lungs was solid, being composed of grey patches with caseous foci; elsewhere in the lungs a moderate number of grey nodules containing caseous foci were seen. In the cortex of each kidney a moderate number of grey tubercles with caseous centres was seen. There was no tuberculosis elsewhere, and the cause of death was not apparent.
			10·0 mg.	2126	1,930	1,150	Died 44 days	There was a moderately large flat caseous local lesion, and one scapular gland contained a caseous focus. The lungs contained scattered tubercles up to a millet seed in size, the larger being caseous. Each kidney showed scattered grey miliary tubercles. There was no tuberculosis elsewhere, and the cause of death was not apparent.
	"	190 days	5·0 mg.	2249	1,650	1,350	Died 81 days	Slight generalised tuberculosis, insufficient to account for death. There was a caseous ulcerated local lesion, and the nearest glands contained caseous nodules. The lungs showed in the thin margins scattered caseous nodules, and elsewhere a few caseating tubercles. The spleen was enlarged and the Malpighian bodies prominent. One kidney contained half a dozen caseating nodules (up to 2·5 mm.). There was no tuberculosis elsewhere.
			1·0 mg.	2248	2,000	2,520	Killed 201 days	The local lesion was a thin-walled cyst containing caseo-pus; the scapular glands were enlarged, cystic, and filled with mucinous fluid. In the thin margins of the lungs were a few reddish-grey and calcareo-caseous tubercles and four small fibro-caseo-calcareous patches. No tuberculosis elsewhere.

RABBITS INOCULATED WITH CULTURES FROM LUPUS VIRUSES—*continued.*

SUBCUTANEOUS INOCULATIONS—*continued.*

Virus.	Immediate Source of Culture.	Total Duration of Artificial Cultivation.	Dose in Milli-grammes.	Number of Rabbit.	Weight in Grammes.		Duration of Life.	Remarks.
					Initial.	Final.		
H. 53. "D.H." (*b*) —*continued.*	Original material through G.P. 3218.	94 days	10·0 mg.	2172	1,370	1,100	Died 95 days	General tuberculosis. The local lesion was large firm and caseous, and the adjacent glands were caseous and softened. The lungs were partly crepitant; their surfaces were beset with small tubercles becoming confluent and irregular caseo-necrotic patches, and the free margins were firm and necrotic; section showed moderately numerous caseous tubercles and nodules up to 3mm. in diameter. The bronchial glands were enlarged and contained caseous nodules. In the spleen one yellowish tubercle was seen. The kidneys were studded with raised tubercles and nodules (up to 3 mm.) the majority yellowish-white; a few caseous tubercles and streaks were seen on section. Caseous miliary tubercles were seen on the omentum and peritoneum, and the abdominal lymph glands contained caseous nodules. There were caseous nodules in the small intestine, caecum and colon (smear, T.B. very numerous).
			10·0 mg.	2173	1,520	1,050	Died 111 days	Generalised tuberculosis, moderately severe in lungs. There was a large firm nodular caseous local lesion; the nearest glands were beset with caseous foci and one was also partly cystic. The lungs contained a fair quantity of crepitant tissue; in the thin margins were irregular firm caseous patches; elsewhere moderately numerous nodules with grey margins and caseous centres were seen, in places aggregated together. The bronchial glands were much enlarged and caseous. In the cortex of each kidney there was a moderate number of miliary caseous tubercles and two grey nodules with caseous foci, and in the depth several caseous streaks. There was no tuberculosis elsewhere.
H. 107. "H.H."	Original material through G.P. 2955.	63 days	10·0 mg.	1895	1,500	900	Died 38 days	Early slight general tuberculosis. Death due to injuries. There was a large local ulcer and the adjacent scapular gland was large and caseous. The lungs and kidneys contained sparsely scattered submiliary grey tubercles with caseous centres. There were a few caseous foci in the bronchial glands.
			10·0 mg.	1896	1,200	1,050	Died 49 days	This rabbit also died of injuries, inflicted by companion rabbits, and showed lesions similar in character and extent to those of Rabbit 1895.
	"	170 days	10·0 mg.	1995	1,550	1,100	Died 165 days	Chronic general tuberculosis. The tumour at the seat of inoculation was caseous, and the adjacent glands were caseous and softened. The thin margins of the lungs were firm and caseating forming an almost continuous band, in the rest of the lungs were scattered tubercles mostly grey some caseous. The right kidney showed on the surface four grey patches with caseous foci, each of which extended inwards to the apex of a papilla as a caseous wedge, and there was caseous substance in some of the calyces; besides the large patches a few smaller nodules were seen. The left kidney was similarly but less severely affected. The single testicle that remained was slightly enlarged and caseous throughout; the epididymis was also caseous.

			10·0 mg.	1996	1,450	1,100	Died 18 days	There was a caseous local lesion and early caseation of the nearest glands only. Death resulted from injuries inflicted by companion rabbits.
H. 108. "H.R."	Original material through G.P. 2957.	57 days	10·0 mg.	1874	1,100	1,150	Killed 155 days (when ill).	Slight chronic general tuberculosis. There was a small fibro-caseous local lesion, and the adjacent glands were enlarged and composed of dry caseous gritty substance. The lungs contained scattered caseous tubercles and nodules; the latter were irregular, and apparently formed by aggregations of tubercles; the thin margin of one lobe was caseous. There were three or four caseous tubercles in the cortex of each kidney, and a few caseous streaks in the medulla of one. The bronchial glands contained a few calcareo-caseous tubercles. Other organs and glands were normal.
			10·0 mg.	1875	850	650	Died 90 days	General tuberculosis not severe. There was a large caseous ulcerated local lesion, and the nearest glands were enlarged and caseous throughout. The lungs contained small tubercles evenly distributed and not very caseous; the bronchial glands were beset with caseous tubercles. The spleen contained a dozen or more pinhead-sized caseous tubercles. There were numerous firm caseating nodules up to a hemp seed in size in the cortex of each kidney, the larger ones projecting on the surface; there were a few caseous tubercles also in the medulla. One or more discrete caseous tubercles were seen in most of the lymphatic glands, and there were tubercles in the marrow of the ribs.
	"	170 days	10·0 mg.	1997	1,070	1,450	Died 159 days	Slight retrogressive generalised tuberculosis; death from other causes. The local lesion was the size of a hen's egg, caseous and softened; the adjacent scapular glands were enlarged and caseo-calcareous; the left tracheal gland was similar; the right was less affected. The lungs showed a few caseous gritty patches in the thin margins and elsewhere scattered caseous gritty tubercles. The kidneys showed on the surface scattered gritty caseous miliary tubercles and in the depth small caseous nodules; on the surface of each there was also a grey nodular patch with caseous foci, which extended inwards as a wedge becoming more caseous towards the apex.
			10·0 mg.	1998	1,070	850	Died 85 days	Slight general tuberculosis; death was probably due to septic absorption from the local lesion, which was a large ulcerated cyst containing foul-smelling pus. The nearest glands were enlarged and partly caseous. The lungs contained a few tubercles up to 1 mm., the larger with minute caseous centres. There were scattered caseous tubercles up to a millet seed in size in the kidneys; the spleen contained two.
H. 53. "D.H." (a)	Original material through G.P. 1482.	594 days	10·0 mg.	956	3,000	2,600	Killed 90 days	Slight generalised tuberculosis. There was a very large caseous and softened tumour at the seat of inoculation, and the adjacent glands were large and caseo-purulent. The lungs contained not very numerous grey tubercles, the larger caseous in the centre, and two irregular grey caseating patches. There were about nine small grey tubercles in the kidneys. The bronchial glands contained one or two minute caseous foci. The left epididymus contained a caseous and softened nodule (T.B. exceedingly numerous) and the right six miliary caseous tubercles.

RABBITS INOCULATED WITH CULTURES FROM LUPUS VIRUSES—*continued.*

SUBCUTANEOUS INOCULATIONS—*continued.*

Virus.	Immediate Source of Culture.	Total Duration of Artificial Cultivation.	Dose in Milli-grammes.	Number of Rabbit.	Weight in Grammes.		Duration of Life.	Result.
					Initial.	Final.		
H. 53. "D.H." (*a*) —*continued.*	Original material through G.P. 1482.	594 days	10·0 mg.	957	2,700	1,950	Died 346 days	Chronic general tuberculosis. There was a baggy pendulous local tumour composed of two cysts filled one with caseo-pus, the other with turbid fluid. The adjacent scapular gland contained a caseous tubercle. The lungs contained scattered caseous nodules with grey margins up to 4 mm. in diameter. On the pleura there were caseous tubercles and several loosely attached caseous nodules. The omentum showed rather numerous translucent tubercles. The liver contained three or four tubercles with soft yellow centres. Each kidney showed on the surface a large irregular scar from which a wedge of tuberculous tissue extended inwards to the papilla, and about half-a-dozen grey tubercles; one contained also a caseous nodule. Two or three of the abdominal glands contained a few caseous foci. Both eyes were almost completely disorganised by tuberculous lesions, and the lachrymal glands were enlarged and extensively caseous.
			1·0 mg.	958	2,450	2,860	Died 76 days	Very slight generalised tuberculosis: the cause of death was not apparent. There was a thin-walled cyst with caseo-purulent contents at the seat of inoculation, and the right axillary gland showed a large cavity filled with mucoid fluid and caseous flakes. The left axillary gland contained a small caseous nodule. The lungs and kidneys contained one or two grey tubercles each.
	"	688 days	10·0 mg.	1094	1,190	1,200	Died 312 days	Chronic general tuberculosis. The local tumour was nodular hard and ulcerated on the surface, and composed of dry caseous substance in a fibrous wall. One scapular gland was a cyst filled with caseo-pus, the other contained soft caseous nodules. The caudal lobes of the lungs contained scattered caseo-purulent gritty nodules up to a small pea in size, and the ventral margin of one cephalic lobe was dense caseous and gritty; small grey fibrous tubercles were scattered throughout the substance of the lungs. One kidney contained two or three minute grey tubercles and fine caseous streaks, the other one minute tubercle only. The wall of the appendix and the termination of the ileum contained a number of miliary caseous gritty tubercles (smear, T.B. numerous). On the right side of the knee not apparently involving the joint there was a granulation-tissue tumour containing caseous foci, and under the tendon of the quadricepsa small caseous nodule (smear, a few T.B.).
			10·0 mg.	1095	1,120	1,370	Died 86 days	Local tuberculosis only; death from pseudo-tuberculosis. There was a very large ulcerated caseous tumour at the seat of inoculation in the back; continuous with it there was a similar but smaller tumour situated posterior to the humerus on the left side, which probably included the left axillary gland. The right axillary gland was almost completely caseous; one pectoral gland contained caseous patches. The organs showed pseudo-tuberculous lesions.

	"	1,069 days	10·0 mg.	1716	2,250	1,720	Died 7 days	Cellulitis.
			10·0 mg.	1717	2,420	1,450	Died 84 days	Chronic general tuberculosis. Death was caused probably by septic absorption from the local lesion, which was very large, caseous and foul-smelling; the skin over it was replaced by a dry scab. The scapular glands were almost entirely caseous and softened. The lungs contained not very numerous miliary caseous tubercles. The liver contained sparsely scattered greyish-white tubercles (smear. no T.B.). Each kidney contained a moderate number of caseous tubercles, those in the cortex projected and the larger ones were caseous throughout, and some were elongated. The portal gland contained two or three calcareous grains, and there were a few caseous tubercles on the mesentery and meso-colon.
H. 85. "H.B."	Original material through G.P. 2363.	83 days	10·0 mg.	1476	1,070	2,300	Killed 153 days (paralysed).	Slight chronic general tuberculosis. The local lesion was composed of an aggregation of caseous nodules; one scapular gland was caseous and gritty throughout, the other contained caseo-calcareous tubercles. The lungs contained each a dozen or more firm irregular caseous nodules up to 8 mm. in diameter. There was a caseous tubercle in one kidney, and a doubtful grey point in the other. The paralysis of the hind quarters was found to be due to softening of the lower part of the spinal cord (not tuberculous).
	"	244 days	40·0 mg.	1705	1,370	840	Died 157 days	Chronic general tuberculosis not severe. There was a large lobulated tumour containing dry cheesy caseous substance at the seat of inoculation. The scapular and axillary glands contained caseous gritty nodules. The glands just within the entrance to the thorax were much enlarged and closely beset with caseous gritty tubercles, often confluent. The lungs contained sparsely scattered caseous tubercles up to a pinhead in size. The kidneys showed on the surface numerous small pits and an occasional focus: in the medullae scattered grey tubercles with caseous centres and caseous streaks were seen; the calyces of one kidney contained caseo-pus. There were scattered miliary caseous tubercles in the areolar tissues of the groin and axilla.
	Original material through G.P. 2365.	98 days	20·0 mg.	1498	1,330	920	Died 34 days	Slight generalised tuberculosis; the cause of death was not apparent. There was a large caseous local tumour broken down in the centre, and the left scapular gland was caseous; other glands in the neighbourhood contained patches of caseous foci. The lungs were congested, and showed here and there a reddish tubercle; one millet-seed sized tubercle was seen in the spleen. No definite tubercles were seen elsewhere. Smears were examined from the substance of the liver (no T.B.) and the spleen (a few T.B.).
	"	189 days	10·0 mg.	1593	1,140	1,150	Died 49 days	Slight generalised tuberculosis; death was due to secondary infection of the local lesion, which consisted of a very large caseous ulcer from the margins of which fibrino-purulent substance extended along the sides of the thorax. The nearest glands contained caseous nodules. The lungs were crepitant and contained small grey tubercles, and one thoracic gland showed a caseous patch. The spleen contained some small greyish-white patches and tubercles, and there were small whitish tubercles in the liver; the kidneys showed scattered miliary tubercles, the largest caseous in the centre. A smear from the spleen showed a few T.B.

RABBITS INOCULATED WITH CULTURES FROM LUPUS VIRUSES—*continued.*

SUBCUTANEOUS INOCULATIONS—*continued.*

Virus.	Immediate Source of Culture.	Total Duration of Artificial Cultivation.	Dose in Milli-grammes.	Number of Rabbit.	Weight in Grammes.		Duration of Life.	Result.
					Initial.	Final.		
H. 85. "H.B."—*continued.*	Original material through G.P. 2365.	189 days	10·0 mg.	1594	1,600	1,950	Died 96 days	Very slight generalised tuberculosis; death was probably the result of secondary infection of the local lesion, which was a large tense cyst filled with foul-smelling caseo-pus; the skin over it showed a small opening covered with dried discharge. The adjacent scapular gland contained two caseo-purulent nodules. The lungs showed on the surface sparsely scattered grey tubercles, the largest containing minute caseous foci. There was no tuberculosis elsewhere. A smear from the pus from the local lesion showed a few T.B. and numerous other organisms.
	,,	218 days	16·0 mg.	1652	2,090	1,810	Killed 72 days	Slight generalised tuberculosis. The rabbit was killed on account of the very foul-smelling local lesion; in spite of the latter the animal appeared in fairly good general condition. The local lesion was nodular, ulcerated on the surface, and composed of caseous nodules partially broken down into watery casec-pus, and was exceedingly foul. The adjacent glands were much enlarged, and partially replaced by caseo-purulent areas. The lungs contained very sparsely scattered tubercles up to a millet seed in size, the larger caseous in the centre. Each kidney showed in the cortex half-a-dozen submiliary caseous tubercles with grey margins.
H. 111. "S.E."	Original material through G.P. 3009.	51 days	10·0 mg.	1918	1,300	1,700	Died 136 days	Chronic slight general tuberculosis. Death appeared to be due to an internal hernia. There was a large thin-walled cyst filled with caseo-pus at the seat of inoculation, and the adjacent scapular gland was caseous throughout. The lungs were crepitant and contained fairly numerous minute grey tubercles and a few larger ones with caseous centres; there was also one grey caseating patch. The bronchial glands and spleen contained each a few caseous tubercles. The kidneys contained a moderate number of small tubercles with caseous centres and grey margins.
			8·0 mg.	1919	1,300	2,900	Killed 207 days	Very slight generalised tuberculosis. There was a softened caseous mass at the seat of inoculation the size of a thrush's egg. The nearest scapular gland contained a small cyst filled with watery fluid and two calcareous foci. Three greyish tubercles were seen on the pleura. The left kidney showed two grey miliary tubercles and two grey nodules containing caseous points; the right showed two grey miliary tubercles. There was no tuberculosis elsewhere.
	,,	91 days	10·0 mg.	1936	1,850	2,050	Killed 167 days	Chronic general tuberculosis, not severe, and not obviously progressing. There was a thin-walled cyst filled with caseo-pus at the seat of inoculation. The adjacent scapular gland contained a softened caseous nodule. The lungs contained not very numerous tubercles up to 1 mm. the larger with caseous centres. The spleen was enlarged and showed a group of soft caseous tubercles. Each kidney showed in the cortex a moderate number of nodules

			About 2·5 mg.	1937	1,400	1,200	Died 138 days	(up to 3 mm.) the larger with firm caseous centres, and in the medulla a few caseous nodules; in the left kidney there was also a peasized caseous nodule and near it two smaller grey nodules containing caseous foci, from these a wedge-shaped area composed of firm caseous streaks extended into the medulla. General tuberculosis. The local tumour was an irregular dry cheesy mass; the adjacent glands were partly caseous and softened. The lungs contained a moderate number of caseous tubercles and the thin margins were in places solid showing caseous foci. The bronchial glands were enlarged and each showed a caseous patch. The liver contained fairly numerous just visible foci. The cortex of each kidney was closely beset with caseous nodules, the larger ones projecting slightly on the surface; there were a few in the medullae. The right knee joint was swollen and contained caseo-pus; the left showed early tuberculosis; the right elbow joint was similar to the right knee, but was less severely affected. A few caseous tubercles were seen in the meso-colon. The spleen was normal.
H. 91. "H.S."	Original material through G.P. 2590.	82 days	50·0 mg.	1686	2,400	2,350	Killed 235 days	There was a cyst containing thick caseo-pus at the seat of inoculation; in the calyces of one kidney there was some whitish caseo-pus. All other organs and the glands were normal.
			10·0 mg.	1689	870	2,150	Killed 235 days	There was a healed ulcer at the site of inoculation and a puckered scar and small caseous nodule in the subcutaneous tissues. In the lung there were two tubercles, one the size of a millet seed and caseo-calcareous, the other small and grey. All other organs and the glands were normal.

(*b*) **With the cultures which grow luxuriantly.**

H. 99. "L.K."	Original material through G.P. 2927.	28 days	50·0 mg.	1814	2,150	1,550	Died 89 days	General tuberculosis. There was a very large caseous and softened local tumour; the adjacent glands were large, caseous, and softened. The lungs were rather closely beset with fibro-caseous nodules. There were one or two caseous foci in the kidneys. The spleen was enlarged, but showed no tubercles.
			35·0 mg.	1815	1,830	1,950	Killed 144 days	There was an ulcerated tumour at the seat of inoculation composed of large caseous softened nodules with thick fibrous capsules. The lungs showed scattered caseous gritty tubercles and a few grey nodules, tuberculous patches here and there in the thin margins, and some superficial fibro-caseo-calcareous patches on the dorsal borders of the caudal lobes. There was no tuberculosis elsewhere.
H 92. "D.N."	Original material through G.P. 2592.	64 days	10·0 mg.	1632	1,100	2,650	Killed 258 days	There were several small flattened cysts with thin yellow purulent contents and fibrous walls at the seat of inoculation, and also several small caseous nodules. The adjacent scapular gland was slightly enlarged, and showed two soft caseous patches. There was no tuberculosis elsewhere.
	Original material through G.P. 2593.	64 days	50·0 mg.	1634	1,120	2,650	Killed 258 days	There was a flattened lobulated tumour filled with thick caseo-pus at the seat of inoculation, and no tuberculosis elsewhere.
			22·0 mg.	1633	1,220	1,650	Died 208 days	The tumour at the seat of inoculation was large, caseous, and softened. The scapular glands were enlarged, but not caseous. There was a small caseous patch at the tip of each cephalic lobe of the lungs, and a caseous streak in the cortex of one kidney. The cause of death was not apparent.

RABBITS INOCULATED WITH CULTURES FROM LUPUS VIRUSES—*continued.*

SUBCUTANEOUS INOCULATIONS—*continued.*

Virus.	Immediate Source of Culture.	Total Duration of Artificial Cultivation.	Dose in Milli-grammes.	Number of Rabbit.	Weight in Grammes.		Duration of Life.	Result.
					Initial.	Final.		
H. 109. "M.W."	Original material through G.P. 3002.	50 days	1·0 mg.	1914	940	2,970	Killed 145 days	There was a thin-walled flattened space lined internally with granulation tissue and containing only a few calcareous grains at the seat of inoculation, and no tuberculosis elsewhere.
			1·0 mg.	1915	940	2,620	Killed 145 days	As in Rabbit 1914.
	"	95 days	50·0 mg.	1938	1,950	2,900	Killed 144 days	There was a caseous and softened nodular local lesion; the nearest scapular gland was twice the normal in size but was not caseous. The lungs contained about a dozen nodules caseous and slightly gritty in the centre with fibrous margins, the largest a little larger than a hemp seed. There were a few tubercles on the mediastinal pleura and one kidney showed two grey tubercles in the cortex.
			10·0 mg.	1939	2,350	3,050	Killed 144 days	There was a thin-walled cyst the size of a pigeon's egg with thick caseous contents at the seat of inoculation, and no tuberculosis elsewhere.
H. 112. "B.B."	Original material through G.P. 3042.	63 days	10·0 mg.	1944	2,200	2,750	Killed 146 days	There was a cyst the size of a pheasant's egg at the seat of inoculation filled with thick caseo-pus, and no tuberculosis elsewhere.
			10·0 mg.	1945	1,550	2,170	Killed 146 days	There was a baggy thin-walled lobular cyst about the size of a hen's egg at the seat of inoculation filled with creamy caseo-pus, and no tuberculosis elsewhere.
H. 71. "L.V." (*a*)	Original material through G.P. 1937.	78 days	50·0 mg.	996	1,310	2,500	Killed 188 days	There was a cyst the size of a pigeon's egg filled with creamy caseo-pus at the seat of inoculation, and the adjacent gland contained a small group of calcareous grains. There was no tuberculosis elsewhere.
			10·0 mg.	997	1,610	2,600	Killed 188 days	At the seat of inoculation there was a group of caseo-purulent nodules surmounted by a dry ulcer and the adjacent glands contained a few calcareous grains. There was no tuberculosis elsewhere.
H. 71. "L.V." (*b*)	Original material through G.P. 3021.	63 days	66·0 mg.	1928	1,250	2,020	Killed 161 days	There was a cyst with thick fibrous wall and caseous contents at the seat of inoculation; the left scapular gland was caseo-calcareous; the right contained a caseo-calcareous nodule. In the lung one miliary calcareous tubercle was seen. There was no tuberculosis elsewhere.
			10·0 mg.	1929	1,370	2,800	Killed 161 days	There was a thin-walled cyst filled with caseo-pus at the seat of inoculation, and no disease elsewhere.
H. 101. "E.G."	Original material through G.P. 2932.	56 days	20·0 mg.	1888	1,000	2,150	Killed 144 days	There was a thin-walled cyst filled with thick caseo-pus at the seat of inoculation, and the nearest scapular gland contained a group of calcareous foci. In the lung there was a large pea-sized nodule containing cavities filled with tenacious muco-purulent substance (smear, T.B. numerous). There was no disease elsewhere.
			10·0 mg.	1889	1,150	1,200	Died 27 days	At the seat of inoculation there was a tumour composed of thick creamy pus; the subjacent muscle was slightly infiltrated with tubercles. The axillary glands were normal. Death was due to causes other than tuberculosis.

	"	150 days	57·0 mg.	1978	1,550	3,250	Killed 160 days	There was a small caseo-purulent lesion at the seat of inoculation, the skin over which showed a small ulcer closed with a dry scab, and no sign of tuberculosis elsewhere.
H. 114. "A.U."	Original material	144 days	10·0 mg.	2011	1,970	2,000	Killed 112 days	There was a group of three caseous nodules the size of partridges' eggs at the seat of inoculation, and three grey tubercles and a small caseous softened nodule in the lungs; there was no tuberculosis elsewhere.
			10·0 mg.	2012	1,920	1,650	Died 42 days	There was a small cyst with softened caseous contents at the seat of inoculation, and one scapular gland was enlarged but not caseous. One grey tubercle was seen in the lung. The cause of death was not apparent.
H. 103. "N.S."	Original material through G.P. 2938.	70 days	31·0 mg.	1883	1,200	2,850	Killed 138 days	There was a small collection of caseo-pus in a thin fibrous capsule at the seat of inoculation, and no disease elsewhere.
			10·0 mg.	1884	1,000	3,250	Killed 138 days	There was a thin-walled cyst with caseo-purulent contents at the seat of inoculation, and no disease elsewhere.
H. 106. "K.R."	Original material	91 days	50·0 mg.	1859	1,270	3,100	Killed 143 days	There were several caseo-purulent thin-walled cysts at the seat of inoculation, and no disease elsewhere.
	Original material through G.P. 2952.	38 days	50·0 mg.	1838	1,150	3,000	Killed 160 days	There was a cyst filled with caseo-pus at the seat of inoculation, and no disease elsewhere.
			20·0 mg.	1839	800	2,570	Killed 160 days	There was a very large thin-walled cyst filled with caseo-pus at the seat of inoculation, and no disease elsewhere.
H. 84. "M.S."	Original material through G.P. 2277.	62 days	47·0 mg.	1361	850	620	Died 4 days	Pseudo-tuberculosis.
			10·0 mg.	1362	1,000	570	Died 8 days	There was a small caseous patch at the site of inoculation, and the scapular glands were slightly enlarged. The cause of death was not apparent.
	"	102 days	1·0 mg	1416	1,050	1,650	Killed 100 days	There was a small collection of caseo-pus in the subcutaneous tissues of the back, a minute grey tubercle in one lung, and no tuberculosis elsewhere.
	"	313 days	56·0 mg.	1757	2,350	4,950	Killed 344 days	There was a cyst the size of a pullet's egg composed of caseo-purulent substance in a thin fibrous wall, and no tuberculosis elsewhere.
H. 102. "N.H."	Original material through G.P. 2934.	62 days	1·0 mg.	1879	950	2,810	Killed 139 days	There was a small thin-walled cyst filled with caseo-pus at the seat of inoculation, and no sign of tuberculosis elsewhere.
			1·0 mg.	1880	900	660	Died 15 days	There was a small local lesion, and slight psorospermosis of liver. The cause of death was not apparent.
	"	160 days	50·0 mg.	1979	2,210	3,200	Killed 160 days	There was a thin-walled cyst filled with caseo-pus at the seat of inoculation and one small tubercle in the lung, and no tuberculosis elsewhere.
			23·0 mg.	1980	2,110	1,650	Died 10 days	Death from an acute infection.
INTRAPERITONEAL INOCULATIONS.								
H. 53. "D.H." (*a*)	Original material through G.P. 1482.	208 days	10·0 mg.	627*	2,880	1,830	Died 18 days	Early tuberculosis of peritoneum and lungs, complicated by severe cysticercosis.
			1·0 mg.	628*	2,350	1,420	Died 29 days	Acute general tuberculosis.
			1·0 mg.	629*	2,450	1,440	Died 35 days	General tuberculosis.
			0·1 mg.	630*	1,720	1,420	Died 55 days	General tuberculosis.
	"	387 days	10·0 mg.	830*	990	910	Died 14 days	Early general tuberculosis.

* The rabbits marked with an asterisk were inoculated by Dr. Cobbett.

RABBITS INOCULATED WITH CULTURES FROM LUPUS VIRUSES—*continued.*

INTRAPERITONEAL INOCULATIONS—*continued.*

Virus.	Immediate Source of Culture.	Total Duration of Artificial Cultivation.	Dose in Milli-grammes.	Number of Rabbit.	Weight in Grammes.		Duration of Life.	Result.
					Initial.	Final.		
H. 53. "D.H." (*a*) —*continued.*	Original material through G.P. 1482.	387 days	1·0 mg.	831*	890	900	Died 46 days	There was severe tuberculous peritonitis. A moderate number of little dark translucent tubercles with caseating foci were seen in the lungs; the anterior parts of the lungs were solid and apparently carnified (? cause). The bronchial glands were caseous. There were some small tubercles, a few with caseous centres, in the kidneys. Some psorosperm nodules were seen in the liver. No T.B. were seen in smears from liver, spleen, or rib marrow; it is doubtful whether the tuberculosis was severe enough to account for death.
			0·1 mg.	832*	920	800	Died 74 days	General tuberculosis.
	"	594 days	1·0 mg.	953	2,700	1,520	Died 45 days	General tuberculosis.
			0·1 mg.	954	3,650	2,170	Killed 90 days	General tuberculosis. The omentum was thickened and fibroid and contained caseous tracts and discrete tubercles, and there were numerous shotty caseous tubercles with narrow grey margins on the peritoneum, mesentery, and meso-colon. The kidneys were enlarged and showed on the surface numerous scars and very numerous nodules from a pin's head up to a pea in size, they were caseous in the centre and some projected; on section the cut surface of the kidney showed caseous streaks. The calyces of the right were filled with caseo-pus; one calyx of the left kidney was similarly affected. The lungs were closely beset with caseous tubercles and irregular caseating patches; the fringes were hypertrophied and contained three or four caseous tubercles. The muscles in various parts of the body showed an occasional caseous tubercle. The portal gland showed two or three caseous foci.
H. 85. "H.B."	Original material through G.P. 2363.	83 days	1·0 mg.	1475	1,350	1,120	Died 41 days	General miliary tuberculosis.
	Original material through G.P. 2365.	98 days	10·0 mg.	1497	1,920	1,320	Died 35 days	General tuberculosis.
H. 71. "L.V." (*a*)	Original material through G.P. 1937.	78 days	10·0 mg.	994	1,460	970	Died 50 days	There was moderately severe tuberculous peritonitis. The lungs contained two grey tubercles, the spleen a few minute yellow tubercles, the liver rather numerous grey translucent tubercles. The kidneys showed numerous minute scars on the surface and fairly numerous tubercles in the cortex and medulla, the majority yellow and caseous throughout. The bronchial and several abdominal glands contained small caseous patches or a few caseous foci.
			1·0 mg.	995	1,350	1,850	Killed 188 days	The omentum contained a few caseo-calcareous tubercles and there were a few on the peritoneum. Both kidneys contained a few grey tubercles, in one of which there was a caseous focus.
H. 84. "M.S."	Original material through G.P. 2277.	62 days	10·0 mg.	1360	1,220	2,600	Killed 147 days	The great omentum and the gastro-splenic omentum contained a moderate number of caseo-calcareous nodules up to a hemp seed in size. There were one or two tubercles on the mesentery and meso-colon. No tuberculosis elsewhere.
	"	102 days	1·0 mg.	1415	1,200	2,450	Killed 100 days	There were about half-a-dozen small calcareous tubercles in the omentum, and no sign of disease elsewhere.

* The rabbits marked with an asterisk were inoculated by Dr. Cobbett.

INOCULATION EXPERIMENTS ON RHESUS MONKEYS.

RHESUS MONKEYS INOCULATED WITH CULTURES FROM LUPUS VIRUSES.

SUBCUTANEOUS INOCULATIONS.

Virus.	Immediate Source of Culture.	Total Duration of Artificial Cultivation.	Dose in Milli-grammes.	Number of Monkey.	Duration of Life.	Result.
				(*a*) With the cultures which grow like bovine tubercle bacilli.		
H. 110. "J.B." (*a*)	Original material through G.P. 3007.	59 days	1·0 mg.	183	Died 30 days	General tuberculosis.
	"	"	0·1 mg.	181	Died 26 days	General tuberculosis.
	"	"	0·01 mg.	179	Died 53 days	General tuberculosis.
H. 100. "R.S." ...	Original material through G.P. 2929.	69 days	1·0 mg.	163	Died 86 days	General tuberculosis not severe and apparently insufficient to account for death. There was a fibrous-walled cyst containing caseo-pus at the seat of inoculation, and several of the adjacent glands were slightly enlarged caseous and softened. The lungs contained fairly numerous grey tubercles, the larger with opaque centres. The omentum showed half-a-dozen caseous tubercles, the spleen a moderate number of small softened caseous nodules, the liver three caseous tubercles, the kidneys over a dozen small tubercles each. The thoracic and the portal glands contained caseous tubercles, and one gastric gland a caseous focus.
	Original material through G.P. 2931.	148 days	1·0 mg.	207	Died 26 days	Local tuberculosis with one or two disseminated lesions. Death was due to cold. There was a collection of caseo-pus at the seat of inoculation, and several of the adjacent glands were enlarged caseous and softened. One bronchial gland and the spleen contained each a caseous tubercle. Other organs and glands were normal.
	"	267 days	1·0 mg.	255	Died 48 days	Slight disseminated tuberculosis. The cause of death was not apparent. There was a prominent caseous tumour at the seat of inoculation, and some of the adjacent glands contained caseous foci or caseous patches. There were small sparsely scattered tubercles in the lungs, liver, and spleen, and one ileo-colic gland contained a caseous tubercle.
	"	"	1·0 mg.	257	Killed 25 days	There was a caseous and softened tumour at the seat of inoculation, and no tuberculosis elsewhere. The monkey was killed on account of the development of a gangrenous condition of the upper lip and gum.
H. 105. "G.S." ...	Original material through G.P. 2950.	60 days	1·0 mg.	175	Died 47 days	General tuberculosis.
	"	144 days	1·0 mg.	205	Died 56 days	General tuberculosis.
H. 53. "D.H." (*b*)	Original material through G.P. 3216.	120 days	1·0 mg.	265	Died 14 days	Small local lesion only. The cause of death was not apparent.
	"	"	1·0 mg.	267	Died 33 days	Slight generalised tuberculosis. The cause of death was not apparent. There was an ulcer at the seat of inoculation and the adjacent glands were slightly enlarged caseous and softened. The lungs and bronchial glands each contained a few caseous miliary tubercles. The liver and spleen each contained a moderate number of miliary tubercles, all were caseous in the former and a few in the latter organ. Three pancreatic glands contained caseous tubercles.
	"	190 days	1·0 mg.	289	Died 35 days	Local tuberculosis; tubercle bacilli in organs. Death was apparently caused by cold. There was an ulcer at the seat of inoculation and the adjacent glands were slightly enlarged and caseous. Tubercle bacilli were demonstrated in smears from the cerebral fluid, and from cut surfaces of the lung, liver and spleen.

	"	"	1·0 mg.	291	Died 34 days	Local tuberculosis and a few disseminated lesions. Death was probably caused by cold. There was a large abscess filled with caseous masses and caseo-pus; in the overlying skin there was a small opening discharging pus. The adjacent glands were moderately enlarged, caseous and softened. There were three small grey tubercles in the lungs and a few in the spleen (smear, numerous T.B.).
H. 107. "H.H."	Original material through G.P. 2955.	170 days	1·0 mg.	219	Died 20 days	Local lesion only. Death was probably due to cold. At the seat of inoculation there was a small cavity filled with caseo-pus. The adjacent glands were enlarged, but showed no sign of caseation.
	"	"	1·0 mg.	221	Died 26 days	Local lesion and two tubercles in the spleen. Death was probably due to cold. There was a cyst at the seat of inoculation containing caseo-pus. The adjacent glands were enlarged, but showed no sign of caseation. The spleen contained two grey miliary tubercles. Other organs and glands were normal.
	"	232 days	1·0 mg.	247	Died 49 days	Slight generalised tuberculosis; the cause of death was not apparent. There was an ulcer at the seat of inoculation, and the right axillary and two vertebral glands were enlarged and extensively caseous. The lungs contained sparsely scattered grey tubercles, the liver two, and one caseous tubercle, the spleen a moderate number of small softened caseous nodules and a few grey tubercles. One thoracic and one pancreatic gland contained caseous nodules.
	"	"	1·0 mg.	249	Died 13 days	Local lesion only. The cause of death was not apparent.
	"	"	1·0 mg.	251	Died 50 days	General tuberculosis of moderate severity. There was an ulcer at the seat of inoculation and the adjacent glands were moderately enlarged and showed varying degrees of caseation. The lungs were crepitant and contained fairly numerous tubercles up to a millet seed in size the larger with caseous centres. The spleen was slightly enlarged and contained moderately numerous small caseous nodules. The liver contained scattered opaque whitish tubercles; the kidneys a moderate number of grey tubercles; there was one caseous tubercle in the small intestine. The inter-bronchial, splenic, pancreatic, and one lumbar glands each contained one or more caseous tubercles. There were a few caseous tubercles and minute grey tubercles on the omentum, mesocolon, and mesentery.
H. 108. "H.R." ...	Original material through G.P. 2957.	57 days	1·0 mg.	165	Died 96 days	General tuberculosis.
H. 53. "D.H." (*a*)	Original material through G.P. 1482.	817 days	10·0 mg.	103	Died 23 days	The cause of death was not apparent. There was a caseous tumour at the seat of inoculation, and the adjacent glands showed early caseation. The organs appeared normal except the liver which showed a few grey foci. T.B. were fairly numerous in a smear from the liver, scanty in a smear from the spleen.
	"	902 days	10·0 mg.	109	Killed 32 days (when dying).	General tuberculosis.
	"	723 days	1·0 mg.	93	Died 105 days	Very slight generalised tuberculosis. The cause of death was not apparent. At the seat of inoculation there was an ulcerated and collapsed cyst. Two adjacent axillary glands were caseous and softened. The lungs contained a softened caseous nodule and half-a-dozen grey tubercles, and showed collapsed areas not very extensive; there were two small tubercles in the liver and one in the left kidney. The vertebral, left inguinal, ventral mediastinal, pharyngeal, and several abdominal glands were caseous and softened, or contained caseous tubercles. One small ulcer was seen in the ileum.
	"	817 days	1·0 mg.	101	Died 42 days	Very slight generalised tuberculosis Death probably due to septic ulcers at the neck caused by the collar. There was a small ulcerated caseo-necrotic tumour at the seat of inoculation. Two axillary and two cervical glands contained caseous nodules. Five grey tubercles were seen in the lungs, scattered miliary tubercles in the spleen, and one tubercle in one kidney. There were caseous tubercles in the portal gland, and one or more caseous foci in a pancreatic, a vertebral, and the bronchial glands.

RHESUS MONKEYS INOCULATED WITH CULTURES FROM LUPUS VIRUSES—*continued.*

SUBCUTANEOUS INOCULATIONS—*continued.*

Virus.	Immediate Source of Culture.	Total Duration of Artificial Cultivation.	Dose in Milli-grammes.	Number of Monkey.	Duration of Life.	Result.
H. 53. "D.H." (*a*)—*continued.*	Original material through G.P. 1482.	902 days	1·0 mg.	111	Died 41 days	Generalised tuberculosis, moderately severe in spleen, other organs very slightly affected. The local tumour was composed of breaking-down caseous substance. Several of the adjacent glands were caseous and softened throughout. The lungs contained half-a-dozen grey miliary tubercles. The spleen was closely beset with caseous miliary tubercles; the liver showed a few small grey tubercles, the kidneys two each. One portal, one splenic, and one bronchial gland contained one or two small tuberculous lesions.
	"	1069 days	1·0 mg.	137	Killed 92 days (when very ill).	General tuberculosis of moderate severity.
	"	"	0·1 mg.	135	Killed 209 days (when very ill).	General tuberculosis, severe in lungs, slight in abdominal organs. There was a caseous mass at the seat of inoculation. The axillary, one submaxillary, the vertebral and thoracic glands were very greatly enlarged, caseous and softened. The lungs were closely beset with grey tubercles confluent in the central parts, and in the anterior lobes showed also many irregular caseous nodules and areas. There was one tubercle in the spleen, there were a few in the kidneys; four transverse ulcers with caseous margins were seen in the small intestine; several abdominal glands showed varying degrees of caseation.
	"	"	0·01 mg.	129	Died 51 days	Local lesion only. The cause of death was not apparent. At the seat of inoculation there was a small tumour composed of breaking-down caseous substance. There was no tuberculosis elsewhere.
H. 85. "H.B." ...	Original material through G.P. 2365.	309 days	10·0 mg.	153	Killed 59 days (when ill).	Slight generalised tuberculosis. Illness probably due to secondary infection of the local lesion. There was a large foul ulcer at the seat of inoculation. The adjacent glands were enlarged, and contained caseous patches and nodules. The lungs showed sparsely scattered grey tubercles, and there were two minute tubercles in the right kidney. The Malpighian bodies of the spleen appeared to be enlarged, but there were no definite tubercles; a smear from the spleen showed numerous T.B.
	"	189 days	1·0 mg.	123	Died 132 days	General tuberculosis.
	"	"	0·1 mg.	121	Killed 97 days (when well).	Slight generalised tuberculosis. There was a cyst containing caseous substance and watery fluid at the seat of inoculation. One right axillary gland was much enlarged, and consisted of a thin-walled cyst with caseo-purulent contents; another, the size of a pea, was caseous. One vertebral gland was enlarged and caseous. Each lung contained about 40 small translucent tubercles and a few larger ones with caseous centres. A few caseo-purulent tubercles were seen in the portal and pancreatic glands, and a few foci (containing very numerous T.B.) in one or two mesenteric glands. The Malpighian bodies of the spleen were conspicuous, and a few T.B. were found in a smear from one.
	"	"	0·01 mg.	119	Died 271 days	Chronic general tuberculosis. There was a soft caseous mass at the seat of inoculation, the skin over which showed three small ulcers; near it was another subcutaneous caseous mass. The right axillary, cervical, and inguinal glands were greatly enlarged caseous and softened, and the vertebral glands adjacent to the lesion

						formed a large caseous mass. The bronchial and several abdominal glands showed varying degrees of caseation, some being severely affected. There were four caseous and softened nodules in the lungs and 20 in the spleen (up to 1·5 cm. in diameter). There was a moderate number of grey tubercle, in the liver, and one caseous tubercle in the small intestine.
H. 111. "S.E." ...	Original material through G.P. 3009.	51 days	1·0 mg.	189	Died 62 days	General tuberculosis.
	"	"	0·1 mg.	191	Killed 242 days (when well).	Chronic general tuberculosis. There was a small ulcer at the seat of inoculation, and a walnut sized caseo-purulent mass in the left axilla. One vertebral gland was much enlarged caseous and softened, another contained a caseous focus. The lungs contained seven caseous nodules (up to 3 mm.) and a few grey miliary tubercles; the liver showed scattered greyish-white foci; the spleen was slightly eularged and contained a moderate number of caseous and softened nodules, the largest 1 cm. in diameter, several of which projected prominently from the surface. One bronchial and one mesenteric gland contained each a caseous tubercle. In the left parietal bone of the skull there was a patch of caseo-necrosis, and in the brain there was a softened caseous nodule 1·5 cm. in diameter.
H. 91. "H.S." ...	Original material through G.P. 2590.	127 days	1·0 mg.	139	Killed 197 days (when in moderately good health).	Slight generalised tuberculosis with severe tuberculosis of one eye. There were several caseous nodules at the seat of inoculation, and the adjacent glands were much enlarged, caseous and softened. There were three small tubercles in the lung, eight softened caseous nodules in the spleen and three muco-purulent cysts in the liver. Many of the lymphatic glands contained caseous nodules. Behind the right eyeball there was a large caseo-purulent swelling and the eye was disorganised and filled with caseo-pus; another caseous nodule was situated just below the orbital ridge. There were four caseous nodules on the frontal bones of the skull, the bone below each being necrossed. Five caseous nodules and one soft grey nodule were seen on the pons.
	"	"	0·1 mg.	133	Killed 203 days (when well).	Chronic general tuberculosis. The lungs contained a moderate number of small yellowish nodules with grey margins, the spleen twenty caseous nodules, the liver three muco-purulent cysts two caseous nodules and four greyish tubercles, and each kidney half-a-dozen small caseous nodules. Most of the thoracic and abdominal glands were enlarged caseous and softened, others contained caseous nodules. There were twelve ulcers in the small intestine and a good many in the large intestine, they showed no sign of caseation. There was a caseous nodule in the brain and half-a-dozen foci of caseo-necrosis in the bones of the skull.

(*b*) With the cultures which grow luxuriantly.

H. 99. "L.K." ...	Original material through G.P. 2927.	28 days	1·0 mg.	147	Died 34 days	General tuberculosis.
	"	"	0·1 mg.	149	Died 50 days	General tuberculosis.
	"	"	0·01 mg.	151	Died 36 days	General tuberculosis.
H. 92. "D.N." ...	Original material through G.P. 2593.	210 days	1·0 mg.	177	Died 39 days	General tuberculosis.
H. 109. "M.W."	Original material through G.P. 3002.	50 days	0·1 mg.	185	Died 80 days	General tuberculosis of moderate severity.
	"	95 days	1·0 mg.	197	Died 30 days	General tuberculosis.

RHESUS MONKEYS INOCULATED WITH CULTURES FROM LUPUS VIRUSES—*continued.*

SUBCUTANEOUS INOCULATIONS—*continued.*

Virus.	Immediate Source of Culture.	Total Duration of Artificial Cultivation.	Dose in Milli-grammes.	Number of Monkey.	Duration of Life.	Result.
H 112. "B.B."	Original material through G.P. 3042.	63 days	1·0 mg.	201	Died 48 days	General tuberculosis.
	"	"	1·0 mg.	199	Died 45 days	Slight generalised tuberculosis. Death was due to cold. There was a firm caseated tumour at the seat of inoculation; one axillary gland was partly caseous and several vertebral glands showed a caseous focus or two. A very few minute grey tubercles were seen in the lungs and a moderate number of small grey tubercles in the spleen, the larger with yellowish centres. A pancreatic gland showed two whitish foci.
H 71. "L.V." (*b*)	Original material through G.P. 3021.	63 days	1·0 mg.	195	Died 36 days	General tuberculosis not severe, and apparently insufficient to account for death. There was a small ulcer at the seat of inoculation and the adjacent glands were moderately enlarged, caseous and softened. The lungs and spleen contained small scattered tubercles the larger caseous in the centre, the liver a moderate number of small caseous tubercles, the kidneys one or two tubercles each. Four caseous tubercles were seen in the bronchial glands and one on the omentum.
	"	"	0·01 mg.	193	Died 48 days	Local tuberculosis with a few disseminated lesions. Death was caused by cold. There was a small ulcer at the seat of inoculation and the adjacent glands were slightly enlarged, caseous and softened. There were four grey tubercles in the lungs, five small softened caseous nodules in the spleen and two in the liver; one pancreatic gland showed three minute caseous foci.
H. 101. "E.G."	Original material through G.P. 2932.	56 days	1·0 mg.	173	Died 77 days	Local tuberculosis with a few disseminated lesions; the cause of death was not apparent. There was a small ulcer at the seat of inoculation; two vertebral and one cervical glands were slightly enlarged caseous and softened; one small axillary gland was adherent to the skin, which was ulcerated at this point; another contained a caseous nodule. Half-a-dozen miliary caseous tubercles were seen in the lungs.
	"	150 days	1·0 mg.	211	Died 51 days	General tuberculosis.
	"	"	1·0 mg.	209	Died 24 days	Local tuberculosis with a few disseminated lesions; death from pneumonia. There was a thin-walled cyst containing caseo-pus at the seat of inoculation, an early caseous focus in each of two axillary glands, and one early tubercle in the liver and one in the spleen.
H. 114. "A.U."	Original material	144 days	1·0 mg.	223	Died 109 days	General miliary tuberculosis.
	"	"	1·0 mg.	225	Died 100 days	General tuberculosis; exposure to severe cold was the immediate cause of death. There was an ulcerated area at the seat of inoculation, and numerous caseous nodules were seen in the adjacent tissues. The adjacent glands were enlarged, and showed varying degrees of caseation and softening. The lungs contained scattered shotty caseous tubercles and nine caseous nodules, the largest 1 cm. in diameter; the bronchial glands were extensively caseated. The spleen was enlarged and closely beset with caseous softened nodules with thin fibrous walls. The liver contained a few greyish tubercles and two or three caseous nodules. In the kidneys there were a dozen tubercles the majority caseous, and one caseous nodule. The right pharyngeal and many abdominal glands showed varying degrees of caseation. The omentum contained a moderate number of translucent grey tubercles.

H. 103. "N.S."	Original material through G.P. 2938.	70 days	1·0 mg.	171	Died 111 days	Chronic general tuberculosis. There was a shallow ulcer at the seat of inoculation; the adjacent glands were much enlarged and caseo-purulent, the left vertebral glands forming a mass 4 cm. long, to which the left lung was adherent; this lung was almost completely airless, and composed of greyish areas and caseating patches. The right lung was crepitant and contained scattered tubercles. The spleen contained a moderate number of caseous and softened nodules, the liver three miliary tubercles, the kidneys a moderate number of caseous miliary tubercles. The bronchial and many abdominal glands contained occasional caseous tubercles, in several mesenteric and colic glands they were more numerous and confluent; the inguinal glands contained softened caseous nodules.
	"	175 days	1·0 mg.	217	Died 102 days	Slight generalised tuberculosis. Death was probably due to cold. There was an ulcer with caseo-necrotic floor at the seat of inoculation and the adjacent glands wer moderately enlarged caseous and softened; four glands in the thorax, and a pancreatic gland, were similarly affected. The spleen contained scattered grey miliary tubercles and about half-a-dozen caseous tubercles were seen in each kidney. The mesenteric glands contained scattered caseous tubercles. T.B. were seen in a smear from the mucous membrane of the small intestine.
H. 106. "K.R."	Original material through G.P. 2952.	38 days	1·0 mg.	155	Died 40 days	Early generalised tuberculosis insufficient to account for death, which was probably due to cold. There was a caseo-necrotic local tumour infiltrating skin and muscles, and containing a cavity filled with caseo-pus. The adjacent glands were enlarged caseous and softened, or contained caseous patches. The lungs contained sparsely scattered translucent grey tubercles, the spleen a moderate number of grey tubercles, the liver a few minute tubercles, each kidney two grey tubercles. The portal gland contained two greyish-white foci.
H. 84. "M.S." ...	Original material through G.P. 2277.	366 days	10·0 mg. (slightly less than).	117	Died 73 days	General tuberculosis not severe, and apparently insufficient to account for death. There was an ulcer at the seat of inoculation with fibrous floor showing no sign of caseation. The adjacent axillary and cervical glands were slightly enlarged and caseous, or contained caseous tubercles. The lungs contained sparsely scattered tubercles mostly grey and translucent, the spleen and liver a moderate number of small fibro-caseous nodules, one kidney a single caseous tubercle. There was an occasional caseous tubercle in the bronchial, three abdominal, and one submaxillary glands. The left tonsil contained a minute whitish focus (T.B.), the omentum a moderate number of tubercles.
		313 days	1·0 mg.	143	Died 110 days	Chronic general tuberculosis. There was a large local ulcer infiltrating the adjacent muscles; two glands in the right axilla and one submaxillary gland were very large, caseous and softened; other glands in the neighbourhood of the local lesion were affected, but less severely. The lungs contained scattered translucent tubercles; the spleen was enlarged and nodular, and showed numerous caseo-purulent nodules; the liver contained a few tubercles and many indefinite foci; each kidney showed about a dozen small tubercles, and one a caseous nodule also. There were five caseous nodules in the small intestine, one ulcerated, and numerous ulcers throughout the entire length of the large intestine (these showed no caseation, and were probably non-tuberculous in origin, but T.B. were numerous in a smear from the necrotic substance which was attached to most of them). Several of the thoracic and most of the abdominal glands showed varying degrees of caseation. There was a firm yellowish nodule on the cerebrum. Ten caseous nodules were seen in the vault of the skull, the bone around each being necrosed. In the muscles of the body three caseous nodules were found, and there was a large caseo-purulent mass under the peritoneum on the left side of the abdomen. One rib was swollen close to its head, and showed a cavity containing caseo-purulent substance. There was a tuberculous ulcer on the tongue, and the adjacent pharyngeal gland was large and muco-purulent.

RHESUS MONKEYS INOCULATED WITH CULTURES FROM LUPUS VIRUSES—*continued.*

SUBCUTANEOUS INOCULATIONS—*continued.*

Virus.	Immediate Source of Culture.	Total Duration of Artificial Cultivation.	Dose in Milli-grammes.	Number of Monkey.	Duration of Life.	Result.
H. 84. "M.S." —*continued.*	Original material through G.P. 2277.	313 days	0·01 mg.	141	Died 95 days	Local tuberculosis with a few disseminated lesions. The large intestine showed extensive non-tuberculous ulceration, which was probably the cause of death. There was a small caseous local tumour. Two axillary and one vertebral glands were slightly enlarged and caseous, or contained caseous tubercles. There was one tubercle in the lung, small caseous areas in the small intestine, and small caseous patches or foci in the mesenteric and one pancreatic glands.
H. 102. "N.H."	Original material through G.P. 2934.	62 days	1·0 mg.	169	Died 55 days	Local tuberculosis with a few disseminated lesions. The cause of death was not apparent. The tumour at the seat of inoculation was composed of breaking-down caseous substance enclosed in a thin fibrous wall; one axillary and one vertebral gland contained caseous tubercles. There was one tubercle in the lung, one in the liver, and one in the spleen.
	"	160 days	1·0 mg.	213	Died 156 days	Chronic general tuberculosis. Death from pneumonia. There was an aggregation of softened caseous nodules at the seat of inoculation; the right axillary and cervical glands were much enlarged caseous and softened; the vertebral glands adjacent to the local lesion formed a caseous and softened mass. The lungs contained scattered caseous and softened nodules with thin fibrous walls, and one mass (1 cm.) composed of aggregated nodules. The spleen contained about 20 softened caseous nodules up to 7 mm. in diameter; there were two or three similar nodules in the kidneys and about 20 in the liver, which also contained a few minute caseous tubercles. There was a caseating nodule and a softened caseous area (2·5 cm.) in the brain. The omentum showed a moderate number of small grey translucent tubercles. Several of the bronchial glands were much enlarged caseous and softened.
	"	"	1·0 mg.	215	Died 183 days	Severe chronic general tuberculosis. There was a small ulcer in the skin at the seat of inoculation, a flat caseous patch in the subcutaneous tissues, and caseous softened nodules in the subjacent muscles. The adjacent glands were much enlarged, caseous and softened. The costal pleura was covered with caseating tuberculous plaques and a small area of the diaphragm was thickened and entirely caseous. The lungs contained scattered firm caseous nodules (up to 5 mm.) and one large nodule 12 mm. in diameter. The omentum contained one caseous nodule and a number of translucent tubercles. The spleen was enormously enlarged and composed of large softened caseous nodules (up to 1 cm.), the liver contained a moderate number of similar nodules (up to 8 mm.) and scattered miliary tubercles, and the kidneys 3 or 4 caseous nodules each. The bronchial and many of the abdominal glands were affected, showing varying degrees of cascation and softening. Two caseous nodules were seen in the muscles.

INOCULATION EXPERIMENTS ON GUINEA-PIGS.

GUINEA-PIGS INOCULATED WITH CULTURES FROM LUPUS VIRUSES.

INTRAPERITONEAL INOCULATIONS.

Virus.	Immediate Source of Culture.	Total Duration of Artificial Cultivation.	Dose in Milligrammes.	Number of Guinea-pig.	Weight in Grammes.		Duration of Life.	Result.
					Initial.	Final.		
(*a*) With the cultures which grow like bovine tubercle bacilli.								
H. 110. "J.B." (*a*)	Original material through G.P. 3007.	59 days	1·0 mg.	3119	320	220	D. 21 days	General tuberculosis.
			0·1 mg.	3117	350	230	D. 17 „	Acute general tuberculosis.
H. 110. "J.B." (*b*)	Original material through G.P. 3290	59 days	0·1 mg.	3395	290	220	D. 16 „	Acute tuberculosis.
H. 100. "R.S."	Original material through G.P. 2929.	69 days	1·0 mg.	3048	220	200	D. 30 „	General miliary tuberculosis.
			0·1 mg.	3050	200	170	D. 43 „	General tuberculosis.
H. 105. "G.S."	Original material through G.P. 2950.	60 days	0·1 mg.	3078	450	300	D. 31 „	General tuberculosis.
H. 53. "D.H." (*b*)	Original material through G.P. 3216.	120 days	0·1 mg.	3432	400	300	D. 39 „	General tuberculosis.
	Original material through G.P. 3218.	94 days	0·1 mg.	3495	270	200	D. 23 „	General tuberculosis, not severe.
H. 107. "H.H."	Original material through G.P. 2955.	63 days	1·0 mg.	3081	320	190	D. 28 „	General tuberculosis.
			0·1 mg.	3083	370	350	D. 98 „	General tuberculosis.
H. 108. "H.R."	Original material through G.P. 2957.	57 days	1·0 mg.	3052	220	170	D. 34 „	General tuberculosis.
			0·1 mg.	3054	200	170	D. 44 „	General tuberculosis.
H. 53. "D.H." (*a*)	Original material through G.P. 1482.	688 days	1·0 mg.	2180	350	220	D. 18 „	General tuberculosis.
			0·1 mg.	2182	450	430	D. 38 „	General tuberculosis.
H. 85. "H.B."	Original material through G.P. 2363.	83 days	1·0 mg.	2574	200	220	D. 26 „	General tuberculosis.
	Original material through G.P. 2365.	98 days	1·0 mg.	2595	220	170	D. 14 „	General tuberculosis.
	„	189 days	0·1 mg.	2847	170	170	D. 40 „	General tuberculosis.
	„	218 days	1·0 mg.	2879	170	150	D. 17 „	General tuberculosis.
H. 111. "S.E."	Original material through G.P. 3009.	51 days	1·0 mg.	3125	550	330	D. 23 „	General tuberculosis
			0·1 mg.	3127	450	400	D. 79 „	General tuberculosis
H. 91. "H.S."	Original material through G.P. 2590.	82 days	1·0 mg.	2900	220	160	D. 21 „	Slight early general tuberculosis.
			0·1 mg.	2898	220	200	D. 19 „	Early general tuberculosis.

GUINEA-PIGS INOCULATED WITH CULTURES FROM LUPUS VIRUSES—*continued.*

INTRAPERITONEAL INOCULATIONS—*continued.*

Virus.	Immediate Source of Culture.	Total Duration of Artificial Cultivation.	Dose in Milligrammes.	Number of Guinea-pig.	Weight in Grammes. Initial.	Weight in Grammes. Final.	Duration of Life.	Result.
				(*b*) With the cultures which grow luxuriantly.				
H. 99. "L.K."	Original material through G.P. 2927.	28 days	1·0 mg.	3023	300	230	D. 16 days	General tuberculosis.
H. 92. "D.N."	Original material through G.P. 2592.	64 days	1·0 mg.	2860	140	120	D. 20 ,,	General tuberculosis.
H. 109. "M.W."	Original material through G.P. 3002.	50 days	1·0 mg.	3122	320	230	D. 24 ,,	General tuberculosis.
			0·1 mg.	3123	320	200	D. 53 ,,	General tuberculosis.
H. 112. "B.B."	Original material through G.P. 3042.	63 days	1·0 mg.	3183	390	220	D. 22 ,,	Early slight general tuberculosis. (Probably killed by rats.)
			0·1 mg.	3185	650	500	D. 23 ,,	Early general tuberculosis. (Probably killed by rats.)
H. 71. "L.V." (*a*)	Original material through G.P. 1937.	78 days	1·0 mg.	1989	250	200	D. 32 ,,	General tuberculosis.
			0·1 mg.	1991	320	210	D. 37 ,,	General tuberculosis.
H. 71. "L.V." (*b*)	Original material through G.P. 3021.	63 days	1·0 mg.	3147	370	230	D. 30 ,,	General tuberculosis.
H. 101. "E.G."	Original material through G.P. 2932.	56 days	0·1 mg.	3075	500	300	D. 35 ,,	General tuberculosis.
H. 114. "A.U."	Original material.	144 days	1·0 mg.	3276	300	205	D. 33 ,,	General tuberculosis.
			1·0 mg.	3277*	250	200	D. 36 ,,	General tuberculosis.
H. 103. "N.S."	Original material through G.P. 2938.	70 days	1·0 mg.	3059†	600	430	D. 142 ,,	Very slight general tuberculosis insufficient to account for death.
	Original material through G.P. 2940.	36 days	1·0 mg.	3035	450	320	D. 46 ,,	General tuberculosis.
H. 106. "K.R."	Original material through G.P. 2952.	38 days	1·0 mg.	3033	550	320	D. 45 ,,	General tuberculosis. (not severe).
H. 84. "M.S."	Original material through G.P. 2277.	62 days	1·0 mg.	2485	250	200	D. 50 ,,	General tuberculosis.
			0·1 mg.	2487	270	230	D. 59 ,,	General tuberculosis.
	,,	266 days	1·0 mg.	2896	250	190	D. 18 ,,	General tuberculosis, less severe than is usually produced by a human Group II. bacillus.
		,,	0·1 mg.	2894	200	170	D. 23 ,,	General tuberculosis, less severe than is usually produced by a human Group II. bacillus.
H. 102. "N.H."	Original material through G.P. 2934.	62 days	0·1 mg.	3057†	550	270	D. 47 ,,	Slight and apparently non-progressive tuberculosis confined to abdomen.
	,,	160 days	10·0 mg.	3231	300	250	D. 45 ,,	General tuberculosis.

* Partly subcutaneous. † For abstracts of the post-mortem notes of guinea-pigs asterisked *see* pages 114–115.

GUINEA-PIGS INOCULATED WITH CULTURES FROM LUPUS VIRUSES.

SUBCUTANEOUS INOCULATIONS.

Virus.	Immediate Source of Culture.	Total Duration of Artificial Cultivation.	Dose in Milligrammes.	Number of Guinea-pig.	Weight in Grammes. Initial.	Weight in Grammes. Final.	Duration of Life.	Result.
(*a*) With the cultures which grow like bovine tubercle bacilli.								
H. 110. "J.B." (*a*)	Original material through G.P. 3007.	59 days	1·0 mg.	3120	220	270	D. 35 days	General tuberculosis (severe).
			0·1 mg.	3118	320	380	D. 69 „	General tuberculosis (severe).
H. 110. "J.B." (*b*)	Original material through G.P. 3290.	59 days	0·1 mg.	3396	220	200	D. 37 „	General tuberculosis.
H. 100. "R.S."	Original material through G.P. 2929.	69 days	1·0 mg.	3049†	250	570	D. 284 „	General tuberculosis.
			0·1 mg.	3051†	220	410	D. 192 „	General tuberculosis.
H. 105. "G.S."	Original material through G.P. 2950.	60 days	1·0 mg.	3080	400	400	D. 188 „	General tuberculosis.
			0·1 mg.	3079	370	440	D. 138 „	General tuberculosis.
H. 53. "D.H." (*b*)	Original material through G.P. 3216.	120 days	0·1 mg.	3433	380	270	D. 82 „	General tuberculosis.
	Original material through G.P. 3218.	94 days	0·1 mg.	3496	200	120	D. 7 „	No apparent cause of death.
H. 107. "H.H."	Original material through G.P. 2955.	63 days	1·0 mg.	3082	300	370	D. 116 „	General tuberculosis.
			0·1 mg.	3084	220	350	D. 171 „	General tuberculosis; death was immediately due to pseudo-T. of the mesenteric glands.
H. 108. "H.R."	Original material through G.P. 2957.	57 days	1·0 mg.	3053	200	270	D. 82 „	General tuberculosis.
			0·1 mg.	3055	200	370	D. 159 „	General tuberculosis.
H. 53. "D.H." (*a*)	Original material through G.P. 1482.	688 days	1·0 mg.	2181	300	280	D. 63 „	General tuberculosis.
			0·1 mg.	2183	400	320	D. 75 „	General tuberculosis.
H. 85. "H.B."	Original material through G.P. 2363.	83 days	1·0 mg.	2575	200	450	D. 140 „	General tuberculosis.
	Original material through G.P. 2365.	98 days	1·0 mg.	2596	290	420	D. 86 „	General tuberculosis.
	„	189 days	0·1 mg.	2848	170	440	D. 123 „	General tuberculosis.
	„	218 days	1·0 mg.	2880	190	300	D. 56 „	General tuberculosis.
H. 111. "S.E."	Original material through G.P. 3009.	51 days	1·0 mg.	3126	500	350	D. 124 „	General tuberculosis.
			0·1 mg.	3128	420	210	D. 100 „	General tuberculosis.
H. 91. "H.S."	Original material through G.P. 2590.	82 days	1·0 mg.	2901	180	160	D. 40 „	General tuberculosis (not severe).
			0·1 mg.	2899	200	200	D. 73 „	General tuberculosis (not severe).
	„	127 days	1·0 mg.	2987	750	500	D. 24 „	Early general tuberculosis.
			1·0 mg.	2988†	790	470	D. 55 „	General tuberculosis.

† For abstracts of the post-mortem notes of guinea-pigs asterisked *see* pages 114–115.

GUINEA-PIGS INOCULATED WITH CULTURES FROM LUPUS VIRUSES—*continued.*

SUBCUTANEOUS INOCULATIONS—*continued.*

Virus.	Immediate Source of Culture.	Total Duration of Artificial Cultivation.	Dose in Milligrammes.	Number of Guinea-pig.	Weight in Grammes. Initial.	Weight in Grammes. Final.	Duration of Life.	Result.
(*b*) With the cultures which grow luxuriantly.								
H. 99. "L.K."	Original material through G.P. 2927.	28 days	1·0 mg.	3024	350	220	D. 27 days	Early general tuberculosis.
H. 92. "D.N."	Original material through G.P. 2952.	114 days	1·0 mg.	2969	500	350	D. 46 ,,	General tuberculosis.
			1·0 mg.	2970	770	480	D. 58 ,,	General tuberculosis.
H. 109. "M.W."	Original material through G.P. 3002.	50 days	1·0 mg.	3121	350	300	D. 136 ,,	Chronic general tuberculosis, not very severe.
			0·1 mg.	3124	220	350	D. 176 ,,	General tuberculosis.
H. 112. "B.B."	Original material through G.P. 3042.	63 days	1·0 mg.	3184	420	350	D. 100 ,,	General tuberculosis.
			0·1 mg.	3186	370	420	D. 141 ,,	General tuberculosis.
H. 71. "L.V." (*a*)	Original material through G.P. 1937.	78 days	1·0 mg.	1990	310	370	D. 67 ,,	General tuberculosis.
			0·1 mg.	1992	360	430	D. 86 ,,	General tuberculosis.
H. 71. "L.V." (*b*)	Original material through G.P. 3021.	63 days	1·0 mg.	3148	320	250	D. 71 ,,	General tuberculosis
H. 101. "E.G."	Original material through G.P. 2932.	56 days	1·0 mg.	3077	350	300	D. 119 ,,	General tuberculosis.
			0·1 mg.	3076†	400	600	D. 454 ,,	Chronic general tuberculosis.
H. 114. "A.U."	Original material.	144 days	1·0 mg.	3278	250	250	D. 139 ,,	General tuberculosis.
			1·0 mg.	3279†	300	500	D. 256 ,,	General tuberculosis.
H. 103. "N.S."	Original material through G.P. 2938.	70 days	1·0 mg.	3060	320	310	D. 134 ,,	General tuberculosis.
	,,	175 days	10·0 mg.	3263	250	310	D. 106 ,,	General tuberculosis.
			1·0 mg.	3262	200	470	D. 193 ,,	General tuberculosis.
	Original material through G.P. 2940.	36 days	1·0 mg.	3036	590	400	D. 129 ,,	General tuberculosis.
H. 106. "K.R."	Original material through G.P. 2952.	38 days	1·0 mg.	3034†	570	550	D. 574 ,,	Chronic general tuberculosis.
			0·1 mg.	3032†	400	400	D. 218 ,,	Local tuberculosis. Cause of death not apparent.
H. 84. "M.S."	Original material through G.P. 2277.	62 days	1·0 mg.	2486†	270	650	D. 855 ,,	General healed tuberculosis.
			0·1 mg.	2488	250	370	D. 257 ,,	Chronic general tuberculosis.
	,,	266 days	1·0 mg.	2897†	190	170	D. 39 ,,	General tuberculosis, less severe than is usually produced by a human Group II. bacillus.
			0·1 mg.	2895	150	170	D. 40 ,,	
	,,	313 days	1·0 mg.	2985	550	500	D. 223 ,,	General tuberculosis.
			1·0 mg.	2986†	500	700	D. 256 ,,	Chronic tuberculosis of an unusual type.
H. 102. "N.H."	Original material through G.P. 2934.	62 days	1·0 mg.	3056†	650	450	D. 504 ,,	Chronic general tuberculosis.
			0·1 mg.	3058†	270	390	D. 462 ,,	Chronic general tuberculosis.
	,,	160 days	10·0 mg.	3230†	310	290	D. 145 ,,	Chronic general tuberculosis.

† For abstracts of the post-mortem notes of guinea-pigs asterisked *see* pages 114 115.

ABSTRACTS OF POST-MORTEM NOTES OF GUINEAPIGS IN WHICH THE DISEASE PRESENTED UNUSUAL FEATURES.

2486.

There was no local lesion. In each groin there was a small sinus leading into a minute cavity, containing caseo-pus, and surrounded by fibrous tissue (all that remained of a gland); the other inguinal glands were fibroid; the axillary glands were enlarged and caseo-purulent. The spleen was normal in size; the liver was slightly atrophied and the surface was irregular; both organs contained a moderate number of miliary fibrous tubercles and one fibroid nodule. The lungs were voluminous and contained irregular dense fibroid patches of various sizes, two large, and a few discrete tubercles; there was no caseation or cavitation in the patches. The bronchial glands were dense and fibroid. The glands in the neck were enlarged stony hard and composed of dense fibroid tissue showing (in two glands) an occasional minute yellow focus. There was no tuberculosis elsewhere. Smears from the lung and a spleen nodule showed each a few tubercle bacilli. [Two guineapigs were inoculated with an emulsion of a fibroid patch from the lung; one was killed after 62 days and showed local tuberculosis only, the other after 161 days and showed slight general tuberculosis.

2897.

There was a small (intramuscular) collection of caseo-pus at the seat of inoculation; several of the adjacent glands were slightly enlarged and contained each a caseous tubercle or two. The spleen was enlarged (to 4 times the normal size) and showed on section grey pin-head sized tubercles (smear, T.B. fairly numerous). The liver was normal in colour and contained fairly numerous grey and yellow foci. Kidneys normal. The lungs were crepitant and contained scattered minute grey tubercles. The bronchial and most of the abdominal lymphatic glands were slightly enlarged; the former contained one focus, the latter showed no sign of caseation. The head of each tibia was enlarged; the right showed on section early caseous necrosis (smear, a few T.B.); there was no caseation in the left.

2986.

There was a pea-sized caseous nodule at the seat of inoculation. The nearest glands were enlarged, firm, and showed small soft caseous foci (smear from one focus, one T.B. seen). There was a large excess of peritoneal fluid. The spleen was very slightly enlarged, otherwise normal (smear from pulp, no T.B.). The liver was red and cirrhotic and showed a moderate number of minute greyish-white points (smear, no T.B.). Kidneys normal. The pleural cavities were full of clear fluid. The lungs were dark greyish-red in colour (fibroid) and almost completely collapsed, a few very small areas of crepitant tissue remaining; no definite tubercles were seen in the organ (smear, no T.B.). The bronchial glands were slightly enlarged and firm, no definite tubercles were seen; the manubrial and sternal were enlarged firm and fibrous throughout; the portal glands showed a few small fibroid tubercles (smear, no T.B.); other lymphatic glands were normal.

2988.

There was a large ulcer at the seat of inculation, and the nearest glands were enlarged and contained softened caseous nodules. The spleen was very large and dark red, the liver was enlarged and paler than normal; both organs were mottled with necrotic patches. Kidneys normal. The lungs were crepitant and contained fairly numerous submiliary grey tubercles. The thoracic and several abdominal glands were enlarged and contained small caseous patches, some gritty.

3032.

At the seat of inoculation there was a healed ulcer represented by a scar; in the subcutaneous tissues near this a small collection of caseo-pus was seen. The nearest glands were moderately large and filled with caseo-pus. There was no sign of tuberculosis elsewhere.

3034.

There was a small dry ulcer at the seat of inoculation; of the adjacent glands some were partly fibroid partly caseous and softened, others were partly caseous. The spleen was moderately enlarged and beset with greyish fibrous miliary tubercles and showed a fibro-caseous patch or two. The liver was enlarged pale fibroid and very irregular on the surface, and contained greyish white fibrous tubercles and a fibro-caseous patch or two. Kidneys normal. There were tubercles and a few caseous nodules in the omentum. The right lung was partly hepatised (red) the rest of the lungs was crepitant; grey fibrous tubercles were scattered throughout. The bronchial, many abdominal glands and the neck glands were slightly enlarged and very dense; the majority were fibrous throughout or showed whitish or softened patches.

3049.

There was a caseous ulcer at the seat of inoculation in the mid line of the abdomen, and there were large caseous ulcers in each groin; the inguinal and axillary glands were enlarged and caseous, and caseous nodules were seen along the vessels leading towards the iliac glands which were caseous. The spleen was adherent enlarged and extensively necrosed; the liver was very large and composed of yellow necrotic areas and light brownish hepatic tissue. Kidneys normal. The right lung was hepatised the left congested; both contained numerous grey or caseous miliary tubercles. The thoracic and abdominal glands were enlarged and caseous, and the glands in the neck and throat contained caseous nodules. The peritoneal cavity was full of blood-stained fluid.

3051.

There was an ulcer at the seat of inoculation and the nearest glands were enlarged and partly caseous. The spleen was moderately enlarged, red, and showed irregular grey tubercles; the liver was enlarged and irregular on the surface and showed a moderate number of small yellow necrotic patches and foci. Kidneys normal. The ventral portions of one cephalic and the tips of each caudal lobe of the lungs were solid and caseous; the rest of the lungs contained scattered caseous nodules, the larger up to 3 mm. in diameter with cavities in the centre. The bronchial glands were enlarged fibroid and showed a few caseous foci; the portal and lumbar were similar but smaller; the sternal were slightly enlarged and partly caseous and softened.

3056.

There was an irregular ulcer with caseous margins at the seat of inoculation; the inguinal glands were caseous and softened; the axillary glands were thin-walled cysts filled with caseo-pus. In the subcutaneous tissues of the abdomen and thorax were many caseous and softened nodules. The spleen was slightly enlarged and contained dense fibro-caseous nodules up to a small pea in size. The liver showed scattered thin-walled caseous nodules and small fibrous foci or patches. The kidneys were normal. The caudal lobes of the lungs were partly consolidated and contained caseous nodules some

softened and with central cavities; in the cephalic lobes there were irregular grey tubercles mostly caseous in the centre. The bronchial and many abdominal lymphatic glands were enlarged dense and fibroid; the iliac glands were caseous; one cervical gland was fibro-caseous, another partly caseous.

3057.

The omentum was not thickened and contained scattered tubercles, the majority grey and translucent a few yellow; there were two small caseous tubercles on the meso-colon. The spleen was twice the normal in size and showed enlargement of the Malpighian bodies and (?) exceedingly numerous just visible grey points. The liver showed fairly numerous minute grey foci. The remaining organs and all the lymphatic glands were normal.

3058.

There was a healing ulcer at the seat of inoculation; the nearest glands were caseous. The spleen was moderately enlarged and showed one large necrotic patch, minute grey tubercles, and large greyish-yellow tubercles. The liver was enlarged and mottled with necrotic patches. Kidneys normal. The anterior lobes of the lungs were composed of grey fibroid masses containing here and there caseous foci or small cavities; in the caudal lobes there were similar masses the majority containing cavities lined with caseous substance or containing thin pus. The bronchial portal and lumbar glands were enlarged very dense and fibroid, and here and there a yellow point was seen.

3059.

The omentum was slightly thickened and fibrous with caseo-purulent areas. The spleen was normal; the liver was somewhat pale and showed on the surface indefinite greyish foci and two or three caseo-purulent nodules. There was a small collection of caseo-pus in the medulla of one kidney. The lungs contained two firm caseous nodules and two or three grey tubercles. One inguinal gland contained a soft yellow focus, and there were a few foci in the mesenteric glands; all other lymphatic glands were normal.

3076.

There was a healing ulcer at the seat of inoculation. The nearest glands contained brownish-yellow pus. The spleen was moderately enlarged and closely beset with greyish fibrous tubercles; the liver contained a few caseo-purulent nodules and caseous patches, and scattered grey tubercles. There was a grey tubercle in one kidney. The lungs were composed almost throughout of dense fibroid tissue, showing on section a few cavities containing caseo-pus and a few softened caseous areas. The ventral mediastinum was filled with nodular fibrous growths and on the costal pleura were fairly numerous grey tubercles. The bronchial glands were enlarged very dense and fibroid; the neck glands and portal glands showed most of their cortex grey and fibrous; in these fibroid glands there was occasionally a yellow focus seen. The lumbar and iliac glands were slightly enlarged.

3230.

There was a large local ulcer with a thin caseous floor; the nearest glands contained caseo-purulent nodules. The spleen was moderately enlarged and contained ill-defined grey nodules. The liver was enlarged firm and composed almost entirely of greyish tissue containing here and there yellowish points. The kidneys were normal. The lungs were crepitant but showed numerous minute grey points of a doubtful nature. Some of the thoracic and abdominal lymphatic glands were slightly enlarged but showed no sign of caseation except the sternal which contained a caseous focus.

3279.

There was a completely healed ulcer at the seat of inoculation; the inguinal glands were moderately enlarged and indurated, the nearest contained cavities filled with caseo pus while the others showed necrotic foci. Other lymphatic glands were indurated, normal in size or slightly enlarged; one only (a lumbar) contained a calcareous focus. The spleen was enormously enlarged stretching from diaphragm to pelvis; it was firm dark red and showed irregular patches of necrosis. Kidneys normal. The liver was pale firm and fibroid and contained a few yellow patches of necrosis. The lungs were voluminous but crepitant and contained moderately numerous small grey tubercles.

INOCULATION EXPERIMENTS ON THE CHIMPANZEE, BABOON, PIG, GOAT, HORSE, CAT, RAT, AND MOUSE

CHIMPANZEE INOCULATED WITH A CULTURE FROM A LUPUS VIRUS.

CUTANEOUS INOCULATION.

Virus.	Immediate Source of Culture.	Duration of Artificial Cultivation.	Dose in Milli-grammes.	Number of Chimpanzee.	Duration of Life.	Result.
H. 85. "H.B."	Original material through G.P. 2365.	273 days	0·01 mg. (the skin was scarified with a scalpel and the culture applied).	9 (young animal).	Died 170 days	The cause of death was not apparent. There was no sign of tuberculosis at the seat of inoculation; in the right axilla there was an ulcer with caseo-purulent floor (which had developed out of an ulcerating caseous gland). There was no tuberculosis elsewhere.

BABOON INOCULATED WITH A CULTURE FROM A LUPUS VIRUS.

SUBCUTANEOUS INOCULATION.

Virus.	Immediate Source of Culture.	Duration of Artificial Cultivation.	Dose in Milli-grammes.	Number of Baboon.	Duration of Life.	Result.
H. 53. "D.H." (*a*)	Original material through G.P. 1482.	968 days	1·0 mg.	7 (young animal).	Died 35 days	The cause of death was not apparent. There was an irregular ulcer at the seat of inoculation; two left axillary glands were enlarged caseous and softened; other glands adjacent contained caseous tubercles and foci. The lungs showed sparsely scattered shotty caseating tubercles up to 1 mm. in diameter; smaller tubercles were seen in the liver and spleen, greyish in colour and sparsely distributed.

PIGS INOCULATED WITH CULTURES FROM LUPUS VIRUSES.

SUBCUTANEOUS INOCULATIONS.

Virus.	Immediate Source of Culture.	Duration of Artificial Cultivation.	Dose in Milli-grammes.	Number of Pig.	Weight in Kilos.		Duration of Life.	Result.
					Initial.	Final.		
H. 53. "D.H." (*a*)	Original material through G.P. 1482.	723 days	50·0 mg.	85	39·91	163·28	Killed 366 days	General tuberculosis, not severe and evidently not progressive. There were scattered caseous nodules in the subcutaneous tissues at the seat of inoculation and the adjacent inguinal glands were large and caseous. The lungs were expanded and evenly beset with caseous nodules with thick fibrous capsules. The spleen contained scattered dry caseo-calcareous nodules with thin grey capsules; fairly numerous encapsuled nodules were seen in the liver; there were three in each kidney. Caseous gritty nodules were seen in most of the lymphatic glands.
	,,	,,	10·0 mg.	87	34·85	99·32	Killed 227 days	General tuberculosis, not severe, and apparently retrogressive. At the seat of inoculation there were numerous scattered softened caseous thin-walled cysts; one was large (2 cm.) with caseo-purulent contents. The adjacent glands were dry, caseous, and slightly calcareous. The spleen and liver showed small sparsely-scattered caseo-calcareous nodules, the left kidney one. The lungs contained fairly numerous softened caseous nodules, a number of grey tubercles, and some fibroid tracts beset with caseous foci. One or more tubercles or nodules were found in the submaxillary, thoracic, and many abdominal glands; there was one in the thymus.
	,,	,,	1·0 mg.	89	42·18	84·35	Killed 123 days	General tuberculosis, not severe. At the seat of inoculation there were caseo-purulent cysts similar to those in Pig 87. The adjacent glands contained caseous nodules. The lungs were moderately closely beset with nodules of various sizes (1–10 mm.), the majority fibro-caseous. In the liver and spleen there were fewer nodules of similar character, and the latter showed also a softened caseous mass (1 cm.). The bronchial, portal, and coeliac glands were largely caseous and softened; a few other glands were affected, but less severely; many were normal.
	,,	1069 days	50·0 mg.	121	18·14	22·67	Died 146 days	Severe tuberculosis of the lungs, with tuberculosis of the lymphatic glands. There were several small dry ulcers at the seat of inoculation, and a mass of caseous tubercles and nodules in the subcutaneous tissues; the adjacent glands were much enlarged and caseous throughout. The lung tissue was firm and congested and resembled pancreas, the lobules being composed of solid greyish tissue, homogenous anteriorly, but showing yellow and then caseous centres in the posterior parts of the lungs. A few lobules were extensively caseated and showed small cavities. Very little crepitant lung tissue remained. The bronchial glands were enlarged and contained caseous nodules small and in places confluent. The abdominal organs were normal; most of the abdominal lymphatic glands contained caseous nodules sometimes confluent.

PIGS INOCULATED WITH CULTURES FROM LUPUS VIRUSES—*continued.*

SUBCUTANEOUS INOCULATIONS—*continued.*

Virus.	Immediate Source of Culture.	Duration of Artificial Cultivation.	Dose in Milli-grammes.	Number of Pig.	Weight in Kilos.		Duration of Life.	Result.
					Initial.	Final.		
H 53. "D.H." (*a*) *continued.*	Original material through G.P. 1482.	1069 days	10·0 mg.	119	18·14	62·58	Killed 225 days	Slight generalised tuberculosis. There was a fibro-caseo-calcareous local lesion, and the adjacent glands were enlarged and composed of similar substance. The lungs contained moderately numerous calcareous tubercles up to a millet seed in size, and there were two in the spleen ; four grey tubercles were seen in the liver. The bronchial and portal glands were beset with calcareous tubercles ; the mesenteric glands contained a varying number and some were calcareous throughout. A few other lymphatic glands were affected. Between the pericardium and the heart, which were adherent, there were three or four fibro-calcareous tubercles.
H. 85. "H.B." ...	Original material through G.P. 2363.	244 days	50·0 mg.	115	18·59	71·66	Killed 307 days	Slight general tuberculosis apparently retrogressive. There was a fibro-calcareo-caseous lesion at the seat of inoculation and the adjacent inguinal glands were large and caseated ; other glands adjacent to the tumour were calcareous. The lungs contained fairly numerous small calcareous nodules, the spleen two caseo-calcareous tubercles. The bronchial and portal glands contained calcareous nodules ; the mesenteric glands were much enlarged and caseo-calcareous ; other abdominal glands contained caseo-calcareous nodules and patches. Three glands in the throat contained each one or more caseo-calcareous nodules.
	"	"	10·0 mg.	117	17·23	57·60	Killed 268 days (when in good condition).	Severe chronic general tuberculosis. At the seat of inoculation there was a nodular tumour composed of caseous encapsuled nodules and there were similar nodules in the adjacent tissues ; the adjacent glands were much enlarged caseous and gritty. The lungs were closely beset with caseous encapsuled nodules and showed also numerous small tubercles. The spleen contained a number of similar caseous nodules, the largest over 1 cm. in diameter, and a few caseous tubercles. The liver was closely beset with similar caseous nodules. There were four tubercles in each kidney. The left testicle contained an encapsuled caseous nodule and there was a smaller nodule in the tunica vaginalis. The thymus contained a caseous nodule. Nearly all the lymphatic glands in the body contained a varying number of softening caseous nodules ; the bronchial, portal, coeliac, iliac, and many mesenteric glands were caseous practically throughout.
H. 92. "D.N." ...	Original material through G.P. 2592.	64 days	50·0 mg.	107	16·78	27·21	Killed 133 days	Slight disseminated tuberculosis. There was a small scar at the seat of inoculation and scattered caseous tubercles in the subcutaneous tissues. A right inguinal and a ventral mediastinal

								gland were enlarged, caseous and softened. In the lungs there were numerous indefinite greyish foci in places forming small patches (smear, a few T.B.). The bronchial glands and two or three glands in the neck contained scattered soft whitish foci. Two small caseous nodules were seen in one suprarenal body. There was an opening in the cornea of each eye and the whole eye was disorganised : there was no definite tuberculosis, but T.B. were found in fluid from the anterior chamber.
	"	"	50·0 mg.	109	14·06	47·60	Killed 159 days	Slight disseminated tuberculosis. There were scattered caseous nodules in the subcutaneous tissues at the seat of inoculation three of which had ulcerated ; the adjacent inguinal and ventral mediastinal glands were enlarged and caseous ; one precrural gland contained caseous nodules, and one submaxillary three caseous tubercles. In the lung two caseous tubercles were seen. There was an opening in the cornea of the right eye and the whole eye was disorganised ; T.B. were found in smears from the anterior and posterior chambers ; the posterior chamber was filled with yellow tenacious pus.

GOATS INOCULATED WITH CULTURES FROM LUPUS VIRUSES.

SUBCUTANEOUS INOCULATIONS.

Virus.	Immediate Source of Culture.	Total Duration of Artificial Cultivation.	Dose in Milli-grammes.	Number of Goat.	Weight in Kilos.		Duration of Life.	Result.
					Initial.	Final.		
H. 85. "H.B."	Original material through G.P. 2363.	244 days	10·0 mg.	63	24·02	23·12	Killed 402 days (when very ill).	Severe chronic general tuberculosis. The local tumour was very large, and was composed of closely packed caseous gritty nodules bound together by fibrous tissue. The adjacent prescapular gland was large and caseous throughout. The lungs were closely packed with cheesy gritty nodules, largest and most softened in the posterior parts of the caudal lobes : in the left caudal lobe there was a cavity communicating with a bronchus ; the cavity and the bronchus contained caseo-pus. The thoracic glands were much enlarged and calcareo-caseous. There were two large fibro-caseo-calcareous nodules in the diaphragm and three caseous nodules on the omentum. The spleen was greatly enlarged ; its peritoneal surfaces showed numerous caseous nodules, and its pulp was almost completely replaced by calcareo-caseous nodules. The liver contained numerous caseous and softened nodules (up to 1 cm.), and the kidneys about a dozen calcareo-caseous nodules. The nodules in the organs all had thin fibrous capsules. Tuberculous lesions were also found in other tissues and organs ; in the testicles, intestines, thyroid body, one eye, an intercostal muscle, and the cancellous tissue of the shaft of each of three ribs. The head of the 8th rib was replaced by a caseo-calcareous mass. Most of the abdominal and peripheral glands contained one or more calcareous or calcareo-caseous nodules ; the glands of the throat and neck contained similar but more numerous nodules.

GOATS INOCULATED WITH CULTURES FROM LUPUS VIRUSES—*continued.*

SUBCUTANEOUS INOCULATIONS—*continued.*

Virus.	Immediate Source of Culture.	Total Duration of Artificial Cultivation.	Dose in Milli-grammes.	Number of Goat.	Weight in Kilos.		Duration of Life.	Result.
					Initial.	Final.		
H. 53. "D.H." (*a*)	Original material through G.P. 1482.	1,069 days	10·0 mg.	65 (kid).	21·77	16·78	Died 38 days	General tuberculosis, severe in lungs. There was an infiltrating caseo-necrotic local tumour; the left prescapular gland was caseated almost throughout, and other adjacent glands contained caseous tubercles and nodules. The lungs were extensively consolidated and very closely beset with miliary caseating tubercles. The thoracic glands were enlarged and caseating. The Malpighian bodies of the spleen were well marked, and a few had yellow centres. There were a few grey tubercles in the liver, kidneys, and suprarenals, and grey foci and occasional miliary tubercles in the mesenteric and coeliac glands.
	,,	1,124 days	10·0 mg.	67 (adult).	29·93	19·50	Died 59 days	General tuberculosis, severe in lungs. There was a collapsed cyst at the seat of inoculation, and the left prescapular gland was caseous throughout and gritty. Part of the caudal lobes of the lungs were solid and caseating, and showed commencing cavitation; the rest of the lungs was closely beset with calcareous miliary tubercles. The thoracic glands were enlarged and showed calcareous streaks and foci. The spleen showed scattered tubercles with minute calcareous centres; the mesenteric glands showed a few calcareous foci. There were no lesions in the other organs and glands.
H. 109. "M.W."	Original material through G.P. 3002.	95 days	1·0 mg.	61 (adult).	44·44	45·80	Killed 197 days	There were three hempseed-sized softened caseous nodules with fibrous walls at the seat of inoculation; the adjacent prescapular gland was normal, and there was no tuberculosis elsewhere.

HORSES INOCULATED WITH CULTURES FROM LUPUS VIRUSES.

Virus.	Immediate Source of Culture.	Total Duration of Artificial Cultivation.	Dose in Milli-grammes.	Number of Horse.	Weight in Kilos.		Duration of Life.	Result.
					Initial.	Final.		
				SUBCUTANEOUS INOCULATIONS.				
H. 85. "H.B."	Original material through G.P. 2363.	244 days	50·0 mg.	5 (yearling).	131·50	134·20	Killed 112 days	Slight disseminated tuberculosis. There was a patch of fibrous tissue at the seat of inoculation; in the left prescapular region there were two large glands filled with caseo-pus and many smaller caseous glands; one left cervical gland was large and caseous, another contained a caseous nodule. Sparsely scattered small grey tubercles were seen in the lungs, spleen, and liver.

H. 92. "D.N."	Original material through G.P. 2592.	114 days	100·0 mg.	9 (yearling).	100·20	115·20	Killed 136 days	There was a linear scar at the seat of inoculation and two left prescapular glands contained each a small fibro-calcareous patch. In the lungs one small grey gritty nodule was seen and one bronchial gland showed a calcareous tubercle ; in one ileo-colic gland there were a few foci. No T.B. were found in smears from several of the lesions.
				INTRAVENOUS INOCULATIONS.				
H. 85. "H.B."	Original material through G.P. 2365.	273 days	10·0 mg.	11 (yearling).	95·24	75·29	Died 51 days	Acute general tuberculosis.
H. 92. "D.N."	Original material through G.P. 2592.	114 days	10·0 mg.	7 (yearling).	116·11	136·06	Killed 137 days	The lungs were crepitant and showed small translucent grey tubercles, numerous in the posterior third of the caudal lobes, scanty in the anterior lobes. In the bronchial glands there were a few calcareous foci, and in the liver one grey translucent tubercle.

CATS INOCULATED WITH CULTURES FROM LUPUS VIRUSES.

SUBCUTANEOUS AND INTRAPERITONEAL INOCULATIONS.

Virus.	Immediate Source of Culture.	Total Duration of Artificial Cultivation.	Dose in Milli-grammes.	Mode of Inocula-tion.	Number of Cat.	Weight in Grammes.		Duration of Life.	Result.
						Initial.	Final.		
H. 107. "H.H."	Original material through G.P. 2955.	63 days	1·0 mg.	Subcut.	51	1,550	990	Died 99 days	The cause of death was not apparent. There was a small clean-cut ulcer without sign of caseation, at the seat of inoculation ; a right inguinal and a right manubrial gland showed caseous lesions ; three or four grey miliary tubercles with soft whitish centres, and some yellowish-grey foci of doubtful origin were seen in the lungs. There was no tuberculosis elsewhere.
	,,	,,	1·0 mg.	Intrap.	49	1,100	1,750	Killed 262 days	In the muscles of the abdominal wall there was a flat mass of tough yellowish caseated tissue. In the omentum there was a mass of fatty tissue embedded in which were softened caseo-calcareous nodules up to a hempseed in size, mainly discrete but here and there aggregated together. There was no sign of tuberculosis elsewhere.
H. 71. "L.V." (*a*)	Calf 1153 (bronchial gland).	133 days	50·0 mg.	Intrap.	43 (Kitten).	720	520	Died 15 days	In the subperitoneal tissues at the seat of inoculation there was a small collection of caseo-pus, and there was no naked-eye evidence of tuberculosis elsewhere ; T.B. were fairly numerous in smears from the lung, spleen, and liver. The cause of death was not apparent.

RATS INOCULATED WITH CULTURES FROM LUPUS VIRUSES.

SUBCUTANEOUS AND INTRAPERITONEAL INOCULATIONS.

Virus.	Immediate Source of Culture.	Total Duration of Artificial Cultivation.	Dose in Milli-grammes.	Mode of Inoculation.	Number of Rat.	Weight in Grammes.		Duration of Life.	Result.
						Initial.	Final.		
H. 53. "D.H." (*a*)	Original material through G.P. 1482.	817 days	50·0 mg.	Intrap.	57	190	110	Died 122 days	The omentum was slightly thickened and contained one millet seed sized caseous tubercle, and there was a hempseed-sized softened caseous nodule near the right suprarenal body. There were no macroscopic lesions elsewhere in the body, but tubercle bacilli were numerous in smears from the liver and spleen, and very numerous in a smear from the lung.
H. 106. "K.R." ...	Original material direct.	91 days	55·0 mg.	Intrap.	61	300	200	Died 141 days	The omentum was thickened and fibrous, and contained a dozen or more nodules with fibrous margins and yellow softened contents. There were a few tubercles with yellow centres and grey margins on the mesentery, on the peritoneum in the lumbar regions, and on the surface of the liver and spleen. There were no definite tubercles elsewhere, but tubercle bacilli were numerous all over the body.
H. 71. "L.V." (*a*)	Original material through G.P. 1937.	78 days	50·0 mg.	Intrap.	50	220	150	Died 28 days	Acute tuberculosis. There was a small collection of caseo-pus in the subcutaneous tissues at the seat of inoculation. The omentum was slightly thickened; along its free border there were a few fibrous nodules showing yellow points. The spleen was enlarged, firm, and dark red, the pulp under the capsule appearing as if speckled with minute grey points. The liver was pale and closely beset with small dark grey foci. There were no visible tubercles in the other organs, but tubercle bacilli were very numerous all over the body.
	,,	,,	50·0 mg.	Subcut.	51	230	150	Died 70 days	There was a linear ulcer at the seat of inoculation, the floor of which was a little fibroid but free from caseation. There was no sign of tuberculosis elsewhere, but tubercle bacilli were fairly numerous in the gland adjacent to the lesion, and a few were seen in smears from the lung and liver (none in a smear from the spleen). The cause of death was not apparent.
	Calf 1153 (bronchial gland).	133 days	20·0 mg.	Intrap.	58	150	160	Died 103 days	The mesentery and peritoneum appeared somewhat thickened, but there were no tubercles. The spleen was enlarged and speckled with minute grey points. The kidneys showed a number of dark grey spots of a doubtful nature on the surface; the lungs were congested and firmer than normal, and mottled with light grey patches or foci; the sternal glands were enlarged and congested. Tubercle bacilli were numerous in smears from the lung, liver and spleen, and bone marrow; none was seen in a smear from a kidney.

	,,	,,	20·0 mg.	Intrap.	59	180	120	Died 344 days	There was no sign of tuberculosis in the omentum or peritoneum. The lungs were fuller than normal, and the dorsal surfaces of the caudal lobes were covered with a grey layer mottled with yellow foci which was apparently thickened pleura; the surface of the organ elsewhere showed numerous more or less discrete grey foci with somewhat yellowish centres; on section these foci were distributed throughout the parenchyma, and could be felt between finger and thumb. There was no tuberculosis elsewhere. Smears from the spleen and lung showed numerous tubercle bacilli; none was seen in a smear from the kidney.

MICE INOCULATED WITH CULTURES FROM LUPUS VIRUSES

SUBCUTANEOUS AND INTRAPERITONEAL INOCULATIONS.

Virus.	Immediate Source of Culture.	Total Duration of Artificial Cultivation.	Dose in Milli-grammes.	Mode of Inoculation.	Number of Mouse.	Duration of Life.	Result.
H. 92. "D.N."	Original material through G.P. 2592.	114 days	50·0 mg.	Subcut.	31	Died 10 days	In the subcutaneous tissues at the seat of inoculation in the groin there was a quantity of granular caseo-purulent substance, the skin over a part of which was ulcerated. The adjacent inguinal gland was surrounded by pus, and was in a state of early caseation. There was no sign of tuberculosis elsewhere; a few clumps of tubercle bacilli were however seen in smears from the lung, liver, and kidney; none was seen in a smear from the spleen.
	,,	,,	50·0 mg.	Subcut.	32	Died 26 days	At the seat of inoculation in the groin there was a clean ulcer 1 cm. in diameter. The left inguinal gland was slightly larger than the right. The organs appeared normal. Scattered tubercle bacilli were seen in smears from the liver and spleen.
	,,	,,	10·0 mg.	Intrap.	29	Died 1 day	There was no sign of disease and no apparent cause for death.
	,,	,,	10·0 mg.	Intrap.	30	Died 1 day	

TABULAR SUMMARIES OF FEEDING EXPERIMENTS.

FEEDING EXPERIMENTS WITH CULTURES FROM LUPUS VIRUSES.

RHESUS MONKEYS.

Virus.	Immediate Source of Culture.	Duration of Artificial Cultivation.	Dose in Milli-grammes.	Number of Monkey.	Duration of Life.	Result.
H. 110. "J.B." (*a*)	Original material through G.P. 3007.	212 days	10·0 mg.	253	Died 30 days	General tuberculosis. The mucous membrane of the duodenum and jejunum showed numerous small ulcers; in the ileum they were less numerous. The majority were merely fine linear fissures; there was no thickening of the bases and no sign of caseation. All the mesenteric glands save one were greatly enlarged and caseo-purulent; the exception was slightly enlarged and contained caseous foci. The spleen showed scattered tubercles up to 1 mm., the larger ones yellowish in colour; the liver contained sparsely scattered submiliary greyish-white tubercles. The remaining organs and glands were normal. A smear from the mucous membrane of the jejunum showed a few T.B.
H. 100. "R.S." ...	Original material through G.P. 2931.	267 days	10·0 mg.	261	Died 79 days	There was a greyish focus in one tonsil (smear, T.B. very numerous). Fourteen ulcers from 2 to 10 mm. in diameter were seen in the small intestine; they had thickened bases and were caseous around the margins. The mesenteric glands were enlarged and fused together forming a caseous and softened mass. The glands of the throat and the ileo-colic glands showed caseous patches. There were some miliary caseous tubercles on the mesentery. The lungs contained six caseous nodules, the spleen three caseous tubercles and the liver scattered opaque greyish tubercles. One bronchial gland was partly caseous, the others contained a few caseous tubercles. The monkey's death was hastened by non-tuberculous ulceration of the large intestine.
H. 85. "H.B." ...	Original material through G.P. 2365.	218 days	1·0 mg.	125	Died 116 days	General tuberculosis, not severe, except in the glands of the alimentary tract. One submaxillary and one pharyngeal gland were enlarged caseous and softened. About a dozen caseous nodules and tubercles were seen in the small intestine some of which were ulcerated, and there was a caseous nodule in the rectum. All the mesenteric, nine colic and one rectal glands were enlarged and caseous. The spleen contained one softened caseous nodule, the liver nine or ten caseo-purulent cysts the largest the size of a small pea, and two small tubercles. The lungs contained nine dense caseous nodules up to 1 cm. in diameter. Three thoracic glands were caseous; one axillary gland contained a caseous nodule. There were four caseous nodules in the mesentery and meso-colon.
		,,	0·1 mg.	127	Killed 115 days (when dying).	General tuberculosis, not severe, except in the glands of the alimentary tract. One submaxillary gland was caseous and softened. The glands in the anterior part of the mesentery formed a large caseous and softened mass; two only in the posterior part were affected containing each a caseous nodule. One ileo-colic, many colic and three rectal glands were caseous throughout or contained caseous nodules. There were several firm caseous nodules along the mesenteric veins. There was no tuberculous lesions in the intestines. The spleen contained six caseous and softened nodules, and there were two or three caseous tubercles and a caseous nodule in the lungs.
H. 53. "D.H." (*a*)	Original material through G.P. 1482.	902 days	10·0 mg.	113	Died 20 days	No tuberculosis. The cause of death was not determined.
		,,	1·0 mg.	115	Died 22 days	

	"	1,069 days	1·0 mg.	131	Killed 294 days (when well).	General tuberculosis. One submaxillary, one pharyngeal and a cervical gland, one gastric, and two ileo-colic glands each contained one or two softened caseous nodules; another submaxillary and most of the mesenteric glands were slightly enlarged, three were caseous throughout, the others closely beset with caseous and softened nodules. In the meso-colon there was a fibro-caseous mass the size of a broad bean (colic glands). The small intestine was normal; in the large intestine there were several small ulcers and two over 1 cm. in diameter; they had smooth fibrous floors and thickened margins. One lobe of the lung was composed of fibroid tissue containing caseous patches and foci; the other lobes contained sparsely scattered fibro-caseous tubercles. The spleen contained a moderate number of irregular softened caseous nodules, the liver a number of muco-purulent cysts, a caseous nodule, and a few small tubercles; the kidneys four small tubercles. In the omentum about three dozen caseous nodules were seen. The bronchial splenic and portal glands showed varying degrees of caseation.
H. 84. "M.S" ...	Original material through G.P. 2277.	313 days	1·0 mg.	145	Killed 139 days (when well).	General progressive tuberculosis of moderate severity. One tonsil contained a soft whitish focus (T.B.). There were two small ulcers without caseation and two or three small fibrous tubercles in the small intestine. The submaxillary glands were greatly enlarged and composed of cheesy caseous substance. The pharyngeal glands were much enlarged and caseo-purulent. The mesenteric and one colic gland (slightly enlarged) contained discrete caseous nodules. The lungs contained one caseating nodule (1 cm.) and sparsely-scattered fibro-caseous tubercles, the spleen sparsely scattered caseous nodules up to 1 cm., the liver scattered miliary caseating tubercles and half a dozen caseous nodules up to a pea in size. Three bronchial, one pancreatic, and two splenic glands showed varying degrees of caseation. The omentum showed numerous miliary caseous tubercles with grey margins; a few were seen on the parietal peritoneum, mesentery, and meso-colon.
H. 102. "N.H."	Original material through G.P. 2934.	277 days	10·0 mg.	259	Died 73 days	Death from ulcerative colitis. There were five small tuberculous ulcers without sign of caseation in the small intestine. The mesenteric glands were not enlarged; they contained scattered caseous miliary tubercles. There was no tuberculosis elsewhere.

CHIMPANZEE.

Virus.	Immediate Source of Culture.	Total Duration of Artificial Cultivation.	Dose in Milli-grammes.	Number of Chimpanzee.	Duration of Life.	Result.
H. 85. "H.B." ...	Original material through G.P. 2365.	273 days	1·0 mg.	11 (young animal).	Killed 271 days (when in good health).	There was a focus of yellow pus in one tonsil; about two dozen small ulcers were seen in the lower half of the small intestine, the majority shallow and without caseation. There was a large mass composed of enlarged caseous and softened glands in the anterior end of the mesentery, elsewhere the mesenteric glands were separate and about sixteen of them were caseous and softened. One pancreatic gland was similar. In the spleen there was a mass (1 cm.) composed of aggregated caseous nodules. One axillary gland was caseous. There was a tubercle in the liver and two on the serous surface of the small intestine.

FEEDING EXPERIMENTS WITH CULTURES DERIVED FROM LUPUS VIRUSES—*continued.*

BABOON.

Virus.	Immediate Source of Culture.	Total Duration of Artificial Cultivation.	Dose in Milli-grammes.	Number of Baboon.	Duration of Life.	Result.
H. 53. "D.H." (*a*)	Original material through G.P. 1482.	968 days	1·0 mg.	5 (young animal).	Died 70 days	The alimentary tract and the glands connected with it were normal. In the lungs there were eight hard nodules with fibrous margins and softened yellow centres, and in one of the bronchial glands half-a-dozen yellow softened foci were seen (spontaneous tuberculosis, a human tubercle bacillus was isolated from the lung). There was no tuberculosis elsewhere ; the cause of death was not apparent.

PIGS.

Virus.	Immediate Source of Culture.	Total Duration of Artificial Cultivation.	Dose.	Number of Pig.	Weight in Kilos.		Duration of Life.	Result.
					Initial.	Final.		
H. 110. "J.B." (*a*)	Original material through G.P. 3007.	158–170 days	Fed on alternate days for a fortnight, seven times in all. Dose : the growth from one serum tube on each occasion.	129	26·30	60·77	Killed 111 days	Slight retrogressive general tuberculosis. One submaxillary and one cervical gland were enlarged and almost entirely occupied by caseous gritty masses ; other submaxillary retro-pharyngeal and cervical glands contained caseous nodules. Caseous or calcareous tubercles were seen in all the Peyer's patches in the small intestine ; they were most numerous in the long patch in the ileum. Two small tubercles were seen in the large intestine. The mesenteric glands were greatly enlarged and composed of caseous gritty substance. Some of the ileo-colic and colic glands were caseous throughout, others contained caseous tubercles or nodules. The lungs contained scattered tubercles, some grey others with caseo-calcareous centres ; the spleen contained one calcareous tubercle ; in the liver there were a moderate number of grey tubercles each with a minute calcareous centre. One bronchial, one splenic, the portal, one ventral mediastinal, one renal, and the coeliac glands showed varying degrees of caseation.
	"	"	Do.	131	19·50	68·00	Killed 145 days	Slight disseminated tuberculosis. There were half-a-dozen caseo-calcareous tubercles in each tonsil. Four submaxillary and the mesenteric glands were slightly enlarged and almost entirely replaced by caseo-calcareous patches. One submaxillary, one pharyngeal, the ileo-colic, and several colic glands contained a varying number of discrete calcareo-caseous nodules and tubercles ; the portal, one pancreatic, and two coeliac glands were similarly affected. There were three small grey tubercles in the lungs, and sparsely scattered grey tubercles in the liver, two having minute calcareous centres.

H. 100. "R.S."	Original material through G.P. 2931.	174–186 days	Fed on alternate days for a fortnight, seven times in all. Dose: the growth from one serum tube on each occasion.	133	22·22	52·16	Killed 114 days	Slight disseminated tuberculosis. The submaxillary glands, the mesenteric glands (much enlarged), and the ileo-colic glands (slightly enlarged) were all occupied to a greater or less extent by caseo-calcareous substance. The intestines were normal. The liver contained scattered grey tubercles with minute calcareous centres; in the lungs half-a-dozen were seen. The portal, one colic, and the coeliac glands contained one or more caseo-calcareous tubercles. There was no tuberculosis elsewhere.
	"	"	Do.	135	24·02	87·08	Killed 146 days	Local tuberculosis. One submaxillary gland on each side was slightly enlarged and contained caseous gritty nodules up to 5 mm. in diameter; a small gland on one side contained a single tubercle. The mesenteric glands were normal in size; several at the anterior end were normal on section; the others contained caseous gritty nodules up to 8 mm. in diameter. Two ileo-colic and one colic gland contained a few tubercles. One minute calcareous focus was seen in the liver. The intestines were normal.
H. 102. "N.H."	Original material through G.P. 2934.	184–196 days	Fed on alternate days for a fortnight, seven times in all. Dose: the growth from one serum tube on each occasion.	137	18·14	50·80	Killed 112 days	In the liver there was a small grey tubercle and an encapsuled nodule containing dry mortary substance (no T.B.). The other organs and all the glands were normal.
	"	"	Do.	139	24·02	83·90	Killed 144 days	One submaxillary gland contained two pinhead-sized caseo-calcareous tubercles. There was no sign of tuberculosis elsewhere.

GUINEA-PIGS.

Virus.	Immediate Source of Culture.	Total Duration of Artificial Cultivation.	Dose in Milligrammes.	Number of Guinea-pig.	Weight in Grammes.		Duration of Life.	Result.
					Initial.	Final.		
H. 92. "D.N." ...	Original material through G.P. 2592.	114 days	Fed daily for five days, and received about 1·0 mg. per day.	2971	570	460	Died 36 days	General tuberculosis; the culture appeared to have been insufflated. The neck glands contained caseous tubercles; the anterior lobes of the lungs were solid and extensively caseous, the posterior lobes were crepitant but closely beset with tubercles. The bronchial glands were much enlarged and caseous. The spleen was large and extensively caseo-necrotic, the liver large pale and mottled with necrotic patches. The intestine and mesenteric glands were normal.

FEEDING EXPERIMENTS WITH CULTURES DERIVED FROM LUPUS VIRUSES—*continued.*

Guinea-pigs—*continued.*

Virus.	Immediate Source of Culture.	Total Duration of Artificial Cultivation.	Dose in Milligrammes.	Number of Guinea-pig.	Weight in Grammes.		Duration of Life.	Result.
					Initial.	Final.		
H. 92. "D.N."—*continued.*	Original material through G.P. 2592.	114 days	Fed daily for five days, and received about 1·0 mg. per day.	2972	690	660	Died 148 days	Chronic general tuberculosis. The submental and one submaxillary glands were enlarged and caseo-purulent, and other glands in the throat and neck were large and fibroid with calcareous foci. All the Peyer's patches showed from the serous surface grey foci and some were ulcerated on the mucous surface, the ulcers showing hard yellow floors. The mesenteric glands were a little enlarged and fibro-calcareous. The anterior lobes of the lungs were solid and composed of fibrous tissue and dense caseous patches; the caudal lobes contained similar masses and discrete caseous nodules; some of the caseous areas showed small cavities. The thoracic and several abdominal glands were very fibroid and calcareous. The spleen contained scattered grey tubercles, the liver necrotic patches and a single tubercle, and one kidney a grey tubercle.
	,,	,,	Do.	2973	450	400	Died 126 days	Chronic general tuberculosis. The glands in the throat and neck were enlarged and caseous or contained caseous nodules. The mesenteric, ileo-colic, and colic glands were much enlarged, firm, and yellowish, containing caseous or calcareous foci. The small and large intestines contained several patches of caseous confluent tubercles some slightly ulcerated on the mucous surface. The lungs were riddled with cavities and showed also numerous thin-walled caseous nodules which had not yet broken down. The bronchial glands contained caseous foci, the sternal glands were caseating. The spleen and liver were enlarged and showed necrotic areas and small grey tubercles.

DETAILED DESCRIPTION, WITH SUMMARY, OF EACH OF THE PASSAGE EXPERIMENTS.

(The full Post-Mortem Notes of the larger animals and Abstracts of the Post-Mortem Notes of the Rabbits used in these Passage Experiments, are placed after the Charts of the Viruses to which they belong, in the second half of the Report.)

PASSAGE EXPERIMENTS WITH LUPUS VIRUSES.

INTRODUCTION.

The description of the passage experiments with each virus is preceded by a summary of the results of the inoculation of the original culture in those animals which were employed to test the virulence of the culture after passage ; the animals which were used were the calf, the rabbit, the monkey and the guinea-pig.

The several passage experiments are described in detail, illustrated by marginal diagrams, and summarised.

And in order that a comparison of the virulence of the passage cultures with that of the original culture may be readily made, a table has been prepared for each virus giving the results in each species of animal used of the inoculation of both the original and the passage cultures.

VIRUS H. 100. "R.S."

Original virulence of culture.

The culture derived from the original material was tested on the calf, rabbit, rhesus monkey, and guinea-pig.

Calves.—Four were inoculated subcutaneously, two with 50 milligrammes and two with 100 milligrammes. Of the former, one was killed 73 days later when dying of general progressive tuberculosis, the other was killed when in fairly good health after 122 days and showed general progressive tuberculosis. The two inoculated with the large doses showed after 95 and 119 days general tuberculosis not severe and not obviously progressive.

Rabbits.—Five were inoculated subcutaneously the dose in each case being 10 milligrammes. All died of general progressive tuberculosis, the duration of life varying from 91 to 337 days.

Monkey.—One inoculated subcutaneously with 1 milligramme died in 86 days and showed general tuberculosis, not severe.

Guinea-pigs.—Two inoculated subcutaneously (doses 1· and 0·1 mg.) died of general tuberculosis in 284 and 192 days respectively.

These experiments showed clearly that the culture from the original material was not so virulent as a bovine tubercle bacillus.

Virulence after passage.

Cultures were recovered from three of the calves and one of the rabbits inoculated with the original culture and tested as to their cultural characters and virulence.

Series α.

Culture.
(Derived from original material through G.P. 2929.)
|
Calf 1419.
Subcut. Dose : 50·0 mg.
Killed after 122 days.
Chronic progressive G.T.
|

Culture. (From the lung.)	*Culture.* (From the liver.)
Calf 1517.	*Calf 1511.*
Subcut. Dose : 50·0 mg. Died in 22 days. Acute tuberculosis.	Subcut. Dose : 50·0 mg. Died in 39 days. General tuberculosis.

From Calf 1419 cultures were isolated from the lung and liver.

The lung strain produced acute tuberculosis in Calf 1517 (died 22 days after 50·0 mg. subcutaneous), fatal generalised progressive tuberculosis in two rabbits inoculated subcutaneously with 2·7 and 10 mg. (died in 52 and 58 days), and rapidly fatal tuberculosis in two guinea-pigs inoculated subcutaneously (both died 39 days after 1 and 0·1 mg.).

The liver strain produced acute tuberculosis in Calf 1511 (died 39 days after 50 mg. subcutaneous), fatal generalised progressive tuberculosis in three rabbits inoculated subcutaneously with 10 mg. (died in 43 to 59 days), rapidly fatal tuberculosis in a guinea-pig (died in 39 days after 0·1 mg. subcutaneous), and severe general tuberculosis in a monkey fatal in 34 days.

Series β.

Culture.
(Derived from original material through G.P. 2931.)
|
Calf 1409.
Subcut. Dose : 100·0 mg.
Killed after 119 days.
Local T. and T. of lungs (not severe).
|
Culture.
(From the mediastinal gland.)
|
Calf 1543.
Subcut. Dose : 50·0 mg.
Killed when dying in 34 days.
General miliary tuberculosis

A culture was isolated from the mediastinal gland of Calf 1409 which showed a mild form of tuberculosis 119 days after the subcutaneous inoculation of 100 milligrammes of the original culture.

The strain from this calf produced acute tuberculosis in Calf 1543 inoculated subcutaneously with 50 milligrammes (killed 34 days when dying), and fatal generalised progressive tuberculosis in two rabbits inoculated subcutaneously with 10 milligrammes (died 51 and 73 days).

Series γ.

Culture.
(Derived from original material through G.P. 2929.)
|

Calf 1523.	*Calf 1547.*
Subcut. Dose : 50·0 mg. Killed when dying in 73 days. General tuberculosis.	Subcut. Dose : 100·0 mg. Killed after 95 days. Generalised tuberculosis, not severe.

|
Culture.
(From the bronchial gland.)
|
Rabbits 2370–2371.
Subcut. Dose : 10 mg. each.
Died in 60 and 83 days.
General tuberculosis.

A culture was isolated from the bronchial gland of Calf 1523 which was killed when dying of general tuberculosis 73 days after a subcutaneous inoculation of 50 milligrammes of the original culture.

The strains from this calf produced fatal generalised progressive tuberculosis in two rabbits, each inoculated subcutaneously with 10 milligrammes (died 60 and 83 days).

VIRUS H. 100. "R.S."—*continued.*

Series δ.

Culture.
(Derived from original material through G.P. 2929.)

Rabbit 1869.
Subcut. 10·0 mg.
Died in 337 days.
General tuberculosis.

Rabbit 1870.
Subcut. 10·0 mg.
Died in 163 days.
General tuberculosis.

Culture.
(From kidney.)

Rabbit 2373.
Subcut. 10·0 mg.
Died in 36 days.
General tuberculosis.

Rabbit 2372.
Subcut. 5·0 mg.
Died in 84 days.
General tuberculosis.

A culture was isolated from one of the rabbits (No. 1869) inoculated subcutaneously with 10 milligrammes of the original culture; the rabbit died of general tuberculosis in 337 days.

The culture isolated from the kidney of the rabbit produced fatal generalised progressive tuberculosis in two rabbits inoculated subcutaneously with 10 and 5 milligrammes (died in 36 and 84 days).

Cultural Characters.

The cultural characters of the recovered cultures were identical with those of the original culture.

SUMMARY.

A culture possessing the cultural characters but not the high virulence of a bovine tubercle bacillus, exhibited the full virulence of the bovine tubercle bacillus after single residences in three calves and one rabbit.

TABULAR SUMMARIES OF THE PASSAGE EXPERIMENTS WITH VIRUS H. 100. "R.S.", SHOWING THE INCREASE IN VIRULENCE FOR THE CALF, RABBIT, MONKEY, AND GUINEA-PIG INDUCED BY PASSAGE.

All the Inoculations in the Table are Subcutaneous.

Source of Origin of Culture Inoculated.	Species and Number of Animal Inoculated, Dose, and Result of Inoculation.				
	Calves.	Rabbits.	Rhesus Monkeys.	Guinea-pigs.	
Series *α* (*virulence increased*).					
Original material (through G.P. 2929).	**1419.** Dose 50 mg. Killed after 122 days Chronic progressive G. T.	**1869.** Dose 10 mg. **1870.** Dose 10 mg. Died in 337 and 163 days. General Tuberculosis.	**163.** Dose 1 mg. Died in 86 days General Tuberculosis, not severe.	**3049.** Dose 1 mg. **3051.** Dose 0·1 mg. Died in 284 and 192 days. General Tuberculosis.	*Original virulence of culture.*
Lung of Calf 1419 (1st calf).	**1517.** Dose 50 mg. Died in 22 days Acute Tuberculosis.	**2075.** Dose 10 mg. **2076.** Dose 2·7 mg. Died in 58 and 52 days General Tuberculosis.	—	**3386.** Dose 1 mg. **3387.** Dose 0·1 mg. Died in 39 and 39 days. General Tuberculosis.	*Virulence after passage through a calf.*
Liver of Calf 1419 (1st calf).	**1511.** Dose 50 mg. Died in 39 days General Tuberculosis.	**2095.** Dose 10 mg. **2096.** Dose 10 mg. **2225.** Dose 10 mg. Died in 45, 43, and 59 days. General Tuberculosis.	**283.** Dose 1 mg. Died in 34 days Severe general tuberculosis.	**3398.** Dose 0·1 mg. Died in 39 days. General Tuberculosis.	

TABULAR SUMMARIES OF THE PASSAGE EXPERIMENTS WITH VIRUS H. 100. "R.S."—*continued.*

	Source of Origin of Culture Inoculated.	Species and Number of Animal Inoculated, Dose, and Result of Inoculation.			
		Calves.	Rabbits.	Rhesus Monkeys.	Guinea-pigs.
		Series β (*virulence increased*).			
Original virulence of culture.	Original material (through G.P. 2931).	1409. Dose 100 mg. Killed after 119 days Local T. and T. of lungs, not severe.	1977. Dose 10 mg. Died in 91 days General Tuberculosis.		
Virulence after passage through a calf.	Mediastinal gland of Calf 1409 (1st calf).	1543. Dose 50 mg. Killed when dying in 34 days. General Tuberculosis.	2176. Dose 10 mg. 2177. Dose 10 mg. Died in 51 and 73 days General Tuberculosis.		
		Series γ (*virulence increased*).			
Original virulence of culture.	Original material (through G.P. 2929).	1523. Dose 50 mg. Killed when dying in 73 days. General Tuberculosis.	2127. Dose 10 mg. 2128. Dose 10 mg. Died in 133 and 145 days. General Tuberculosis.		
Virulence after passage through a calf.	Bronchial gland of Calf 1523		2370. Dose 10 mg. 2371. Dose 10 mg. Died in 60 and 83 days. General Tuberculosis.		
		Series δ (*virulence increased*).			
Original virulence of culture.	Original material (through G.P. 2929).		1869. Dose 10 mg. Died in 337 days. General Tuberculosis.		
Virulence after passage through a rabbit.	Kidney of Rabbit 1869		2373. Dose 10 mg. 2372. Dose 5 mg. Died in 36 and 84 days. General Tuberculosis.		

VIRUS H. 108. "H.R."

The culture derived from the original material through the guinea-pig was tested on the calf, rabbit, guinea-pig, and rhesus monkey. Original virulence of culture.

Calves.—Slight disseminated tuberculosis was produced in two calves inoculated subcutaneously with 50 and 88 milligrammes.

Rabbits.—Four rabbits were inoculated subcutaneously each with 10 milligrammes; one died in 90 days of general tuberculosis, not severe, the lungs being crepitant and containing miliary tubercles; one was killed after 155 days and showed slight generalised tuberculosis; the other two died in 85 and 159 days and showed generalised tuberculosis insufficient to account for death.

Rhesus Monkey.—One inoculated subcutaneously with 1 milligramme died in 96 days of general tuberculosis of moderate severity.

Guinea-pigs.—Two inoculated subcutaneously one with 1 milligramme the other with 0·1 milligramme died of general tuberculosis in 82 and 159 days.

The above tests showed that the virulence of the culture was much lower for all four species of animals than that of a bovine tubercle bacillus.

Cultures were recovered from the two calves inoculated with the original culture, from the lung and mediastinal gland of Calf 1417 and the spleen of Calf 1421; each of the three strains was inoculated into another calf and the cultures recovered from two of these were inoculated each into a third calf. Virulence after passage.

Series α.

1st Passage.—The strain from the lung of Calf 1417 (which showed slight generalised tuberculosis 125 days after a subcutaneous inoculation of 50 mg.) was inoculated subcutaneously into Calf 1539, dose 50 milligrammes; the calf died in 16½ days of acute generalised tuberculosis.

Two rabbits inoculated subcutaneously at the same time with 10 milligrammes died of general tuberculosis within six weeks. The strain was subsequently tested on another rabbit (dose 10 mg.), two monkeys (doses 1 mg.), and a guinea-pig (dose 0·1 mg.); all the animals died of general tuberculosis, the rabbit in 37 days, the monkeys in 28 and 29 days, and the guinea-pig in 44 days.

2nd Passage.—A culture was isolated from the bronchial gland of Calf 1539 and inoculated subcutaneously into Calf 1509, a heifer 6 months old, in a dose of 50 milligrammes, and into two rabbits, dose 10 milligrammes each.

The calf died of acute general tuberculosis in 29 days, the rabbits of general tuberculosis in 36 and 44 days.

Culture.
(Derived from O.M. through G.P. 2957.)
|
Calf 1417.
Subcut. Dose: 50·0 mg.
Killed after 125 days.
Slight generalised tuberculosis.
|
Culture.
(From lung.)
|
Calf 1539.
Subcut. Dose: 50·0 mg.
Died in 16½ days.
Acute tuberculosis.
|
Culture.
(From bronchial gland.)
|
Calf 1509.
Subcut. Dose: 50·0 mg.
Killed when dying in 29 days.
Acute general tuberculosis.

The disease produced in the various animals by the first and second passage cultures was identical in every respect with that produced by a bovine tubercle bacillus.

Series β.

Commencing with a
Culture
derived from the long mediastinal gland of
Calf 1417.

Calf 1537.
Subcut. Dose: 50·0 mg.
Killed after 99 days.
G.T. of moderate severity but mainly retrogressive.
|
Culture.
(From mediastinal gland.)
|
Calf 1605.
Subcut. Dose: 50·0 mg
Died in 54 days.
Severe general tuberculosis.

Calf 1533.
Subcut. Dose: 50·0 mg.
Killed after 98 days.
Slight retrogressive G.T.

Rabbit 2311.
|
Cultures
(Kidney and lung).
|
Rabbits 2498–2502.
Died in 43 to 69 days.
General tuberculosis.

1st Passage.—The strain from the mediastinal gland of Calf 1417 was inoculated subcutaneously into two calves, dose in each case 50 milligrammes, and into three rabbits (10 mg. each) and one monkey (1 mg.).

Calf 1533 was killed 98 days later and showed slight generalised retrogressive tuberculosis. Calf 1537 was killed after 99 days and showed general tuberculosis of moderate severity, but mainly retrogressive.

Two of the rabbits died in 122 and 193 days and one was killed after 206 days; all showed chronic and not severe generalised tuberculosis. The monkey died in 144 days of chronic general tuberculosis.

2nd Passage.—A culture isolated from the mediastinal gland of Calf 1537 was inoculated subcutaneously into

Calf 1605, dose 50 milligrammes, five rabbits, dose 10 milligrammes each, two monkeys and ten guinea-pigs, dose 1 milligramme each.

Calf 1605 died in 54 days of severe general tuberculosis similar in all respects to that produced by a bovine tubercle bacillus.

The rabbits, the monkeys, and the guinea-pigs also died of general tuberculosis identical with that produced by a bovine tubercle bacillus.

From Rabbit 2311, inoculated with the culture from the mediastinal gland of Calf 1417, two strains of culture were isolated, one from the kidney and one from the lung. The kidney strain produced in three rabbits, inoculated subcutaneously each with 10 milligrammes, severe and rapidly fatal general tuberculosis similar to that produced by a bovine tubercle bacillus. The lung strain caused in one rabbit, inoculated subcutaneously with 9 milligrammes, general tuberculosis fatal in 61 days; another, inoculated subcutaneously with 10 milligrammes, died in 69 days, and showed general tuberculosis, not severe, and insufficient to account for death. The virulence of the latter strain, while higher than the original, was not apparently equal to that of a typical bovine tubercle bacillus.

Series γ.

1st Passage.—The third strain, recovered from the spleen of Calf 1421 (which showed slight disseminated tuberculosis 101 days after a subcutaneous inoculation of 88 milligrammes) was inoculated subcutaneously into Calf 1553, dose 50 milligrammes, and two rabbits, dose in each case 10 milligrammes.

The calf was killed 96 days later and showed slight generalised tuberculosis apparently retrogressive. The two rabbits died in 208 and 234 days of chronic generalised tuberculosis, the lesions in the lungs and kidneys resembling those produced by the human tubercle bacillus intravenously inoculated.

Culture.
(Derived from O.M. through G.P. 2957.)
|
Calf 1421.
Subcut. Dose: 88·0 mg.
Killed after 101 days.
Slight disseminated tuberculosis.
|
Culture.
(From spleen.)
|
Calf 1553.
Subcut. Dose: 50·0 mg.
Killed after 96 days.
Slight generalised tuberculosis, apparently retrogressive.

Cultural Characters.

The cultural characters of the passage cultures were identical with those of the original culture.

SUMMARY.

The culture from virus H. 108, which though possessing the cultural characters of a bovine tubercle bacillus exhibited low virulence for the calf, rabbit, monkey and guinea-pig, was recovered from two calves subcutaneously inoculated with it.

From one of the calves (duration of life 101 days) one strain was isolated from the spleen; this strain had no higher virulence for the calf and rabbit than the original culture.

From the other calf (duration of life 125 days) two strains were isolated, one from the lung and one from the long mediastinal gland.

The strain from the lung produced in all the animals inoculated, calves, rabbits, monkeys and guinea-pigs, rapidly fatal generalised tuberculosis identical with that set up by bovine tubercle bacilli.

The strain from the mediastinal gland had no higher virulence, as was shown by the results of its inoculation into two calves, a series of rabbits, and a monkey; after further residence in the body of a calf (99 days) and also in that of a rabbit (206 days) the strain acquired the virulence typical of the bovine tubercle bacillus.

TABULAR SUMMARIES OF THE PASSAGE EXPERIMENTS WITH VIRUS H. 108. "H.R."

All the Inoculations in the Table are Subcutaneous.

Source of Origin of Culture Inoculated.	Species and Number of Animal Inoculated, Dose, and Result of Inoculation.				
	Calves.	Rabbits.	Rhesus Monkeys.	Guinea-pigs.	
Series *a* (*virulence increased*).					
Original material (through G.P. 2957).	1417. Dose 50 mg. Killed, 125 days. Slight generalised Tuberculosis.	1874 and 1875. Dose 10 mg. each. One was killed after 155 days (slight G. T.), the other died in 90 days (G. T.).	165. Dose 1 mg. Died in 96 days. G. T. of moderate severity.	3053. Dose 1 mg. 3054. Dose 0·1 mg. Died in 82 and 159 days. General Tuberculosis.	*Original virulence of culture.*
Lung of Calf 1417 (1st calf).	1539. Dose 50 mg. Died in 16½ days. Acute Tuberculosis.	2107–8, 2309. Dose 10 mg. each. Died in 31 to 39 days. General Tuberculosis.	307 and 309. Dose 1 mg. each. Died in 28 and 29 days. General Tuberculosis.	3422. Dose 0·1 mg. Died in 44 days. Severe general Tuberculosis.	*Virulence after passage through a calf.*
Bronchial gland of Calf 1539 (2nd calf).	1509. Dose 50 mg. Killed when dying, 29 days. Acute general Tuberculosis.	2325 and 2326. Dose 10 mg. each Died in 36 and 44 days. General Tuberculosis.			*Confirmatory test.*
Series *β* (*virulence increased*).					
Commences with a culture derived from the long mediastinal gland of Calf 1417.					
Mediastinal gland of Calf 1417 (1st calf).	1533 and 1537. Dose 50 mg. each. Killed after 98 and 99 days. Slight retrogressive G. T. in 1533; G. T. of moderate severity in 1537.	2120, 2121, and 2311. Dose 10 mg. each. Two died in 122 and 193 days (chronic G. T., not severe), the third was killed after 206 days and showed G. T., not severe.	311. Dose 1 mg. Died in 144 days. Chronic G. T.		*Virulence of first passage culture.*
Mediastinal gland of Calf 1537 (2nd calf).	1605. Dose 50 mg. Died in 54 days. Severe general Tuberculosis.	2465, 2467, 2478, and 2479. Dose 10 mg. each; and 2477, dose 8 mg. All died of G.T. in from 35 to 74 days.	361 and 363. Dose 1 mg. each. Died in 53 and 58 days; severe G.T.	Ten, Nos. 3920–3929. Dose 1 mg. each. Died in 43 to 70 days; G. T.	*Virulence after passage through two calves.*
Rabbit 2311. (Inoculated with culture from Calf 1417.) Kidney	—	2498–2500. Dose 10 mg. each. Died in 43 to 63 days. General Tuberculosis.			*Virulence after passage through a calf and a rabbit.*
Lung	—	2501. Dose 9 mg. Died in 61 days. G. T. 2502. Dose 10 mg. Died in 69 days. G. T., not severe.			
Series *γ* (*virulence not increased*).					
Original material (through G.P. 2957).	1421. Dose 88 mg. Killed, 101 days. Slight disseminated T.	1997 and 1998. Dose 10 mg. each. Died in 159 and 85 days. (Slight G. T., insufficient to account for death.)			*Original virulence culture.*
Spleen of Calf 1421 (1st calf).	1553. Dose 50 mg. Killed, 96 days. Slight G. T., apparently retrogressive.	2180 and 2181. Dose 10 mg. each. Died in 234 and 208 days. Chronic G. T. not severe.			*Virulence after passag through a calf.*

VIRUS H. 105. "G.S."

Original virulence of culture.

The culture from the original material through the guinea-pig was tested on calves, rabbits, rhesus monkeys, and guinea-pigs.

Calves.—Two calves were inoculated subcutaneously, one with 48 the other with 92 milligrammes. The former was killed after 130 days and showed a mild form of generalised tuberculosis; the latter, killed after 101 days, showed generalised tuberculosis more severe than in the former but not obviously progressive.

Rabbits.—Of the four inoculated subcutaneously two showed when killed after 152 days chronic slowly-progressing general tuberculosis; the other two died from other causes in 111 and 162 days and showed slight general tuberculosis.

Monkeys.—Two monkeys, subcutaneously inoculated each with 1 milligramme, died in 47 and 56 days of general tuberculosis.

Guinea-pigs.—Two guinea-pigs, inoculated subcutaneously (doses 1 and 0·1 milligramme), died of general tuberculosis in 188 and 138 days.

The above tests showed that the culture from the original material was distinctly less virulent for each of the four species than the bovine tubercle bacillus.

Virulence after passage.

Cultures were recovered from each of the two calves inoculated to test the virulence of the original culture and passed through three other calves in succession, a culture intervening between each passage animal.

Culture.
(Derived from original material through G.P. 2950.)
|
Calf 1449.
Subcut.
Dose: 48·0 mg.
Killed after 130 days.
Generalised T., not severe.
|
Culture.
(From popliteal gland.)
|
Calf 1521.
Subcut.
Dose: 50·0 mg.
Killed when very ill, 78 days.
Severe general tuberculosis.
|
Culture.
(From portal gland.)
|
Calf 1465.
Subcut.
Dose: 20·0 mg.
Killed after 62 days.
Slight retrogressive G. T.
|
Culture.
(From bronchial gland.)
|
Calf 1573.
Subcut.
Dose: 47·0 mg.
Killed after 114 days.
Chronic G. T., slowly progressing.
|
Culture.
(From lung.)
|
Rabbits.

Culture.
(From lung.)
|
Calf 1525.
Subcut.
Dose: 50·0 mg.
Killed after 93 days.
Very slight retrogressive G. T.

Series a.

The series began with Calf 1449. Two cultures were isolated, one from the lung and one from a popliteal gland.

1st Passage.—The lung strain produced in a calf (No. 1525) inoculated subcutaneously (dose 50 milligrammes) slight generalised retrogressive tuberculosis.

Two rabbits, inoculated subcutaneously with 10 milligrammes of the same strain, died in 144 and 145 days; one showed general tuberculosis severe in the lungs and kidneys, the other slight generalised tuberculosis.

A monkey inoculated subcutaneously with 1 milligramme of the culture died in 44 days of general tuberculosis. A guinea-pig, inoculated subcutaneously with 0·1 milligramme, died in 80 days and showed general tuberculosis of a chronic fibroid type.

The popliteal gland strain was inoculated subcutaneously into Calf 1521, dose 50 milligrammes, and into two rabbits, doses 1 and 5 milligrammes.

The calf was killed when very ill 78 days later and showed severe generalised progressive tuberculosis.

The rabbits died in 96 and 116 days; both showed generalised tuberculosis, but the disease in neither case was typical of infection with a fully virulent bacillus; the lungs, for example, collapsed partially and were still largely crepitant, and the lesions in them and the kidneys were mainly miliary and not obviously progressive.

2nd Passage.—A culture was isolated from the portal gland of Calf 1521 and inoculated subcutaneously into Calf 1465 (dose 20 milligrammes). The calf was killed 62 days later and showed slight retrogressive general tuberculosis.

Two rabbits inoculated subcutaneously each with 1 milligramme of the culture died, one in 46 days of general tuberculosis equal in severity to that produced by a bovine bacillus, the other in 109 days of paralysis; the latter showed local tuberculosis, scattered caseating nodules in the lungs, one tubercle in a kidney, and no tuberculosis elsewhere.

A monkey, inoculated subcutaneously with 1 milligramme, died in 35 days of general tuberculosis not severe.

A guinea-pig, inoculated subcutaneously with 0·1 milligramme, and one, inoculated intraperitoneally with an equivalent dose, died in 48 days of not very severe general tuberculosis, the lymphatic glands generally being only slightly enlarged and containing in a few cases only a caseous focus or two.

3rd Passage.—A culture was isolated from the bronchial gland of Calf 1465 and inoculated subcutaneously in a dose of 47 milligrammes into Calf 1573; this calf was killed 114 days later and showed moderately severe general tuberculosis, slowly progressing.

Two rabbits were inoculated subcutaneously each with 1 milligramme of the culture; one showed after 122 days generalised tuberculosis, not severe; the other showed after 139 days very slight disseminated tuberculosis.

Two monkeys were inoculated subcutaneously each with 1 milligramme of the culture and died of general tuberculosis in 43 and 55 days.

At this point, after a residence of 270 days in the body of the calf (3 calves) there was no evidence of increased virulence either for the calf or the rabbit or the monkey.

Virulence after passage through four calves.—A culture obtained from the lung of Calf 1573, the fourth of the series, was tested on rabbits and guinea-pigs.

Six rabbits were inoculated subcutaneously each with 10 milligrammes and died of general tuberculosis in from 55 to 113 days. The disease in four of these animals was practically equal in severity to that produced by a bovine tubercle bacillus; the disease in the other two was slightly less severe. The average duration of life of the six was 75·7 days as compared with 53·7 days for bovine tubercle bacilli.

Nine guinea-pigs were inoculated subcutaneously each with 1 milligramme and died of general tuberculosis in periods varying from 36 to 89 days. The disease in three cases was equal in severity to, while in the remainder it was slightly less severe than, that produced by a typical bovine tubercle bacillus.

The results both in rabbits and guinea-pigs showed that the virulence of the culture from Calf 1573 falls little below that of a bovine tubercle bacillus. The culture has been raised in virulence therefore for rabbits and guinea-pigs during its residence in the fourth of a series of calves, since the culture from the third of the series, like the original culture, was distinctly less virulent for these species than the bovine tubercle bacillus.

Series β.

This series began with Calf 1405, inoculated subcutaneously with 92 milligrammes of the original culture, which showed when killed after 101 days general tuberculosis, severe but not apparently progressive.

Culture.

(Derived from O.M. through G.P. 2950.)

|

Calf 1405.

Subcut. Dose: 92·0 mg.
Killed after 101 days.
G.T., severe but not apparently progressive.

|

Culture.

(From popliteal gland.)

|

Calf 1527.

Subcut. Dose: 50·0 mg.
Died in 59 days.
General tuberculosis.

|

Culture.

(From mediastinal gland.)

|

Calf 1557.

Subcut. Dose: 44·0 mg
Killed after 85 days.
G.T. of moderate severity, not apparently progressive.

|

Culture.

(From popliteal gland.)

|

Calf 1591.

Subcut. Dose: 50·0 mg.
Killed after 90 days.
General tuberculosis, not severe and retrogressive.

|

Culture.

|

Rabbits.

1st Passage.—The second calf, No. 1527, was inoculated subcutaneously with 50 milligrammes of culture derived from the popliteal gland of the first calf. Calf 1527 died in 59 days of general tuberculosis.

Two rabbits were inoculated each with 10 milligrammes of the same culture; one died in 50 days, the other in 120 days, of general tuberculosis not severe in either case.

2nd Passage.—A culture was isolated from the mediastinal gland of the second calf, and 44 milligrammes were inoculated subcutaneously into Calf 1557; this calf was killed 85 days later and showed general tuberculosis of moderate severity but not obviously progressive.

Two rabbits inoculated subcutaneously with 1 and 0·5 milligramme of the same strain died in 101 and 159 days of general tuberculosis; the kidneys of each of the rabbits contained numerous nodules resembling exactly those produced by bovine tubercle bacilli; the lungs however were still largely crepitant and presented a miliary type of disease, not the massive pneumonic type characteristic of bovine infections.

3rd Passage.—A culture was isolated from the popliteal gland of Calf 1557 and inoculated subcutaneously in a dose of 50 milligrammes into Calf 1591, and in a dose of 10 milligrammes into each of three rabbits. The calf was killed after 90 days and showed general tuberculosis, not severe and retrogressive. Two of the rabbits died in 58 and 73 days, the third was killed after 94 days; all showed general tuberculosis of a slightly less severe type than that which generally follows the inoculation of an equivalent dose of bovine tubercle bacilli.

Two monkeys inoculated subcutaneously each with 1 milligramme of the 2nd passage culture died of severe general tuberculosis in 74 and 76 days, and two inoculated subcutaneously each with 1 milligramme of the 3rd passage culture died of general tuberculosis in 41 and 42 days.

At this stage of the passage the culture after residing 245 days in the body of the calf (3 calves) showed no higher virulence for the calf or the monkey than the original culture but had apparently higher virulence for the rabbit.

Virulence after passage through four calves.—The virulence for the rabbit was tested again after passage through the fourth calf (Calf 1591); guinea-pigs were also inoculated.

Of three rabbits inoculated subcutaneously each with 10 milligrammes one died in 69 days of a secondary infection, the others were killed after 70 days. Two showed in addition to local tuberculosis severe tuberculosis of the lungs and moderately severe tuberculosis of the kidneys, the third slight tuberculosis of lungs and kidneys. These results were less severe than those obtained with the third passage culture and were slightly more severe than those produced by the original culture.

Of five guinea-pigs inoculated subcutaneously each with 1 milligramme one died and four were killed after 70 days and all showed chronic general tuberculosis similar in type to that produced by the original culture.

The results of the inoculations of the third and fourth passage cultures in rabbits are more severe than those produced by the original culture (though not as severe as after bovine tubercle bacilli) and indicate a slight increase in virulence for this species; this conclusion is not supported, as was the case in the first series, by the results of the guinea-pig inoculations.

Cultural Characters.

The cultural characters of the passage cultures were identical with those of the original culture.

SUMMARY.

A culture possessing the cultural characters but not the high virulence of a bovine tubercle bacillus was passed through two series of three calves in succession; a culture was isolated from each of the calves and inoculated into another calf as well as into rabbits, and sometimes monkeys and guinea-pigs.

The culture from the third calf in each series (duration of residence, 270 and 245 days) was found to be not more virulent for the calf or the monkey than the original culture. For the rabbit the culture of series α was not more virulent than the original culture; the culture of series β on the other hand had apparently higher virulence for this species than the original culture.

The culture from the fourth calf in each series was tested as to virulence on rabbits and guinea pigs. The culture from the fourth calf of series α produced in these animals tuberculosis much more severe than that which followed the inoculation of the original culture and only slightly less severe than that which is produced by a bovine tubercle bacillus; that from the fourth calf of series β appeared to have for the rabbit but not for the guinea-pig slightly higher virulence than the original culture.

The second calf in each series developed more severe disease than the calves inoculated with the original culture, one dying of general tuberculosis in 59 days, the other having to be killed after 78 days. The results of the inoculation experiments on other animals with the cultures used for these calves, and of those on calves with the subsequent passage cultures showed that the severe infections were due to high individual susceptibility of the calves, and not, as was supposed at the time, to an increase in virulence of the virus.

TABULAR SUMMARIES OF THE PASSAGE EXPERIMENTS WITH VIRUS H. 105. "G.S."

All the Inoculations in the Table are Subcutaneous.

	Source of Origin of Culture Inoculated.	Species and Number of Animal Inoculated, Dose, and Result of Inoculation.			
		Calves.	Rabbits.	Rhesus Monkeys.	Guinea-pigs.
	Series α (*virulence of final passage culture increased for rabbit and guinea-pig*).				
Original virulence of culture.	Original material (through G.P. 2950).	1449. Dose 48 mg. Killed 130 days Generalised T., not severe.	1893. Dose 10 mg. 1894. Dose 1 mg. Killed 152 days. Progressive G. T.	175. Dose 1 mg. Died in 47 days. General Tuberculosis.	3080. Dose 1·0 mg. 3079. Dose 0·1 mg. Died in 188 and 138 days. General Tuberculosis.
Virulence of 1st passage culture.	Popliteal gland of Calf 1449 (1st calf).	1521. Dose 50 mg. Killed, very ill, 78 days. Severe G. T.	2083. Dose 1 mg. 2084. Dose 5 mg. Died in 96 and 116 days. General tuberculosis, moderately severe.		
Virulence of 1st passage culture.	Lung of Calf 1449	1525. Dose 50 mg. Killed 93 days. Very slight retrogressive G. T.	2085. Dose 10 mg. 2086. Dose 10 mg. The former died in 144 days of G. T., the latter died in 145 days and showed slight G. T.	303. Dose 1 mg. Died in 44 days General Tuberculosis.	3700. Dose 0·1 mg. Died in 80 days. General Tuberculosis.
Virulence of 2nd passage culture.	Portal gland of Calf 1521 (2nd calf).	1465. Dose 20 mg. Killed 62 days Slight retrogressive G. T.	2293. Dose 1 mg. 2294. Dose 1 mg. The former died of G. T. in 46 days, the latter died of paralysis in 109 days and showed slight generalised T.	297. Dose 1 mg. Died in 35 days. G. T. not severe.	3698. Dose 0·1 mg. Died in 48 days. General Tuberculosis.
Virulence of 3rd passage culture.	Bronchial gland of Calf 1465 (3rd calf).	1573. Dose 47 mg. Killed (well) 114 days Chronic general tuberculosis moderately severe and slowly progressing.	2384. Dose 1 mg. 2385. Dose 1 mg. One died in 122 days and showed generalised tuberculosis, not severe, the other was killed after 139 days and showed very slight disseminated tuberculosis.	341. Dose 1 mg. 343. Dose 1 mg. Died in 43 and 55 days. General Tuberculosis.	
Virulence after passage through four calves.	Lung of Calf 1573 (4th calf).		2483-2488. (six) Dose 10 mg. each All died of General Tuberculosis in from 55 to 113 days.		3944-3953. (ten) Dose 1 mg. each. Nine died of general tuberculosis in from 36 to 89 days; one died prematurely.
	Series β (*virulence for the rabbit slightly increased*).				
Original virulence of culture.	Original material (through G.P. 2950.)	1405. Dose 92 mg. Killed 101 days. G. T., severe, but not apparently progressive.	1971. Dose 10 mg. 1972. Dose 10 mg. Died in 162 and 111 days. Slight G. T.; deaths from other causes.	205. Dose 1 mg. Died 56 days. General Tuberculosis.	
Virulence of 1st passage culture.	Popliteal gland of Calf 1405. (1st calf).	1527. Dose 50 mg. Died 59 days. General Tuberculosis.	2139. Dose 10 mg. 2140. Dose 10 mg. The former died in 50 days, the latter in 120 days of G. T. not severe in either case.		

TABULAR SUMMARIES OF THE PASSAGE EXPERIMENTS WITH VIRUS H. 105. "G.S."—*continued.*

Source of Origin of Culture Inoculated.	Species and Number of Animal Inoculated, Dose, and Result of Inoculation.				
	Calves.	Rabbits.	Rhesus Monkeys.	Guinea-pigs.	
		Series β (*continued*).			
Mediastinal gland of Calf 1527 (2nd calf).	**1557.** Dose 44 mg. Killed 85 days. G. T. of moderate severity not apparently progressive.	**2323.** Dose 1 mg. **2324.** Dose 0·5 mg. Died in 101 and 159 days. General tuberculosis.	**313.** Dose 1 mg. **315.** Dose 1 mg. Died in 76 and 74 days. General Tuberculosis, severe.	**3735.** Dose 0·1 mg. Died in 54 days. General Tuberculosis.	*Virulence of 2nd passage culture.*
Popliteal gland of Calf 1557 (3rd calf).	**1591.** Dose 50 mg. Killed, 90 days. G. T. not severe and retrogressive.	**2447.** Dose 10 mg. **2448.** Dose 10 mg. **2449.** Dose 10 mg. Two died in 58 and 73 days, one was killed after 94 days; all showed G. T.	**357.** Dose 1 mg. **359.** Dose 1 mg. Died in 42 and 41 days. General Tuberculosis.		*Virulence of 3rd passage culture.*
Popliteal gland of Calf 1591. (4th calf).		**2506–2508.** Dose 10 mg. each. One died in 69 days of a secondary infection. the others were killed after 70 days; two showed G. T. severe in lungs, the third slight G. T.		**3995–4000.** (Six) Dose 1 mg. each One died in 37 days (Slight G. T.); one died and four were killed after 70 days (chronic G. T.).	*Virulence after passage through four calves.*

VIRUS H. 107. "H.H."

Original virulence of culture.

The culture derived from the original material through the guinea-pig was tested in calves, rabbits, rhesus monkeys, and guinea-pigs.

Calves.—Two inoculated subcutaneously (doses 50 and 80 milligrammes) and killed 126 and 104 days later showed slight generalised tuberculosis.

Rabbits.—One inoculated subcutaneously with 10 milligrammes died in 165 days of chronic general tuberculosis (the others died prematurely); two inoculated intravenously with 0·01 milligramme died of general tuberculosis in 142 and 149 days.

Monkeys.—Two inoculated subcutaneously, each with 1 milligramme, died in 49 and 50 days; the former showed slight generalised tuberculosis insufficient to account for death, the latter general tuberculosis of moderate severity.

Guinea-pigs.—One inoculated subcutaneously with 1 milligramme died in 116 days of general tuberculosis.

The virulence of the original culture for all four species was therefore much lower than that of a bovine tubercle bacillus, and for two, the monkey and the guinea-pig, lower than that of a human tubercle bacillus.

Virulence after passage.

The culture was passed through two series of calves, each of which began with one of the calves inoculated with the original culture.

Series a.

This series began with Calf 1453, which showed 126 days after 50 milligrammes subcutaneously slight generalised tuberculosis. Cultures were isolated from the lung and spleen.

Culture.
(Derived from original material through G.P. 2955.)

Calf 1453.
Subcut.
Dose: 50·0 mg.
Killed after 126 days.
Slight generalised tuberculosis.

Culture.
(From spleen.)

Calf 1519.
Subcut.
Dose: 50·0 mg.
Died in 47 days.
General tuberculosis.

Culture.
(From bronchial gland.)

Calf 1551.
Subcut.
Dose: 50·0 mg.
Killed after 70 days.
Slight retrogressive generalised T.

Culture.
(From bronchial gland.)

Calf 1577.
Subcut.
Dose: 50·0 mg.
Killed after 103 days.
Very slight disseminated tuberculosis.

Culture.
(From lung.)

Calf 1505.
Subcut.
Dose: 100·0 mg.
Killed after 101 days.
Local T. and a few ulcerated nodules in intestines.

Calf 1513.
Subcut.
Dose: 50·0 mg.
Killed after 102 days.
Slight retrogressive generalised T.

1st Passage.—The lung strain produced slight retrogressive tuberculosis in two calves inoculated subcutaneously with 100 and 50 milligrammes respectively. One rabbit inoculated subcutaneously with 50 milligrammes died of general tuberculosis in 153 days, but two rabbits inoculated with 1 and 3 milligrammes showed after 207 days only slight generalised tuberculosis. Two monkeys inoculated subcutaneously with 1 milligramme of the culture died in 55 and 44 days and showed general tuberculosis not severe enough to account for death.

The spleen strain produced in Calf 1519 inoculated subcutaneously with 50 milligrammes general tuberculosis fatal in 47 days. The disease in this animal was of a type unfamiliar after subcutaneous inoculation and resembled that following an intravenous inoculation of tubercle bacilli. The lungs were almost completely consolidated, the consolidated tissue being dark red, firm, quite airless, and composed of greyish-red tissue peppered with minute whitish tubercles. The spleen, liver, kidneys, and suprarenal bodies all contained numerous grey tubercles, minute and just visible in the liver, miliary or submiliary in the other organs. Tubercle bacilli were numerous in smears from the organs.

Two rabbits inoculated subcutaneously each with 10 milligrammes of the spleen strain showed after 144 and 150 days slight generalised tuberculosis; two inoculated intravenously, one with 0·1 the other with 0·01 milligramme, died of general tuberculosis in 41 and 115 days. For the rabbit therefore the strain exhibited no higher virulence than the original culture.

Two guinea-pigs inoculated each with 1 milligramme of the culture died of general tuberculosis in 74 and 82 days.

2nd Passage.—The passage was continued with a culture isolated from the bronchial gland of Calf 1519; 50 milligrammes of this culture were inoculated subcutaneously into Calf 1551, which showed, when killed 70 days later, slight generalised retrogressive tuberculosis.

The strain was also inoculated into rabbits, a monkey, and a guinea-pig, and produced in these animals no more severe disease than the original culture.

3rd Passage.—The culture was recovered from the bronchial gland of Calf 1551, and tested on a calf, rabbits, and a monkey.

The calf (No. 1577) received 50 milligrammes subcutaneously and showed, when killed 103 days later, very slight disseminated tuberculosis.

Two rabbits each received 10 milligrammes subcutaneously; they were killed after 116 days, and one showed local tuberculosis only, the other a mild form of generalised tuberculosis. The monkey inoculated subcutaneously with 1 milligramme died in 114 days of chronic general tuberculosis.

After a residence, therefore, of 243 days in the body of the calf, the culture had no higher virulence for the calf, rabbit, and monkey than the original culture.

Series β.

This series began with Calf 1497, which showed 104 days after a subcutaneous inoculation of 80 milligrammes of the original culture slight generalised tuberculosis.

Culture.
(Derived from original material through G.P. 2955).
|
Calf 1497.
Subcut. Dose : 80·0 mg.
Killed after 104 days.
Slight generalised tuberculosis.
|
Culture.
(From mediastinal gland).
|
Calf 1549.
Subcut. Dose : 50·0 mg.
Killed after 97 days.
Slight G. T., apparently progressive in thoracic glands.
|
Culture.
(From mediastinal gland.)
|
Calf 1583.
Subcut. Dose : 50·0 mg.
Killed after 127 days.
Very slight disseminated tuberculosis.

1st Passage.—A culture isolated from one of the mediastinal glands of the calf was inoculated subcutaneously into a calf and two rabbits.

The calf (No. 1549), dose 50 milligrammes, showed when killed 97 days later slight general tuberculosis apparently progressive in the thoracic glands. The two rabbits, dose 10 milligrammes each, died in 138 and 163 days and showed chronic and not severe general tuberculosis.

2nd Passage.—The culture was recovered from the mediastinal gland of Calf 1549 and tested subcutaneously on a calf and two rabbits.

The calf received 50 milligrammes and was killed 127 days later ; it showed very slight disseminated tuberculosis resembling exactly that which has frequently been produced by 50 milligrammes of a human Group II. culture.

One of the rabbits, dose 10 milligrammes, died in 138 days and showed only slight retrogressive generalised tuberculosis ; the other, dose 1 milligramme, was killed after 138 days and showed besides local tuberculosis slight tuberculosis of the lungs and moderately severe tuberculosis of the kidneys.

The culture therefore after a residence of 201 days in the body of the calf (two calves) displayed no higher virulence for the calf and the rabbit than the original culture.

Cultural Characters.

The cultural characters of the passage cultures were identical with those of the original culture.

SUMMARY.

The virulence of the culture from H. 107. " H.H." was not increased after a residence of 243 days in one series of three calves and 201 days in another series of two calves ; the species of animals tested with the final cultures were the calf and rabbit, and in one case the monkey.

The severe result in the second calf of series *a* was due either to high susceptibility of the calf or to the entrance of some of the culture into a vein at the time of inoculation.

TABULAR SUMMARIES OF THE PASSAGE EXPERIMENTS WITH VIRUS H. 107. " H.H."

Source of Origin of Culture Inoculated.	Species and Number of Animal Inoculated, Dose, and Result of Inoculation.					
	Calves (subcutaneous).	Rabbits (subcutaneous).	Rabbits (intravenous).	Rhesus monkeys (subcutaneous).	Guinea-pigs (subcutaneous).	
Series *a* (*virulence not increased*).						
Original material (through G.P. 2955).	1453. Dose 50 mg. Killed, 126 days. Slight generalised T.		1897. Dose 1 mg. 1898. Dose 0·1 mg. 1899. Dose 0·01 mg. 1900. Dose 0·01 mg. Died in 18, 21, 142, and 149 days of general tuberculosis.	247. Dose 1 mg. 251. Dose 1 mg. Died in 49 and 50 days. The latter showed G.T. of moderate severity, the former G. T. slight (and insufficient to account for death).	3082. Dose 1 mg. Died in 116 days. General tuberculosis.	*Original virulence of culture.*
Spleen of Calf 1453 (1st calf).	1519. Dose 50 mg. Died, 47 days. General tuberculosis.	2080. Dose 10 mg. Killed 150 days. Slight generalised T.	2077. Dose 0·1 mg. 2078. Dose 0·01 mg. Died in 41 and 115 days. General tuberculosis.		3391. Dose 1 mg. 3392. Dose 1 mg. Died in 74 and 82 days. General tuberculosis.	*Virulence of 1st passage culture.*

TABULAR SUMMARIES OF THE PASSAGE EXPERIMENTS WITH VIRUS H. 107. "H.H."—*continued.*

	Source of Origin of Culture Inoculated.	Species and Number of Animal Inoculated, Dose, and Result of Inoculation.				
		Calves (subcutaneous).	Rabbits (subcutaneous).	Rabbits (intravenous.)	Rhesus Monkeys (subcutaneous).	Guinea-pigs (subcutaneous).
		Series *α* (*virulence not increased*).				
Virulence of 1st passage culture.	**Lung of Calf 1453.**	1505. Dose 100 mg. 1513. Dose 50 mg. Killed after 101 and 102 days. Slight retrogressive tuberculosis.	2103. Dose 50 mg. Died in 153 days. General tuberculosis. 2247 Dose 3 mg. 2246. Dose 1 mg. Killed after 207 and 207 days. Slight generalised T.	2100. Dose 1 mg. 2101. Dose 0·1 mg. 2102. Dose 0·01 mg. Died in 22, 25, and 62 days. General tuberculosis.	285. Dose 1 mg. 287. Dose 1 mg. Died in 55 and 44 days. G. T. not severe (insufficient to account for death).	
Virulence of 2nd passage culture.	**Bronchial gland of Calf 1519** (2nd calf).	1551. Dose 50 mg. Killed, 70 days. Slight retrogressive generalised T.	2253. Dose 42 mg. Died in 145 days. Chronic slight G.T. (insufficient to account for death).	2252. Dose 1 mg. 2251. Dose 0·1 mg. Died in 17 and 36 days. General tuberculosis.	295. Dose 1 mg. Killed after 224 days. Chronic G. T.	3664. Dose 0·1 mg. Died 233 days. General tuberculosis.
Virulence after passage through three calves.	**Bronchial gland of Calf 1551** (3rd calf).	1577. Dose 50 mg. Killed, 103 days. Very slight disseminated tuberculosis.	2403. Dose 10 mg. 2404. Dose 10 mg. Killed after 116 days. One showed local T. only, the other G. T., not severe.		355. Dose 1 mg. Died in 114 days. Chronic G. T.	
		Series *β* (*virulence not increased*).				
Original virulence.	**Original material** (through G.P. 2955).	1497. Dose 80 mg. Killed 104 days. Slight generalised T.	1995. Dose 10 mg. Died 165 days. Chronic G. T.			
Virulence of 1st passage culture.	**Mediastinal gland of Calf 1497** (1st calf).	1549. Dose 50 mg. Killed 97 days. Slight G. T. (apparently progressive in thoracic glands).	2178. Dose 10 mg. 2179. Dose 10 mg. Died in 138 and 163 days. Chronic G. T., not severe.			
Virulence after passage through two calves.	**Mediastinal gland of Calf 1549** (2nd calf).	1583. Dose 50 mg. Killed 127 days. Very slight disseminated tuberculosis.	2387. Dose 10 mg. 2386. Dose 1 mg. The former died in 138 days and showed slight retrogressive G. T., the latter was killed after 138 days and showed generalised T., moderately severe in kidneys.			

VIRUS H. 85. "H.B."

Calves.—Two calves were inoculated subcutaneously with culture from the original material through the guinea-pig, one with 50 the other with 96 milligrammes. The former (No 1289) was killed 94 days later and showed slight generalised tuberculosis, the latter (No. 1331) after 90 days showed local tuberculosis only. Original virulence of culture.

Rabbits.—Two rabbits were inoculated subcutaneously one with 40 the other with 10 milligrammes; the former died in 157 days the latter was killed after 153 days; both showed slight chronic general tuberculosis.

The virulence of the culture therefore for the calf and rabbit was much lower than that of a bovine tubercle bacillus.

Rhesus Monkey.—The culture was less virulent also for the rhesus monkey. One inoculated subcutaneously with 1 milligramme died of general tuberculosis in 132 days, another inoculated subcutaneously with 0·01 milligramme survived 271 days and then died of general tuberculosis.

Passage Experiments.

The culture was tested as to its virulence after passage through a series of five calves, and after a single residence in a monkey. Virulence after passage.

Calf Passage.

The culture was passed through five calves in series. The first calf was inoculated subcutaneously with 50 milligrammes of the original culture, the second with an emulsion of the prescapular gland of the first, and the third with an emulsion of the tuberculous organs of two guinea-pigs inoculated with an emulsion of the prescapular gland of the second.

The fourth and fifth calves were inoculated with cultures obtained in each case from a lesion in the preceding calf.

The first calf (No. 1289) had slight generalised tuberculosis, the second (No. 1319) local tuberculosis, the third (No. 1397) local tuberculosis and a few disseminated lesions.

The fourth calf (No. 1445) which received 50 milligrammes of culture derived from a mediastinal gland of the third calf showed when killed 95 days later generalised tuberculosis, very slight in the great organs, and moderately severe in the thoracic and mesenteric glands, suprarenal bodies and intestines.

The fifth calf (No. 1531) was inoculated with 50 milligrammes of culture derived from a mediastinal gland of Calf 1445, and was killed when well 84 days later; the disease in this animal was more severe than in any of the other passage calves. There were numerous large nodules in the liver and a smaller number of similar ones in the lungs; in other parts of the body the lesions were small and sparsely scattered.

A culture was obtained from one of the liver nodules of Calf 1531 and 50 milligrammes were inoculated subcutaneously into Calf 1565. The calf was killed after 99 days and showed very slight generalised tuberculosis retrogressive in character.

The culture from Calf 1531 and cultures from each of the other passage calves were tested on rabbits subcutaneously the doses varying from 10 to 24 milligrammes; the total number of rabbits inoculated was ten; they were killed or died in periods varying from 120 to 464 days; they all showed a mild form of general tuberculosis similar to that produced by the original culture.

Two monkeys inoculated subcutaneously each with 1 milligramme of the culture from Calf 1531 died prematurely in 39 and 51 days and showed slight generalised tuberculosis.

Culture.
(Derived from original material through G.P. 2363.)
|
Calf 1289.
Subcut. Dose: 50·0 mg.
Killed after 94 days.
Slight generalised tuberculosis.
|
Calf 1319.
Subcut.
Killed after 110 days.
Local tuberculosis.
|
Guinea-pigs.
|
Calf 1397.
Subcut.
Killed after 113 days.
Local tuberculosis and a few disseminated lesions.
|
Culture.
(From mediastinal gland.)
|
Calf 1445.
Subcut. Dose: 50·0 mg.
Killed after 95 days.
General tuberculosis, not severe.
|
Culture.
(From mediastinal gland.)
|
Calf 1531.
Subcut. Dose: 50·0 mg.
Killed after 84 days.
General tuberculosis, moderately severe in liver.
|
Culture.
(From liver.)
|
Calf 1565.
Subcut. Dose: 50·0 mg.
Killed after 99 days.
Generalised tuberculosis, very slight and retrogressive.

Rhesus Monkey Passage.

Culture.
(Derived from original material through G.P. 2365.)

Rhesus Monkey 119.
Subcut. Dose: 0·01 mg.
Died in 271 days.
General tuberculosis.
|
Culture.
(From spleen.)
|
Rhesus Monkey 235.
Subcut. Dose: 1·0 mg.
Died in 48 days.
General tuberculosis, not severe.

Rhesus Monkey 123.
Subcut. Dose: 1·0 mg.
Died in 132 days.
General tuberculosis.

A monkey (No. 119), inoculated subcutaneously with 0·01 milligramme of the original culture died of general tuberculosis in 271 days. A culture was isolated from its spleen and tested as to its virulence for the monkey and rabbit.

The monkey (No. 235) inoculated subcutaneously with 1 milligramme died in 48 days and showed general tuberculosis not severe and apparently insufficient to account for death. For the rabbit the culture was not more virulent than the original culture

Cultural Characters.

The cultural characters of the passage cultures were identical with those of the original culture.

SUMMARY.

The culture from Virus H. 85. "H.B." was passed through five calves in series, the total duration of residence in the body of the calf being 496 days.

The culture recovered from the last calf, the most severely affected of the series, exhibited no higher virulence for the calf, rabbit, or monkey, than the original culture.

After a residence of 271 days in the body of a rhesus monkey the culture was found to be unchanged in its virulence for the monkey and rabbit.

TABULAR SUMMARIES OF THE PASSAGE EXPERIMENTS WITH VIRUS H. 85. "H.B."

I.—CALF PASSAGE.

All the Inoculations in the Table are Subcutaneous.

	Source of Origin of Culture or Tissue Emulsion Inoculated.	Number and Species of Animal, Dose, and Result of Inoculation.	
		Calves.	Rabbits.
Preliminary test inoculations.	Culture from original material (through G.P. 2363).	1289. Dose 50 mg. Killed 94 days. Slight generalised tuberculosis.	1705. Dose 40 mg. Died 157 days 1476. Dose 10 mg. Killed, 153 days. Both showed slight chronic general tuberculosis.
1st passage.	Culture from prescapular gland of Calf 1289 (1st calf). Emulsion of prescapular gland of Calf 1289 (1st calf).	1319. Killed 110 days. Local tuberculosis.	1693. Dose 24 mg. Died 133 days. 1694. Dose 10 mg. Killed 464 days. Both showed very slight chronic generalised tuberculosis.
2nd passage.	Culture from bronchial gland of Calf 1319 (2nd calf) through G.P. 2991. Emulsion of tissues from two guinea-pigs inoculated with an emulsion of prescapular gland of Calf 1319 (2nd calf).	1397. Killed 113 days. Local tuberculosis and a few disseminated lesions.	1921. Dose 20 mg. Died 194 days. 1922. Dose 10 mg. Died 211 days. No. 1921 showed slight G.T. (? cause of death). No. 1922 showed general tuberculosis (not severe).
3rd passage.	Culture from mediastinal gland of Calf 1397 (3rd calf).	1445. Dose 50 mg. Killed 95 days. General tuberculosis, not severe.	2020. Dose 10 mg. Died 137 days. 2021. Dose 10 mg. Killed 209 days. Both showed slight general tuberculosis.
4th passage.	Culture from mediastinal gland of Calf 1445 (4th calf).	1531. Dose 50 mg. Killed 84 days. General tuberculosis, moderately severe in the liver.	2174. Dose 10 mg. Died 134 days. 2175. Dose 10 mg. Died 120 days. Both showed chronic general tuberculosis (not severe).
Final test inoculations.	Culture from liver of Calf 1531 (5th calf).	1565. Dose 50 mg. Killed 99 days. Very slight generalised retrogressive tuberculosis.	2378. Dose 10 mg. Killed 147 days. 2379. Dose 10 mg. Died 144 days. Both showed chronic general tuberculosis, not severe.

II.—RHESUS MONKEY PASSAGE.

	Source of Origin of Culture Inoculated.	Species and Number of Animal, Dose, and Result of Inoculation.	
		Rhesus Monkeys (subcutaneous).	Rabbits (intravenous).
Original virulence of culture.	Culture from original material (through G.P. 2365).	119. Dose 0·01 mg. Died in 271 days. General tuberculosis.	1591. Dose 1 mg. Died 31 days. 1592. Dose 0·1 mg. Died 38 days. General miliary tuberculosis.
Virulence after passage through a monkey.	Culture from spleen of Monkey 119.	235. Dose 1·0 mg. Died in 48 days. General tuberculosis, not severe.	2054. Dose 1 mg. Died 39 days. 2055. Dose 0·1 mg. Died 38 days. General miliary tuberculosis.

VIRUS H. 53. "D.H" (*a*).

The virulence of this culture was tested shortly after its isolation on calves and rabbits.

Original virulence of culture.

Calves.—Three calves were inoculated subcutaneously, each with 50 milligrammes of culture from the original material. They were killed when well after three months; two showed slight generalised tuberculosis, the third a rather more severe generalised tuberculosis.

Rabbits.—Ten rabbits were inoculated intraperitoneally with the original culture, the doses varying from 10 to 0·01 milligrammes. They all died of general tuberculosis in from 13 to 74 days. The duration of life of these animals was a little longer than that of animals inoculated with equivalent doses of bovine tubercle bacilli.

Cultural Characters.—The cultural characters were those of the more easy-going bovine tubercle bacilli.

Virulence test after a single calf passage.

A culture was isolated from one of the calves (905) inoculated with the original culture and was tested on four calves. They were inoculated subcutaneously, two with 50 and two with 10 milligrammes, and were killed when well three months later. In one of the two former the disease was limited to the site of inoculation and the nearest glands; the other showed generalised tuberculosis similar to that produced in the calves inoculated with the original culture. Of the two inoculated with 10 mgs. one showed slight tuberculosis, the other generalised tuberculosis not severe.

The culture was inoculated intraperitoneally into three rabbits (doses 1, 0·1, and 0·01 mg.); they died in 46, 63, and 131 days of general tuberculosis; in the last case it was noted that the disease was scarcely sufficient to account for death.

The above inoculations were performed by Dr. Cobbett and are fully detailed in the Second Interim Report (*see* Appendix Vol. II, pages 882–896); they showed that the culture, though growing like a bovine tubercle bacillus, was distinctly less virulent for the calf and slightly less virulent for the rabbit (intraperitoneal inoculation only) than the bovine tubercle bacillus, and that this virulence was not increased for the calf or the rabbit after a single residence in the body of the calf.

Further Experiments with the Original Culture.

Virulence of the culture after long cultivation.

The culture derived from the original material was tested on various species of animals on different occasions during the period between the 594th and the 1,124th day after its isolation.

Calves.—Two calves (Nos. 1135 and 1155) were inoculated subcutaneously each with 50 milligrammes of culture (after 688 days artificial cultivation) and were killed 79 and 136 days later respectively; in the first there was very slight disseminated tuberculosis; in the second the lesions were more generalised but the disease was not severe and exhibited retrogressive characters.

Rabbits.—Sixteen rabbits in all were inoculated, seven intravenously, two intraperitoneally, and seven subcutaneously. The intravenous and intraperitoneal animals all died of general tuberculosis but the duration of life was in every case, in some cases considerably, longer than after equivalent doses of bovine tubercle bacilli. Some of the animals inoculated subcutaneously lived a very long time (others died prematurely or were killed); the tuberculosis in every case was much less severe than that which the bovine tubercle bacillus gives rise to.

Monkeys.—One (No. 137) inoculated subcutaneously with 1 milligramme was killed when ill 92 days after inoculation and showed not very severe general tuberculosis; another (No. 93) inoculated with 1 milligramme died in 105 days and showed general tuberculosis less severe than in Monkey 137. Another (135) inoculated subcutaneously with 0·1 milligramme was killed when very ill after 209 days and showed general tuberculosis.

The additional experiments with the culture on calves and rabbits showed that the long cultivation had caused a diminution of the virulence of the culture for the rabbit but had not apparently produced any diminution in its virulence for the calf. The experiments on the monkey showed that the culture was much less virulent for this animal than the bovine or the human tubercle bacillus.

Passage Experiments.

Virulence after passage.

Observations have been made on the virulence of the culture after passage through two series of calves, a series of goats, and after a single passage through a rabbit, each of two monkeys, and a pig.

(i) *Calf Passages.*

The first calf in each series was inoculated with culture from the original material; each succeeding calf was inoculated with emulsions of the tuberculous tissues of the preceding calf or of guinea-pigs which had been inoculated with the calf lesions.

Cultures were isolated from the last animals of the series and tested on calves and rabbits.

Series a

Culture.

(Derived from original material through G.P. 1482.)

|

Calf 1135.

Subcut.

Dose: 50·0 mg.

Killed after 79 days.

|

Calf 1135 was inoculated subcutaneously with 50 mg. of the culture when it had been 688 days in artificial cultivation; the calf was killed when well 79 days later and showed local tuberculosis, scattered gritty foci in the thoracic glands and a tubercle in each suprarenal body.

An emulsion of the prescapular gland of this calf was inoculated subcutaneously into the second calf (No. 1199) which was killed 118 days later. The tuberculous prescapular gland of the second calf was used to inoculate the third calf (No. 1257) which was killed after 94 days. In both calves the disease, though generalised, was slight in extent and exhibited retrogressive characters. Up to this point the passage had lasted 291 days.

A culture obtained from the spleen of the third calf displayed no higher virulence for the calf and rabbit than the original culture.

The passage was continued with the bacilli from the prescapular and left bronchial glands of the third calf.

An emulsion of the prescapular gland was inoculated subcutaneously into Calf 1295; the calf remained well and showed when killed after 101 days very slight generalised tuberculosis. A culture from the portal gland of this calf in a dose of 45 milligrammes subcutaneously gave rise in Calf 1381 to very slight generalised tuberculosis; two rabbits inoculated intravenously with 0·1 and

Calf 1199.
Subcut.
Killed after 118 days.

Calf 1257.
Subcut.
Killed after 94 days.

- *Culture.* → *Calf 1363.* Subcut. Dose: 50·0 mg. Killed after 96 days.
- *Calf 1295.* Subcut. Killed after 101 days. → *Culture.* → *Calf 1381.* Subcut. Dose: 45·0 mg. Killed after 152 days.
- *Guinea-pigs.* → *Guinea-pigs.*
  - *Calf 1341.* Subcut. Killed after 138 days. → *Culture.*
    - *Calf 1473.* Subcut. 47·0 mg. Killed after 92 days.
    - *Calf 1477.* Subcut. 50·0 mg. Killed after 96 days.
  - *Calf 1333.* Subcut. Killed after 135 days.

0·01 milligramme of the culture died of general tuberculosis in 71 days, a duration of life which was longer than that of rabbits inoculated with equivalent doses of the original culture. The total duration of residence of this culture in the body of the calf was 392 days.

An emulsion of the bronchial gland of the third calf (No. 1257) was inoculated into a series of two guinea-pigs; these were killed 28 days later, and in order further to increase the numbers of the tubercle bacilli the emulsified tuberculous tissues were inoculated into a second series of three guinea-pigs. The tuberculous tissues of the latter were emulsified and inoculated subcutaneously into two calves (Nos. 1333 and 1341); the emulsion was very rich in tubercle bacilli.

Calf 1333 was killed when well after 135 days and showed a very limited retrogressive tuberculosis. The same amount of emulsion gave rise in Calf 1341, killed in good health after 138 days, to generalised tuberculosis not severe and not apparently progressive.

A culture isolated from the prescapular gland of Calf 1333 was tested on a series of rabbits intravenously and subcutaneously; the rabbits inoculated intravenously died of general tuberculosis, but the duration of life was longer than that of those inoculated with equivalent doses of the original culture; after subcutaneous inoculation, on the other hand, slightly more severe results were obtained than with the original culture; of two rabbits inoculated subcutaneously (dose in each case 10 mg.), one died in 174 days of general tuberculosis not severe, the other died in 204 days of general tuberculosis severe in the lungs.

A culture isolated from the suprarenal body of Calf 1341 was tested on two calves subcutaneously one receiving 47, the other 50 milligrammes; the calves were killed 92 and 96 days later, and slight generalised tuberculosis only was found in each case.

After a residence therefore of 426 to 429 days in the body of the calf the culture was not increased in virulence for the calf but produced in some of the rabbits subcutaneously inoculated more severe tuberculosis than the original culture; the results after intravenous inoculation, however, were not more severe than were those produced by the original culture (when tested after 688 days artificial cultivation).

Series β.

This series began with Calf 1155 which was inoculated subcutaneously with 50 milligrammes of the original culture. The calf was killed 136 days after inoculation and showed slight generalised tuberculosis.

Culture.
(Derived from original material through G.P. 1482.)

Calf 1155.
Subcut. Dose: 50·0 mg.
Killed after 136 days.

Calf 1231.
Subcut.
Killed after 112 days.

Calf 1269.
Subcut.
Killed after 140 days.

Calf 1367.
Subcut.
Killed after 118 days.

Culture.

Calf 1461.
Subcut. Dose: 50·0 mg.
Killed after 111 days.

Cultures were isolated from the lung and a precrural gland and 10 milligrammes of each culture were subcutaneously inoculated into a rabbit; one rabbit was killed when ill 199 days later, the other died in 163 days; in both there was chronic generalised tuberculosis, not severe in the former.

An emulsion of the caseous prescapular gland of Calf 1155 was made and inoculated subcutaneously into Calf 1231. From the latter calf the bacilli were passed on into a third, and from the third into a fourth calf, an emulsion of the prescapular gland of the preceding calf being used for inoculation in each case. The second, third, and fourth calves were killed after 112, 140, and 118 days respectively, and each showed very slight disseminated tuberculosis.

A culture from the prescapular gland of the second calf was not more virulent for the rabbit (by subcutaneous inoculation) than the original culture.

From the thoracic gland of the fourth calf (No. 1367) a culture was isolated and inoculated into a calf and two rabbits. Fifty milligrammes of the culture produced in the calf (No. 1461) after 111 days local tuberculosis and a few disseminated lesions only.

Two rabbits inoculated subcutaneously each with 10 milligrammes of the culture died in 74 and 162 days of general tuberculosis. The duration of life of these rabbits was shorter, and the disease in the lungs and kidneys more severe than in the rabbits inoculated with the original culture, but not equal in severity to that produced by bovine tubercle bacilli.

The total duration of residence of the culture in the body of the calf was 506 days; this long residence had not produced any increase in the virulence of the culture for the calf, but there was a slight increase in the virulence for the rabbit compared with that of the original culture after 688 days artificial cultivation.

(ii) *Goat Passage.*

The culture was passed through two goats in succession.

Culture.
(Derived from original material through G.P. 1482.)
|
Goat 65. (Kid.)
Subcut. Dose : 10·0 mg.
Died in 38 days.
Local T., severe T. of lungs, few disseminated lesions elsewhere.
|
Goat 57. (Adult.)
Subcut.
Died in 89 days.
Local T., severe T. of lungs, few disseminated lesions elsewhere.
|
Culture
(From mediastinal gland.)
|
Calf 1435.
Subcut. Dose : 50·0 mg.
Killed after 94 days.
Local T. and a few disseminated tubercles.

The first goat, No. 65, a kid, was inoculated subcutaneously with 10 milligrammes of the original culture. It died in 38 days of tuberculosis generalised all over the body and very severe in the lungs.

An emulsion made from the lung of this goat was inoculated subcutaneously into Goat 57, an adult, which died in 89 days of general tuberculosis ; the lungs were severely affected, the spleen and some of the abdominal lymphatic glands slightly. A rabbit inoculated subcutaneously with some of the lung emulsion died in 195 days and showed besides local disease slight tuberculosis of the lungs and kidneys and tuberculosis of the joints of both fore feet and ankles.

The culture was recovered from a mediastinal gland of Goat 57 and was tested subcutaneously on a calf and two rabbits. The calf (No. 1435) received 50 milligrammes and showed after 94 days slight generalised tuberculosis.

The two rabbits received 10 milligrammes each ; one died in 136 days of general tuberculosis of an irregular type, the other died in 162 days and showed chronic general tuberculosis insufficient to account for death.

The virulence of the culture therefore was not increased for the calf and rabbit after a residence of 127 days in the body of the goat.

(iii) *Rhesus Monkey Passages.*

The virulence of the culture for the monkey and the rabbit has been tested in two instances after a single residence in the body of the monkey.

In one case the culture was recovered from the spleen of a monkey (No. 135) which was killed when dying of general tuberculosis 209 days after the subcutaneous inoculation of 0·1 milligramme of the original culture.

a

Culture.
(Derived from original material through G.P. 1482.)
|
Rhesus Monkey 135.
Subcut. Dose : 0·1 mg.
Killed when very ill, 209 days.
General tuberculosis.
|
Culture.
|

Rhesus Monkey 243.	*Rhesus Monkey 245.*
Subcut. Dose 1·0 mg.	Subcut. Dose : 1·0 mg.
Died in 78 days.	Killed when dying in 78 days.
Severe G. T.	Severe G. T.

With this culture two monkeys were inoculated subcutaneously each with 1 milligramme, and three rabbits intravenously with 1, 0·1, and 0·01 milligramme.

The monkeys died on the same day, 78 days after inoculation, of severe generalised tuberculosis ; the disease in these monkeys was much more severe than in any of the monkeys inoculated with the original culture.

The rabbits died of general tuberculosis in 25, 50 and 71 day periods, which agreed very closely with the duration of life of rabbits inoculated with equivalent doses of the original culture.

In the second case the culture was recovered from an animal which had been fed with 1 milligramme of the original culture ; the monkey was killed when well 294 days later and showed general tuberculosis.

β

Culture.
(Derived from original material through G.P. 1482.)
|
Rhesus Monkey 131.
Fed. Dose : 1·0 mg.
Killed after 294 days.
General tuberculosis.
|
Culture.
|

Rhesus Monkey 273.	*Rhesus Monkey 275.*
Subcut. Dose : 1·0 mg.	Subcut. Dose : 1·0 mg.
Died in 60 days.	Died in 51 days.
General tuberculosis, severe.	General tuberculosis.

The culture was obtained direct from the spleen and was inoculated subcutaneously into two monkeys (doses 1 mg.) and two rabbits (doses 10 mg.).

The monkeys died of general tuberculosis in 60 and 51 days respectively ; the disease was very severe in the former, not so severe in the latter.

The two rabbits died in 95 and 113 days and showed slight chronic general tuberculosis very similar in character to that produced by the original culture.

In each case therefore residence in the body of the monkey had apparently increased the virulence of the culture for the monkey but had produced no alteration in it for the rabbit.

Rabbit Passage.

The culture after passage through one calf (alf 905) was inoculated subcutaneously in a dose of 10 milligrammes into Rabbit 1059. The rabbit died 133 days later and showed chronic generalised tuberculosis; one knee-joint was swollen and showed early tuberculosis and from the fluid within it a culture was isolated.

Two rabbits were inoculated subcutaneously with this culture, one with 50, the other with 10 milligrammes; the former died in 118 days and showed slight general tuberculosis, apparently retrogressive; the latter died in 165 days of general tuberculosis, no organ being very severely affected.

Calf 905.
(Inoculated subcutaneously with culture derived from the original material.)
|
Culture.
(Derived from prescapular gland of Calf 905.)
|
Rabbit 1059.
Subcut. Dose: 10·0 mg.
Died in 133 days.
Chronic generalised tuberculosis.
|
Culture.
(from knee joint.)
|

Rabbit 1390.	*Rabbit 1391.*
Subcut. Dose: 50·0 mg. Died in 118 days. G. T. slight and retrogressive.	Subcut. Dose: 10·0 mg. Died in 165 days. General tuberculosis, not severe.

The residence of 133 days in the body of the rabbit had produced no increase in the virulence of the culture for the rabbit.

(iv) *Pig Passage.*

The virulence of the culture for the rabbit has been tested after a single residence in the body of the pig.

Pig 119 (a young pig) was inoculated subcutaneously with 10 milligrammes of the original culture. It was killed 225 days later and showed generalised tuberculosis, not severe and retrogressive.

A culture isolated from a bronchial gland of the pig was inoculated intravenously into three rabbits. Two (doses 1 and 0·1 mg.) died of general tuberculosis in 19 and 33 days; the third (dose 0·01 mg.) died in 107 days of general tuberculosis of a chronic type. The results in these rabbits agree very closely with those which have been obtained after the intravenous inoculation of equivalent doses of the original culture.

No change in the virulence of the culture for the rabbit occurred, therefore, after a residence of 225 days in the body of the pig.

Cultural Characters.

Several of the passage strains of the virus (Calves 1199, 1367, 1231, 1341, Goat 65) produced either on glycerin agar or glycerin potato growths which were almost equal in luxuriance to those produced by human tubercle bacilli, but which were much slower in their development; the growths on potato were not however better than that which had been obtained with the original culture after long cultivation.

Other strains did not produce better growths than when the culture was first tested.

SUMMARY OF THE RESULTS OF THE PASSAGE EXPERIMENTS WITH VIRUS H. 53. "D.H." (*a*)

The virulence of the culture from Virus H. 53. "D.H." (*a*) was tested after residence in the tissues of the calf, the goat, the monkey, the rabbit, and the pig; the culture resembled a bovine tubercle bacillus in its cultural characters, but differed from it in possessing a definitely lower grade of virulence for all the species of animals tested.

After residing 426 and 429 days in a series of four calves, and 506 days in another series of calves, the culture was unchanged in its virulence for the calf. The final culture of one series showed a slight but definite increase in virulence for the rabbit.

There was no change in the virulence of the culture for the calf and rabbit after a residence of 127 days in the tissues of the goat (two animals), or for the rabbit after a residence of 133 days in the body of a rabbit following 91 days in the body of a calf.

The culture recovered in two instances after a single residence (209 and 294 days) in the body of the rhesus monkey produced more severe effects in the monkey than the original culture but was apparently unchanged in its virulence for the rabbit.

The culture recovered after a single residence of 225 days in the body of the pig was unchanged in its virulence for the rabbit.

TABULAR SUMMARY OF THE PASSAGE EXPERIMENTS WITH VIRUS H. 53. "D.H." (*a*).

CALF PASSAGES.

Series *a* (*virulence not increased for calf, ? slightly increased for rabbit*).

Source of Origin of Culture or Tissue Emulsion Inoculated.	Number of Animal Inoculated, Dose, and Result of Inoculation.			
	Calves (subcutaneous).	Rabbits (intravenous).	Rabbits (subcutaneous).	
Culture from original material (through G.P. 1482).	1135. Dose 50 mg. Killed after 79 days. Local T., and a few disseminated lesions.	1715. Dose 1 mg. 1093. Dose 0·1 mg. 1714. Dose 0·01 mg. Died in 23, 33, and 66 days. General Tuberculosis.	957. Dose 10 mg. 1094. Dose 10 mg. Died in 346 and 312 days. Chronic general Tuberculosis, not severe and insufficient to account for death.	*Preliminary test inoculations.*
Culture from prescapular gland of Calf 1135 (1st calf).	—	1322. Dose 1 mg. 1323. Dose 1 mg. Died in 19 and 21 days. General Tuberculosis.		*1st passage.*
Emulsion of prescapular gland of Calf 1135 (1st calf).	1199. Killed after 118 days. Very slight generalised T.			
Emulsion of prescapular gland of Calf 1199 (2nd calf).	1257. Killed after 94 days. Slight generalised T.			*2nd passage.*
Emulsion of prescapular gland of Calf 1257 (3rd calf).	1295. Killed after 101 days. Very slight generalised T.			*3rd passages.*
Bronchial gland of Calf 1257 (through two series of guinea-pigs).	1333. Killed after 135 days. Local T. and three disseminated lesions. 1341. Killed after 138 days. G. T. not severe, and apparently not progressive.			
Culture from spleen of Calf 1257 through a guinea-pig (3rd calf).	1363. Dose 50 mg. Killed after 96 days. Slight generalised T.	1695. Dose 1 mg. 1696. Dose 0·1 mg. Died in 25 and 32 days. General Tuberculosis.	1697. Dose 10 mg. Died in 195 days. General Tuberculosis not severe, but more severe than in 1094. 1698. Dose 5 mg. Died in 206 days. Slight G. T.	*Final test inoculations.*
Culture from prescapular gland of Calf 1257.	—	—	1607. Dose 10 mg. 1608. Dose 10 mg. The latter died of G. T. of moderate severity in 100 days; the former died in 459 days and showed very slight generalised T.	
Culture from portal gland of Calf 1295 (4th calf).	1381. Dose 45 mg. Killed after 152 days. Very slight generalised T.	1818. Dose 0·1 mg. 1819. Dose 0·01 mg. Died in 71 and 71 days. General Tuberculosis.		
Culture from prescapular gland of Calf 1333 (4th calf).	—	1950. Dose 1 mg. 1951. Dose 0·1 mg. 1952. Dose 0·01 mg. The two former died in 27 and 38 days of general miliary T.; the latter died in 133 days, and showed chronic G. T. not very severe.	1953. Dose 10 mg. 1954. Dose 10 mg. The former died in 174 days and showed G. T. not very severe; the latter died of severe G. T. in 204 days.	
Culture from suprarenal body of Calf 1341 (4th calf).	1473. Dose 47 mg. 1477. Dose 50 mg. Killed after 92 and 96 days. Slight generalised T			

TABULAR SUMMARY OF THE PASSAGE EXPERIMENTS WITH VIRUS H. 53. "D.H." (*a*)—*continued.*

Series β (*virulence not increased for calf, slightly increased for rabbit*).

	Source of Origin of Culture or Tissue Emulsion Inoculated.	Species and Number of Animal Inoculated, Dose, and Result of Inoculation.	
		Calves (subcutaneous).	Rabbits (subcutaneous).
Preliminary test inoculations.	Culture from original material (through G.P. 1482).	1155. Dose 50 mg. Killed after 136 days. Slight generalised Tuberculosis.	957. Dose 10 mg. Died 346 days. 1094. Dose 10 mg. Died 312 days. Chronic general tuberculosis, not severe and insufficient to account for death.
1st passage.	Culture from lung of Calf 1155 (1st calf).	—	1504. Dose 10 mg. Killed (when ill) 199 days. Chronic general Tuberculosis, not severe.
	Culture from precrural gland of Calf 1155.	—	1501. Dose 10 mg. Died 163 days. Chronic general Tuberculosis.
	Emulsion of prescapular gland of Calf 1155 (1st calf).	1231. Killed after 112 days. Local Tuberculosis and a few disseminated lesions.	—
2nd passage.	Culture from prescapular gland of Calf 1231 (2nd calf).	—	1609. Dose 10–15 mg. Died 310 days. 1610. Dose 10–15 mg. Died 197 days. Chronic general Tuberculosis.
	Emulsion of prescapular gland of Calf 1231 (2nd calf).	1269. Killed after 140 days. Local Tuberculosis with a few disseminated lesions.	—
3rd passage.	Emulsion of prescapular gland of Calf 1269 (3rd calf).	1367. Killed after 118 days. Very slight generalised Tuberculosis.	
Final test inoculations.	Culture from thoracic gland of Calf 1367 (4th calf).	1461. Dose 50 mg. Killed after 111 days. Local Tuberculosis and a few disseminated lesions.	2050. Dose 10 mg. Died 162 days. 2051. Dose 10 mg. Died 74 days. General Tuberculosis.

GOAT PASSAGE (*virulence not increased*).

	Source of Origin of Culture Inoculated.	Species and Number of Animal Inoculated, Dose, and Result of Inoculation.		
		Goats (subcutaneous).	Calf (subcutaneous).	Rabbits (subcutaneous).
Preliminary test inoculations.	Original material (through G.P. 1482).	65 (kid). Dose 10 mg. Died in 38 days. Severe T. of lungs; few tubercles in abdominal organs.	—	1717. Dose 10 mg. Died 84 days. Chronic general Tuberculosis, not severe.
1st passage.	Emulsion of lung of Goat 65 (1st goat).	57 (adult). Died in 89 days. Severe T. of lungs, slight T. of spleen and abdominal glands.		
Final test inoculations.	Culture from mediastinal gland of Goat 57 (2nd goat).	—	1435. Dose 50 mg. Killed after 94 days. Slight generalised Tuberculosis.	2006. Dose 10 mg. 2005. Dose 1·0 mg. The former died of general tuberculosis in 136 days, the latter died in 162 days and showed chronic G. T. insufficient to account for death.

TABULAR SUMMARY OF THE PASSAGE EXPERIMENTS WITH VIRUS H. 53. "D.H." (*a*)—*continued.*

RHESUS MONKEY PASSAGES.

Series *α*. (*Virulence increased for monkey, not for rabbit*).

Source of Origin of Culture Inoculated.	Species and Number of Animal Inoculated, Dose, and Result of Inoculation.			
	Rhesus Monkeys (subcutaneous).		Rabbits (intravenous).	
Original material (through G.P. 1482).	135. Dose 0·1 mg. Killed, when very ill, 209 days. General Tuberculosis.	(Controls.) 93 and 137. Dose 1 mg. each. One was killed after 92 days, the other died in 105 days; both showed G. T., not severe.	1715. Dose 1 mg. Died 23 days. 1714. Dose 0·01 mg. Died 66 days. General Tuberculosis.	*Original virulence of culture.*
Spleen of Monkey 135	243. Dose 1 mg. 245. Dose 1 mg. Both died in 78 days of severe general Tuberculosis.		2059. Dose 1 mg. Died 25 days. 2060. Dose 0·1 mg. Died 50 days. 2061. Dose 0·01 mg. Died 71 days. General Tuberculosis.	*Virulence after passage through a monkey.*

Series *β*. (*Virulence increased for monkey, not for rabbit*).

Source of Origin of Culture Inoculated.	Species and Number of Animal Inoculated, Dose, and Result of Inoculation.		
	Rhesus Monkeys (one fed, the others subcutaneous).	Rabbits (subcutaneous).	
Original material (through G.P. 1482).	131 (Fed). Dose 1 mg. Killed (when well) after 294 days. General Tuberculosis.	1717. Dose 10 mg. Died 84 days. Chronic general Tuberculosis, not severe.	*Original virulence of culture.*
Spleen of Monkey 131	273. Dose 1 mg. 275. Dose 1 mg. Both died of general Tuberculosis, in 60 and 51 days respectively.	2190. Dose 10 mg. Died 95 days. 2191. Dose 10 mg. Died 113 days Slight chronic general Tuberculosis.	*Virulence after passage through a monkey.*

PIG PASSAGE (*virulence not increased*).

Source of Origin of Culture Inoculated.	Species and Number of Animal Inoculated, Dose, and Result of Inoculation.		
	Pig (subcutaneous).	Rabbits (intravenous).	
Original material (through G.P. 1482).	119. Dose 10 mg. Killed after 225 days. General Tuberculosis, not severe and retrogressive.	1715. Dose 1 mg. Died 23 days. 1714. Dose 0·01 mg. Died 66 days. General Tuberculosis.	*Original virulence of culture.*
Bronchial gland of Pig 119.	—	2062. Dose 1 mg. Died 19 days. 2063. Dose 0·1 mg. Died 33 days. 2064. Dose 0·01 mg. Died 107 days. General Tuberculosis.	*Virulence after passage through a pig.*

VIRUS H. 53. "D.H. (*b*).

Original virulence of culture.

This culture was obtained after the lapse of 3 years 7 months from the same situation in the same patient as the culture from Virus H. 53. "D H." (*a*).

It was tested on calves, rabbits, monkeys, and guinea-pigs.

Calves.—Three calves were inoculated subcutaneously each with 50 milligrammes of culture (two different strains were used).

Calf 1507 was killed when dying 63 days later and showed general tuberculosis, and Calf 1545 died in 52 days of general tuberculosis. The disease in these two animals was of an unusual type and unlike that produced after a similar period of time by the bovine tubercle bacillus; the condition in the lungs suggested an intravenous inoculation, the lesions being numerous and very small and the parenchyma extensively hepatised, and the liver was practically normal in each case. The third calf, Calf 1535, killed when well 103 days after inoculation, was found to have a mild form of generalised tuberculosis, the lesions exhibiting retrogressive characters.

Rabbits.—Ten rabbits were inoculated intravenously with doses varying from 1 to 0·01 milligramme; they all died of general tuberculosis, but the duration of life was prolonged as compared with that of rabbits inoculated with bovine tubercle bacilli; two each of which received 0·01 milligramme lived 70 and 136 days.

Four rabbits were inoculated subcutaneously each with 10 milligrammes; two died prematurely 44 and 56 days and showed slight generalised tuberculosis insufficient to account for death; the other two died in 95 and 111 days of general tuberculosis, moderately severe in the first, of moderate severity in the lungs only in the second. Two inoculated subcutaneously one with 5 milligrammes and one with 1 milligramme showed after 81 and 201 days slight generalised tuberculosis.

Rhesus Monkeys.—Four were inoculated subcutaneously each with 1 milligramme of culture; they all died prematurely in 14, 33, 34, and 35 days; in one of the latter the disease was limited to the site of inoculation, but microscopically tubercle bacilli were found all over the body; of the others two showed slight generalised tuberculosis, the third (14 days) a small local lesion only.

The above summary of the virulence tests shows that the culture D.H. (*b*) was more virulent for the calves inoculated than the first culture (D.H. (*a*)), two out of three developing fatal tuberculosis while none inoculated with culture—(*a*) became fatally infected.

For the rabbit culture—(*b*) had not definitely higher virulence than culture—(*a*).

The monkey experiments are unsatisfactory, but it is to be noted that none of the three animals which lived 4 or nearly 5 weeks, the period at which most of the monkeys inoculated with bovine tubercle bacilli died of acute tuberculosis, showed more than slight generalised tuberculosis.

Virulence after passage.

Observations have been made on the virulence of the culture after passage through two series of calves.

Series a.

Culture.
(Derived from original material through G.P. 3215.)

Calf 1507.
Subcut. Dose: 50·0 mg.
Killed when moribund 63 days.
General tuberculosis.

Culture.
(From portal gland.)

Calf 1555.
Subcut. Dose: 50·0 mg.
Died (of pneumonia) 26 days.
Early generalised tuberculosis.

Culture.
(From small mediastinal gland.)

Calf 1563.
Subcut. Dose 50·0 mg.
Killed when very ill 87 days.
General tuberculosis, severe.

Culture.
(From popliteal gland.)

Calf 1599.
Subcut. Dose: 50·0 mg.
Killed when well 105 days.
Slight retrogressive generalised tuberculosis.

Calf 1559.
Subcut. Dose: 50·0 mg.
Killed after 111 days.
Slight general tuberculosis.

The first calf of the series was inoculated with 50 milligrammes of the original culture (G.P. 3215 strain) and was killed 63 days later when dying of general tuberculosis, not typical of infection with a bovine tubercle bacillus.

A culture was isolated from one of the portal glands which was inoculated subcutaneously into a calf and at the same time into rabbits and monkeys.

The calf (Calf 1555) which received 50 milligrammes died in 26 days of non-tuberculous pneumonia and showed on post-mortem examination early general tuberculosis. (Later on the culture was tested in a dose of 50 milligrammes on another calf which remained well and showed after 111 days only slight generalised tuberculosis.)

Three rabbits were inoculated subcutaneously each with 10 milligrammes; two died in 125 and 169 days and showed slight chronic general tuberculosis, the third died in 103 days of moderately severe general tuberculosis; a rabbit inoculated intravenously with 0·01 milligramme of the culture died in 73 days of general tuberculosis.

Two monkeys inoculated subcutaneously each with 1 milligramme died in 51 and 57 days of general tuberculosis, severe in the latter not so severe in the former.

The culture was recovered from one of the mediastinal glands of Calf 1555 and inoculated into a calf, a series of rabbits and two monkeys.

The calf (Calf 1563) received 50 milligrammes subcutaneously and was killed when very ill 87 days later. It showed severe generalised tuberculosis indistinguishable from that set up by bovine tubercle bacilli.

Rabbits inoculated subcutaneously and intravenously with the culture were not more severely affected than those inoculated with the original or first passage cultures.

Two monkeys inoculated subcutaneously each with 1 milligramme died of general tuberculosis in 59 and 68 days.

A culture isolated from a popliteal gland of Calf 1563 was tested on a calf and three rabbits subcutaneously.

The calf (No. 1599) received 50 milligrammes and was killed 105 days later; it showed slight generalised tuberculosis. The rabbits showed after 134 to 192 days slight chronic general tuberculosis.

Thus after a residence of 176 days in the body of the calf (3 calves) the culture produced in the calf less severe disease than the original culture and no more severe disease than culture—(*a*).

Series β

Culture.

(Derived from original material through G.P. 3216.)

Calf 1545.

Subcut. Dose: 50·0 mg. Died in 52 days. General tuberculosis.

Culture.

(From portal gland.)

Calf 1561.

Subcut. Dose: 50·0 mg. Killed when dying: 39 days. Acute miliary tuberculosis.

Culture.

(From a mediastinal gland.)

Calf 1571.

Subcut. Dose: 50·0 mg. Killed after 111 days. Local tuberculosis and a few disseminated lesions.

Calf 1535.

Subcut. Dose: 50·0 mg. Killed after 103 days. Slight generalised tuberculosis.

The first calf (No. 1545) of this series was inoculated subcutaneously with 50 milligrammes of the original culture (G.P. 3216 strain). It died in 52 days of general tuberculosis of an unusual type (another calf inoculated at the same time developed only slight generalised tuberculosis).

A culture was raised from a portal gland of Calf 1545, and was inoculated into a calf, a series of rabbits, and two monkeys.

The calf (No. 1561) received 50 milligrammes subcutaneously, and was killed when dying 39 days later of an acute miliary tuberculosis.

A rabbit inoculated subcutaneously with 10 milligrammes of the culture died in 106 days, and showed very slight generalised tuberculosis.

Two monkeys inoculated subcutaneously each with one milligramme died of general tuberculosis in 46 and 54 days respectively.

A culture isolated from the mediastinal gland of the second calf was tested subcutaneously on a calf, two rabbits, and two monkeys.

The calf (No. 1571) received 50 milligrammes subcutaneously, and showed, when killed 111 days later very slight disseminated tuberculosis very similar to that which has often been produced by Group II. cultures.

One of the rabbits (dose 9 milligrammes) died in 116 days and showed slight general tuberculosis not sufficient to account for death. The other rabbit (dose 10 milligrammes) was killed after 130 days; the disease in this animal was even less severe than in the first one.

The two monkeys received 1 milligramme each subcutaneously. One died in 33 days of general tuberculosis; the other died in 40 days and showed slight general tuberculosis.

The result in this series was the same as in series *α*; the virulence of the culture was not increased for the calf and rabbit after a residence of 91 days in the body of the calf (2 calves).

Cultural Characters.

The cultural characters of the passage cultures were identical with those of the original culture.

SUMMARY.

The cultures from Virus H. 53. "D.H." (*b*) produced fatal tuberculosis in two out of the three calves inoculated, and appeared therefore to possess higher virulence for the calf than the culture (D.H. (*a*)) obtained from the same patient $3\frac{7}{12}$ years previously. For the rabbit the culture did not exhibit definitely higher virulence than culture—(*a*); and the experiments on the monkey, though unsatisfactory in terminating prematurely, showed quite conclusively that the culture had not the high virulence that the results in the calves would lead one to expect.

The culture was recovered from each of the two severely affected calves and passed in one case through two other calves in series and in the other through a second calf, a culture intervening between each passage animal.

In each series the culture from the last animal produced in the calf less severe disease than the original culture.

The various passage cultures, including the last, in each series produced in rabbits no more severe disease than the original culture.

For the monkey the virulence of the various passage cultures was moderately uniform and was definitely though only slightly lower than that of a bovine tubercle bacillus, but whether or no this virulence was higher than that of the original culture cannot be stated since all the monkeys inoculated with the latter died prematurely.

TABULAR SUMMARIES OF THE PASSAGE EXPERIMENTS WITH VIRUS H. 53. "D.H." (*b*).

	Source of Origin of Culture.	Species and Number of Animal, Dose, and Result of Inoculation.			
		Calves (subcutaneous).	Rabbits (subcutaneous).	Rabbits (intravenous).	Rhesus Monkeys (subcutaneous).
		Series *α* (*virulence not increased*).			
Original virulence.	Original material (through G.P. 3215).	1507. Dose 50 mg. Killed (dying) 63 days General Tuberculosis.	—	2065. Dose 1 mg. 2066. Dose 0·1 mg. 2067. Dose 0·1 mg. 2068. Dose 0·01 mg. Died of general tuberculosis in 27, 36, 25, and 136 days.	
Virulence of 1st passage culture.	Portal gland of Calf 1507 (1st calf).	1555. Dose 50 mg. Died (of pneumonia) in 26 days. Early general Tuberculosis. 1559. Dose 50 mg. Killed after 111 days. Slight generalised T.	2182. Dose 10 mg. 2183. Dose 10 mg. Died in 125 and 169 days. Slight chronic general Tuberculosis. 2224. Dose 10 mg. Died in 103 days. General Tuberculosis.	2346. Dose 1 mg. 2345. Dose 0·1 mg. 2344. Dose 0·01 mg. Died of general Tuberculosis in 15, 19, and 73 days.	277. Dose 1 mg. 279. Dose 1 mg. Died in 51 and 57 days. General Tuberculosis (severe in 279).
Virulence of 2nd passage culture.	Mediastinal gland of Calf 1555 (2nd calf).	1563. Dose 50 mg. Killed (very ill) 87 days. Acute miliary Tuberculosis.	2355. Dose 47 mg. 2356. Dose 10 mg. Died in 61 and 123 days. General Tuberculosis, not severe.	2352. Dose 0·1 mg. 2353. Dose 0·1 mg. Died in 34 and 22 days. General Tuberculosis.	325. Dose 1 mg. 327. Dose 1 mg. Died in 59 and 68 days. Severe general Tuberculosis.
Virulence after passage through three calves.	Popliteal gland of Calf 1563 (3rd calf).	1599. Dose 50 mg. Killed after 105 days. Slight generalised T.	2464. Dose 10 mg. 2463. Dose 5 mg. 2462. Dose 5 mg. All died or were killed in from 134 to 192 days and showed slight chronic G. T.		
		Series *β* (*virulence not increased*).			
Original virulence.	Original material (through G.P. 3216).	1545. Dose 50 mg. Died 52 days. General Tuberculosis. 1535. Dose 50 mg. Killed after 103 days. Slight generalised T.	2249. Dose 5 mg. 2248. Dose 1 mg. The former died in 81 days, the latter was killed after 201 days; both showed slight generalised Tuberculosis.	2122. Dose 1 mg. 2123. Dose 0·1 mg. 2124. Dose 0·01 mg. Died of general Tuberculosis in 20, 24, and 70 days.	Four were inoculated each with 1 mg.; they died prematurely in from 14 to 35 days; two showed local T. only; in the other two there was slight disseminated Tuberculosis.
Virulence of 1st passage culture.	Portal gland of Calf 1545 (1st calf).	1561. Dose 50 mg. Killed when dying in 39 days. General Tuberculosis.	2351. Dose 10 mg. Died in 106 days. Very slight generalised Tuberculosis.	2350. Dose 0·1 mg. 2349. Dose 0·01 mg. Died in 17 and 44 days. General Tuberculosis.	317. Dose 1 mg. 319. Dose 1 mg. Died in 46 and 54 days. General Tuberculosis.
Virulence after passage through two calves.	Mediastinal gland of Calf 1561 (2nd calf).	1571. Dose 50 mg. Killed 111 days. Local tuberculosis and a few disseminated lesions.	2394. Dose 10 mg. 2393. Dose 9 mg. One was killed after 130 days, the other died in 116 days; both showed slight generalised Tuberculosis.	—	349. Dose 1 mg. 351. Dose 1 mg. Died in 40 and 33 days. General Tuberculosis (slight in 349).

TEST OF VIRULENCE FOR THE RABBIT OF VIRUS H. 71. "L.V." (*a*) AFTER PASSAGE THROUGH A CALF.

Source of Origin of Culture Inoculated.	Species and Number of Animal, Dose, and Result of Inoculation.	
	Calf (subcutaneous).	Rabbits (subcutaneous).
Original material (through G.P. 1937).	1153. Dose 50 mg. Killed after 95 days. Slight retrogressive generalised Tuberculosis.	996. Dose 50 mg. Killed 188 days. 997. Dose 10 mg. Killed 188 days. Local Tuberculosis only.
Bronchial gland of Calf 1153	—	1352. Dose 10 mg. Killed 143 days. 1353. Dose 10 mg. Killed 143 days. Local lesions only.

SUMMARY.

After residing 95 days in the body of the calf the culture of Virus H. 71. "L.V." (*a*) was unchanged in its virulence for the rabbit.

VIRUS H. 102. "N.H."

RHESUS MONKEY PASSAGE.

Rhesus Monkeys.—Two were inoculated subcutaneously each with 1 milligramme of the culture from the original material; they died in 156 and 183 days of general tuberculosis. Original virulence of culture.

Guinea-pigs.—Three guinea-pigs were inoculated subcutaneously, one with 10 milligrammes and two with 1 milligramme each ; they all died of chronic general tuberculosis, the former in 145 days, the two latter in 504 and 462 days.

The culture was recovered from the lung of one of the monkeys (duration of life 156 days) and tested on two monkeys and two guinea-pigs, the dose in each case being 1 milligramme subcutaneously. Virulence after passage.

The two monkeys died of general tuberculosis in 127 and 154 days.

The two guinea-pigs were killed 193 days after inoculation ; one had local tuberculosis only, the other slight generalised retrogressive tuberculosis.

The culture therefore had no higher virulence for the monkey and guinea-pig than the original culture.

SUMMARY.

The culture from Virus H. 102. "N.H." was not increased in virulence for the monkey or the guinea-pig by a residence of 156 days in the body of the monkey.

TABULAR SUMMARY.

Source of Origin of Culture Inoculated.	Species and Number of Animal, Dose, and Result of Inoculation.	
	Rhesus Monkeys (subcutaneous).	Guinea-pigs (subcutaneous).
Original material (through G.P. 2934).	213. Dose 1 mg. Died in 156 days. Chronic general Tuberculosis (death from pneumonia). (Control.) 215. Dose 1 mg. Died in 183 days. Severe chronic general Tuberculosis.	3230. Dose 10 mg. 3056. Dose 1 mg 3058. Dose 1 mg. Died in 145, 504 and 462 days. Chronic general Tuberculosis.
Lung of Monkey 213.	321. Dose 1 mg. Died 154 days. 323. Dose 1 mg. Died 127 days. Chronic general Tuberculosis (very severe in spleen in 323).	3761. Dose 1 mg. 3762. Dose 1 mg. Killed after 193 days. One showed local Tuberculosis only, the other slight generalised retrogressive Tuberculosis.

VIRUS H. 114. "A.U."

RHESUS MONKEY PASSAGE.

Original virulence of culture.

Rhesus Monkeys.—Two were inoculated subcutaneously each with 1 milligramme of the culture derived from the original material; both died of general tuberculosis, one in 100 days, the other in 109 days.

Guinea-pigs.—Two guinea-pigs inoculated subcutaneously each with 1 milligramme died of general tuberculosis in 139 and 256 days.

Virulence after passage.

The culture was recovered from the spleen of one of the monkeys (duration of life 100 days) inoculated to test the virulence of the culture.

It was inoculated subcutaneously into two monkeys and a guinea-pig (dose in each case 1 milligramme). The monkeys died in 75 and 82 days and showed generalised tuberculosis, severe in the former, slight and insufficient to account for death in the latter.

The guinea-pig was killed 279 days after inoculation and showed chronic retrogressive tuberculosis, atypical in character.

SUMMARY.

After a residence of 100 days in the body of the rhesus monkey the culture of Virus H. 114. "A.U." showed no definite increase in virulence for the monkey and was not increased in virulence for the guinea-pig.

TABULAR SUMMARY.

Source of Origin of Culture Inoculated.	Species and Number of Animal, Dose, and Result of Inoculation.	
	Rhesus Monkeys (subcutaneous).	Guinea-pigs (subcutaneous).
Original material (direct).	225. Dose 1 mg. Died in 100 days. General Tuberculosis. (Control). 223. Dose 1 mg. Died in 109 days. General Tuberculosis.	3278. Dose 1 mg. 3279. Dose 1 mg. Died in 139 and 256 days. General Tuberculosis.
Spleen of Monkey 225	269. Dose 1 mg. 271. Dose 1 mg. Died in 75 and 82 days. General Tuberculosis (severe in 269, slight and insufficient to account for death in 271).	3513. Dose 1 mg. Killed after 279 days. Chronic retrogressive tuberculosis of an atypical kind.

VIRUS H. 84. "M.S."

RHESUS MONKEY AND GUINEA-PIG PASSAGES.

Original virulence of culture.

Rhesus Monkeys.—One inoculated subcutaneously with 1 milligramme of the original culture died in 110 days of general tuberculosis.

Guinea-pigs.—Four were inoculated subcutaneously each with 1 milligramme; two died of chronic general tuberculosis (of an unusual type in one) in 223 and 256 days. Another died in 855 days and showed retrogressive tuberculosis; the fourth died in 39 days and showed general tuberculosis less severe than is usually produced by a human Group II bacillus.

Virulence after passage through a monkey.

(*a*) A culture was isolated from a monkey which had been fed with 1 milligramme and which showed when killed 139 days later general progressive tuberculosis of moderate severity.

The recovered culture was inoculated subcutaneously into two monkeys, and into one guinea-pig, the dose in each case being 1 milligramme.

One of the monkeys died prematurely, the other died in 31 days of general tuberculosis.

The guinea-pig died in 29 days of severe general tuberculosis. (A guinea-pig inoculated intraperitoneally with 1 milligramme of the same culture died of general tuberculosis in 20 days.)

The culture exhibited therefore higher virulence for the monkey and guinea-pig than the original culture. The cultural characters of the strain were those of the original culture.

Virulence after passage through a guinea-pig.

(*b*) A culture was isolated from the spleen of a guinea-pig which had been inoculated subcutaneously with 1 milligramme, and which showed after 855 days retrogressive tuberculosis.

The recovered culture was inoculated subcutaneously into two monkeys and ten guinea-pigs, and intravenously into two rabbits, the dose in each case being 1 milligramme.

One of the monkeys died prematurely, the other died in 81 days and showed general tuberculosis not severe except in the spleen.

Five of the guinea-pigs died in from 22 to 57 days, and each showed slight general tuberculosis; one died in 114 days of chronic general tuberculosis; the remaining four were killed after 124 days, and all showed chronic general tuberculosis.

One rabbit died in 36 days, the other was killed after 107 days; both showed very slight tuberculosis of the lungs, and no tuberculosis elsewhere.

The culture exhibited, therefore, no higher virulence for the guinea-pig, rabbit, and monkey than the original culture. The cultural characters were those of the original culture.

SUMMARY.

A culture obtained from the lung of a monkey fed with culture from Virus H. 84. "M.S." possessed higher virulence for the monkey and guinea-pig than the original culture and exhibited the properties of the human tubercle bacillus.

The culture recovered after 855 days residence in the body of a guinea-pig had no higher virulence for the guinea-pig, monkey, and rabbit than the original culture.

TABULAR SUMMARY OF RHESUS MONKEY PASSAGE EXPERIMENT.

All Subcutaneous inoculations (except Monkey 145).

Source of Origin of Culture Inoculated.	Species and Number of Animal, Dose, and Result of Inoculation.	
	Rhesus Monkeys.	Guinea-pigs.
Original material (through G.P. 2277).	145 (Fed). Dose 1 mg. Killed 139 days. General progressive Tuberculosis of moderate severity. (Control.) 143. Dose 1 mg. Died 110 days. General Tuberculosis.	2985, 2986, 2486, 2897. Dose 1 mg. each. Died in 223, 256, 855, and 39 days. The first two showed chronic general tuberculosis (of an unusual type in one), the third healed tuberculosis, the fourth general tuberculosis less severe than is usually produced by a human Group II. bacillus.
Lung of Monkey 145	231. Dose 1 mg. Died in 31 days. General Tuberculosis.	3385. Dose 1 mg. Died in 29 days. General Tuberculosis.

TABULAR SUMMARY OF GUINEA-PIG PASSAGE EXPERIMENT.

Source of Origin of Culture Inoculated.	Species and Number of Animal, Dose, and Result of Inoculation.		
	Guinea-pigs (subcut.).	Rhesus Monkeys (subcut.).	Rabbits (intravenous).
Original material (through G.P. 2277).	2486. Dose 1 mg. Died 855 days. Retrogressive tuberculosis. *For Controls see Table (a).*	143. Dose 1 mg. Died 110 days. General tuberculosis.	1414. Dose 1 mg. Died 100 days. One tubercle in each kidney; no tuberculosis elsewhere.
Spleen of Guinea-pig 2486.	3974—3983 (ten). Dose 1 mg. each. Five died in from 22 to 57 days, and showed slight G.T.; one died in 114 days of chronic G. T., and four were killed after 124 days and showed chronic G. T.	367. Dose 1 mg. Died 81 days. General tuberculosis.	2503 and 2504. Dose 1 mg. each. One died in 36 days, the other was killed after 107 days; both showed very slight T. of the lungs only.

CHARTS OF THE INOCULATION EXPERIMENTS WITH EACH VIRUS AND OF THE PASSAGE EXPERIMENTS WITH CERTAIN OF THE VIRUSES:

FULL POST-MORTEM NOTES OF ALL THE LARGER ANIMALS INOCULATED WITH ORIGINAL AND PASSAGE CULTURES:

ABSTRACTS OF THE POST-MORTEM NOTES OF THE RABBITS INOCULATED WITH PASSAGE CULTURES (PAGES 212, 242, 293, 338, 387, 418, 441).

VIRUS H. 53. "D.H." (*a*).

LUPUS.

CULTURE INOCULATIONS.

I.—October 19, 1906.

The strain was derived from the original material, through G.P. 1482, and had been in cultivation a total period of 594 days.

The culture used was the 18th generation, 21 days old.

RABBITS.

Number.	Method.	Dose.	Duration of Life.	Result.
955	Intrav.	1·0 mg.	D. 22 days	Acute G. T.
953	Intrap.	1·0 mg.	D. 45 „	G. T.
954	Intrap.	0·1 mg.	K. 90 „	G. T.
956	Subcut.	10·0 mg.	K. 90 „	Slight T.
957	Subcut.	10·0 mg.	D. 346 „	G. T.
958	Subcut.	1·0 mg.	D. 76 „	Local lesion. Slight T. of axillary glands, lungs, and kidneys. Cause of death not ascertained.

December 28, 1906.

The strain was derived from the prescapular gland of Calf 905, direct, and had been in artificial cultivation a total period of 361 days.

The culture used was the 13th generation, 21 days old.

RABBITS.

Number.	Method.	Dose.	Duration of Life.	Result.
1055	Intrav.	1·0 mg.	D. 19 days	G. T.
1056	Intrav	0·1 mg.	D. 29 „	G. T.
1057	Intrap.	10·0 mg.	D. 17 „	G. T.
1058	Intrap.	1·0 mg.	D. 104 „	G. T.
1059	Subcut.	10·0 mg.	D. 133 „	Chronic G. T.
1060	Subcut.	1·0 mg.	K. 223 „	Chronic G. T.

II.—January 21, 1907.

The strain was derived from the original material through Guinea-pig 1482, and had been 688 days in artificial cultivation.

The culture used was the 23rd generation, 21 days old.

CALF 1135.

Subcutaneous.
Dose : 50·0 mg.
Killed : April 10, 1907.
79 days.

P.M.—Caseous and partly softened mass surrounded by a fibro-caseo-calcareous zone at seat of inoculation. More than half the left prescapular gland was composed of fibro-caseo-calcareous tissue. There were scattered gritty foci in the thoracic glands, and one tubercle in each suprarenal.

A guinea-pig inoculated with an emulsion of the spleen became tuberculous.

CALF 1155.

Subcutaneous.
Dose : 50·0 mg.
Killed : June 6, 1907.
136 days.

P.M.—The local tumour was fibro-caseo-calcareous. The adjacent glands were largely caseous and softening. In the lungs and spleen were small scattered nodules with grey margins and caseo-calcareous and sometimes softened centres. Moderately numerous softened and caseous or calcareous tubercles and nodules were seen in nearly every lymphatic gland in the body.

RABBITS.

Number.	Method.	Dose.	Duration of Life.	Result.
1093	Intrav.	0·1 mg.	D. 33 days	G. T.
1094	Subcut.	10·0 mg.	D. 312 „	Chronic G. T.
1095	Subcut.	10·0 mg.	D. 86 „	Local T. and T. of nearest glands. Pseudo-tuberculosis in the organs.

GUINEA-PIGS.

Number.	Method.	Dose.	Duration of Life.	Result.
2180	Intrap.	1·0 mg.	D. 18 days	G. T.
2182	Intrap.	0·1 mg.	D. 38 „	G. T.
2181	Subcut.	1·0 mg.	D. 63 „	G. T.
2183	Subcut.	0·1 mg.	D. 75 „	G. T.

FOWLS.

Number.	Method.	Dose.	Duration of Life.	Result.
19	Intrav.	10·0 mg.	D. 14 days	No macroscopic lesions, but T.B. found in all organs.
21	Intrav.	50·0 mg.	D. 12 „	
23	Intrav.	1·0 mg.	K. 114 „	In the spleen and in the liver there was a single doubtful focus.

III.—February 25, 1907.

The strain was derived from the original material, through Guinea-pig 1482, and had been 723 days in artificial cultivation.

The 25th generation of culture was used when 21 days old.

PIG 85.

Subcutaneous.
Dose : 50·0 mg.
Killed : February 26, 1908.
366 days.

P.M. — General tuberculosis, not severe, and evidently not progressive.

PIG 87.

Subcutaneous.
Dose : 10·0 mg.
Killed : October 10, 1907.
227 days.

P.M. — General tuberculosis, not severe, and apparently retrogressive.

PIG 89.

Subcutaneous.
Dose : 1·0 mg.
Killed : June 28, 1907.
123 days.

P.M. — General tuberculosis, not severe.

RHESUS MONKEY 93.

Subcutaneous.
Dose : 1·0 mg.
Died : June 10, 1907.
105 days.

P.M.—Collapsed cyst at seat of inoculation. Adjacent glands caseous and softened. In the lung, liver, and left kidney there were one or more small tubercles; the lung contained also a pea-sized caseous nodule. Many of the lymphatic glands were affected, some being caseous and softened throughout; the ventral mediastinal glands were as large as thrush's eggs, and must have caused the difficulty of respiration noticed during life.

FOWLS.

Number.	Method.	Dose.	Duration of Life.	Result.
31	Intrap.	50·0 mg.	K. 170 days	No T.
29	Intrap.	10·0 mg.	K. 169 „	Two tubercles in the liver only.
27	Intrap.	1·0 mg.	D. 98 „	No T.
35	Subcut.	50·0 mg.	K. 172 „	Small local tumour, composed of tough yellowish material in a thin fibrous wall. No T. elsewhere.
33	Subcut.	10·0 mg.	K. 172 „	Caseo-necrotic nodules set in fibroid tissue at seat of inoculation. No T. elsewhere.

CULTURE INOCULATIONS—*continued.*

VI.—October 28, 1907.

The strain was derived from the original material through G. P. 1482, and had been in artificial cultivation a total period of 968 days.

The culture used was the 37th generation, 21 days old.

BABOON 5.
Fed.
Dose : 1·0 mg.
Died : Jan. 6, 1908.
70 days.

P.M.—The alimentary tract and the glands connected with it was normal. In the lungs there were eight hard nodules with fibrous margins and softened yellow centres and in one of the bronchial glands half-a-dozen yellow softened foci were seen (? spontaneous T.). There was no tuberculosis elsewhere ; the cause of death could not be determined.

BABOON 7.
Subcutaneous.
Dose : 1·0 mg.
Died : December 2, 1907.
35 days.

P.M.—There was an ulcer at the seat of inoculation ; two left axillary glands were much enlarged and composed of breaking-down caseous substance ; other left axillary and one left inguinal glands contained caseous tubercles and foci. The lungs showed sparsely scattered caseating tubercles up to 1 mm. in diameter ; smaller tubercles were seen in the liver and spleen, greyish in colour and sparsely distributed. The cause of death was not apparent.

VII.—February 6, 1908.

The strain was derived from the original material through G.P. 1482 and had been 1069 days in artificial cultivation.

The culture used was the 43rd generation, 21 days old.

FOWL 85.
Intravenous.
Dose : 10·0 mg.
Died : 207 days.
P.M.—No tuberculosis.

GOAT 65 (Kid).
Subcutaneous.
Dose : 10·0 mg.
Died : March 15, 1908.
38 days.

P.M.—Severe tuberculosis of the lungs ; a few tubercles only in the abdominal organs.

PIG 119.
Subcutaneous.
Dose : 10·0 mg.
Killed : September 16, 1908.
225 days.

P.M.—Moderately numerous very calcareous tubercles in lungs, one or two tubercles in spleen and liver. The bronchial portal and several mesenteric glands were beset with calcareous tubercles ; several other lymphatic glands were less severely affected.

CULTURE.

Derived from the bronchial gland.

Inoculated on November 10, 1908, after 55 days artificial cultivation, into :

RABBITS.

Number.	Method.	Dose.	Duration of Life.	Result.
2062	Intrav.	1·0 mg.	D. 19 days	G. T.
2063	Intrav.	0·1 mg.	D. 33 „	G. T.
2064	Intrav.	0·01 mg.	D. 107 „	Chroni G.T.

PIG 121.
Subcutaneous.
Dose : 50·0 mg.
Died : July 1, 1908.
146 days.

P.M.—Severe tuberculosis of the lungs. The abdominal glands contained caseous nodules, but the abdominal organs were free from tuberculosis.

RHESUS MONKEY 129.
Subcutaneous.
Dose : 0·01 mg.
Died : March 28, 1908.
51 days.

P.M.—Small breaking-down caseous local tumour. No tuberculosis elsewhere. The cause of death was not determined.

RHESUS MONKEY 135.
Subcutaneous.
Dose : 0·1 mg.
Killed : September 2, 1908 (when very ill).
209 days.

P.M.—General tuberculosis.

Caseous non-ulcerated local lesion ; axillary, vertebral, and thoracic glands very greatly enlarged caseous and softened. Lungs closely beset with grey tubercles confluent in central parts ; many caseous nodules also in anterior lobes. One tubercle in spleen, a few in kidneys ; four ulcers in intestine ; varying degrees of caseation in many abdominal glands.

RHESUS MONKEY 137.
Subcutaneous.
Dose : 1·0 mg.
Killed : May 8, 1908 (when very ill),
92 days.

P.M.—General tuberculosis.

Ulcerated caseous tumour ; adjacent glands caseous and softened. The lungs contained scattered grey nodules and a patch of firm grey tissue on one caudal lobe. The spleen was enlarged and contained a moderate number of small caseous and softened nodules ; there were five in the liver, one in a suprarenal and a dozen in the kidneys ; half a dozen were seen in the subcutaneous tissues of the body, and they were seen in varying number in most of the lymphatic glands.

RHESUS MONKEY 131.
Fed.
Dose : 1·0 mg.
Killed : November 26, 1908 (when well).
294 days.

P.M.—General tuberculosis.

The majority of the glands of the alimentary tract were slightly enlarged and showed varying degrees of caseation ; the bronchial, splenic and portal glands were similar. There were several small ulcers, and two over 1 cm. in diameter, in the large intestine. One lobe of the lung was fibroid with caseous patches, elsewhere there were a few shotty tubercles. The spleen contained a moderate number of irregular softened caseous nodules, the liver a number of muco-purulent cysts, a caseous nodule and a few small tubercles, the kidneys four tubercles. In the omentum about three dozen caseous nodules were seen.

RABBITS.

Number.	Method.	Dose.	Duration of Life.	Result.
1715	Intrav.	1·0 mg.	D. 23 days	G. T.
1714	Intrav.	0·01 mg.	D. 66 „	G. T.
1716	Subcut.	10·0 mg.	D. 7 „	Cellulitis.
1717	Subcut.	10·0 mg.	D. 84 „	Chronic G. T. death caused probably by septic absorption from local lesion.

VIRUS H. 53. "D.H." (*a*)—*continued.*

CULTURE INOCULATIONS—*continued.*

IV.—May 30, 1907.

The strain was derived from the original material, through G.P. 1482, and had been 817 days in artificial cultivation.

The culture used was the 30th generation, 21 days old.

RAT 57.
Intraperitoneal.
Dose : 50·0 mg
Died : 122 days.
P.M. — No visible lesions. T.B. numerous in organs.

RHESUS MONKEY 101.
Subcutaneous.
Dose : 1·0 mg.
Died : July 11, 1907.
42 days.
P.M.—Caseo - necrotic tumour. Caseous nodules in adjacent glands. Five grey tubercles in lungs ; scattered miliary tubercles in spleen ; one in one kidney. A few lymphatic glands contained caseous foci. Death due to causes other than tuberculosis.

RHESUS MONKEY 103.
Subcutaneous.
Dose : 10·0 mg.
Died : June 22, 1907.
23 days.
P.M.—Caseous tumour. The adjacent glands showed early caseation. The organs appeared normal except the liver which showed a few minute grey foci. T.B. were seen in smears from the spleen and liver.

V.—August 23, 1907.

The strain was derived from the original material, through Guinea-pig 1482, and had been 902 days in artificial cultivation.

The culture used was the 34th generation, 20 days old.

RHESUS MONKEY 109.
Subcutaneous.
Dose : 10·0 mg.
Killed when dying : September 24, 1907.
32 days.
P.M.—General tuberculosis, severe in spleen. There was a large local ulcer and the adjacent glands were much enlarged, caseous, and softened. The lungs and kidneys contained very sparsely scattered opaque whitish tubercles, the liver fairly numerous similar tubercles ; the spleen was closely beset with caseous softened tubercles. Three abdominal glands were extensively caseous ; a few other glands were slightly affected.

RHESUS MONKEY 111.
Subcutaneous.
Dose : 1·0 mg.
Died : October 3, 1907.
41 days.
P.M.—General tuberculosis, rather severe in spleen.
Infiltrating caseous tumour ; adjacent glands enlarged, caseous, and softened. The lungs contained half a dozen, the kidneys four, and the liver a few, small grey tubercles. The spleen was closely beset with soft caseous tubercles. Most of the lymphatic glands were normal.

RHESUS MONKEY 113.
Fed.
Dose : 10·0 mg.
Died : September 12, 1907.
20 days.
P.M.—No tuberculosis.

RHESUS MONKEY 115.
Fed.
Dose : 1·0 mg.
Died : September 14, 1907.
22 days.
P.M.—No tuberculosis.

VIRUS H. 53. "D.H." (*a*)—*continued.*

CULTURE INOCULATIONS—*continued.*

VIII.—April 1, 1908.

The strain was derived from the original material through G.P. 1482. Total duration of artificial cultivation, 1124 days.

The culture used was the 47th generation, 12 days old.

CALF 1391.
Intravenous.
Dose : 1·0 mg.
Killed when dying : May 11, 1908.
40 days.
P.M.—General tuberculosis.

CALF 1395.
Intravenous.
Dose : 5·0 mg.
Died : April 22, 1908.
21 days.
P.M.—Acute general tuberculosis.

GOAT 67 (Adult).
Subcutaneous.
Dose : 10·0 mg.
Died : May 30, 1908.
59 days.
P.M.—Severe tuberculosis of lungs ; few tubercles in spleen and mesenteric glands ; liver and kidneys normal.

RABBITS.

Number.	Method.	Dose.	Duration of Life.	Result.
1804	Intrav.	0·1 mg.	D. 40 days	G. T.
1805	Intrav.	0·01 mg.	D. 131 „	G. T.
1806	Intrav.	0·001 mg.	D. 106 „	G. T

CALF PASSAGE EXPERIMENT (A).

CULTURE.
(From original material through G.P. 1482 after 688 days cultivation.)

JANUARY 21, 1907.

CALF 1135
Subcutaneous.
Dose: 50·0 mg.
Killed: April 10, 1907. 79 days.
P.M.—Caseous local tumour. Left prescapular gland partly fibro-caseo-calcareous. Scattered gritty foci in thoracic glands. One tubercle in each suprarenal

RABBITS.

Number.	Method.	Dose.	Duration of Life.	Result.
1093	Intrav.	0·1 mg.	D. 33 days	G.T.
1094	Subcut.	10·0 mg.	D. 312 „	Chronic G.T.
1095	Subcut.	10·0 mg.	D. 86 „	Local T., and T. of nearest glands. Pseudo-tuberculosis in organs.

E. of prescapular gland—estimated to contain 31¾ million T.B. per cc.

CALF 1199.
Subcutaneous.
Dose: 10·0 cc. (317,600,000 T.B.).
Killed: August 6, 1907. 118 days.
P.M.—Loculated cyst. Caseo-calcareous mass and caseous nodules in left prescapular gland. In the spleen and kidneys were sparsely scattered small tubercles, and one in the left suprarenal. The thoracic and many abdominal glands showed small tubercles mostly calcareous.

RABBITS.

Number.	Method.	Dose.	Duration of Life.	Result.
1243	Intrap.	1·0 cc.	K. 161 days	G.T. apparently slowly progressing.
1244	Subcut.	1·0 cc.	K. 161 „	Slight chronic G. T.

CULTURE.
Derived from the prescapular gland of Calf 1135. Inoculated on June 5, 1907, after 21 days artificial cultivation, into:

RABBITS.

Number.	Method.	Dose.	Duration of Life.	Result.
1322	Intrav.	1·0 mg.	D. 19 days	G. T.
1323	Intrav.	1·0 mg.	D. 21 „	G. T.

E. of prescapular gland (T.B. in moderate numbers).

CALF 1257.
Subcutaneous.
Dose: 10·0 cc. of emulsion.
Killed: November 8, 1907. 94 days.
P.M.—Small fibro-caseous tumour; left prescapular gland caseous. Few scattered tubercles in lungs, spleen, and liver. The thoracic, portal, and many other glands contained one or more small nodules mostly calcareous.

RABBITS.

—	Number.	Method.	Dose.	Duration of Life.	Result.
E. of prescapular gland.	1412	Subcut.	4·0 cc.	K. 232 days	Local lesion. T. of lungs, pleura, and kidney.
E. of bronchial gland.	1413	Subcut.	—	D. 124 days	Local T., and T. of lungs. Death from cellulitis.

E. of prescapular gland. (T.B. moderately numerous.)

CALF 1295.
Subcutaneous.
Dose: 20·0 cc. of emulsion.
Killed: February 17, 1908.
101 days.
P.M.—Small fibro-calcareous tumour; softened caseous nodules in prescapular gland; calcareous foci in thoracic and many abdominal glands.

RABBITS.

Number.	Method.	Dose.	Duration of Life.	Result.
1557	Subcut.	5·0 cc.	D. 117 days	G.T.
1558	Subcut.	5·0 cc.	K. 117 „	Slight G. T.

CULTURE.
(Derived from portal gland. Duration of artificial cultivation, 52 days.)
APRIL 9, 1908.

CALF 1381.
Subcutaneous.
Dose 45·0 mg.
Killed: September 8, 1908.
152 days.
P.M. — Small local tumour composed mainly of thickened skin. Half the left prescapular gland was occupied by caseous substance. Scattered calcareous foci or tubercles were seen in the thoracic portal mesenteric and ileo-colic glands.

RABBITS.

Number.	Method.	Dose.	Duration of Life.	Result.
1817	Intrav.	1·0 mg.	D. 17 days	G. T.; also pseudo-tuberculosis.
1818	Intrav.	0·1 mg.	D. 71 „	G. T.
1819	Intrav.	0·01 mg.	D. 71 „	G. T.

(E. of bronchial gland.)

GUINEA-PIGS 2701-2.

GUINEA-PIGS 2836-8.

JANUARY 11, 1908.

E. of G.P.'s tissues (T.B. extremely numerous).

CALF 1333.
Subcutaneous.
Dose: 10·0 cc. of emulsion.
Killed: May 25, 1908.
135 days.
P.M.—Fibrous-walled abscess. Caseo-calcareous masses in adjacent glands. One tubercle in a Peyer's patch and two in an ileo-colic gland.

RABBITS.

Number.	Method.	Dose.	Duration of Life.	Result.
1653	Subcut.	3·0 cc.	D. 58 days	Early generalised T.
1654	Subcut.	3·0 cc.	D. 71 „	G. T.

CULTURE.
(Derived from prescapular gland. Duration of artificial cultivation 67 days.)

RABBITS.

Number.	Method.	Dose.	Duration of Life.	Result.
1950	Intrav.	1·0 mg.	D. 27 days	General miliary T.
1951	Intrav.	0·1 mg.	D. 38 „	General miliary T.
1952	Intrav.	0·01 mg.	D. 133 „	Chronic G. T. not very severe.
1953	Subcut.	10·0 mg.	D. 174 „	Local lesion; T. of lungs and slight T. of one kidney.
1954	Subcut.	10·0 mg.	D. 204 „	G.T. (not severe).

CALF 1341.
Subcutaneous.
Dose: 10·0 cc. of emulsion.
Killed: May 28, 1908.
138 days.
P.M.—General tuberculosis not severe and apparently not progressive.

CULTURE.
(Derived from suprarenal body. Duration of artificial cultivation 98 days.)
SEPTEMBER 3, 1908.

CALF 1473.
Subcutaneous.
Dose: 47·0 mg.
Killed: December 4, 1908.
92 days.
P.M. — Slight generalised tuberculosis of the usual type.

CALF 1477.
Subcutaneous.
Dose: 50·0 mg.
Killed: December 8, 1908.
96 days.
P.M. — Slight generalised tuberculosis of the usual type.

CULTURE.
Derived from the prescapular gland of Calf 1257. Inoculated on December 19, 1907, after 41 days artificial cultivation.

RABBITS.

Number.	Method.	Dose.	Duration of Life.	Result.
1607	Subcut.	10·0 mg.	D. 459 days	Local T., and slight T. of lungs, pleura, and heart.
1608	Subcut.	10·0 mg.	D. 100 „	G. T.

CULTURE.
Derived from the spleen of Calf 1257 through Guinea-pig 2703. Inoculated on January 25, 1908, after 50 days artificial cultivation.

CALF 1363.
Subcutaneous.
Dose: 50·0 mg.
Killed: April 30, 1908.
96 days.
P.M.—Fibrous-walled cyst. Prescapular gland caseous and softened. Scattered caseous gritty tubercles in spleen and lungs; one in the right suprarenal. Nearly all the lymphatic glands contained caseous or calcareous tubercles.

RABBITS.

Number.	Method.	Dose.	Duration of Life.	Result.
1695	Intrav.	1·0 mg.	D. 25 days	G. T.
1696	Intrav.	0·1 mg.	D. 32 „	Gen. miliary T.
1697	Subcut.	10·0 mg.	D. 195 „	G. T.
1698	Subcut.	5·0 mg.	D. 206 „	Local T., and slight T. of lungs and kidneys.

GUINEA-PIGS.

Number	Method.	Dose.	Duration of Life.	Result.
2916	Intrap.	0·1 mg.	D. 65 days	G. T
2917	Subcut.	0·1 mg.	D. 62 „	G. T

VIRUS H. 53. "D.H." (*a*)—*continued.*
CALF PASSAGE EXPERIMENT (B).

CULTURE.

(From original material through G.P. 1482—after 688 days cultivation.)

JANUARY 21, 1907.

CALF 1155.

Subcutaneous.
Dose : 50·0 mg.
Killed : June 6, 1907.
136 days.

P.M.—Local tumour fibro-caseous; adjacent glands caseous and softening. In the lungs and spleen were small scattered nodules with caseo-calcareous sometimes softened centres. Similar tubercles and nodules were seen in nearly every gland in the body.

RABBITS.

Number.	Method	Dose.	Duration of Life.	Result.
1093	Intrav.	0·1 mg.	D. 33 days	G. T.
1094	Subcut.	10·0 mg.	D. 312 ,,	Chronic G. T.
1095	Subcut.	10·0 mg.	D. 86 ,,	Local T. and T. of nearest glands (pseudo-tuberculosis in organs).

E. of prescapular gland (tubercle bacilli numerous).

CALF 1231.

Subcutaneous.
Dose : 10·0 cc. of emulsion.
Killed : September 26, 1907.
112 days.

P.M. — Local tumour of moderate size, partly cystic. Adjacent glands caseous and softened. Scattered calcareous foci in thoracic glands. A single tubercle in each of two throat glands.

RABBITS.

Number.	Method.	Duration of Life.	Result.
1329	Subcut.	K. 242 days	Local lesion. Slight T. of lungs and kidneys.
1330	Subcut.	D. 146 ,,	G. T.

E. of prescapular gland (tubercle bacilli numerous).

CALF 1269.

Subcutaneous.
Dose : 20·0 cc. of emulsion.
Killed : February 13, 1908.
140 days.

P.M.—Multilocular cyst. Adjacent glands caseo-calcareous. Few calcareous tubercles in thoracic glands and one in a portal gland. One grey tubercle in spleen.

RABBITS.

Number.	Method.	Dose.	Duration of Life.	Result.
1510	Subcut.	3·0 cc.	K. 224 days	Local T. and T. of lungs and kidneys.
1511	Subcut.	3·0 cc.	D. 224 ,,	Chronic G. T.

E. of prescapular gland (tubercle bacilli not numerous).

CALF 1367.

Subcutaneous.
Dose : 10·0 cc. of emulsion.
Killed : June 10, 1908.
118 days.

P.M.—Fibro-calcareous tumour. Adjacent glands fibro-calcareo-caseous. The thoracic and one coeliac gland contained calcareous tubercles. Two throat glands contained each a caseo-purulent nodule. Three tubercles in lung, one in liver, and two in spleen.

RABBITS.

Number.	Method.	Dose.	Duration of Life.	Result.
1730	Subcut.	2·0 cc.	K. 250 days	Chronic G. T., not apparently progressive.
1731	Subcut.	2·0 cc.	D. 140 ,,	Local T. and T. of lungs and kidneys.

CULTURE.

(Derived from thoracic gland—134 days artificial cultivation.)

October 22, 1908.

CALF 1461.

Subcutaneous.
Dose : 50·0 mg.
Killed : February 10, 1909.
111 days.

P.M.—There was a large fibrous-walled cyst at the seat of inoculation. The adjacent glands contained caseous and calcareous patches and tubercles. Two thoracic glands contained a few calcareous foci; the liver contained one grey tubercle; three caseous and softened tubercles were seen in a suprammary gland, and in fluid from the mamma T.B. were seen.

RABBITS.

Number.	Method.	Dose.	Duration of Life.	Result.
2050	Subcut.	10·0 mg.	D. 162 days	G. T.
2051	Subcut.	10·0 mg.	D. 74 ,,	G. T.

VIRUS H. 53. "D.H." (*a*)—*continued.*

VIRULENCE TESTS ON RABBITS OF CULTURES OBTAINED AT INTERMEDIATE STAGES OF THE CALF PASSAGE EXPERIMENT (B).

Culture derived from the lung of Calf 1155 (1st calf). Inoculated on September 14, 1907, after 100 days artificial cultivation.

RABBITS.

Number.	Method.	Dose.	Duration of Life.	Result.
1502	Intrav.	1·0 mg.	D. 21 days	G. T. and coccidiosis of the liver.
1503	Intrap.	1·0 mg.	D. 32 „	G. T.
1504	Subcut.	10·0 mg.	K. 199 „ (when ill).	Chronic G. T.

Culture derived from the precrural gland of Calf 1155 (1st calf). Inoculated on September 14, 1907, after 100 days artificial cultivation.

RABBITS.

Number.	Method.	Dose.	Duration of Life.	Result.
1499	Intrav.	1·0 mg.	D. 26 days	G. T.
1500	Intrap.	1·0 mg.	D. 152 „	G. T.
1501	Subcut.	10·0 mg.	D. 163 „	Chronic G. T.

Culture derived from the prescapular gland of Calf 1231 (2nd calf). Inoculated on December 19, 1907, after 84 days artificial cultivation.

RABBITS.

Number.	Dose.	Method.	Duration of Life.	Result.
1609	1 serum culture each (10·0–15·0 mg.)	Subcut.	D. 310 days	Chronic G. T.
1610		Subcut.	D. 197 „	G. T.

VIRUS H. 53. "D.H." (*a*)—*continued.*

RHESUS MONKEY PASSAGE EXPERIMENTS.

CULTURE.

(Derived from the original material through Guinea-pig 1482.)

FEBRUARY 6, 1908.

RHESUS MONKEY 135.

Subcutaneous.

Dose : 0·1 mg.

Killed when very ill : September 2, 1908.

209 days.

P.M.—General tuberculosis.

CULTURE.

(Derived from the spleen.)

The 5th generation of culture, 10 days old, was used for inoculation on November 5, 1908 ; the total duration of artificial cultivation was 64 days.

RABBITS.

Number.	Method.	Dose.	Duration of Life.	Result.
1715	Intrav.	1·0 mg.	D. 23 days	G. T.
1714	Intrav.	0·01 mg.	D. 66 „	G. T.
1717	Subcut.	10·0 mg.	D. 84 „	Chronic G. T. not severe. Death caused probably by septic absorption from local lesion.

RHESUS MONKEY 131.

Fed.

Dose : 1·0 mg

Killed when well : November 26, 1908.

294 days.

P.M.—General tuberculosis.

CULTURE.

Derived from the spleen of Monkey 131. Inoculated on March 12, 1909, after 106 days artificial cultivation. The culture used was the 6th generation, 18 days old.

RHESUS MONKEY 243.

Subcutaneous.

Dose : 1·0 mg.

Died : January 22, 1909.

78 days.

P.M.—Severe general tuberculosis.

RHESUS MONKEY 245.

Subcutaneous.

Dose : 1·0 mg.

Killed : January 22, 1909 (when moribund).

78 days.

P.M.—Severe general tuberculosis.

RABBITS.

Number.	Method.	Dose.	Duration of Life.	Result.
2059	Intrav.	1·0 mg.	D. 25 days	G. T.
2060	Intrav.	0·1 mg.	D. 50 „	G. T.
2061	Intrav.	0·01 mg.	D. 71 „	G. T.

RHESUS MONKEY 273.

Subcutaneous.

Dose : 1·0 mg.

Died : May 11, 1909.

60 days.

P.M. — General tuberculosis.

RHESUS MONKEY 275.

Subcutaneous.

Dose : 1·0 mg.

Died : May 2, 1909

51 days.

P.M. — General tuberculosis.

RABBITS.

Number.	Method.	Dose.	Duration of Life.	Result.
2190	Subcut.	10·0 mg.	D. 95 days	Slight chronic G. T.
2191	Subcut.	10·0 mg.	D. 113 „	Slight chronic G. T.

VIRUS H. 53. "D. H." (*a*)—*continued.*

FOWL PASSAGE EXPERIMENT.

CULTURE.

(Derived from original material through Guinea-pig 1482.)
February 25, 1907.

FOWL 33.

Subcutaneous.
Dose : 10·0 mg.
Killed : August 16, 1907. 172 days.

P.M.—Group of caseo-necrotic nodules set in fibrous tissue at seat of inoculation only.

CULTURE.

(Derived from the local lesion.)
Inoculated on October 2, 1907, after 47 days artificial cultivation, into :—

FOWL 61.

Intramuscular.
Dose : 2 serum tubes.
Killed : February 14, 1908. 135 days.

P.M.—Cavity at seat of inoculation filled with caseous masses and purulent fluid. No tuberculosis elsewhere.

PIGEON 55.

Intravenous.
Emulsion of local lesion.
Killed : Sept. 29, 1908.
218 days.
Healthy throughout.

GUINEA-PIGS.

—	Number.	Method.	Duration of Life.	Result.
E. of local lesion.	2949	Intrap.	K. 105 days	Healthy throughout.
E. of spleen	2948	Intrap.	K. 105 „	

RABBIT PASSAGE EXPERIMENT.

CALF 905.

(Inoculated subcutaneously with culture derived from the original material.)
Killed : January 1, 1906.

CULTURE.

(Derived from prescapular gland of Calf 905.)
Inoculated on December 28, 1906, after 361 days artificial cultivation, into:—

RABBIT 1059.

Subcutaneous.
Dose : 10·0 mg.
Died : May 10, 1907. 133 days.

P.M.—Ulcerated caseous local lesion. Axillary glands partly caseous. Numerous irregular caseous nodules in lungs, fairly numerous small caseous tubercles in spleen, many grey tubercles and a few caseous tubercles in kidneys. Scattered caseous nodules in the subcutaneous tissues of the groin. Right knee joint was swollen and contained a mucinous substance in which were small flakes (T.B. numerous).

CULTURE.

(Derived from the knee joint.)
Inoculated on July 15, 1907, after 66 days artificial cultivation, into :—

RABBIT 1390.

Subcutaneous.
Dose : 50·0 mg.
Died : November 10, 1907. 118 days.

P.M.—Large thin-walled cyst filled with caseo-pus. Caseo-calcareous nodules in adjacent glands. Scattered grey tubercles with yellow centres in lungs. Two or three minute tubercles in spleen, and few grey tubercles with caseous centres in kidneys.

RABBIT 1391.

Subcutaneous.
Dose : 10·0 mg.
Died : December 27, 1907. 165 days.

P.M.—Local ulcer ; adjacent scapular gland caseous. Lungs showed numerous minute translucent tubercles, and some larger with caseous centres. There were half a dozen small yellow tubercles in liver, and in the kidneys grey tubercles with yellow centres and caseous streaks. On the outer condyle of one femur there was a patch of tuberculous tissue (T.B. numerous) covering bare bone.

VIRUS H. 53. "D.H." (*a*)—*continued.*

GOAT PASSAGE EXPERIMENT.

CULTURE.

(From original material through G.P. 1482—After 1069 days artificial cultivation.)

February 6, 1908.

GOAT 65 (Kid).

Subcutaneous.

Dose : 10·0 mg.

Died : March 15, 1908.

38 days.

P.M.—Severe tuberculosis of the lungs ; a few tubercles only in the abdominal organs.

RABBITS.

Number.	Method.	Dose.	Duration of Life.	Result.
1715	Intrav.	1·0 mg.	D. 23 days	G. T.
1714	Intrav.	0·01 mg.	D. 66 „	G. T.
1717	Subcut.	10·0 mg.	D. 84 „	Chronic G. T., not severe. Death probably caused by septic absorption from local lesion.

Emulsion of lung (T.B. not numerous).

GOAT 57 (Adult).

Subcutaneous.

Dose : 10·0 cc. of emulsion.

Died : June 13, 1908.

89 days.

P.M.—Severe tuberculosis of the lungs. A few tubercles in the spleen and in several abdominal glands.

RABBITS.

Number.	Method.	Dose.	Duration of Life.	Result.
1771	Subcut.	4·0 cc.	D. 36 days	Local T. and early T. of lungs. Psorospermosis of liver.
1772	Subcut.	3·0 cc.	D. 195 days	Chronic G. T., not severe.

CULTURE.

(Derived from the mediastinal gland.)

Inoculated on September 15, 1908, after 94 days artificial cultivation, into :—

CALF 1435.

Subcutaneous.

Dose : 50·0 mg.

Killed : December 18, 1908.

94 days.

P.M.—Large local lesion composed of thickened skin and fibroid tissue containing caseous nodules and a small cavity containing caseo-pus. There were caseous nodules in the subjacent muscles. The left prescapular gland was very large, caseous and softening throughout. About eighteen small caseo-calcareous nodules were counted on the surface of the lungs. One bronchial gland, both suprarenals, and two mesenteric glands each contained a single caseous nodule. Three ileo-colic glands showed caseo-calcareous patches.

RABBITS

Number.	Method.	Dose.	Duration of Life.	Result.
2005	Subcut.	10·0 mg.	D. 162 days	Chronic G.T., insufficient to account for death.
2006	Subcut.	10·0 mg.	D. 136 „	G. T.

CALF 1135. Virus H. 53. "D.H." (*a*).

Subcutaneous inoculation of culture derived from the original material, through G.P. 1482.

Dose—50·0 milligrammes.

Date of Inoculation—January 21, 1907. [Age about 20 weeks.]

Killed when in good health—April 10, 1907. [79 days after inoculation.]

Clinical Notes.

Ten days after inoculation on the left side of the neck there was a flat firm subcutaneous swelling, which measured 8·3 by 11·5 cm. The adjacent prescapular gland was considerably enlarged, measuring 11·5 cm. in length.

Subsequently both the swelling and gland diminished in size; on the 52nd day the former was pear shaped, firm, measuring 6 by 9 cm.; the gland was hard, about 8 cm. in length.

No further changes in the local conditions were noted. The calf remained in good health during the experiment.

Temperature.

On the third day after inoculation the temperature rose to 40·4° C., and remained high (between 39° C. and 40·4° C.) for three weeks. During the remaining period of the experiment it was quite normal.

Tuberculin Test.

The calf was not tested subsequent to inoculation.

Weights.

	cwt.	qrs.	lbs.
January 21, 1907	1	3	15
April 10, 1907	2	1	9

Total gain of weight.—1 qr. 22 lbs.

Average rate of gain per week.—4·5 lbs.

POST-MORTEM EXAMINATION.

The carcass was in good condition.

Local Lesion.—In the subcutaneous tissues on the left side of the neck there was a tense swelling measuring 6 by 5 by 2·5 cm.; on section it was composed of caseous substance partly dense and partly broken down to form thick caseo-pus, surrounded by a narrow zone of translucent fibroid tissue studded with caseo-calcareous tubercles; the skin was intimately adherent to the latter and was thickened; the tumour was adherent also to the muscle, which was not infiltrated.

Left Prescapular Gland.—The left prescapular gland measured 7·5 by 3·5 by 2·5 cm., and was irregular in outline; on section more than half of the gland tissue was replaced by fibro-calcareo-caseous substance, containing here and there some dense irregular homogeneous yellow caseous patches; the capsule at one point was much thickened.

Right Prescapular Gland.—The right prescapular gland measured 5·5 by 2·5 by 1·5 cm. and was normal on section.

Prepectoral and Axillary Glands.—Normal.

Thorax.

Pleura.—Normal.

Lungs.—The lungs collapsed normally, and were crepitant throughout; on the surface as well as on section there were fairly numerous red points, probably petechial haemorrhages; no definite tubercles were seen.

Thoracic Glands.—The bronchial and mediastinal glands, normal in size and general appearance, showed in their cortices scattered yellow gritty foci, some very minute.

Heart.—Normal.

Abdomen.

Omentum and Peritoneum, Spleen, Liver, Kidneys, and Portal Glands.—Normal.

Suprarenals.—Each suprarenal body showed in the cortex one spherical greyish white tubercle, 1 mm. in diameter.

Renal, Lumbar, and Iliac Glands.—Normal.

Alimentary Tract.

Tongue, Pharynx, Palate, Tonsils; Submaxillary, Retro-pharyngeal, Hyoid, and Parotideal Glands.—Normal.

Intestines, Mesenteric, Ileo-colic, and Colic Glands.—Normal.

Mammary Gland and Supramammary Lymphatic Glands.—Normal.

Various Lymphatic Glands.

Precrural, Popliteal, Gluteal, and Ischiatic.—Normal.

Microscopical Examinations.

Emulsion of Prescapular Gland.—Tubercle bacilli fairly numerous.

Foci from Long Mediastinal Gland.—Two tubercle bacilli seen.

Crushed tubercle from the Left Suprarenal.—Twelve tubercle bacilli counted.

Animals Inoculated.

Calf 1199 was inoculated subcutaneously with 10·0 cc. of an emulsion made from the prescapular gland.

Rabbits 1243 and 1244 were inoculated subcutaneously, each with 1 cc. of the same emulsion; they were killed 161 days later, and showed chronic general tuberculosis.

Guinea-pig 2337 was inoculated intraperitoneally with an emulsion made from the spleen; it was killed 89 days later, and showed chronic general tuberculosis.

CALF 1155. Virus H. 53. "D.H." (*a*).

Subcutaneous inoculation of culture derived from the original material through G.P. 1482.

Dose—50·0 milligrammes.

Date of Inoculation—January 21, 1907. [Age about 5 months.]

Killed when in good health—June 6, 1907. [136 days after inoculation.]

Clinical Notes.

Eleven days after the inoculation on the left side or the neck there was a flat firm subcutaneous local thickening, measuring 8·3 by 10·5 cm. The adjacent prescapular gland was enlarged, 10·5 cm. in length. On the 52nd day there was a prominent tumour at the seat of inoculation, measuring 12 by 8 cm., doughy

and semi fluctuant all over. The prescapular gland was 8 cm. in length; the left prepectoral gland was the size of a walnut.

On the 93rd day the swelling burst and discharged caseo-purulent contents.

On the 136th day the calf was killed when in good health. It had remained well during the whole period of the experiment.

Temperature.

On the 9th day the temperature rose to 39·6° C., reaching a maximum of 40·5° C. on the 14th day. It then slowly fell, and was normal on the 38th day. During the remaining period of the experiment the temperature was quite normal.

Tuberculin Test.

May 9, 1907. [108 days after inoculation.]

Reacted. Rise of temperature, 1·9° C.

Weights.

	cwt.	qrs.	lbs.
January 21, 1907	2	1	14
June 6, 1907	3	1	2

Total gain of weight.—3 qrs. 16 lbs.

Average rate of gain per week.—5·2 lbs.

POST-MORTEM EXAMINATION.

The carcass was in good condition.

Local Lesion.—On the left side of the neck there was a firm tumour, 8 cm. in greatest diameter, consisting of greatly thickened skin and a flat subcutaneous patch of pinkish fibroid tissue containing a few small fibrous tubercles with calcareous grains in the centre; in the subcutaneous tissues around the margins of the latter patch and in the muscles under it were several large nodules with thick fibrous walls and yellow caseo-purulent contents. The surface of the skin showed an irregular depressed and puckered scar.

Left Prescapular Gland.—The left prescapular gland measured 6·5 by 4·5 by 3·5 cm., and on section showed more than three quarters of its substance occupied by a caseous tuberculous mass surrounded by a thick fibrous capsule; the peripheral parts of the mass were softened, the rest was dense and formed a loose sequestrum; at one extremity of the gland there was a patch of normal-looking gland tissue which contained small calcareous patches.

Right Prescapular Gland.—The right prescapular gland measured 5·5 by 3·2 by 1·5 cm., and showed on section half a dozen large nodules, up to 8 mm. in diameter, filled with yellow caseo-pus.

Left Prepectoral Glands.—The rounded prepectoral gland was the size of a walnut; on section more than half of the gland was composed of dense pinkish caseo-necrotic substance which was separated from the thickened capsule by a layer of caseo-pus; the rest of the gland showed a cicatricial patch of fibrous tissue and some small calcareous patches.

The reniform gland contained three miliary caseo-calcareous tubercles.

Axillary Glands.—In each there were from six to nine caseo-calcareous nodules up to a hemp seed in size; the larger ones were more softened than the smaller ones.

Cervical Glands.—Three contained each one small caseo-calcareous tubercle.

Near the hyoid bone on each side was a large gland which contained two large yellow caseous and softened nodules, and a few caseo-calcareous tubercles.

Thorax.

Pleura.—Normal.

Lungs.—The lungs were crepitant throughout; they showed under the pleura sparsely scattered nodules (30 were counted on the surface of the right ranging) from about 1 to 4 mm. in diameter; the nodules had fibrous margins and caseo-calcareous centres which in the larger ones were soft, yellow, and purulent.

On section similar nodules were sparsely scattered throughout the lung parenchyma; one in the right caudal lobe was larger than any of the others, measuring 5 mm. in diameter.

Thoracic Glands.—The ventral mediastinal glands contained each a few caseo-calcareous tubercles.

The bronchial and mediastinal glands were little if at all enlarged; they showed on section numerous discrete calcareous tubercles, many not larger than a grain of sand, in several of the glands aggregated together to form irregular calcareous patches.

The inter-bronchial glands were distinctly enlarged, and were more severely affected than the bronchial, the greater part of the gland substance being replaced by calcareous patches.

Heart.—Normal.

Abdomen.

Omentum and Peritoneum.—Normal.

Liver.—No tubercles were seen either on the surface or on section.

Portal Glands.—The portal glands were not enlarged, and contained fairly numerous discrete pinhead sized calcareous tubercles.

Spleen.—The spleen was normal in size and showed on section scattered caseo-calcareous tubercles with grey margins varying in size from a millet to a hemp seed. 30 were counted in a single longitudinal section.

Kidneys.—Normal.

Suprarenal Bodies.—In the cortex of the left there was one grey miliary tubercle with a yellow calcareous centre. The right was normal.

Iliac Glands.—In each there were about half-a-dozen caseo-calcareous tubercles, the largest rather larger than a millet seed; the tubercles readily shelled out from the gland substance.

Lumbar Glands.—One showed scattered tubercles similar to those in the iliac glands; another contained fairly numerous pinhead-sized calcareous tubercles.

Alimentary Tract.

Tongue, Tonsils, Pharynx, Larynx.—Normal.

Submaxillary Glands.—One showed three large pea-sized caseous and softened nodules; the other one large nodule and a small tubercle.

Parotideal Glands.—The parotideal glands were distinctly enlarged, and contained numerous yellow caseous and softened nodules, the largest 1 cm. in diameter; these nodules had congested fibrous capsules which appeared to be lined internally with granulation tissue.

Retro-pharyngeal Glands.—The right was normal. The left contained one pea-sized softened caseous nodule.

Small Intestines.—Three Peyer's patches in the ileum showed under the mucous membrane each one calcareous focus; in the mucous membrane near the margin of one of the above patches was a minute ulcer with slightly raised margins and thickened base showing no sign of caseation or calcification.

Large Intestine.—Normal.

Mesenteric Glands.—There were scattered discrete caseo-calcareous tubercles in each of the mesenteric glands; in those at the extremities of the mesentery there were besides some larger softened nodules.

Ileo-colic Glands.—Three contained nodules similar to those in the terminal mesenteric glands.

Colic and Gastric Glands.—These glands contained sparsely scattered caseo-calcareous tubercles.

Testicles.—Normal.

Various Lymphatic Glands.

Coeliac Glands.—The coeliac glands were not enlarged; they contained scattered caseo-calcareous tubercles up to a millet-seed in size.

Precrural Glands.—Each gland contained about nine softened caseous gritty nodules with fibrous capsules, ranging in size up to a large pea.

Popliteal, Gluteal, and Pudic Glands.—These glands contained nodules similar to those in the precrural; the pudic glands were distinctly enlarged, the others were slightly enlarged.

Microscopical Examinations.

Lung (tubercle from).—Two tubercle bacilli seen.

Lung (soft caseous matter from tubercle).—Four tubercle bacilli seen.

Suprarenal (tubercle from).—Five tubercle bacilli seen.

Intestine (focus from).—No tubercle bacilli seen.

Prescapular Gland (scraping from). — Tubercle bacilli numerous.

Precrural Gland (tubercle from).—Nine tubercle bacilli seen.

Mediastinal Gland (tubercle from).—Six tubercle bacilli seen.

Mediastinal Gland (emulsion of).—Fifteen tubercle bacilli seen.

Animals Inoculated.

Calf 1231 was inoculated subcutaneously with 10·0 cc. of emulsion of the prescapular gland.

Two rabbits (1329 and 1330) were inoculated subcutaneously with the same emulsion. One died of general tuberculosis in 146 days, the other showed slight general tuberculosis when killed after 242 days.

Two guinea-pigs (2466 and 2467) were inoculated intraperitoneally with the emulsion from the prescapular gland; they died of general tuberculosis in 29 and 25 days.

Two (2468 and 2469) were inoculated intraperitoneally with an emulsion made from the mediastinal gland. One died in 55 days, the other was killed after 57 days; both showed general tuberculosis.

CALF 1391. Virus H. 53. "D.H." (*a*).

Intravenous inoculation of culture derived from the original material through Guinea-pig 1482.

Dose—1·0 milligramme.

Date of Inoculation—April 1, 1908. [Age about 13 weeks.]

Killed when dying—May 11, 1908. [40 days after inoculation.]

Clinical Notes.

The course of the disease was similar to that usually seen in acute tuberculosis following an intravenous inoculation.

Temperature.

The temperature rose to 40·0° C. on the 12th day, and remained irregular and fairly high (between 38·9 and 40·4° C.) until a few days before death, when it fell rapidly to below 35·0° C.

Weights.

	cwt.	qr.	lbs.
April 1, 1908	1	0	25
May 11, 1908	1	0	3

Total loss of weight.—22 lbs.

Average rate of loss per week.—3·8 lbs.

POST-MORTEM EXAMINATION.

The carcass was emaciated.

Local Lesion.—On the wall of the jugular vein at the site of inoculation there was an irregular mass about 2·5 cm. in greatest diameter, composed of dense caseous substance surrounded by reddish fibroid tissue.

The Prescapular, Prepectoral, and Cervical Glands appeared normal.

Thorax.

Lungs.—The lungs weighed 4 lbs. 2 ozs.; they were extensively consolidated, more than three-quarters being red and hepatised; there were some groups of crepitant lobules on the dorsal and posterior parts of the caudal lobes and at the ventral margins of the cephalic; these showed under the pleura a number of irregular greyish-red foci; no definite tubercles were seen in the solid areas, but there was in several places a greyish-yellow moss-like mottling. On section of the lung fairly numerous transparent tubercles were seen in the crepitant lobules; the solid areas were closely beset with minute grey tubercles, very distinct in some lobules, but in the majority aggregated together into groups apparently around a bronchiole, producing in the red solid tissue a greyish moss-like or dendritic mottling.

Thoracic Glands.—The bronchial and mediastinal glands were much enlarged; on section their cortices were firm, grey, and infiltrated with a congested yellowish caseous network, or in places beset with caseous foci.

Heart.—There was no fat around the base of the heart; on the endocardium of the right ventricle there were a few minute grey tubercles and one miliary grey tubercle.

Pleura.—Normal.

Abdomen.

Omentum and Peritoneum.—Normal.

Spleen.—The spleen appeared normal on the surface and on section.

Liver.—The liver showed on the surface under the capsule three small greyish-yellow foci; on section a few sparsely scattered minute grey foci and two or three larger greyish tubercles were seen.

Portal Glands.—The portal glands were slightly enlarged; the cortices showed firm and grey lobular areas in a state of early caseation.

Kidneys.—Each kidney showed on the surface numerous small irregular grey tubercles, all less than 1 mm. in diameter; similar tubercles were seen in the depth of the cortex, but they were not so numerous or so distinct as on the surface.

Suprarenal Bodies.—In the cortex of the right suprarenal there was a minute grey tubercle; in that of the left there was a miliary slightly opaque tubercle.

Renal and Iliac Glands.—Normal.

Lumbar Glands.—One lumbar gland showed an early caseating patch.

Alimentary Tract.

Tongue, Pharynx, Tonsils.—Normal.

Submaxillary, Retro-pharyngeal, and Parotideal Glands.—Normal.

Intestines.—Normal.

Mesenteric Glands.—Normal.

Testicles.—Normal.

Various Lymphatic Glands.

Precrural, Popliteal, Gluteal, Ischiatic, Pudic.—Normal.

Microscopical Examination.

Smears from :—

Lung.—Tubercle bacilli very numerous.

Liver.—Two tubercle bacilli seen.

Spleen.—No tubercle bacilli.

Mesenteric Gland. — Tubercle bacilli in moderate numbers.

Precrurial Gland.—No tubercle bacilli.

Tubercle from Suprarenal Body.—Tubercle bacilli in moderate numbers.

CALF 1395. Virus H. 53. "D.H." (*a*).

Intravenous inoculation of culture derived from the original material through Guinea-pig 1482.

Dose—5·0 milligrammes.

Date of Inoculation—April 1, 1908. [Age about 14 weeks.]

Died—April 22, 1908. [21 days after inoculation.]

Clinical Notes.

The calf was first noticed to be ill at the beginning of the third week after inoculation ; it stood with head down, shoulders humped, and staring coat, and the respiration was accelerated. The respiratory difficulty increased, the calf rapidly became weak and thin, and was found dead on the morning of April 22.

Temperature.

On the 10th day the temperature rose to 40·0° C. ; it reached 40·8° C. on the 13th day. From the 15th to the 20th day the temperature slowly fell ; it was 39·8° C. on the day before death.

Weights.

	cwt.	qr.	lbs.
April 1, 1908	1	1	6
April 22, 1908	1	0	18

Total loss of weight.—16 lbs.

Average rate of loss per week.—5·3 lbs.

POST-MORTEM EXAMINATION.

The carcass was thin.

Local Lesion.—At the seat of inoculation there was a small elongated patch of fibrous tissue containing caseous points in the sheath of the left jugular vein.

Cervical and Prescapular Glands.—Normal.

Thorax.

Lungs.—The lungs were heavy and weighed 6 lbs. 8 ozs. They were extensively consolidated and dark red in colour : small sharply-defined polygonal areas of air-containing but often congested lung tissue were irregularly and sparsely distributed in the anterior lobes and the dorsal parts of the right caudal lobe, and the dorsal and much of the marginal portions of the left caudal lobe were still pink and crepitant.

Innumerable irregular greyish points and an occasional definite tubercle were visible in the consolidated portion of the lung through the pleura ; none could be made out with certainty in the air-containing portions.

On section the consolidated portions of the upper lobes showed innumerable irregular grey foci : the consolidated patches and areas in the caudal lobes had a moss-like appearance due to innumerable very minute greyish tubercles, aggregated into groups with ill-defined margins, and so closely packed as to leave only a reticulum of reddish lung tissue.

The air-containing portions were also closely packed with minute grey foci which gave the cut surface a granular appearance.

Thoracic Glands.—The thoracic glands were moderately enlarged (the long mediastinal measured 10 by 3·4 by 2·5 cm.), soft and dark red in colour. On section the cortices were composed of greyish-red or grey tissue, firmer than normal gland tissue, but without any sign of cascation ; the medullary parts were soft and deeply congested.

Heart.—No tubercles were seen in the heart.

Pleura.—The fringes on the borders of the ribs were congested and hypertrophied : numerous congested villous tufts were seen on the pleural surface of the diaphragm : the pleura was everywhere rough to the feel, but no tubercles were visible.

Abdomen.

Omentum and Peritoneum.—Normal.

Spleen.—The spleen was large and flabby. No tubercles were visible in it.

Liver.—The liver was very large, weighing 5 lbs. 2 ozs. : the substance was pale, soft, and friable. The convex surface was peppered with innumerable very minute irregular greyish foci ; none could be made out with certainty on the concave surface. On section the liver was packed as closely as possible with just visible grey points.

Portal Glands.—The portal glands were oedematous : no tubercles were seen in them.

Kidneys.—A small number of very minute greyish-white foci were just visible on the surface of the left kidney : about half-a-dozen were seen on that of the right ; no tubercles were visible on section.

Suprarenal Bodies.—Normal.

Renal, Lumbar, and Iliac Glands.—Normal.

Alimentary Tract.

Tongue, Pharynx, Palate, Tonsils.—Normal.

Retro-pharyngeal, Submaxillary and Parotideal Glands.—Normal.

Intestines and Mesenteric Glands.—Normal.

Testicles.—Normal.

Various Lymphatic Glands.

Axillary, Precrural, Popliteal, Gluteal, Ischiatic, Pudic.—Normal.

Microscopical Examination.

(Smears from)

Lung.—Tubercle bacilli numerous.

Liver.—A few tubercle bacilli seen.

Spleen.—A few tubercle bacilli seen.

Kidney.—Three tubercle bacilli seen.

Suprarenal Body.—A few tubercle bacilli seen.

Right Prescapular Gland.—A moderate number of tubercle bacilli seen.

Portal Gland.—Tubercle bacilli numerous; many small clumps.

Gluteal Gland.—Tubercle bacilli in moderate numbers, mostly in small clumps.

CALF 1199. Virus H. 53. "D.H." (*a*).

Subcutaneous inoculation of an emulsion made from the left prescapular gland of Calf 1135.

Dose—317,600,000 T.B. (Vol. 10 cc. E=31,760,000 T.B. per cc.)

Date of Inoculation—April 10, 1907. [Age about 15 weeks.]

Killed when in good health—August 6, 1907. [118 days after inoculation.]

Clinical Notes.

A tumour of moderate size (maximum, 10 by 4·5 cm. on May 16) developed at the seat of inoculation on the left side of the neck; it was at first firm and hard, but afterwards became soft and fluctuating. The left prescapular gland became moderately enlarged (maximum 7 cm.).

The calf remained in good health during the experiment.

Temperature.

On the 22nd day after inoculation the temperature rose, reached a maximum (40·0° C.) on the 31st day, then quickly fell to normal, and remained normal for nearly three months.

Tuberculin Test.

The calf was not tested subsequent to inoculation.

Weights.

		cwt.	qrs.	lbs.
April 10, 1907	... ...	1	0	9
August 6, 1907	... ...	2	0	20

Total gain of weight.—1 cwt. 11 lbs.

Average rate of gain per week.—7·2 lbs.

POST-MORTEM EXAMINATION.

Carcass in good condition.

Local Lesion.—At the seat of inoculation on the left side of the neck there was a somewhat lobulated fluctuating swelling measuring 9 by 5 by 4 cm.; on section it was a loculated cyst filled with thick caseo-pus and surrounded by fibrous tissue containing calcareous tubercles.

Left Prescapular Gland.—The left prescapular gland measured 6 by 3·5 by 2 cm., and showed at one extremity an irregular caseo-calcareous mass replacing from one third to half of the gland substance; in the cortex around the hilum of the gland there was a number of softened caseous nodules, none larger than a pea.

Right Prescapular Gland.—The right prescapular gland measured 4·5 by 2 by 1·2 cm., and was normal on section.

Prepectoral Glands.—On the left side one, 1·5 cm. in diameter, was calcareo-caseous throughout; another showed two minute caseous foci in the cortex.

The glands on the right side were normal.

Axillary and Cervical Glands.—Normal.

Thorax.

Pleura.—Normal.

Lungs.—The lungs were pinkish and crepitant throughout; one doubtful grey point was seen under the pleura. No tubercles were seen on section.

Thoracic Glands.—The bronchial and mediastinal glands were normal in size, and showed on section sparsely scattered calcareous tubercles, the largest about 1 mm. in diameter.

Heart, Larynx and Trachea.—Normal.

Abdomen.

Omentum and Peritoneum.—Normal.

Spleen.—The pulp contained sparsely scattered grey miliary tubercles, the majority of which had calcareous centres mostly very minute.

Liver.—In the substance under the capsule two minute grey points were seen; on section a minute grey focus was found in the depth.

Portal Glands.—In each portal gland there were a few small calcareous tubercles.

Kidneys.—Each showed near the surface about half-a-dozen translucent grey tubercles, the largest the size of a millet seed, some of which had minute opaque centres; on section two were seen in the depth of the cortex of the left and four in that of the right.

Suprarenal Bodies.—A minute grey tubercle was seen in the cortex of the left suprarenal. The right was normal.

Coeliac Glands.—One showed in the cortex a caseo-calcareous tubercle the size of a millet seed.

Iliac Glands.—One contained three calcareous foci.

Renal Gland.—Three small calcareous tubercles were seen in the cortex.

Lumbar Glands.—One contained fairly numerous small calcareous tubercles; another contained a minute calcareous focus.

Alimentary Tract.

Tongue, Pharynx, Palate, Tonsils.—Normal.

Submaxillary, Retro-pharyngeal, and Hyoid Glands.—Normal.

Parotideal Glands.—In the left there was a soft caseous millet-seed sized tubercle; the right parotideal gland was normal.

Intestines, Mesenteric and Ileo-Colic Glands.—Normal.

Mammary Gland.—Normal.

Supramammary Lymphatic Glands.—Normal.

Eyes.—Normal.

Various Lymphatic Glands.

Precrural and Popliteal.—Normal.

Gluteal and Ischiatic.—Normal.

Microscopical Examination.

Emulsion of Left Prescapular Gland.—Tubercle bacilli in moderate numbers.

Emulsion of Left Bronchial Gland.—One tubercle bacillus seen.

Tubercle from Left Parotideal Gland. — Three tubercle bacilli seen.

Animals Inoculated.

Calf 1257 was inoculated subcutaneously with 10·0 cc. of the emulsion made from the left prescapular gland.

Rabbit 1412 was subcutaneously inoculated with 4 cc. of the same emulsion. [Killed, 232 days; slight general tuberculosis.]

Rabbit 1413 was subcutaneously inoculated with the emulsion made from the left bronchial gland. [Died, 124 days, of cellulitis, and showed local tuberculosis and tuberculosis of lungs.]

CALF 1257. Virus H 53. "D.H." (*a*).

Subcutaneous inoculation of an emulsion made from the left prescapular gland of Calf 1199.

Dose—10·0 cc. of emulsion containing T.B. in moderate numbers.

Date of Inoculation—August 6, 1907. [Age about 16 weeks.]

Killed when in good health—November 8, 1907. [94 days after inoculation.]

Clinical Notes.

A small firm slightly raised tumour developed at the seat of inoculation on the left side of the neck, and the adjacent prescapular gland became moderately enlarged. The calf appeared in good health during the whole period of the experiment.

Temperature. (Chart to September 26.)

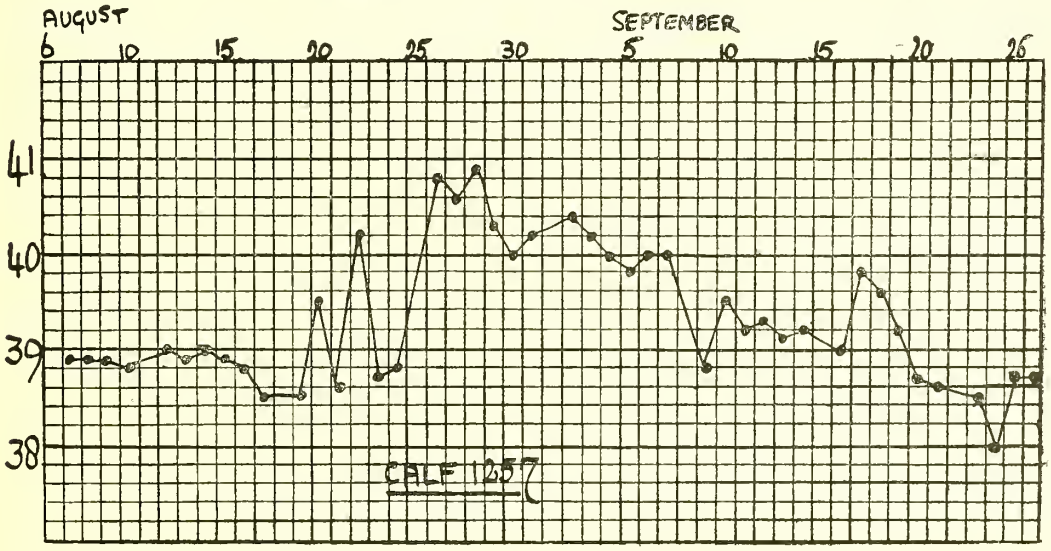

From September 26 onwards the temperature was normal.

Tuberculin Test.

October 24, 1907. [79 days after inoculation.] Reacted. Rise of temperature, 2·0° C.

Weights.

			cwt.	qrs.	lbs.
August 6, 1907	...	...	1	1	20
November 8, 1907	...	...	1	3	4

Total gain of weight.—1 qr. 12 lbs.

Average rate of gain per week.—3·0 lbs.

POST-MORTEM EXAMINATION.

Carcass in good condition.

Local Lesion.—At the seat of inoculation on the left side of the neck there was a well-defined somewhat irregular tumour measuring 7 by 5 by 3 cm.; on section it was composed of a thick fibrous margin or capsule and a firm caseous sequestrum separated from the capsule by creamy caseo-pus.

Left Prescapular Gland.—The left prescapular gland measured 7 by 5 by 3 cm.; on section it was composed practically throughout of dense caseous substance slightly gritty from calcification; the capsule was greatly thickened.

Right Prescapular Gland.—The right prescapular gland measured 5·5 by 2·8 by 1·4 cm., and was normal on section.

Prepectoral Glands.—On the left side one the size of a pea was indurated and beset with calcareous foci; another contained two pinhead-sized calcareous tubercles. The glands on the right side were normal.

Cervical Glands.—On the left side one in the middle of the neck the size of a small bean was composed of brownish fibroid tissue beset with calcareous foci and had a thickened capsule. An upper cervical gland contained two or three calcareous tubercles, while the corresponding gland on the right side contained one. The rest were normal.

Axillary Glands.—Normal.

Thorax.

Pleura.—Normal.

Lungs.—The lungs were normal in general appearance. In the left lung under the pleura ten tubercles were seen : there was a small number on the surface of the right ; the tubercles had calcareous centres and fibrous margins. On section similar tubercles were very sparsely scattered throughout the parenchyma.

Thoracic Glands. — The dorsal mediastinal and bronchial glands were not enlarged ; they showed on section small irregular calcareous nodules and discrete calcareous tubercles.

Heart and Pericardium.—Normal.

Larynx and Trachea.—Normal.

Abdomen.

Omentum and Peritoneum.—Normal.

Spleen.—The pulp contained eight caseo-calcareous nodules with grey fibrous margins, the largest 2·5 mm. in diameter.

Liver.—Scattered throughout the substance of the liver there were nodules similar to those in the spleen.

Portal Glands.—The portal glands were normal in size and contained scattered discrete irregular calcareo-caseous nodules 2 to 3 mm. in diameter.

Kidneys and Suprarenal Bodies.—Normal.

Renal Glands.—A renal gland contained several nodules similar to those in the portal glands.

Coeliac Glands.—One of the coeliac glands contained a calcareous nodule the size of a barley grain.

Lumbar and Iliac Glands.—Normal.

Alimentary Tract.

Tongue, Pharynx, Tonsils, Intestines, Mesenteric and Ileo-Colic Glands.—Normal.

Testicles.—Normal.

Various Lymphatic Glands.

The Left Precrural Gland showed in the cortex a group of five soft caseous nodules gritty from calcification, the largest 2 mm. in diameter.

There was a similar nodule in the *left popliteal gland*, and three or four in one of the *pudic glands.*

The Left Parotideal Gland showed a minute calcareous tubercle; the right a softened gritty caseous nodule the size of a hemp seed.

The Right Submaxillary Gland showed one small calcareo-caseous nodule, the left was normal.

The Left Retro-pharyngeal Gland contained one yellow caseo-calcareous nodule, the right several.

The Gluteal and Ischiatic Glands were normal.

Microscopical Examination.

Emulsion of Left Prescapular Gland.—Tubercle bacilli moderately numerous.

Emulsion of Left Bronchial Gland.—No tubercle bacilli seen.

Animals Inoculated.

The whole of the tuberculous tissue from the prescapular gland was emulsified in normal saline ; after filtration through muslin the emulsion amounted to about 32 cc. ; 20 cc. of this were inoculated into a calf [No. 1295] subcutaneously ; and 5 cc. subcutaneously into each of two rabbits [1557–1558]. One rabbit died in 117 days of general tuberculosis (probably mainly spontaneous), the other was killed after 117 days and showed slight general tuberculosis.

The whole of the left bronchial gland was emulsified and inoculated intraperitoneally into two guinea-pigs [2701–2702].

One of the nodules from the spleen was emulsified and inoculated intraperitoneally into a guinea-pig [2703].

All three guinea-pigs were killed 28 days later and showed early general tuberculosis.

CALF 1295. Virus H. 53. "D.H." (*a*).

Subcutaneous inoculation of an emulsion made from the prescapular gland of Calf 1257.

Dose—20·0 cc., containing moderately numerous tubercle bacilli.

Date of Inoculation—November 8, 1907. [Age about 5 months.]

Killed when in good health—February 17, 1908. [101 days after inoculation.]

Clinical Notes.

Four weeks after inoculation there was a firm flat local tumour irregular in outline, measuring about 11 by 7 cm. in greatest superficial area. The adjacent prescapular gland was enlarged and hard, measuring 9 cm. in length. Subsequently both the tumour and the gland diminished in size.

The calf remained well during the experiment.

Temperature.

There was a very slight rise of temperature, commencing 19 days after inoculation and lasting 10 days (maximum 39·9° C.) ; subsequently the temperature was normal.

Tuberculin Test.

The calf was not tested subsequent to inoculation.

Weights.

	cwt.	qrs.	lbs.
November 8, 1907	1	3	19
February 17, 1908	2	3	16

Total gain of weight.—3 qrs. 25 lbs.

Average rate of gain per week.—7·5 lbs.

POST-MORTEM EXAMINATION.

The carcass was in good condition.

Local Lesion.—In the subcutaneous tissues on the left side of the neck there was a flat tumour measuring 5 by 4 by 0·5 cm. composed of white fibrous tissue, closely beset with small calcareous nodules with brownish translucent fibrous margins.

Left Prescapular Gland.—The left prescapular gland was slightly enlarged, measuring 6 by 3 by 2 cm. It showed on section four softened caseous slightly gritty nodules, the smallest 1 cm., the largest 2 cm. in greatest diameter ; the nodules were intersected by trabeculæ of fibrous tissue. There were besides in the cortex a few small calcareous nodules.

Right Prescapular Gland.—The right prescapular gland measured 4 by 2·5 by 1 cm., and was normal on section.

Prepectoral Glands, Axillary and Cervical Glands.—Normal.

Thorax.

Pleura, Lungs, Heart—Normal.

Thoracic Glands.—The bronchial and mediastinal

glands were not enlarged; each, however, showed a number of irregular yellow calcareous foci distributed regularly throughout the cortex; they were more numerous than in the portal glands.

Abdomen.

Omentum and Peritoneum, Spleen, Liver, Kidneys, and Suprarenal Bodies, and Intestines.—Normal.

Portal Glands.—Each gland showed several irregular calcareous foci in the cortex.

Coeliac Glands.—One gland of the group contained a few minute calcareous foci.

Lumbar Glands.—Two contained each three or four minute calcareous foci.

Renal Gland.—In this gland there were four calcareous foci.

Mesenteric Glands.—Several of the mesenteric glands in different parts of the mesentery showed in the cortex a few small irregular calcareous tubercles.

Ileo-Colic Glands.—The majority contained tubercles similar to those in the mesenteric glands.

Tongue, Pharynx, Palate, Tonsils.—Normal.

Peripheral Lymphatic Glands.—All were examined and found to be normal.

Microscopical Examination.

Emulsion of Prescapular Gland.—Tubercle bacilli numerous.

Emulsion of Portal Glands.—A few tubercle bacilli seen.

Guinea-pigs Inoculated.

One guinea-pig, No. 2961, was inoculated intraperitoneally with an emulsion made from the left prescapular gland; two, Nos. 2962 and 2963, intraperitoneally with an emulsion made from the portal glands. All died of general tuberculosis in 37, 189, and 66 days respectively.

CALF 1333. Virus H. 53. "D.H." (*a*).

Subcutaneous inoculation of emulsion of various tissues (omentum, spleen, and a few of the lymphatic glands) of each of three guinea-pigs, 2836–2837–2838, the second series from Calf 1257.

Dose—10·0 cc. of the emulsion, in which T.B. were extremely numerous.

Date of Inoculation—January 11, 1908. [Age about 13 weeks.]

Killed when in good health—May 25, 1908. [135 days after inoculation.]

Clinical Notes.

A large firm prominent tumour developed at the seat of inoculation, which afterwards became fluctuating and pendulous. The adjacent prescapular gland became moderately enlarged.

The calf remained well during the experiment, but the rate of growth was slower than is usual with healthy calves.

Temperature.

On the 13th day after inoculation the temperature rose to 39·7° C., and a maximum of 40·6° C. was reached on the 16th day; it then slowly fell, being normal on the 25th day. Subsequently the temperature was approximately normal, though somewhat irregular.

Tuberculin Tests.

March 4, 1908. [53 days after inoculation.]
Dose, 1·0 cc. Reacted. Rise of temperature, 1·0° C.

May 20, 1908. [130 days after inoculation.]
Dose, 2·0 cc. Reacted. Rise of temperature, 2·0° C.

Weights.

	cwt.	qrs.	lbs.
January 11, 1908	1	0	18
May 25, 1908	1	2	17

Total gain of weight.—1 qr. 27 lbs.

Average rate of gain per week.—2·9 lbs.

POST-MORTEM EXAMINATION.

The carcass was in good condition.

Local Lesion.—At the seat of inoculation on the left side of the neck there was a prominent somewhat pendulous fluctuating tumour measuring 13 by 8 by 7 cm.; on section it was a cyst filled with light-brownish-yellow caseo-pus containing some solid caseous masses; the walls were moderately thick, fibrous, and lined internally with gritty granulation tissue; the cavity was crossed by fibrous trabeculæ.

Left Prescapular Gland.—The left prescapular measured 5·8 by 3 by 2·4 cm. and showed about half the substance composed of softened caseous and calcareous masses which had fused together.

Right Prescapular Gland.—The right prescapular gland measured 5·6 by 2·5 by 1·3 cm. and was slightly oedematous (recent tuberculin test).

Prepectoral Glands.—One of the prepectoral glands on the left side contained a pea-sized calcareous nodule; the rest were normal.

Cervical Glands.—One in the middle of the neck on the left side was caseous and calcareous practically throughout; the caseous parts were softened. The rest were normal.

Thorax.

Pleura.—The parietal and visceral pleuræ were slightly roughened and there was slight hypertrophy of the fringes around the margins of the lungs.

Lungs.—No tubercles were seen on the surface or on section of the lungs.

Thoracic Glands.—Normal.

Heart.—Normal.

Abdomen.

Omentum and Peritoneum.—The ventral surface of the omentum and the peritoneal surface of the diaphragm showed numerous villous tags of connective tissue, in some of which hæmorrhage had taken place; there were no tuberculous nodules.

Spleen.—On the convex surface there was a number of villous processes similar to those on the diaphragm; on section the pulp was normal.

Liver and Portal Glands.—Normal.

Kidneys and Suprarenal Bodies.—Normal.

Renal, Lumbar, and Iliac Glands.—Normal.

Alimentary Tract.

Tongue, Pharynx, Tonsils.—Normal

Submaxillary, Parotideal, and Retro-pharyngeal Glands.—Normal.

Small Intestine.—A Peyer's patch in the ileum contained a slightly raised grey nodule in the centre of which were two calcareous foci.

Large Intestine.—Normal.

Mesenteric Glands.—Normal.

Ileo-Colic Glands.—One contained a soft caseous focus and a calcareous focus; the rest were normal.

Mammary Gland.—Normal.

Various Lymphatic Glands.

Axillary, Precrural, Popliteal, Gluteal, Ischiatic, Pudic.—Normal.

Microscopical Examination.

Emulsion of Left Prescapular Gland.—Tubercle bacilli numerous.

Foci from Small Intestine.—No tubercle bacilli seen.

CALF 1341. Virus H. 53. "D.H." (*a*).

Subcutaneous inoculation of an emulsion of various tissues (the omentum, the spleen, and a few of the lymphatic glands) of each of three guinea-pigs, Nos. 2836–2837–2838, the second series from Calf 1257.

Dose—10·0 cc. of the emulsion, in which T.B. were extremely numerous.

Date of Inoculation—January 11, 1908. [Age about 13 weeks.]

Killed when in good health—May 28, 1908. [138 days after inoculation.]

Clinical Notes.

A large firm tumour developed at the seat of inoculation which afterwards became soft and fluctuating; the adjacent prescapular gland became considerably enlarged, but diminished in size during the later period of the experiment.

The general health of the calf was good during the experiment, but the rate of growth was somewhat slower than is usual with healthy calves.

Temperature.

On the 13th day after inoculation the temperature rose to 39·8° C., and it remained slightly raised for nearly seven weeks. The maximum temperature recorded during this period was 40·1 C.; the average temperature was but little above 39·0° C.

The temperature was normal during the remaining period of the experiment.

Tuberculin Test.

March 4, 1908. [53 days after inoculation.]

Dose 1·0 cc. Reacted. Rise of temperature, 1·3° C.

Weights.

	cwt.	qrs.	lbs.
January 11, 1908	1	0	16
May 28, 1908	1	2	15

Total gain of weight.—1 qr. 27 lbs.

Average rate of gain per week.—2·8 lbs.

POST-MORTEM EXAMINATION.

The carcass was in good condition.

Local Lesion.—At the seat of inoculation there was a prominent fluctuating tumour measuring 14 by 10 by 5·5 cm.; on section it was a cyst filled with light-brownish-yellow caseo-pus containing some firm caseous masses; the capsule was thick and fibrous and lined internally with gritty granulation tissue.

Left Prescapular Gland.—The left prescapular gland measured 6·5 by 4 by 3·4 cm. and was caseous practically throughout; the caseous substance in places had broken down to form caseo-pus and was gritty from calcification.

Right Prescapular Gland.—The right prescapular gland measured 4·5 by 2 by 1 cm. and showed in the cortex one millet-seed-sized yellow gritty tubercle.

Prepectoral Glands.—One on the left side, spherical and about 1 cm. in diameter, was caseous throughout slightly gritty and breaking down around the margins. Another gland contained two small caseo-calcareous patches; a third was normal.

One gland on the right side contained a yellow calcareous tubercle.

Cervical Glands.—On the left side in the middle of the neck there was an enlarged hard gland measuring 2 by 1 cm. which on section was dense and caseous throughout; the caseous substance was gritty around the margins and could be readily separated from a thickened capsule; a slightly enlarged gland near the latter and two lower cervical glands were partly calcareo-caseous; two others contained one or two calcareous tubercles. On the right side one gland contained a caseo-calcareous tubercle; the rest were normal.

Axillary Glands.—The right was normal; the left contained three miliary calcareous tubercles.

Thorax.

Pleura.—Normal.

Lungs.—The lungs were crepitant and showed under the pleura sparsely scattered shotty nodules ranging in size up to 5 mm; the larger ones, of which there were only two or three, were caseous and gritty and had fibrous walls; the rest were quite calcareous and had fibrous margins; on section they appeared to be less numerous even than on the surface.

Thoracic Glands.—The mediastinal and bronchial glands were moderately enlarged and felt very hard; on section they were calcareous practically throughout; the calcareous patches were composed of large calcareous granules set in fibroid tissue and there was little or no caseous tissue.

Heart.—Normal.

Abdomen.

Omentum and Peritoneum.—Normal.

Spleen.—The spleen was normal on the surface and showed in the pulp moderately numerous caseo-calcareous nodules with fibrous margins, the largest 3 or slightly more millimetres in diameter.

Liver.—The substance of the liver contained moderately numerous caseo-calcareous nodules ranging in size from a millet to that of a hemp seed, similar to those in the spleen; and also fairly numerous grey tubercles with calcareous centres, the largest about 1 mm. in diameter; some of the nodules projected from the surface and had slightly overhanging margins; they closely resembled nodules produced by a bovine tubercle bacillus.

Portal Glands.—The portal glands were enlarged and closely beset with irregular yellow calcareous tubercles, in one gland forming large patches.

Kidneys.—On the surface of the right kidney there were six grey tubercles with calcareous centres, the largest 1 mm. in diameter; six similar tubercles were seen in the depth of the cortex.

In the cortex of the left kidney there were similar tubercles, five on the surface and three in the depth.

Suprarenal Bodies.—In the medulla of the left suprarenal body there were three calcareo-caseous nodules, the largest 3 mm. in diameter; in the right there were two similar nodules.

Coeliac Glands.—One was slightly enlarged and its substance extensively replaced by yellow calcareous patches formed by aggregated tubercles; other coeliac glands contained a few discrete calcareous tubercles.

Alimentary Tract.

Tongue, Pharynx, Tonsils.—Normal.

Small Intestine.—Most of the Peyer's patches in the small intestine contained a few caseo-calcareous tubercles.

Large Intestine.—Normal.

Mesenteric Glands.—Each contained a few calcareous nodules, varying in size up to a pea, with fibrous capsules.

Thymus.—In the substance of the thymus there were several softened caseous and gritty nodules.

Various Lymphatic Glands.

The precrural, popliteal, gluteal, pudic, iliac, one parotideal, the submaxillary and retro-pharyngeal glands showed in the cortex scattered discrete nodules varying in size from a pin's head to that of a hemp seed: the majority were small and calcareo-caseous, the larger ones were caseous and softened. Some of the glands contained one or two only, few more than half a dozen. The other parotideal and the ischiatic glands were normal.

The lumbar and renal glands were closely beset with calcareous tubercles.

Microscopical Examinations.

Tubercle from Thymus.—A few tubercle bacilli seen

Tubercle from Spleen.—One tubercle bacillus seen.

Tubercle from Mediastinal Gland.—No tubercle bacilli seen.

Tubercle from Suprarenal Body.—A few tubercle bacilli seen.

Animals Inoculated.

Guinea-pigs 3088 and 3089 were inoculated intraperitoneally with an emulsion made from the spleen. They died of general tuberculosis in 155 and 154 days respectively.

CALF 1473. Virus H. 53. "D.H." (*a*).

Subcutaneous inoculation of culture derived from the suprarenal body of Calf 1341.

Dose—47·0 milligrammes.

Date of Inoculation—September 3, 1908. [Age about 5 months.]

Killed when in good health—December 4, 1908. [92 days after inoculation.]

Clinical Notes.

A prominent tumour of moderate size developed at the seat of inoculation on the left side of the neck, and the left prescapular gland became moderately enlarged.

The calf showed no signs of ill health during the experiment, but it did not grow, and even lost 6 lb. in weight.

Temperature.

There was a period of pyrexia lasting from the eleventh to the twenty-eighth day after inoculation (maximum 40·6° C.).

Subsequently the temperature was normal.

Tuberculin Test.

November 4, 1908. [62 days after inoculation.] Dose, 2·0 cc. Reacted. Rise of temperature, 2·3° C.

Weights.

			cwt.	qrs.	lbs.
September 3, 1908	...	...	1	3	3
December 4, 1908	...	...	1	2	25

Loss of weight—6 lbs.

POST-MORTEM EXAMINATION.

The carcass was in fairly good condition.

Local Lesion.—At the seat of inoculation on the left side of the neck there was a firm prominent tumour measuring 12 by 7·5 by 5 cm.; on section it was composed of a mass of firm caseous substance, which was completely separated by thin caseo-pus from a thick fibrous wall lined internally with gritty granulation tissue.

Left Prescapular Gland.—The left prescapular gland measured 6·5 by 4·5 by 3 cm., and showed more than three-quarters of its substance composed of dense pinkish caseous substance, the rest being fibro-calcareous.

The Right Prescapular Gland measured 4 by 2 by 1 cm., and was normal on section.

Prepectoral Glands.—On the left side, one (1 cm. in diameter) was partly dense and caseous, partly calcareous; another contained a calcareous focus.

The glands on the right side were normal.

Cervical and Axillary Glands.—Normal.

Thorax.

Pleura.—Normal.

Lungs.—The lungs were crepitant throughout; they showed under the pleura sparsely scattered grey miliary tubercles with calcareous centres; there were also three caseous and softened nodules with fibrous capsules, the largest the size of a hempseed. Scattered tubercles with minute calcareous centres were seen on section.

Thoracic Glands.—The bronchial and dorsal mediastinal glands were not enlarged; the bronchial glands

showed moderately numerous minute calcareous foci in the cortex; in the mediastinal glands there were similar tubercles sparsely scattered, the long mediastinal gland containing also a calcareous patch composed of calcareous tubercles.

Heart.—Normal.

Abdomen.

Omentum and Peritoneum.—Normal.

Spleen.—The spleen was normal in size; it showed in the pulp a moderate number of caseo-calcareous nodules with grey fibrous margins, the largest 2 mm. in diameter.

Liver.—The capsule on the anterior surface showed several filmy grey foci; in the substance just beneath the capsule a few translucent grey tubercles and two or three calcareous foci were seen; on section, a few translucent grey tubercles were found in the depth of the liver.

Portal Glands. — The portal glands were not enlarged; they showed in the cortex a moderate number of discrete irregular calcareous tubercles.

Kidneys.—There were no tubercles in either kidney.

Suprarenal Bodies.—Normal.

Coeliac Glands.—One coeliac gland showed a few calcareous tubercles.

Renal Glands.—One renal gland contained one calcareous tubercle, another four ranging in size from a point to a millet-seed.

Lumbar Glands.—One contained a minute calcareous tubercle.

Iliac Glands.—Normal.

Alimentary Tract.

Tongue, Pharynx.—Normal.

Tonsils.—One tonsil contained a small collection of yellow pus; the other was normal.

Retro-pharyngeal Glands.—There were two calcareous foci in the left pharyngeal gland. The right was normal.

Under the mucous membrane of the vault of the pharynx, in the mid line, there was a small gland which contained a caseo-calcareous nodule.

Submaxillary and Parotideal Glands.—Normal.

Intestines.—Normal.

Mesenteric Glands.—The mesenteric glands contained scattered calcareous tubercles and calcareous patches composed of groups of calcareous grains.

The Ileo-colic Glands were similarly affected.

Various Lymphatic Glands.

Popliteal Glands.—In the cortex of each there was a projecting nodule, brownish and translucent, containing a calcareous grain.

Precrural Glands.—In the cortex of each there was a fibrous nodule, 2 mm. in diameter, with softened caseous foci in the centre; in the left gland projecting from the surface under the capsule there were two rather smaller brownish translucent nodules, one of which contained a calcareous grain.

Gluteal Glands. — The right gluteal contained a fibrous tubercle with a calcareous centre; the left was normal.

Ischiatic and Pudic Glands.—Normal.

Testicles.—Normal.

Microscopical Examination.

Caseous nodule from lung.—No tubercle bacilli seen.

CALF 1477. Virus H. 53. "D.H." (*a*).

Subcutaneous inoculation of culture derived from the suprarenal body of Calf 1341

Dose—50·0 milligrammes.

Date of Inoculation—September 3, 1908. [Age about 5 months.]

Killed when in good health—December 8, 1908. [96 days after inoculation.]

Clinical Notes.

A firm raised swelling of moderate size developed at the seat of inoculation on the left side of the neck and the left prescapular gland became moderately enlarged. Apart from constitutional disturbance accompanying the rise of temperature, the calf was well during the experiment; its weight, however, remained stationary.

Temperature.

On the eleventh day after inoculation the temperature rose to 39·9° C. and reached a maximum (40·5° C.) on the fifteenth day; it then slowly declined to the normal, and was normal during the remaining period of the experiment.

Tuberculin Test.

November 4, 1908. [62 days after inoculation.] Dose, 2·0 cc. Reacted. Rise of temperature, 2·3° C.

Weights.

	cwt.	qrs.	lbs.
September 3, 1908	1	3	11
December 8, 1908	1	3	18

Total gain of weight.—7 lbs.

POST-MORTEM EXAMINATION.

The carcass was in good condition.

Local Lesion.—At the seat of inoculation on the left side of the neck there was a firm tumour measuring 8 by 7 by 4 cm., the skin over the centre of which was thinned and breaking down; on section it was composed of a loose mass of dense caseo-necrotic substance and a thick fibrous capsule.

Left Prescapular Gland.—The left prescapular gland measured 7 by 4·3 by 3 cm. and was composed throughout of dense pinkish caseous substance, gritty around the margins; the capsule was thickened.

Right Prescapular Gland.—The right prescapular gland measured 4 by 1·7 by 1 cm. and was normal on section.

Prepectoral Glands.—On the left side one the size of a walnut and another that of a large pea, were dense and caseous throughout, the capsules in each case being much thickened; another gland was normal. The glands on the right side were normal.

Cervical Glands.—One on the left side in the lower part of the neck contained a calcareo-caseous mass about 1 cm. in diameter; the rest were normal.

Axillary Glands.—The left contained a caseous tubercle, 2 mm. in diameter; the right was normal.

Thorax.

Pleura.—Normal.

Lungs.—The lungs were crepitant throughout; they showed under the pleura sparsely scattered tubercles varying from 0·5 to 1·5 mm in diameter;

one or two of the larger ones were caseous and slightly gritty, the others were calcareous. Similar tubercles were seen on section; they were not evenly distributed; in some regions it was difficult to find them, in others a number was seen recurring quite close together.

Thoracic Glands.—The bronchial and dorsal mediastinal glands were perhaps slightly enlarged: on section they showed calcareous patches formed by aggregated tubercles.

Heart.—Normal.

Abdomen.

Omentum and Peritoneum.—Normal.

Spleen.—The spleen was normal in size and contained about a dozen yellow caseous nodules, 1 to 2·5 mm. in diameter.

Liver.—The liver appeared normal.

Portal Glands.—The portal glands were slightly enlarged and closely beset with caseo-calcareous tubercles, aggregated together in one gland to form nodules.

Coeliac Glands.—Two contained numerous caseous gritty nodules, the largest 2 mm. in diameter; two others contained each one or two.

Kidneys.—In the cortex of each kidney there were numerous pale wedge-shaped areas; no tubercles were seen.

Suprarenal Bodies.—In the cortex of the right suprarenal there were two firm caseous gritty nodules, the largest the size of a hempseed. The left was normal.

Renal Glands.—Two contained each one yellow caseo-calcareous tubercle and scattered minute greyish-white points.

Lumbar Glands.—Two contained each one or two minute calcareous tubercles.

Iliac Glands.—One contained a caseous tubercle.

Alimentary Tract.

Tongue, Pharynx, Palate, Tonsils.—Normal.

Retro-pharyngeal Glands.—The left contained two softened caseous nodules up to a hempseed in size.

Parotideal Glands.—The right parotideal gland showed one softened caseous nodule, 2 mm. in diameter, slightly gritty from calcification; the left, a minute calcareous focus.

Submaxillary Glands.—Normal.

Intestines.—In the small intestine all the Peyer's patches except the long one contained yellow foci, some in rather large numbers. The large intestine was normal.

Mesenteric Glands.—All the mesenteric glands were affected containing scattered calcareous foci, and nodules ranging up to 5 mm. in diameter composed of loosely aggregated calcareous foci.

The Ileo-colic and the Gastric Glands resembled the mesenteric.

Larynx and Trachea.—Normal.

Testicles.—Normal.

Various Lymphatic Glands.

Procrural Glands.—One was normal, the other contained two caseous tubercles.

Popliteal Glands.—Each contained several caseous tubercles.

Pudic Glands.—In one there was a calcareo caseous tubercle.

Gluteal Glands.—Each contained a calcareous tubercle.

Ischiatic Glands.—Normal.

Microscopical Examination.

Emulsion of the Long Mediastinal Gland.—A few tubercle bacilli seen.

Focus from a Peyer's Patch in the Small Intestine.—Two tubercle bacilli seen.

CALF 1363. Virus H. 53. "D.H." (*a*).

Subcutaneous inoculation of culture derived from Guinea-pig 2703, inoculated with an emulsion of the spleen of Calf 1257 [3rd passage].

Dose—50·0 milligrammes.

Date of Inoculation—January 25, 1908. [Age about 12 weeks.]

Killed when well—April 30, 1908. [96 days after inoculation.]

Clinical Notes.

The calf remained well during the experiment.

Temperature.

The temperature was slightly raised during the first three weeks after the inoculation; subsequently it was quite normal.

Tuberculin Test.

March 4, 1908. [39 days after inoculation.] Dose 4·0 cc. of Leishmann's tuberculin. Result: no rise of temperature.

Weights.

	cwt.	qrs.	lbs.
January 25, 1908	1	0	12
April 30, 1908	1	2	18

Total gain of weight.—2 qrs. 6 lbs.

Average rate of gain per week.—4·5 lbs.

POST-MORTEM EXAMINATION.

The carcass was in good condition.

Local Lesion.—On the left side of the neck, at the site of inoculation, there was a fluctuating swelling measuring 9 by 6 by 4 cm. On section it was a cyst filled with solid caseous masses and creamy caseo-pus; the wall was of fibrous tissue, not very thick, lined internally with granulation tissue; the cavity was crossed by fibrous trabeculæ.

Left Prescapular Gland.—The left prescapular gland was the size and shape of a hen's egg (6 by 4 by 4 cm.). On section the gland had a thick fibrous capsule and contained a dense pinkish caseous mass or sequestrum separated from the capsule by creamy caseo-pus.

Right Prescapular Gland.—The right prescapular gland measured 3·5 by 1·8 by 1 cm. and contained a caseous and softened nodule about 2 mm. in diameter.

Prepectoral Glands.—Normal.

Axillary Glands.—Normal.

Cervical Glands.—One of the lower cervical glands on the left side contained a millet seed sized caseous tubercle. On the right side two glands each contained one caseo-calcareous tubercle.

Thorax.

Pleura.—Normal.

Lungs.—The lungs were crepitant and collapsed normally. Under the pleura of the left lung eight tubercles were seen; they varied from about 0·5 mm. up to 2 mm. in diameter; the larger ones were caseous and very slightly gritty; the smallest ones were grey and translucent.

From the surface of the right lung seven similar tubercles were seen. No tubercles were seen on section.

Thoracic Glands.—The bronchial and mediastinal glands were normal in size; they showed in the cortex scattered quite discrete caseo-calcareous tubercles, the the largest 1 mm. in diameter.

Heart.—Normal.

Abdomen.

Omentum and Peritoneum.—Normal.

Spleen.—In the pulp there were scattered caseous slightly gritty nodules varying in size up to 3 mm.; they were somewhat irregular in outline, especially the larger ones. Thirty were counted on one flat surface after longitudinal section.

Liver.—Normal on the surface and on section.

Portal Glands.—The portal glands were not enlarged; they showed in the cortex rather numerous calcareo-caseous tubercles ranging in size from a mere point up to that of a pin's head.

Kidneys.—Normal.

Suprarenal Bodies.—In the cortex of the right there was a yellow caseo-calcareous nodule 2 mm. in diameter. The left was normal.

Coeliac Glands.—One half of one gland was beset with yellow miliary caseous tubercles, slightly gritty from calcification.

Lumbar Glands.—Two lumbar glands contained each a few pinhead-sized caseo-calcareous tubercles.

Iliac Glands.—Normal.

Renal Glands.—A renal gland contained a number of yellow gritty foci.

Alimentary Tract.

Tongue, Pharynx, Tonsils.—Normal.

Submaxillary Glands.—The left contained a small pea-sized softened caseous nodule, and there was a small caseous tubercle in the right.

Parotideal Glands.—In the left there were three caseous and softened nodules, the largest the size of a hemp seed; the right contained one caseous tubercle.

Retro-pharyngeal Glands.—In the cortex of each there were fairly numerous yellow caseous and softened nodules varying from 1 mm. up to 3 mm. in diameter.

Intestines.—Normal.

Mesenteric Glands.—Each of the mesenteric glands contained a few irregular caseo-calcareous nodules up to 2·5 mm. in diameter.

Ileo-Colic Glands.—The ileo-colic glands contained similar nodules.

Testes.—Normal.

Various Lymphatic Glands.

Precrural.—The precrural glands contained each two softened caseous nodules a little larger than millet seeds.

Gluteal.—The right contained a caseous nodule 2 mm. in diameter. The left was normal.

Pudic, Ischiatic, and Popliteal.—Normal.

CALF 1381. Virus H. 53. "D.H." (*a*).

Subcutaneous inoculation of culture derived from the portal gland of Calf 1295.

Dose—45·0 milligrammes.

Date of Inoculation—April 9, 1908.

Killed when in good health—September 8, 1908. [152 days after inoculation.]

Clinical Notes.

The calf remained well during the experiment.

Temperature.

For a period of three weeks after the inoculation the temperature was slightly irregular (maximum 39·7° C.). Subsequently it was quite normal.

Tuberculin Test.

August 18, 1908. [131 days after inoculation]. Dose, 2·0 cc. Reacted. Rise of temperature, 1·8° C.

Weights.

	cwt.	qrs.	lbs.
April 9, 1908	0	3	24
September 8, 1908	1	3	0

Total gain of weight.—3 qrs. 4 lbs.

Average rate of gain per week.—4 lbs.

POST-MORTEM EXAMINATION.

The carcass was in good condition.

Local Lesion.—On the left side of the neck there was a firm tumour measuring 7 by 4 cm. in area; it consisted mainly of thickened skin, which in places was more than 1 cm. in thickness; the central part of the skin was thinner and scarred; beneath this scar tissue there was a patch of brownish translucent fibroid tissue containing calcareous grains.

Left Prescapular Gland. — The left prescapular gland measured 4·5 by 2·5 by 2 cm., and showed about half its substance caseous, the caseous material being slightly gritty.

Right Prescapular Gland. — The right prescapular gland measured 4·5 by 2·2 by 2 cm., and was normal on section.

Prepectoral, Cervical, and Axillary Glands.—Normal.

Thorax.

Pleura, Lungs, Heart.—Normal

Thoracic Glands.—The dorsal mediastinal and bronchial glands showed in the cortex very sparsely scattered minute calcareous grains.

Abdomen.

Omentum and Peritoneum, Spleen and Liver.—Normal.

Portal Glands.—Two or three minute calcareous foci were seen.

Kidneys.—On the surface of one kidney there was a doubtful grey focus. The other was normal.

Suprarenal Bodies.—Normal.

Renal, Lumbar, and Iliac Glands.—Normal.

Alimentary Tract.

Tongue, Pharynx, Palate, Tonsils.—Normal.

Submaxillary, Retro-pharyngeal, and Parotideal Glands.—Normal.

Intestines.—Normal.

Mesenteric Glands.—Each of the mesenteric glands contained sparsely scattered irregular calcareous tubercles in the cortex.

Ileo-Colic Glands.—The ileo-colic glands contained similar tubercles.

Testicles.—Normal.

Various Lymphatic Glands.

Precrural, Popliteal, Gluteal, Ischiatic, Pudic.—Normal.

Calf 1231. Virus H. 53. "D.H." (*a*).

Subcutaneous inoculation of an emulsion of the prescapular gland from Calf 1155.

Dose—10·0 cc. of emulsion, containing numerous tubercle bacilli.

Date of Inoculation—June 6, 1907. [Age about 16 weeks.]

Killed when in good health—September 26, 1907. [112 days after inoculation.]

Clinical Notes.

A small firm tumour developed at the seat of inoculation on the left side of the neck, and the adjacent prescapular gland became moderately enlarged. The tumour did not ulcerate.

The calf remained well during the experiment.

Temperature.

The temperature rose to 40·1° C. on the 15th day; during the following 16 days it fluctuated between 39·2° C. and 40·1° C.; the temperature then fell to normal (38·8° C.), and remained approximately normal until the close of the experiment.

Tuberculin Test.

The calf was not tested subsequent to inoculation.

Weights.

	cwt.	qrs.	lbs.
June 6, 1907	1	1	15
September 26, 1907	2	0	10

Total gain of weight.—2 qrs. 23 lbs.

Average rate of gain per week.—5 lbs.

POST-MORTEM EXAMINATION.

The carcass was in good condition.

Local Lesion.—At the seat of inoculation on the left side of the neck there was a slightly raised tumour, pear-shaped in outline, measuring 10 by 6 by 2·5 cm.; on section the narrow lower extremity of the tumour was fibro-calcareo-caseous, the rest of the tumour was a cyst with thick fibrous walls and caseo-purulent contents, the cavity being crossed by numerous fibrous trabeculæ; the skin over the cyst was thickened but not ulcerated.

Left Prescapular Gland.—The left prescapular gland measured 6·5 by 4· by 2·5 cm.; just under the capsule in several places numerous discrete yellow tubercles could be seen; on section about three-quarters of the gland was occupied by a caseous softened mass with a thick capsule surrounding it; the rest of the gland contained fairly numerous discrete caseo-calcareous tubercles and a few larger nodules.

Right Prescapular Gland.—Measured 5 by 2·5 by 1 cm., and was normal on section.

Prepectoral Glands.—On the left side one, 2·5 cm in diameter, was composed throughout of dense caseated tissue breaking down around the periphery and almost completely separated from the thickened capsule.

Other prepectoral glands were normal.

Axillary Glands.—Normal.

Thorax.

Pleura.—Normal.

Lungs.—There was a fibrous adhesion of the right lung to the chest wall; the right anterior and middle lobes were adherent in several places to the pericardium.

The right anterior lobe was solid and airless, and from the surface had a pinkish somewhat translucent appearance; on section the bronchi were dilated and filled with muco-pus, the lung tissue surrounding them being pinkish translucent fibroid and airless. The rest of the lung was normal except for one or two collapsed lobules.

Thoracic Glands.—There was a number of scattered yellow calcareous foci in the long mediastinal gland, a few in the other dorsal mediastinal glands, and a few in the left bronchial gland. The right bronchial gland and several glands below the trachea in front of the heart were enlarged and firm; on section they showed an increase in interstitial connective tissue but no tubercles.

Heart.—Normal.

Abdomen.

Omentum and Peritoneum.—Normal.

Liver.—Normal.

Portal Glands.—Normal.

Spleen.—Normal.

Kidneys.—On the surface of each kidney a number of small scars was seen; there were no tubercles.

Suprarenal Bodies.—Normal.

Renal, Lumbar, and Iliac Glands.—Normal.

Alimentary Tract.

Tongue, Pharynx, Palate, Tonsils.—Normal.

Retro-pharyngeal Glands.—In the cortex of the left there was one soft caseous miliary tubercle. The right was normal.

Parotideal Glands.—The left contained one calcareous tubercle. The right was normal.

Submaxillary and Hyoid Glands.—Normal.

Intestines.—Normal.

Mesenteric Glands.—Normal.

Testes.—Normal.

Various Lymphatic Glands.

Precrural, Popliteal, Gluteal, Ischiatic, Pudic.—Normal.

Microscopical Examination.

Emulsion of Prescapular Gland.—Tubercle bacilli numerous.

Emulsion of Consolidated Lung.—No tubercle bacilli seen.

Animals Inoculated.

Calf 1269 was inoculated subcutaneously with 20·0 cc. of an emulsion made from the prescapular gland.

Rabbits 1510–1511 were inoculated subcutaneously each with 3·0 cc. of the same emulsion. The former was killed after 224 days, the latter died in 224 days: both showed chronic general tuberculosis.

Guinea-pig 2612 was inoculated intraperitoneally with an emulsion made from the consolidated lung. It was killed after 64 days and showed tuberculosis of the omentum and the pyloric gland.

CALF 1269. Virus H. 53. "D.H." (*a*).

Subcutaneous inoculation of an emulsion made from the left prescapular gland of Calf 1231.

Dose—20·0 cc. of emulsion, in which T.B. were numerous.

Date of Inoculation—September 26, 1907. [Age about 4 months.]

Killed when in good health—February 13, 1908. [140 days after inoculation.]

Clinical Notes.

Three weeks after the inoculation on the left side of the neck there was a flat slightly-raised subcutaneous tumour irregular in outline measuring 11 by 7 cm. The adjacent prescapular gland was enlarged, not very firm, and measured 8 cm. in length; a prepectoral gland was the size of a small walnut.

Ten weeks after inoculation the tumour was nodular and slightly raised, measuring 10 by 7 cm. The prescapular gland was 7 cm. in length; the prepectoral gland about the size of a Barcelona nut

The calf remained well during the experiment.

Temperature.

There was a very slight rise of temperature commencing on the 16th day after inoculation and lasting 12 days (maximum 39·7° C.). Subsequently the temperature remained normal.

Tuberculin Tests.

October 24, 1907. [28 days after inoculation.] Dose, 2·0 cc. Reacted. Rise of temperature, 1·1° C.

October 30, 1907. [34 days after inoculation.] Dose, 2·0 cc. Reacted. Rise of temperature, 1·8° C.

Weights.

	cwt.	qrs.	lbs.
September 26, 1907	1	2	21
February 13, 1908	3	0	8

Total gain of weight.—1 cwt. 1 qr. 15 lbs.

Average rate of gain per week.—7·75 lbs.

POST-MORTEM EXAMINATION.

The carcass was fat.

Local Lesion.—At the seat of inoculation on the left side of the neck there was a lobulated fluctuating tumour measuring 10 by 8 by 4 cm.; on section it was a multilocular cyst filled with tenacious yellow caseo-pus.

Left Prescapular Gland.—The left prescapular gland measured 7 by 4 by 2 cm.; it contained two softened caseo-calcareous masses, one large and one small, which composed about two-thirds of the gland substance. Each of the masses was surrounded by a capsule of fibrous tissue.

Right Prescapular Gland (6·5 by 2·3 by 1·2 cm.).—Normal.

Prepectoral Glands.—On the left side one, 1 cm. in diameter, was caseo-calcareous almost throughout. Two others were normal.

Thorax.

Pleura.—Normal.

Lungs.—The lungs were crepitant throughout; the lymphatic fringes around the margins of the lungs as well as on the surface were hypertrophied; no tubercles were seen either on the surface or on section.

Thoracic Glands.—The bronchial and mediastinal glands were normal in size; each bronchial gland and the larger mediastinal glands contained sparsely scattered yellow calcareous tubercles, the largest the size of a millet seed. There were about half-a-dozen in the left bronchial gland and the long mediastinal and a smaller number in each of the others; the small mediastinal glands were normal.

Heart.—Normal.

Abdomen.

Omentum and Peritoneum, Liver, Kidneys, and Suprarenal Bodies.—Normal.

Spleen.—In the pulp one grey miliary tubercle with an opaque not gritty centre was seen.

Portal Glands.—One contained a pinhead-sized calcareous tubercle.

Renal, Lumbar, and Iliac Glands.—Normal.

Alimentary Tract.

Tongue, Pharynx, Palate, Tonsils.—Normal.

Retro pharyngeal, Submaxillary, and Parotideal Glands.—Normal.

Intestines.—Normal.

Mesenteric and Ileo-Colic Glands.—Normal.

Testicles.—Normal.

All the Peripheral Lymphatic Glands were normal.

Microscopical Examination.

Emulsion of Left Prescapular Gland.—Tubercle bacilli not numerous.

Emulsion of Mediastinal Gland.—No tubercle bacilli seen.

Animals Inoculated.

Calf 1367 was inoculated subcutaneously with 10·0 cc. of an emulsion made from the left prescapular gland.

Rabbits 1730–1731 were inoculated subcutaneously each with 2·0 cc. of this emulsion. The latter died in 140 days and showed local T., and T. of lungs and kidneys, the former was killed after 250 days and showed chronic G.T. not apparently progressive.

Guinea-pig 2946 was inoculated intraperitoneally with an emulsion made from the spleen (not including the tubercle). It was killed after 230 days and showed slight tuberculosis.

Guinea-pig 2947 was inoculated intraperitoneally with an emulsion made from the long mediastinal gland (including one tubercle). It died in 212 days of general tuberculosis.

CALF 1367. Virus H. 53. "D.H." (*a*).

Subcutaneous inoculation of an emulsion of the left prescapular gland of Calf 1269.

Dose—10·0 cc. of emulsion in which tubercle bacilli were not numerous.

Date of Inoculation—February 13, 1908. [Age about 9 weeks.]

Killed when in good health—June 10, 1908. [118 days after inoculation.]

Clinical Notes.

The calf remained well during the experiment.

Temperature.

Normal throughout.

Tuberculin Tests.

March 4, 1908. [20 days after inoculation.] Dose, 4·0 cc. Leishmann's tuberculin. Reacted. Rise of temperature, 1·0° C.

May 20, 1908. [97 days after inoculation.] Dose, 2·0 cc. Reacted. Rise of temperature, 1·5° C.

Weights.

	cwt.	qrs.	lbs.
February 13, 1908	0	3	22
June 10, 1908	1	2	11

Total gain of weight.—2 qrs. 17 lbs.

Average rate of gain per week.—4·3 lbs.

POST-MORTEM EXAMINATION.

The carcass was in good condition.

Local Lesion.—On the left side of the neck there was a firm circumscribed tumour measuring 6 by 4·5 by 1 cm.; on section it was composed of dense fibrous tissue beset with calcareous foci and containing a small cavity with gritty caseo-pus.

Left Prescapular Gland.—The left prescapular gland measured 6·7 by 3 by 1·6 cm. and showed the cortex extensively replaced by fibro-calcareous patches containing caseous areas, some dense, some softened; about three-quarters of the gland substance was affected.

Right Prescapular Gland.—The right prescapular gland measured 6·5 by 2·4 by 1 cm. and was normal on section.

Prepectoral Glands.—On the left side one the size of a pea was fibro-caseo-calcareous throughout. Other prepectoral glands were normal.

Cervical Glands.—One in the middle of the neck on the left side the size of a broad bean was fibro-caseo-calcareous throughout; the rest were normal.

Thorax.

Pleura.—Normal.

Lungs.—The lungs were normal in general appearance; on the surface of the left caudal lobe under the pleura two grey tubercles with calcareous centres were seen; in the right cephalic lobe there was a minute grey tubercle. No tubercles were seen on section.

Thoracic Glands.—The bronchial and mediastinal glands were normal in size. On section they showed in the cortex sparsely scattered irregular calcareous tubercles varying in size up to a millet seed.

Heart.—Normal.

Abdomen.

Omentum and Peritoneum.—Normal.

Spleen.—Ten grey miliary tubercles with calcareous centres were seen in the pulp.

Liver.—On the surface just under the capsule there was a slightly projecting grey fibrous nodule 2 mm. in diameter with a minute opaque centre. No tubercles were seen on section.

Portal Glands.—Normal.

Coeliac Glands.—One contained a number of pin-head-sized calcareous tubercles. The rest were normal.

Kidneys and Suprarenal Bodies.—Normal.

Renal, Lumbar, and Iliac Glands.—Normal.

Alimentary Tract.

Tongue, Pharynx, Tonsils.—Normal.

Retro-pharyngeal Glands.—Normal.

Parotideal and Submaxillary Glands.—One parotideal and one submaxillary gland contained each a caseo-purulent gritty nodule the size of a hemp seed.

Intestines and Mesenteric Glands.—Normal.

Various Lymphatic Glands.

Precrural, Popliteal, Gluteal, Ischiatic, Pudic, Axillary.—Normal.

Microscopical Examination.

Fibrous Nodule from Liver.—No tubercle bacilli.

Emulsion of Left Prescapular Gland.—Tubercle bacilli in moderate numbers.

Emulsion of Thoracic Gland.—No tubercle bacilli.

Tubercle from Submaxillary Gland.—A few tubercle bacilli.

CALF 1461. Virus H 53. "D.H." (*a*).

Subcutaneous inoculation of culture derived from the thoracic gland of Calf 1367.

Dose—50·0 milligrammes.

Date of Inoculation—October 22, 1908. [Age about 6 months.]

Killed when in good health—February 10, 1909. [111 days after inoculation.]

Clinical Notes.

The calf remained in good health during the experiment.

Temperature.

The temperature rose on the seventh day to 39·5° C. and reached a maximum (40·7° C.) on the thirteenth day; it then slowly returned to the normal; pyrexia lasted 21 days in all. Subsequently the temperature remained normal.

Tuberculin Test.

January 7, 1909. [77 days after inoculation.] Dose, 2·0 cc. Reacted. Rise of temperature, 2·0° C.

Weights.

	cwt.	qrs.	lbs.
October 22, 1908	2	1	2
February 10, 1909	2	2	5

Total gain of weight.—1 qr. 3 lbs.

Average rate of gain per week.—1·9 lbs.

POST-MORTEM EXAMINATION.

The carcass was in good condition.

Local Lesion.—At the seat of inoculation on the left side of the neck there was a prominent fluctuating tumour measuring 12 by 9 by 6·5 cm.; on section it was a cyst containing yellowish slightly turbid fluid and caseo-necrotic masses; the walls were composed of pinkish fibroid tissue varying from 5 to 10 mm. in thickness, lined internally with granulation tissue; the cavity was crossed by thick fibrous trabeculæ.

Left Prescapular Gland.—The left prescapular gland measured 5·8 by 3·5 by 3 cm. and showed about three-quarters of its substance replaced by tuberculous tissue, partly calcareous and partly dense and caseous. The cortex of the rest of the gland showed scattered calcareous grains.

The Right Prescapular Gland measured 5 by 2 by 1 cm. and was normal on section.

Prepectoral Glands.—On the left side one, 1 cm. in diameter, was caseo-calcareous in the centre. The rest were normal.

Cervical Glands.—One on the left side, not apparently enlarged, was partly calcareous. The rest were normal.

Thorax.

Lungs, Pleura, Heart.—Normal.

Thoracic Glands.—The left bronchial and one of the dorsal mediastinal glands contained very sparsely scattered minute calcareous foci; other thoracic glands were normal.

Abdomen.

Omentum and Peritoneum, Spleen, Kidneys, and Suprarenal Bodies.—Normal.

Liver.—Under the capsule of the liver there was one grey tubercle, 1 mm. in diameter, with a slightly opaque centre.

Portal Glands.—Normal.

Genito-Urinary System.

Uterus.—Normal.

Mamma.—The milk sinuses contained a small quantity of opalescent fluid. The mammary tissue was normal.

Supramammary Lymphatic Glands.—The one on the right side contained a group of three caseous and softened tubercles.

All the remaining organs and glands were examined and found healthy.

Microscopical Examination.

Emulsion of Left Prepectoral Gland.—Tubercle bacilli numerous.

Secretion from one of the Milk Sinuses of the Mamma.—A moderate number of tubercle bacilli. Numerous cells, alveolar cells, lymphocytes, a few leucocytes.

Tubercle from the Liver.—No tubercle bacilli.

Animal Inoculated.

Guinea-pig 3476 was inoculated intraperitoneally with a few drops of fluid from one of the milk sinuses of the mamma.

CALF 1435. Virus H. 53. "D.H." (*a*).

Subcutaneous inoculation of culture derived from the long mediastinal gland of Goat 57.

Dose—50·0 milligrammes.

Date of Inoculation—September 15, 1908.

Killed when in good health—December 18, 1908. [94 days after inoculation.]

Clinical Notes.

A very large tumour developed at the seat of inoculation on the left side of the neck, and the adjacent prescapular gland became enormously enlarged.

On October 19, 34 days after inoculation, the tumour measured 19 cm. in length and 13 cm. in breadth; it was heavy, pendulous, and cystic. The prescapular gland was about 14 cm. in length. The temperature, which had been raised and irregular since the inoculation, was now normal, and the general condition of the animal was good.

The tumour subsequently opened and discharged caseo-purulent contents, and both it and the prescapular gland diminished greatly in size.

The general health of the calf appeared to be good throughout the period of the experiment, but it did not increase in weight.

Temperature.

There was a period of irregular pyrexia, commencing on the third day after inoculation and lasting 31 days.

The highest temperature recorded during this period was 40·9° C., the lowest 38·6° C.

Subsequently the temperature was normal.

Tuberculin Test.

The calf was not tested subsequent to inoculation.

Weights.

	cwt.	qrs.	lbs.
September 15, 1908	1	3	14
December 18, 1908	1	3	17

Total gain of weight.—3 lbs.

POST-MORTEM EXAMINATION.

The carcass was in good condition.

Local Lesion.—At the seat of inoculation there was a firm prominent lesion measuring 13 by 8 by 4 cm.; on section it was composed of thickened skin, 1 cm. in greatest thickness, showing softened caseous nodules, and a mass of pinkish fibroid tissue containing softened discrete caseous nodules and a small cavity filled with tenacious caseo-pus. The skin showed on the surface a shallow depression, from the bottom of which a narrow sinus led into the cavity in the body of the tumour. The muscles under the tumour showed a moderate number of caseous nodules up to a pea in size.

Left Prescapular Gland.—The left prescapular gland measured 8 by 6·5 by 5·5 cm.; it was composed of breaking-down caseous substance, slightly gritty from calcification, and had a very thick capsule from which trabeculæ of fibrous tissue passed into the gland; projecting from the convex surface there was a soft fluctuating swelling filled with caseous pus; the capsule over this was thinned and adherent to the muscles.

Right Prescapular Gland.—The right prescapular gland measured 4 by 1·7 by 1 cm., and was normal on section.

Prepectoral Glands.—On the left side, two were much enlarged and on section were found to be composed of glandular tissue, rather firmer than normal, but free from caseation or calcification.

The glands on the right side were normal.

Cervical and Axillary Glands.—Normal.

Thorax.

Lungs.—The left lung showed on the surface about a dozen nodules, ranging in size from a pin's head to a hemp seed; they had caseous or casco-calcareous centres and grey margins; the right lung contained about half a dozen similar nodules. No nodules were seen on section.

Thoracic Glands.—The left bronchial gland contained a hemp-seed sized caseous and softened nodule. Other thoracic glands were normal.

Pleura and Heart.—Normal.

Abdomen.

Omentum and Peritoneum.—Normal.

Spleen, Liver, and Portal Glands.—Normal.

Kidneys.—Normal.

Suprarenal Bodies.—Each suprarenal showed in the cortex a caseous nodule with a grey fibrous margin, rather smaller than a hemp seed.

Renal, Lumbar, and Iliac Glands.—Normal.

Alimentary Tract.

Tongue, Pharynx, Palate, Tonsils.—Normal.

Submaxillary, Retro-pharyngeal, and Parotideal Glands.—Normal.

Intestines.—Normal.

Mesenteric Glands.—Two mesenteric glands contained each one caseous and softened nodule with a fibrous wall, one the size of a millet seed, the other that of a pea.

Ileo-Colic Glands.—Three glands showed in the cortex caseo-calcareous patches.

Testicles.—Normal.

Various Lymphatic Glands.

Precrural, Popliteal, Gluteal, Ischiatic, Pudic.—Normal.

Microscopical Examination.

Smear from Lung Tubercle.—A few tubercle bacilli.

Smear from Bronchial Gland Nodule.—A few tubercle bacilli.

PIG 85. Virus H. 53. "D.H." (*a*).

Subcutaneous inoculation of culture derived from the original material through Guinea-pig 1482.

Dose—50·0 milligrammes.

Date of Inoculation—February 25, 1907. [Age 5 months.]

Killed when in good health—February 26, 1908. [366 days after inoculation.]

Clinical Notes.

The pig remained well during the experiment, and gained weight rapidly.

Temperature.

Normal.

Tuberculin Test.

July 5, 1907. [130 days after inoculation.] Reacted. Rise of temperature, 2·1° C.

Weights.

	cwt.	qrs.	lbs.
February 25, 1907	0	3	4
February 26, 1908	3	0	24

Total gain of weight.—2 cwt. 1 qr. 20 lbs.

Average rate of gain per week.—5·2 lbs.

POST-MORTEM EXAMINATION.

The carcass was fat.

Local Lesion.—In the subcutaneous fatty tissues on the right side of the abdomen scattered over a wide area there were caseous nodules ranging in size from a millet seed to a large pea; they had each a thin fibrous wall, and the caseous substance was dry cheesy and gritty; 24 to 30 were counted; there were a few similar tubercles in the muscles of the abdominal wall. Between the muscles at the right margin of the thorax half a dozen large caseous nodules were subsequently found.

No scars were seen in the skin, which was not adherent to any of the nodules; there was however in the subcutaneous tissues a puckered scar with fibrous processes radiating in all directions from its margins, which probably marked the site of inoculation.

Superficial Inguinal Glands.—In the group on the right side there were two large glands 2·5 cm. in greatest diameter, which were composed throughout of cheesy caseous slightly gritty substance, surrounded by a fibrous capsule ; four smaller glands in this group were caseous almost throughout or contained caseous nodules ; some smaller ones were normal.

The glands on the left side were normal.

Inguinal Glands.—Normal.

Ventral Mediastinal Glands.—The gland on the right side measured 2 cm. in diameter, and was dense and caseo-calcareous throughout ; the one on the left side was normal.

Thorax.

Pleura.—Normal.

Lungs.—There were no adhesions to the chest wall ; there were however a few slender fibrous adhesions between the lobes on each side. The lungs were expanded and showed on the surface numerous slightly raised nodules, ranging in size from a millet seed to that of a pea ; a few were surrounded by a small amount of reddish consolidated tissue, while the pleura over others was thickened or showed soft connective tissue outgrowths ; in the thin margins of the lungs especially were several consolidated lobules containing a number of caseous nodules.

On section of the lung the parenchyma was found to be evenly beset with nodules similar to those seen from the surface ; they were caseous, some were gritty, and all had moderately thick fibrous capsules from which the caseous substance was readily shelled.

Bronchial Glands.—The bronchial glands were enlarged and indurated, and contained discrete caseous nodules similar to those in the portal glands, but not so numerous.

Dorsal Mediastinal Glands.—Normal.

Heart.—Normal.

Abdomen.

Omentum and Peritoneum.—Normal.

Spleen.—The spleen was not enlarged and was normal on the surface. It showed in the pulp scattered evenly distributed dry caseo-calcareous nodules with thin grey capsules ranging in size from a pin's head to that of a small hemp seed ; ten were counted in an area of the cut surface 5 cm. square.

Liver.—The liver contained fairly numerous encapsuled caseous nodules, ranging in size from 2 to 9 mm. in diameter (the majority varied from 5 to 6 mm.) ; sixty were counted on the anterior surface and a much smaller number on the posterior, and they were scattered fairly evenly in the depth ; the caseous substance was dry cheesy and gritty, and was readily shelled out from the fibrous capsule.

Kidneys.—In the cortex of each there were three nodules, the largest 8 mm. in diameter, similar to those in the liver.

Suprarenal Bodies.—Normal.

Iliac Glands.—One on the right side was slightly enlarged and had a mulberry-like outline ; on section it was closely beset with firm caseous gritty nodules up to 5 mm. in diameter, with thin fibrous capsules from which the caseous substance was readily shelled ; a smaller gland contained half a dozen similar nodules.

The left iliac glands were normal.

Lumbar Glands.—Three, not apparently enlarged, contained two and three caseo-calcareous tubercles up to a millet seed in size.

Coeliac Glands.—Some were slightly enlarged ; they contained discrete caseous gritty nodules ranging in size from a pin's head to that of a hemp seed.

Portal and Pancreatic Glands.—These glands contained nodules similar to those in the iliac glands, but attaining a larger size.

Alimentary Tract.

Tongue, Pharynx, Tonsils.—Normal.

Submaxillary Glands.—The left contained three caseo-calcareous miliary tubercles ; the right about half a dozen, on the whole larger ones.

Cervical Glands.—A left mid-cervical gland contained a pea-sized caseous and softened nodule, another a millet-seed sized tubercle.

One on the right side near the episternum showed a small caseous nodule.

Other cervical glands were normal.

Intestines.—Normal.

Mesenteric Glands.—All the mesenteric glands contained several caseous nodules, the largest the size of a pea.

Ileo-Colic Glands.—The ileo-colic glands showed similar nodules.

Colic Glands.—Large caseous nodules were found in some of the colic glands.

Prescapular Glands.—The right contained one hemp-seed sized caseous gritty nodule ; the left was normal.

Microscopical Examination.

Emulsion of tubercle from Lung.—No tubercle bacilli seen.

Emulsion of tubercle from Liver.—No tubercle bacilli seen.

Animals Inoculated.

Guinea-pig 2982 was inoculated intraperitoneally with the emulsion made from the lung (died, 73 days, no tuberculosis) ; and 2981 intraperitoneally with that made from the liver (killed, 88 days, slight tuberculosis).

PIG 87. Virus H. 53. "D.H." (*a*).

Subcutaneous inoculation of culture derived from the original material through Guinea-pig 1482.

Dose—10·0 milligrammes.

Date of Inoculation—February 25, 1907. [Age 5 months.]

Killed when in good health—October 10, 1907. [227 days after inoculation.]

Clinical Notes.

The pig showed no signs of ill-health during the experiment, and grew normally.

Temperature.

Normal.

Tuberculin Test.

July 5, 1907. [130 days after inoculation.] Reacted. Rise of temperature, 2·5° C.

Weights.

	cwt.	qrs.	lbs.
February 25, 1907	0	2	20
October 10, 1907	1	3	23

Total gain of weight.—1 cwt. 1 qr. 3 lbs.

Average rate of gain per week.—4·4 lbs.

POST-MORTEM EXAMINATION.

The carcass was fat.

Local Lesion.—The skin on the right side of the abdomen between the crest of the ilium and a line midway between the xiphisternum and umbilicus showed a series of widely distributed slightly raised nodules ; one was large, measuring 2 cm. in diameter, and was a thin-walled cyst with yellow tenacious caseo-purulent contents ; the others varied in size up to that of a pea ; some were movable under the skin, others were adherent, the skin being either ulcerated or thin and slightly bluish ; on section the nodules were composed of breaking-down caseous substance, surrounded by a thin fibrous capsule. Similar nodules were found in the subcutaneous fatty tissue and in the superficial muscles ; they were rather numerous in the immediate neighbourhood of the large cyst, but elsewhere were sparsely scattered.

Superficial Inguinal Glands.—On the right side three were enlarged, the largest 2·5 cm. in greatest diameter, and were composed throughout of greyish-yellow friable mortary-looking caseous substance, very slightly gritty from calcification, which readily shelled out *en masse* from a thin fibrous capsule.

The other glands on this side and all those on the left were normal.

Ventral Mediastinal Glands.—One on the right side was very large, measuring 4·5 cm. in length, and showed more than three quarters of its substance composed of caseous material similar to that in the inguinal glands. The one on the left side was normal.

Precrural Glands.—Normal.

Abdomen.

Omentum and Peritoneum.—Normal.

Spleen.—The spleen showed in the pulp evenly distributed yellow nodules, not in very large number, varying in size from a pin's head to about that of a hemp seed ; they were caseo-calcareous and had a thin fibrous capsule from which the caseous substance was readily shelled ; some projected nearly their whole diameter from the surface, others were just visible under the capsule ; forty eight were counted on the convex surface.

Liver.—The liver contained sparsely scattered nodules similar to those in the spleen.

Portal Glands.—The portal glands were normal in size, and contained sparsely scattered caseo-calcareous tubercles, the largest the size of a millet seed.

Kidneys.—The left kidney showed in the depth of the cortex a calcareo-caseous nodule with a fibrous margin, 2 mm. in diameter. The right was normal.

Suprarenal Bodies.—Normal.

Coeliac Glands.—Two coeliac glands, not enlarged, showed on section a few soft caseous tubercles, the largest 1 mm. in diameter, some slightly gritty.

Pancreatic Glands.—A caseo-calcareous tubercle was found in each of two of these glands.

Iliac and Ilio-Sacral Glands.—Normal.

Lumbar Glands.—One lumbar gland contained a caseo-calcareous tubercle the size of a millet seed, and three or four minute whitish foci.

Thorax.

Pleura and Diaphragm.—There was a small caseo-calcareous nodule on the parietal pleura.

The tendon of the diaphragm contained a lenticular caseous gritty nodule with a fibrous capsule, 7 mm. in greatest diameter, which projected slightly from both surfaces of the diaphragm.

Lungs.—The lungs were fuller and firmer than normal and somewhat congested ; they showed under the pleura fairly numerous (36 were counted in an area 5 cm. square) yellow caseous nodules, ranging from 1 to 5 mm. in diameter, which on section were softened and had thin fibrous capsules ; there were besides a number of grey tubercles some slightly opaque in the centre irregularly distributed and tending to occur in groups ; similar nodules and tubercles were seen on section of the lung.

In the anterior lobes and in the antero-ventral parts of the caudal lobes chiefly, but also occasionally in other parts of the caudal lobes, firm very irregular consolidated patches were seen which on section were composed of reddish fibroid tissue beset with soft caseous tubercles some gritty ; they occupied the whole or part of a lobule, and in the anterior lobes here and there formed serpiginous tracts running around the peripheral parts of lobules.

Thoracic Glands.—The bronchial glands were moderately large and were congested and firmer than normal ; they contained however only sparsely scattered caseous nodules, the largest the size of a hemp seed.

One dorsal mediastinal gland showed several minute calcareous tubercles.

Heart.—Normal.

Alimentary Tract.

Tongue, Tonsils, Pharynx.—Normal.

Submaxillary Glands.—The right submaxillary gland contained a pinhead-sized spherical calcareous tubercle which readily shelled out. The left was normal. Other lymphatic glands in the neck were also normal.

In the left submaxillary salivary gland there was a pea-sized caseous nodule.

Intestines.—Normal.

Mesenteric Glands.—Scattered dry caseo-calcareous nodules were found in the mesenteric glands, one measuring 1 cm. in diameter, the others not larger than 5 mm.

The ileo-colic glands were normal.

Thymus Gland.—A pinhead-sized yellow tubercle was found in the thymus gland.

Larynx and Trachea.—Normal.

Prescapular and Prepectoral Glands.—Normal.

Microscopical Examination.

Tubercle from the Thymus.—One tubercle bacillus seen.

Nodule from the Submaxillary Salivary Gland.—No tubercle bacilli seen.

Nodule from the Left Kidney.—A few tubercle bacilli were seen.

PIG 89. Virus H. 53. "D.H." (*a*).

Subcutaneous inoculation of culture derived from the original material, through Guinea-pig 1482.

Dose—1·0 milligramme.

Date of Inoculation—February 25, 1907. [Age 5 months.]

Killed when in good health—June 28, 1907. [123 days after inoculation.]

Clinical Notes.

The pig remained well during the whole period of the experiment.

Temperature.

Normal throughout.

Weights.

	cwt.	qrs.	lbs.
February 25, 1907	0	3	9
June 28, 1907	1	2	18

Total gain of weight during experiment.—3 qrs. 9 lbs.

Average rate of gain per week.—5·3 lbs.

POST-MORTEM EXAMINATION.

Carcass in good condition.

Local Lesion.—In the skin of the abdominal wall to the right of the umbilicus there was a linear cicatrix showing on its surface four small ulcers covered with dry scabs; in the subcutaneous tissues immediately beneath this were several caseous nodules, varying up to a pea in size; some of these were adherent to the cicatrix and formed the base of the ulcers above described. The skin between this lesion and the superficial inguinal glands showed from 8 to 10 widely distributed projecting nodules, the largest about 1 cm. in diameter, several of which were ulcerated and covered with a dry scab; the skin over the others was thin and bluish.

In the subcutaneous fatty tissues between the cicatrix and the glands were several nodules, not adherent to the skin, the largest 1 cm. in diameter. All the nodules on section were found to be filled with thick caseo-purulent substance.

Superficial Inguinal Glands.—On the right side one at the anterior extremity of the group contained a hemp-seed-sized softened caseous nodule; the others were normal. A little anterior to this group there was an isolated gland, the size of a broad bean, half the substance of which was caseous and softened.

Thorax.

Pleura.—Normal.

Lungs.—The lungs collapsed normally, and were moderately closely beset with hard nodules varying greatly in size, from 1 to 10 mm. in diameter; the nodules under the pleura projected from the surface. On section some of the larger nodules were spherical and caseous throughout, but the majority were somewhat lobulated, and were composed of firm translucent fibroid tissue containing softened caseous foci of various sizes; the smaller nodules had caseo-calcareous centres and fibrous margins; calcareous grains were just perceptible in some of the larger nodules.

Thoracic Glands.—The bronchial glands were slightly enlarged, and beset with greenish yellow softened caseous masses and small caseous tubercles.

The dorsal mediastinal glands were normal.

Ventral Mediastinal Glands.—One on the right side showed at one extremity a group of four greenish yellow caseous nodules, the largest the size of a pea.

Heart.—Normal.

Abdomen.

Peritoneum.—The serous surfaces of the large intestine and stomach were roughened with short villous processes of connective tissue; attached to the extremities of a few of those on the stomach were small haemorrhagic tubercles.

There was similar roughening of the peritoneum on the left side of the diaphragm, which showed also one slightly raised hard grey tubercle the size of a millet seed.

Omentum.—Normal.

Liver.—The liver showed under the capsule altogether about twenty nodules, ranging in size from 1 to 5 mm. in diameter; the larger nodules were caseous and softened and slightly gritty, the small ones had caseo-calcareous centres; all had fibrous margins from which the caseous centre could be readily separated. Similar nodules were sparsely distributed throughout the substance of the liver.

Portal Glands.—The portal glands were slightly enlarged and closely beset with softened caseous nodules ranging in size from a millet seed to a large pea.

Coeliac Glands.—The coeliac glands were slightly enlarged; one was yellow caseous and softened throughout, two were partly caseous; two or three contained a few discrete caseous nodules up to a hemp seed; the rest were normal.

Spleen.—The spleen was normal in size; in the pulp were scattered nodules similar to those in the liver; there was besides one large spherical softened caseous nodule 1 cm. in diameter, which projected about half its diameter from the surface.

Kidneys and Suprarenal Bodies.—Normal.

Iliac, Ilio-Sacral, and Lumbar Glands.—Normal.

Alimentary Tract.

Tongue, Pharynx, Tonsils.—Normal.

Intestines.—Normal.

Mesenteric Glands.—One contained a millet seed sized caseous tubercle.

Ileo-Colic and Colic Glands.—Normal.

Various Lymphatic Glands.

Submaxillary Glands.—Each submaxillary gland contained about half a dozen yellow caseous tubercles, the largest rather larger than a millet seed.

Retro-pharyngeal Glands.—Normal.

Cervical Glands.—One in the middle of the neck on the right side showed a pea-sized softened caseous nodule. Other cervical glands were normal.

Prescapular and Prepectoral Glands.—Normal.

Microscopical Examination.

Emulsion of Spleen Nodule.—Tubercle bacilli scanty.

PIG 121. Virus H. 53. "D.H." (*a*).

Subcutaneous inoculation of culture derived from the original material through G.P. 1482.

Dose—50·0 milligrammes.

Date of Inoculation—February 6, 1908. [Age 12½ weeks.]

Died—July 1, 1908. [146 days after inoculation.]

Clinical Notes.

The respiration was noticed to be affected some two months before death, and the pig was small and thin as compared with its fellow; the respiration slowly became more rapid and laborious, and the animal became weak and very emaciated; death ensued on the 146th day.

Weights.

	qrs.	lbs.
February 6, 1908	1	12
July 1, 1908...	1	22

Total gain of weight.—10 lbs.

POST-MORTEM EXAMINATION.

The carcass was emaciated.

Local Lesion.—The skin of the abdomen on the left flank showed close together several small dry ulcers; on section in the subcutaneous and muscular tissues under these there was a small mass composed of closely aggregated caseous tubercles from a millet to a hemp seed in size; here and there there was a larger softened caseous nodule; between this mass and the inguinal glands were scattered caseous tubercles.

Inguinal Glands.—On the left side there was a mass measuring 4 by 3·3 by 1·5 cm. composed of several glands which were cheesy and caseous throughout. Posterior to this mass there was a single gland 1 cm. in diameter caseous throughout.

The right inguinal glands were normal.

Ventral Mediastinal Glands.—On the left side there was a large gland 3·3 cm. in length which was composed throughout of dense caseous slightly gritty substance. Attached to the large gland was a small one which contained caseo-calcareous nodules.

On the right side a gland contained a pinhead-sized caseous tubercle.

Iliac Glands.—On the left side there was a glandular mass measuring 3·4 c.m. in greatest diameter composed practically throughout of cheesy caseous slightly gritty substance.

On the right side there was one gland with a pinhead-sized caseous tubercle.

Thorax.

Lungs.—The lungs filled the chest and did not collapse; they weighed 2 lbs. 13 ozs.; the lung tissue was firm, congested on the surface, and showed well-marked lobulations. On section the lungs throughout resembled pancreas, the lobules being composed of solid greyish tissue; most of the lobules in the anterior lobes were homogeneous; then here and there some of the lobules showed the periphery opaque and yellowish; in the caudal lobes and especially towards the posterior parts most of the lobules contained discrete cheesy caseous tubercles up to 2 or 3 mm. in diameter; a few of the lobules were more extensively caseated and showed small cavities; there was very little crepitant lung tissue remaining and this was very emphysematous.

Bronchial Glands.—The bronchial glands were much enlarged and deeply congested; they showed on section moderately numerous cheesy caseous nodules varying in size up to a hemp seed; in places they were confluent, forming irregular patches; the caseous substance was just perceptibly gritty.

Pleura.—Normal.

Heart.—Normal.

Abdomen

Omentum and Peritoneum.—Normal.

Spleen.—The spleen was normal in size; no tubercles were seen on surface or on section.

Liver.—Normal.

Gall-bladder.—On the surface of the gall-bladder there were two flat grey growths with undermined margins, the larger about 5 mm. in greatest diameter.

Portal Glands.—The portal glands were moderately enlarged; on section they were closely beset with softened caseous nodules up to a hemp seed in size, not perceptibly gritty; the caseous substance readily shelled out from a thin fibrous capsule with a smooth internal surface.

Coeliac Glands.—The coeliac glands, slightly enlarged, contained fairly numerous discrete caseous tubercles up to a millet seed in size which readily shelled out leaving a smooth-walled cavity.

Kidneys.—The kidneys were much enlarged, flabby, and pale; the cortices were peppered with minute yellow points (urinary salts); the medullary zones showed fine yellowish striae which extended into the papillary zones; no tubercles were seen.

Suprarenal Bodies.—Normal.

Lumbar and Renal Glands.—The lumbar and renal glands resembled the coeliac, but the tubercles were on the whole larger and more numerous.

Ilio-sacral Glands.—The ilio-sacral glands contained a few discrete caseous tubercles.

Alimentary Tract.

Tongue, Pharynx.—Normal.

Tonsils.—Many of the crypts contained soft yellow pultaceous substance.

Submaxillary and Retro-pharyngeal Glands.—Normal.

Cervical Glands.—One on each side just in front of the first rib contained a pinhead-sized caseous tubercle; the rest were normal.

Small Intestine.—Normal.

Large Intestine.—The mucous membrane of the large intestine showed numerous small ulcers (not tuberculous).

Mesenteric Glands.—In the anterior third of the mesentery the glands were normal; then they began to show discrete nodules, and gradually as one passed towards the posterior part they became more and more severely affected, those in about the last fourth being enlarged and caseous practically throughout; the ileo-colic glands were also enlarged and extensively caseous.

Testes.—Normal.

Prescapular and Axillary Glands.—Normal.

Microscopical Examination.

Yellow focus from right Tonsil.—T.B. moderately numerous.

PIG 119. Virus H. 53. "D.H." (*a*).

Subcutaneous inoculation of culture derived from the original material through Guinea-pig 1482.

Dose—10·0 milligrammes.

Date of Inoculation—February 6, 1908. [Age—12½ weeks.]

Killed when in good health—September 16, 1908. [225 days after inoculation.]

Clinical Notes.

The pig remained well during the experiment.

Weights.

	cwt.	qrs.	lbs.
February 6, 1908	0	1	12
September 16, 1908	1	0	26

Total gain of weight.—3 qrs. 14 lbs.

POST-MORTEM EXAMINATION.

The carcass was fat.

Local Lesion.—In the superficial muscles of the left side of the abdomen there was a tough fibro-caseous mass calcareous around the margin measuring 4·5 by 2 by 1·5 cm.; it was surrounded by a capsule of fibrous tissue.

Inguinal Glands.—On the left side one near the lesion measured 2 cm. in greatest diameter, and was composed of dense pinkish fibro-caseous substance highly calcareous around the margins; another gland 1 cm. in diameter was calcareo-caseous throughout; the rest were normal. Those on the right side were normal.

Ventral Mediastinal Gland.—The ventral mediastinal gland on the left side was the size of a pigeon's egg and was dense and caseous throughout, the margins being highly calcareous; the caseous substance shelled out en masse from a fibrous capsule.

Thorax.

Pleura.—Normal.

Lungs.—The lungs were crepitant throughout; they contained moderately numerous evenly distributed shotty tubercles, ranging in size from that of a pin's head to that of a millet seed; on section they were found to be completely calcareous and to have thin fibrous capsules.

Bronchial Glands.—The bronchial glands were slightly enlarged and were closely beset with irregular calcareous tubercles.

Heart.—The pericardium was adherent to the heart; between the layers there were four flattened millet-seed sized fibrous tubercles, three with calcareous centres. The heart muscle and valves were normal.

Abdomen.

Omentum and Peritoneum.—Normal.

Spleen.—Two calcareous tubercles, the largest the size of a pin's head, were found in the spleen pulp.

Liver.—Under the capsule four small grey tubercles were seen; none were seen in the depth.

Portal Glands.—The portal glands were slightly enlarged and closely beset with irregular calcareous tubercles up to a hemp seed in size.

Kidneys and Suprarenal Bodies.—Normal.

Coeliac Glands.—Two were slightly enlarged and contained a moderate number of millet-seed sized calcareo-caseous tubercles.

Lumbar Glands.—Two contained together half a dozen calcareous tubercles, the largest the size of a millet seed.

Iliac Glands.—The left contained four calcareous tubercles up to a small pin's head in size. The right was normal.

Alimentary Tract.

Tongue, Pharynx, Tonsils.—Normal.

Submaxillary Glands.—The left contained two caseous tubercles, the largest the size of a millet seed. The right was normal.

Retro-pharyngeal Glands.—Normal.

Intestines.—Normal.

Mesenteric Glands.—The glands in the anterior part of the mesentery contained scattered calcareous tubercles; those in the posterior part became more severely affected as one proceeded backwards, the terminal ones being slightly enlarged and almost entirely calcareous.

Colic Glands.—There were a few miliary caseo-calcareous tubercles in the colic glands.

Various Lymphatic Glands.

Cervical, Prescapular, Axillary, Pudic, and Precrural.—Normal.

Uterus.—Normal.

Microscopical Examination.

Crushed Tubercle from the Pericardium.—A few tubercle bacilli.

Emulsion of Bronchial Gland.—A few tubercle bacilli.

GOAT 65 [Kid]. Virus H. 53. "D.H." (*a*).

Subcutaneous inoculation of culture derived from the original material through Guinea-pig 1482.

Dose—10·0 milligrammes.

Date of Inoculation—February 6, 1908. [Age 5 months.]

Died—March 15, 1908. [38 days after inoculation.]

Clinical Notes.

The illness was of sudden onset; it commenced about a week before death, with rapid breathing and loss of appetite. The respiration increased in frequency and during the last two days was extremely quick. The goat became emaciated and progressively weaker, and died in the afternoon of March 15.

Temperature.

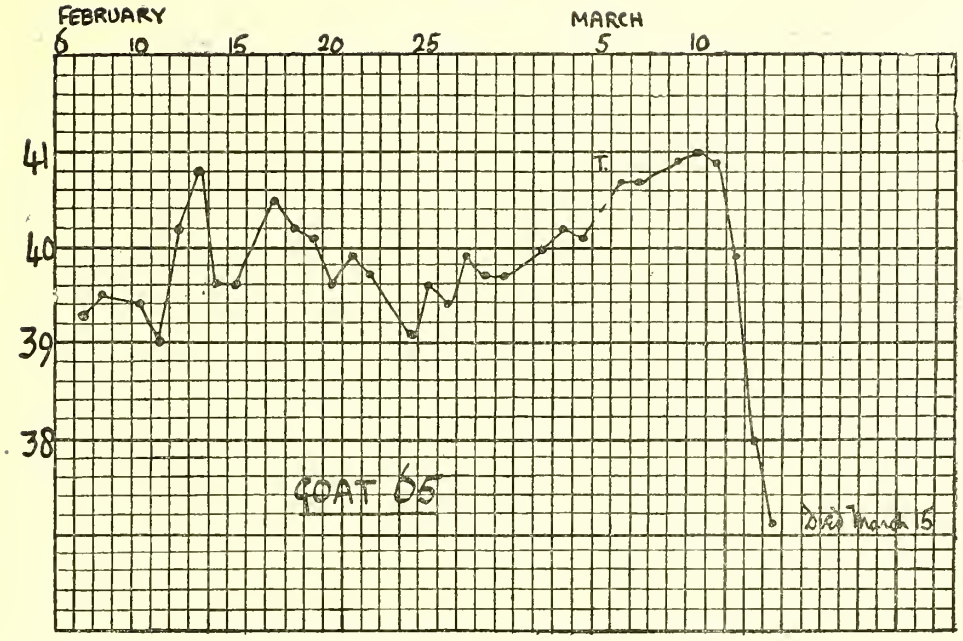

Tuberculin Test.

March 4. [27 days after inoculation.] Dose : 2·0 cc. Leishmann's tuberculin. No reaction. Rise of temperature, 0·2° C.

Weights.

	qr.	lbs.
February 6, 1908	1	20
March 15, 1908	1	9

Total loss of weight.—11 lbs.

POST-MORTEM EXAMINATION.

The carcass was emaciated.

Local Lesion.—At the seat of inoculation on the left side of the neck there was a slightly raised well-defined tumour measuring 10 by 7 by 3 cm. ; it was composed of congested yellow caseo-necrotic substance which readily broke down when scraped with a scalpel, and in which there were several irregular cavities filled with thin blood-stained yellow pus. The muscles and the skin were infiltrated, the latter showing an ulcerous opening which communicated with one of the cavities in the tumour.

Left Prescapular Gland.—The left prescapular gland measured 4·5 by 2·8 by 2 cm. and was composed practically throughout of firm caseated tissue occurring in places in the form of a coarse network in a translucent fibroid matrix ; minute calcareous foci were scattered throughout.

Right Prescapular Gland.—The right prescapular gland measured 3 by 1 by 0·8 cm., and showed in the cortex three firm caseating nodules up to 1 cm. in diameter.

Prepectoral Glands.—On the left side one the size of a large pea contained a caseating nodule which replaced about half of its substance. A smaller gland showed around the outer margin of the cortex several small caseous tubercles. A third gland was normal.

On the right side one gland was found which was normal on section.

Cervical Glands.—On the left side the superior cervical gland was the size of a kidney bean and was caseous almost throughout ; the lower cervical gland was enlarged and showed in the cortex several small groups of caseous tubercles. The right cervical glands appeared normal.

Axillary Glands.—Normal.

Thorax.

Pleura.—The parietal pleura was normal. On the diaphragmatic pleura there was one grey miliary tubercle.

Lungs.—The lungs on opening the chest did not collapse ; they were firm heavy deeply congested and extensively consolidated, and beset almost as closely as possible with miliary caseating tubercules with grey margins and in many cases gritty centres.

Thoracic Glands.—The long mediastinal gland was two or three times the normal in size ; it was firm congested and showed in the cortex small very irregular yellow caseous patches rather numerous in the anterior half but sparsely scattered in the posterior.

There were four small dorsal mediastinal glands. Two of these were caseating almost throughout ; the other two showed more or less discrete caseous tubercles in the cortex.

The bronchial glands were enlarged ; on section they were reddish in colour and infiltrated with irregular caseous tracts.

Heart.—Normal.

Abdomen.

Omentum and Peritoneum.—Normal.

Spleen.—The pulp was soft ; the Malpighian bodies were well-marked and were seen as grey bodies 1 mm. or more in diameter, a few of which had yellow centres.

Liver.—There was well-marked lobulation. Under the capsule of the Spigelian lobe a few minute grey foci were just visible ; no foci were visible elsewhere from the surface ; on section one or two doubtful grey foci were seen.

Portal Glands.—The glands were normal in size and no tubercles were seen.

Kidneys.—The substance of both kidneys, particularly the cortical portions, was speckled with fine dust-like foci, and the tubules were mapped out as fine greyish and in the papillary zone as yellowish streaks ; in the cortex of the left kidney there were a few submiliary grey tubercles ; in that of the right only one minute grey focus was seen (? an early tubercle).

Suprarenal bodies.—The suprarenal bodies were pale and showed in the cortex a few small grey tubercles : a minute grey tubercle was seen in the medulla of one of the bodies.

Coeliac Glands.—A few minute grey foci were seen in the coeliac glands.

Alimentary Tract.

Tongue, Pharynx, and Tonsils.—Normal.

Submaxillary, Parotideal, and Retro-pharyngeal Glands.—Normal.

Intestines.—The mucous membrane was deeply congested ; no tubercles were seen.

Mesenteric Glands.—All the mesenteric glands showed in the cortex scattered greyish-white foci ; in the medullary parts of the gland there was an occasional miliary tubercle with caseous centre and grey margin.

Various Lymphatic Glands.

Renal, Lumbar, Iliac, Precrural, and Popliteal.—Normal.

Microscopical Examination.

Emulsion of Lung.—A few tubercle bacilli seen.

Yellow centre of a Malpighian body from Spleen.—A few tubercle bacilli seen.

General scraping from Kidney.—One tubercle bacillus seen.

General scraping from Liver.—A few small clumps of tubercle bacilli seen.

General scraping from Coeliac Gland.—Three tubercle bacilli seen.

General scraping from Parotideal Gland.—No tubercle bacilli seen.

Animals Inoculated.

Goat 57 was inoculated subcutaneously with 10·0 cc. of an emulsion made from the lung.

Rabbits 1771 and 1772 were inoculated subcutaneously with the same emulsion. The former died in 36 days and showed local tuberculosis, early tuberculosis of lungs, and psorospermosis of liver ; the latter died in 195 days of chronic general tuberculosis.

GOAT 57 [Adult Female]. Virus H. 53. "D.H." (*a*).

Subcutaneous inoculation of an emulsion made from the lung of Goat 65.

Dose—10·0 cc. of the emulsion, in which T.B. were not numerous.

Date of Inoculation—March 16, 1908.

Died—June 13, 1908. [89 days after inoculation.]

Clinical Notes.

About a month after inoculation the respiration was noticed to be quickened. The goat lost appetite and slowly became ill and thin ; the difficulty of respiration increased ; emaciation became more pronounced ; and death supervened on the 89th day after inoculation.

Temperature.

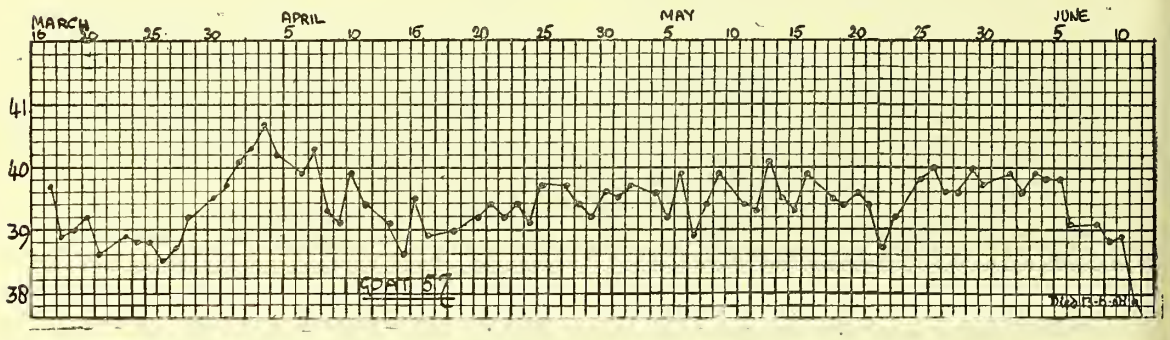

Tuberculin Test.

The goat was not tested subsequent to inoculation.

Weights.

	qrs.	lbs.
March 16, 1908	3	9
June 13, 1908	2	5

Total loss of weight.—1 qr. 4 lbs.

Average rate of loss per week.—2·5 lbs.

POST-MORTEM EXAMINATION.

The carcass was emaciated.

Local Lesion.—On the left side of the neck there was an ulcerated lesion measuring 8·5 by 6 by 2 cm. ; the ulcer measured 5 by 4·5 cm. in area and showed a very irregular floor formed by dried caseous substance and irregular everted fissured margins covered with masses of dried discharge ; on section the whole thickness of the tumour beneath the ulcer was dry and hard, the rest being composed of cheesy caseous substance. The muscles attached to the tumour were beset with miliary caseous tubercles.

Left Prescapular Gland.—The left prescapular gland measured 7·4 by 4·8 by 2 cm., and was composed almost throughout of dense yellowish caseous substance slightly gritty from calcification ; the less affected parts of the gland were beset with caseous tubercles.

Right Prescapular Gland.—The right prescapular gland measured 2·8 by 1·5 by 0·7 cm. and showed on section four softened caseous tubercles, each about the size of a millet seed.

Prepectoral Glands.—Normal.

Thorax.

Pleura.—Normal.

Lungs.—The lungs did not collapse ; they were heavy and weighed 2 lbs. 13 ozs. ; the tissue felt firm, and there was very little crepitant lung tissue, the parenchyma showing a diffuse grey consolidation ; they showed under the pleura numerous yellow nodules ranging in size from a millet seed to that of a pea, the majority being the size of a millet seed ; on the surfaces of the ventral parts of the lung were several flat grey growths most of which appeared to have developed over nodules in the parenchyma ; on

section of the lung the substance was found to be closely beset with yellow caseous and softened nodules similar to those seen on the surface; in the caudal lobes there were many small smooth-walled cavities containing varying amounts of caseo-pus.

Thoracic Glands.—The dorsal mediastinal and bronchial glands were much enlarged, the long mediastinal measuring 15 cm. in length; on section their substance was congested and showed in the cortex yellow caseous gritty tubercles and small irregular patches formed by aggregated tubercles; they were evenly distributed throughout the cortices but were not very numerous.

Heart.—Normal.

Abdomen.

Omentum and Peritoneum.—Normal.

Spleen.—The spleen was slightly enlarged; the pulp was very soft and showed on longitudinal section six miliary caseo-calcareous tubercles; eighteen tubercles were counted altogether.

Liver.—The liver was pale; no tubercles were seen on the surface or on section.

Portal Glands.—The portal glands were not enlarged, but contained sparsely scattered caseo-calcareous pinhead-sized tubercles.

Kidneys.—Normal.

Suprarenal Bodies.—Normal.

Renal, Lumbar, and Iliac Glands.—Normal.

Alimentary Tract.

Tongue, Pharynx, and Tonsils.—Normal.

Retro-Pharyngeal, Submaxillary, and Parotideal Glands.—Normal.

Intestines.—Normal.

Mesenteric Glands.—Four were affected, each containing scattered caseous tubercles.

Ileo-Colic Glands.—These also contained scattered caseous tubercles.

Peripheral Lymphatic Glands.

Axillary, Precrural, Popliteal, Pudic, Gluteal.—Normal.

Mamma.—Normal.

Microscopical Examination.

Emulsion of a piece of Lung containing Caseous Tubercles.—No tubercle bacilli seen.

Emulsion of Bronchial Gland.—One tubercle bacillus seen.

GOAT 67 [Adult Female]. Virus H. 53. "D.H." (*a*).

Subcutaneous inoculation of culture derived from the original material through G.P. 1482

Dose—10·0 milligrammes.

Date of Inoculation—April 1, 1908.

Died—May 30, 1908. [59 days after inoculation.]

Clinical Notes.

About the fourth week after inoculation the goat became ill and weak and showed increased respiration; loss of appetite and emaciation followed. The difficulty of respiration continued and became more marked, and the goat became progressively weaker and more emaciated; death supervened on the 59th day after inoculation.

Temperature.

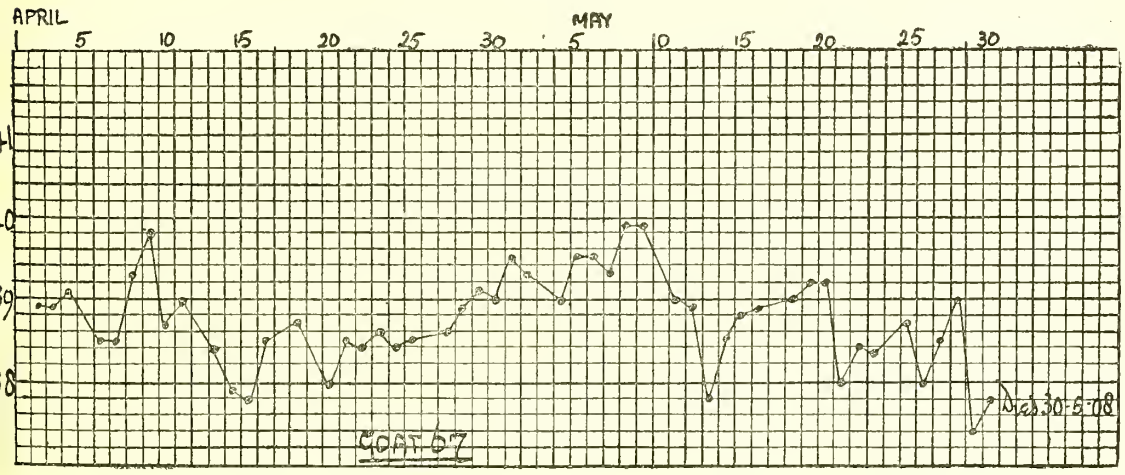

Tuberculin Test.

The goat was not tested subsequent to inoculation.

Weights.

	qrs.	lbs.
April 1, 1908	2	10
May 30, 1908	1	15

Total loss of weight.—23 lbs.

Average rate of loss per week.—2·7 lbs.

POST-MORTEM EXAMINATION.

The carcass was emaciated.

Local Lesion.—At the seat of inoculation on the left side of the neck there was a collapsed cyst measuring 5·5 by 8 cm. in area, the skin over which showed a small opening covered with a dry crust. On section the cyst contained a small quantity of yellow pus; its walls were thin and lined internally with granulation tissue.

Left Prescapular Gland.—The left prescapular

gland measured 5·5 by 2·7 by 2 cm. and was composed practically throughout of dense congested caseous substance slightly gritty from calcification.

Prepectoral, Cervical, and Axillary Glands.—Normal.

Thorax.

Pleura.—Normal.

Lungs.—The lungs did not collapse and were very heavy. The posterior and dorsal portions of the caudal lobes (about one-third of each) were solid. The remaining portions of the lungs were crepitant but congested, and closely beset with irregular grey miliary tubercles with calcareous centres. The solid portions showed on section soft yellow caseous areas varying in size up to about 8 mm., each surrounded by a thin fibrous capsule and separated from other areas by a small amount of translucent grey tissue; in several of the caseous areas there was a cavity and these communicated with bronchi.

Thoracic Glands.—The bronchial and mediastinal glands were enlarged and oedematous; on section the substance resembled ordinary (hypertrophied) glandular tissue, but contained here and there irregular calcareous streaks, forming a network, and calcareous foci.

Heart.—On the mitral and tricuspid valves there were some vegetations. In the left ventricle there was a firm mass of old clot entirely decolorised.

Abdomen.

Omentum and Peritoneum.—Normal.

Spleen.—The spleen was slightly enlarged, rather soft and full of blood; the pulp contained scattered greyish tubercles, the largest the size of a millet seed, each with a minute opaque calcareous centre.

Liver.—The liver was pale and firm; it showed no tubercles either on the surface or on section.

Portal Glands.—Normal.

Kidneys.—In the cortex of each kidney there were some pale areas, the tubules in which contained yellow granular substance; there were no tubercles.

Suprarenal Bodies.—The suprarenal bodies were pale and apparently enlarged, but showed no definite tubercles.

Renal, Lumbar, and Iliac Glands.—Normal.

Alimentary Tract.

Tongue, Pharynx, and Tonsils.—Normal.

Retro-pharyngeal, Parotideal, and Submaxillary Glands.—Normal.

Intestines.—Normal.

Mesenteric Glands.—The mesenteric glands contained sparsely scattered calcareous foci.

Various Lymphatic Glands.

Precrural, Popliteal, Gluteal, Ischiatic, Pudic.—Normal.

Mammary Gland.—Normal.

Microscopical Examinations.

Caseous Material from Lung Cavity.—Very numerous tubercle bacilli.

Tubercle from Spleen.—One tubercle bacillus seen.

Smear from Liver.—No tubercle bacilli.

Smear from Popliteal Gland.—No tubercle bacilli.

Smear from Heart Valve.—A few tubercle bacilli seen.

Mammary Fluid.—No tubercle bacilli.

RHESUS MONKEY 93. Virus H 53. "D.H." (*a*).

(Young animal.)

Subcutaneous inoculation of culture derived from the original material through G.P. 1482.

Dose—1·0 milligramme.

Date of Inoculation—February 25, 1907.

Died—June 10, 1907. [105 days after inoculation.]

Clinical Notes.

A soft fluctuating tumour developed at the seat of inoculation between the shoulders; on the 23rd day it was the size of a pigeon's egg. The axillary glands were then not obviously enlarged.

On the 26th day the tumour opened and discharged its purulent contents.

On the 73rd day the respiration was noticed to be very slightly increased in frequency. The monkey had not grown since inoculation, and now began to look unwell, remaining quietly in a corner of its cage with bowed head. The breathing became laboured, but no further increase in frequency was noticed. The monkey lost its appetite, became very thin, and died on the 105th day.

Temperature.

During the first seven weeks after inoculation the temperature remained approximately normal (maximum 39·7° C.). During the following four weeks the temperature was irregular and a little raised (maximum 40·1 C., minimum 38·4° C.). The temperature then suddenly fell to 37·3° C., and was subnormal and irregular during the remaining fortnight, at the close of which death took place.

Tuberculin Test.

The monkey was not tested subsequent to inoculation.

Weight.

At death—1600 grammes.

POST-MORTEM EXAMINATION.

Local Lesion.—At the seat of inoculation between the scapulæ there was a collapsed cyst, with a fibrous wall lined internally with granulation tissue covered with caseo-pus; the cyst communicated externally through a small irregular ulcer in the skin, which was covered with dried discharge. In the tissues beneath and around the cyst were scattered yellow caseous nodules up to a pea in size.

Axillary Glands.—In the right axillary region there was a caseous and softened gland the size of a broad bean to which the skin was adherent and on the point of breaking down.

A small gland near it contained a pinhead-sized caseous tubercle; the remaining glands were enlarged, deeply congested, and showed no caseation.

On the left side there was a gland the size of a broad bean, with thin walls and caseo-purulent

contents; this gland was not adherent to the skin. Other glands in this group were slightly enlarged, deeply congested, but not caseous.

Vertebral Glands.—In the ninth interspace on the right side there was a gland the size of a split pea which was caseous and softened almost throughout; on the left side there was a continuous chain of small caseous glands extending from the fourth to the tenth interspace.

Inguinal Glands.—One of the left inguinal glands contained a softened caseous tubercle.

The right inguinal glands were normal.

Thorax.

The pleural cavities contained a slight excess of fluid.

Pleura.—There were no tubercles on the pleura, costal or diaphragmatic.

Under the pleura on the right side in the seventh interspace about half an inch from the vertebral column there was a prominent raised caseous and softened nodule.

Lungs.—The left cephalic lobe was slightly adherent at one point to the costal pleura.

Around the root of each caudal lobe were some irregular patches of collapse and the small middle lobes on each side were partially collapsed and airless; with these exceptions the lungs were normally crepitant. The right middle lobe contained a pea-sized softened caseous nodule with a fibrous wall. In the left cephalic lobe there were two or three small grey fibrous tubercles, and in the left caudal lobe were two or three up to a millet seed in size.

Bronchial Glands.—The bronchial glands were slightly enlarged, deeply congested, but not caseous.

Ventral Mediastinal Glands.—Just within the anterior opening of the thorax, and almost completely filling it, were two large glands, each about the size of a thrush's egg, which were yellow caseous and softened throughout; these glands must have caused considerable interference to respiration and deglutition.

Heart and Pericardium.—Normal.

Abdomen.

Omentum.—The omentum showed one millet-seed sized caseous tubercle with a grey margin.

Peritoneum.—Normal.

Spleen.—The spleen was not enlarged and appeared normal on the surface and on section.

Liver.—The liver was pale; it showed on the surface under the capsule two translucent grey tubercles, the largest, slightly opaque in the centre being about a millimetre in diameter. No tubercles were seen on section.

Portal Glands.—Normal.

Kidneys.—The kidneys were pale; on the surface of the right there was a greyish pinhead-sized focus of doubtful nature with a congested margin; otherwise the kidney was normal.

The left kidney showed no tubercles on the surface, but in the depth of the cortex one pinhead-sized caseous tubercle was seen.

Suprarenal Bodies.—Normal.

Iliac Glands.—Normal.

Lumbar Glands.—The lumbar glands were enlarged, deeply congested but not caseous.

Pancreatic Gland.—On the anterior margin of the pancreas there was a pea-sized softened and caseous gland.

A slightly enlarged gland in the gastro-splenic omentum contained a caseo-purulent nodule the size of a hemp seed.

Alimentary Tract.

Tongue, Pharynx, and Tonsils.—Normal.

Retro-pharyngeal Glands.—These glands were enlarged to the size of peas; one was caseous and softened throughout; the other was partly caseous.

Other glands in the neck appeared normal.

Gastric Glands.—One near the pylorus along the great curvature contained two miliary caseous tubercles.

Other gastric glands appeared normal

Small Intestines.—In the ileum there was a small transverse ulcer with congested margins and slightly thickened base.

Mesenteric Glands.—Three of the mesenteric glands were enlarged, two being nearly 1·5 cm. in greatest diameter, the other about the size of a small pea. The two larger ones were yellow and filled with creamy caseo-pus; the smaller one was partly caseous and softened.

Other mesenteric glands, the ileo-colic, and colic glands were normal.

Brain.—Normal.

Microscopical Examinations.

Sternal Gland (scraping from).—Tubercle bacilli moderately numerous.

Mesenteric Gland (scraping from).—Tubercle bacilli numerous.

RHESUS MONKEY 101. Virus H. 53. "D.H." (*a*).

(A young animal.)

Subcutaneous inoculation of culture derived from the original material through Guinea-pig 1482.

Dose—1·0 milligramme.

Date of Inoculation—May 30, 1907.

Died—July 11, 1907. [42 days after inoculation.]

Clinical Notes.

A fluctuating tumour developed at the seat of inoculation between the shoulders. This burst and discharged pus on June 18. On June 29 it was still discharging pus, and appeared as a raised disc-like swelling, 4 by 3 cm., with a central opening. The glands in both axillæ were slightly enlarged.

On July 11 the monkey died. A few days before death it was found that its collar though quite loose had produced numerous ulcers in the skin of the neck which had become septic. It is probable that this condition was the immediate cause of the death of the animal.

The monkey had always looked somewhat depressed,

crouching quietly in a corner of a cage with head bent ; it gradually became more seedy-looking, and towards the end lost appetite. The respiration was at no time increased in frequency.

Temperature.

The temperature was raised and irregular during almost the whole period of the experiment, the range of variation being 1·8° C. (maximum 40·4° C., minimum 38·6° C.). During the last week of life the temperature fell rapidly from 39·4° C. to below 35·0° C.

Weight.

At death—1510 grammes.

POST-MORTEM EXAMINATION.

Carcass in fair condition.

Local Lesion.—At the seat of inoculation between the scapulæ there was a raised flattened disc-like tumour 3·5 cm. in diameter, the skin over the centre of which showed a small ulcer discharging ill-formed pus. On section the tumour was 1·2 cm. in greatest thickness, and was composed of firm yellow caseo-necrotic substance breaking down just beneath the skin.

The skin around the back and left side of the neck was thickened and showed a number of ulcers discharging pus (caused by the collar).

Axillary Glands.—One on the right side was enlarged and contained a soft yellow caseous nodule the size of a large pea.

On the left side a slightly enlarged gland contained two softened caseous nodules, one 5 the other 2 mm. in diameter. Other axillary glands were normal.

Cervical Glands.—On the right side a gland behind the clavicle contained a millet-seed sized caseous tubercle.

Another was enlarged but not caseous.

On the left side a gland behind the clavicle contained a pea-sized caseous nodule.

A few others were slightly enlarged but not caseous.

Other cervical glands and other glands in the neck were normal.

Vertebral Gland.—A vertebral gland in the 10th interspace was slightly enlarged and contained one caseous focus.

Thorax.

Lungs.—The lungs were normal in general appearance ; in each caudal lobe, just under the pleura, there was a greyish tubercle about 2 mm. in diameter with a greyish white centre.

In the right caudal lobe there was besides a pin-head-sized grey tubercle.

In the left cephalic and in the right middle lobe there was a small greyish red nodule without central caseation.

Bronchial Glands.—The bronchial glands were not enlarged. Each contained one or two caseous foci 0·5 mm. in diameter.

Abdomen.

Spleen.—The spleen, not enlarged, showed on section scattered miliary tubercles some with minute yellow centres, others distinctly caseous and softened in the centre.

Liver.—The liver appeared normal.

Portal Gland.—The portal gland showed in the cortex scattered caseous tubercles, the largest the size of a millet seed.

Pancreatic Gland.—There were a few caseous foci in a pancreatic gland.

Kidneys.—The right showed near the surface of the cortex a minute greyish-white tubercle. The left was normal.

All the other glands and organs were examined and found normal.

Microscopical Examination.

(Smears from)

Spleen (tubercle)	Tubercle bacilli numerous.
Right Axillary Gland (caseous nodule)	

Lung (tubercle).—Tubercle bacilli scanty.

RHESUS MONKEY 103. Virus H. 53. "D.H." (*a*).

(A young animal.)

Subcutaneous inoculation of culture derived from the original material, through Guinea-pig 1482.

Dose—10·0 milligrammes.

Date of Inoculation—May 30, 1907.

Died—June 22, 1907. [23 days after inoculation.]

Clinical Notes.

The monkey became weak and ill-looking at the beginning of the third week after inoculation, and lost appetite ; death ensued on the 23rd day. There was no increase in respiration during the illness.

Temperature.

On the day after the inoculation the temperature rose to 40·0° C. ; during the following week it was between 39·0 and 40·0° C. ; it then fell gradually until the 19th day, when 38·2° C. was recorded. The temperature then fell rapidly to 35·0° C. and death ensued.

Weight.

At death—1400 grammes.

POST-MORTEM EXAMINATION.

Carcass in poor condition.

Local Lesion.—In the subcutaneous tissues over the right scapula there was a flattened slightly raised tumour measuring 3 by 3 by 1 cm., composed of firm yellow caseous substance breaking down in the central parts. The skin was adherent but not ulcerated.

Axillary Glands.—The right axillary gland was slightly enlarged and contained three whitish friable caseous nodules, the largest 3 mm. in greatest diameter.

The left axillary gland was normal.

Cervical Glands.—Behind the right clavicle there was a group of glands ; one the size of a hemp seed, another that of a millet seed, were caseous throughout. Two other very slightly enlarged glands showed early caseation affecting part of the cortex only. Other cervical glands were normal.

Vertebral Glands.—One gland in the seventh interspace was slightly enlarged, and showed early caseation of the cortex.

Thorax.

Lungs.—The lungs were pink and crepitant and with the exception of two small cysts containing the *pneumonyssus griffithi* were perfectly healthy.

Abdomen.

Liver.—The liver showed a few minute grey points of a doubtful nature.

All the remaining organs and glands were examined and found normal.

Microscopical Examination.

Right Axillary Gland.—Tubercle bacilli extremely numerous.

Scraping from Spleen.—A few tubercle bacilli seen.

Scraping from Liver.—Tubercle bacilli fairly numerous.

RHESUS MONKEY 109. Virus H. 53. "D.H." (*a*).

(A young animal.)

Subcutaneous inoculation of culture derived from the original material through G.P. 1482.

Dose—10·0 milligrammes.

Date of Inoculation—August 23, 1907.

Killed when moribund—September 24, 1907. [32 days after inoculation.]

Clinical Notes.

A soft and fluctuating tumour developed at the seat of inoculation which opened and discharged caseo-purulent matter on September 6, 14 days after inoculation.

A short time after inoculation the monkey became depressed and unwell, and lost its appetite; it became progressively worse and was dying on September 24.

Temperature.

For 11 days the temperature was approximately normal; it then rose, reaching a maximum of 40·6° C. on the 14th day. It was irregular from the 15th to the 27th day (maximum 39·8° C., minimum 38·3° C.). From the 28th to the 31st day the temperature fell rapidly (to 35° C.). On the 32nd day the monkey was dying, and was therefore killed.

Weight.

At death—1400 grammes.

POST-MORTEM EXAMINATION.

Local Lesion.—The skin over the lower part of the right scapula showed a shallow ulcer 6 by 2 cm. in area with undermined margins and fibroid base covered with a thin layer of caseo-pus.

Under the skin around the anterior end of the ulcer caseous substance extended for some distance in the subcutaneous tissue.

Vertebral Glands.—On the right side of the vertebral column, in the 7th to the 10th interspaces, there was a chain of large caseous and softened glands, the largest being about 1· cm. in greatest diameter.

Axillary Glands.—In the right axilla there was a group of enlarged softened and caseous glands forming a mass measuring 4 by 2 by 1 cm. The glands on the left side appeared normal.

Cervical Glands.—Behind the middle of the right clavicle there was a group of three caseous and softened glands, the largest the size of a pea.

One in the middle of the neck showed a minute caseous focus.

Another under the origin of the sterno-mastoid was enlarged but not caseous.

All the glands on the left side appeared normal.

Other glands in the neck were normal.

Thorax.

Pleura.—Normal.

Lungs.—The right middle lobe was collapsed and quite airless and of a dark red colour.

The ventral portion of the left cephalic lobe was in a similar condition, otherwise the lungs were pink and crepitant. They contained very sparsely scattered opaque whitish tubercles, the largest 1· mm. in diameter.

Bronchial Glands.—One intertracheo - bronchial gland contained a pinhead-sized caseous tubercle, another a very minute opaque point. The rest were normal.

Heart.—Normal.

Abdomen.

Peritoneum.—Normal.

Liver.—The liver was pale and contained fairly numerous opaque whitish tubercles, the largest the size of a pin's head.

Spleen.—The spleen was slightly enlarged and closely beset with tubercles, caseous and softened at the centre, varying in size up to that of a millet seed.

Kidneys.—Each kidney showed on the surface three or four greyish opaque tubercles, the largest the size of a pin s head; a few similar tubercles were seen in the depth.

Various Abdominal Glands.—A gland in the small omentum near the pylorus was enlarged and closely beset in the cortex with softened caseous nodules.

The portal gland was similarly affected.

A gland lying on the head of the pancreas was partly caseous and softened.

The mesenteric, ileo-colic and colic glands were normal.

Two of the lumbar glands and one iliac gland contained each a miliary caseous tubercle.

Intestines.—Normal.

Brain.—Normal.

Submaxillary Glands.—The right submaxillary gland contained a miliary caseous tubercle. The left was normal.

RHESUS MONKEY 111. Virus H. 53. "D.H." (*a*).

(A young animal.)

Subcutaneous inoculation of culture derived from the original material through Guinea-pig 1482.

Dose—1·0 milligramme.

Date of Inoculation—August 23, 1907.

Died—October 3, 1907. [41 days after inoculation.]

Clinical Notes.

A small fluctuating tumour developed at the seat of inoculation over the angle of the right scapula, which opened on the 24th day and discharged caseo-purulent matter. The right axillary glands became enlarged.

The illness of the monkey was similar to that of its fellow No. 109. It died on October 3 (41 days).

Temperature.

The temperature was a little raised (39·9° C.) during the first six days; it then fell to 38·8° C., and afterwards slowly rose, reaching a maximum of 40·7° C. on the 18th day. From the 19th to the 32nd day there was a gradual fall to 38·2° C. During the following four days the temperature rose one degree; it then fell rapidly to below 35·0° C. (over 4 degrees Centigrade in 4 days), and the monkey died.

Weight.

At death—1350 grammes.

POST-MORTEM EXAMINATION.

Local Lesion.—Over the angle of the right scapula there was a raised flattened tumour oval in outline measuring 4 by 3 by 1 cm.; on section it was composed of yellow caseous substance breaking down in the centre and infiltrating the superficial muscles. The skin was adherent all over; it was thin bluish and showed near the posterior margin a small opening discharging caseo-pus.

Axillary Glands.—In the right axilla there were two moderately large glands the largest 1·7 cm. in length, caseous and softened throughout, a pea-sized gland partly caseous, a small gland with a caseous tubercle, and two or three normal glands.

The axillary glands on the left side appeared normal.

Cervical Glands.—Behind the middle of the clavicle on the right side there were three pea-sized softened and caseous glands.

Behind the sternal end of the clavicle on this side there was a small gland containing a caseous tubercle.

On the left side about the middle of the clavicle there was one pea-sized softened and caseous gland. Other cervical glands were normal.

Vertebral Glands.—In each of the 6th, 7th, and 8th interspaces, near the vertebral column, there was a caseous and softened gland, the largest of which was the size of a split pea.

Thorax.

Pleura.—Normal.

Lungs.—The lungs were expanded and crepitant throughout; they contained altogether about half a dozen grey miliary tubercles slightly opaque in the centre.

Bronchial Glands.—There was a minute whitish point in one bronchial gland. The others appeared normal.

Heart.—Normal.

Abdomen.

Omentum and Peritoneum.—Normal

Spleen.—The spleen was not apparently enlarged, but was closely beset with soft caseous miliary tubercles.

Splenic Glands.—One gland in the gastro-splenic omentum contained a small caseous tubercle, the others were normal.

Liver.—The liver showed very sparsely scattered greyish translucent tubercles ranging up to 0·5 mm. or rather more in diameter.

Portal Glands.—A portal gland showed in the cortex two or three minute caseous foci.

Other abdominal lymphatic glands appeared normal.

Kidneys.—Each kidney showed in the cortex two small grey tubercles with opaque caseous centres.

Intestines.—Normal.

Tongue, Pharynx, Tonsils.—Normal.

Pharyngeal Glands.—Normal.

Microscopical Examination.

Spleen, Tubercle from.—Tubercle bacilli very numerous.

Liver, Tubercle from.—A few tubercle bacilli seen.

Marrow from the Femur.—No tubercle bacilli.

RHESUS MONKEY 113. Virus H. 53. "D.H." (*a*).

(A young animal.)

Fed with culture derived from the original material through Guinea-pig 1482.

Dose—10·0 milligrammes.

Date of Inoculation—August 23, 1907.

Died—September 12, 1907. [20 days after feeding.]

Clinical Notes.

When fed on August 23 this monkey was noticed to have oedema of the eyelids, face, and neck; otherwise it appeared to be healthy.

On the following day the animal appeared to be unwell; it gradually grew worse and died on the 20th day.

Temperature.

The temperature rose to 39·6° C. on the 4th day, and then fell, slowly at first, rapidly later, reaching 37·7° C. on the 16th day and 36·0° C. on the 19th day; on the following day the animal was dead.

Weight.

At death—1280 grammes.

POST-MORTEM EXAMINATION.

The carcass was thin.

In the medulla of each suprarenal body there was a small irregular chalky nodule, the largest about half the size of a barley grain ; other organs and all lymphatic glands were normal, and there was no naked-eye evidence of tuberculosis anywhere in the body. Nothing was found to account for the death of the animal.

Microscopical Examination.

Nodule from Suprarenal Body.—No tubercle bacilli.

RHESUS MONKEY 115. Virus H. 53. "D.H." (*a*).

(A young animal.)

Fed with culture derived from the original material through Guinea-pig 1482.

Dose—1·0 milligramme.

Date of Inoculation—August 23, 1907.

Died—September 14, 1907. [22 days after feeding.]

Clinical Notes.

The monkey appeared to be quite well when fed on August 23, but a few days later it was unwell, and its appetite was poor. The animal gradually grew worse, and died on September 14.

Temperature.

The temperature curve was very similar to that of Monkey 113. The temperature rose to 39·2° C. on the 4th day, and then fell, slowly at first, more rapidly later, reaching 37·7° C. on the 20th day, and 36·3° C. on the 21st day ; the following day the animal was dead.

Weight.

At death—1700 grammes.

POST-MORTEM EXAMINATION.

The body was thin.

All the organs and glands were perfectly normal in appearance and nothing was found to account for the death of the animal.

RHESUS MONKEY 129. Virus H. 53. "D.H." (*a*).

(A young animal.)

Subcutaneous inoculation of culture derived from the original material through Guinea-pig 1482.

Dose—0·01 milligramme.

Date of Inoculation—February 6, 1908.

Died—March 28, 1908. [51 days after inoculation.]

Clinical Notes.

The monkey was first noticed to be ill about ten days before death ; it lost its appetite and became weak and thin. The respiration was normal. Weakness and emaciation continued, and the monkey died during the evening of March 28.

Temperature.

The temperature remained approximately normal until a few days before death ; it then fell rapidly ; 36·6° C. was recorded on March 27, and on the morning of March 28 the temperature was below 35·0° C., and could not be recorded by the clinical thermometer.

Weight.

At death—2160 grammes.

POST-MORTEM EXAMINATION.

The carcass was emaciated.

Local Lesion.—In the subcutaneous tissues near the posterior angle of the right scapula there was a hemispherical breaking-down caseous tumour 1·5 cm. in diameter ; the skin over it was thinned and bluish, and showed two openings discharging thin pus.

Left Axillary Glands.—The left axillary glands were not enlarged, and there was no sign of caseation in any of them.

There was no sign of tuberculosis elsewhere in the body. The lungs, liver, spleen, kidneys, and intestines were perfectly normal to the naked eye, and there was absolutely nothing to account for the death of the animal.

RHESUS MONKEY 135. Virus H. 53. "D.H." (*a*).

(A young animal.)

Subcutaneous inoculation of culture derived from the original material through Guinea-pig 1482.

Dose—0·1 milligramme.

Date of Inoculation—February 6, 1908.

Killed when very ill—September 2, 1908. [209 days after inoculation.]

Clinical Notes.

The monkey remained in fairly good health until the end of July. During August the temperature fell gradually and steadily (from 39·5 to below 35·0° C.) and the monkey lost appetite, became thin, weak, and ill looking. On September 2 the monkey was extremely weak, and for three days no temperature had been recorded by the clinical thermometer; it was therefore killed. The weight at death was 1670 grammes.

Temperature.

From the commencement of the experiment to the middle of April the temperature was approximately normal, but a slight tendency upward was noticed during this period. During May the temperature continued to rise gradually, and a maximum of 40·4° C. was reached on June 3. From this time until the end of July the temperature approximated to 39·0° C., varying within narrow limits. During August the temperature fell steadily to 35·0° C.

POST-MORTEM EXAMINATION.

The carcass was emaciated.

Local Lesion.—Over the right scapula in the subcutaneous tissues there was a caseous mass measuring 1·5 by 1 by 0·5 cm., the skin over which was normal; extending backwards and outwards from this there was a thin red scar in the skin under which were three small caseous nodules.

Axillary Glands.—On the right side there was a chain of glands extending from the level of the nipple into the axilla; two of those near the nipple and one in the axilla were much enlarged measuring from 1·5 to 2 cm. in diameter and were yellow caseous and softened throughout; one of the former was adherent to the skin, which was reddened and thinned but had not broken down; the other glands showed no sign of caseation but two were large and oedematous.

The glands on the left side were normal.

Cervical Glands.—Normal.

Vertebral Glands.—Projecting from the dorsal wall of the thorax on the right side, extending between the seventh and eleventh ribs antero-posteriorly, and the left margins of the bodies of the vertebræ and the angle of the ribs laterally, was a large yellowish mass measuring 4 by 2·5 by 1 cm.; this on section was found to be composed of a number of caseous and softened glands which had become fused together. On the left side there was one small caseous gland.

Thorax.

Lungs.—The right caudal lobe was firmly adherent along its dorsal border to the mass of enlarged vertebral glands. The left lung was slightly adherent to the chest wall along its dorsal border.

The lungs were expanded and emphysematous and crepitant-looking, except for some dark pigmented solid patches, one in the left caudal lobe near its root, the others on the surface of the right lung; they showed under the pleura moderately numerous dark grey irregular tubercles ranging in size up to a millet seed, the majority were homogeneous but several had caseous centres.

On section the lungs internally were rather more severely affected than the inspection of the surface had led me to expect; the tissue of the left caudal lobe internally was closely beset with grey miliary tubercles, only the marginal parts being crepitant; in the central parts the tubercles were confluent and the majority were without central caseation; here and there were some rather larger caseous tubercles; the right caudal lobe contained similar tubercles but not so numerous.

In the small anterior lobes besides tubercles there were many irregular caseous nodules and caseous areas; in the left anterior lobe the latter appeared to be the result of direct extension from one of the caseous bronchial glands which was almost completely embedded in the lung substance.

Thoracic Glands.—The glands around the bronchi and thoracic trachea were greatly enlarged ranging in size from a large pea to a thrush's egg; there were fourteen altogether, two of the largest being situated one each side at the entrance to the thorax between the manubrium sterni and trachea; all the glands were yellow caseous and softened throughout.

Pleura.—The pleura was normal except in the neighbourhood of the enlarged vertebral glands and where the dorsal border of the left lung was adherent to it.

Heart.—Normal.

Abdomen.

Omentum.—The omentum contained two caseous nodules, one rather larger than a millet seed the other the size of a small pea.

Parietal Peritoneum.—Normal.

Spleen.—The spleen was smaller than normal and contained one yellow caseous tubercle about 1·5 mm. in diameter.

Liver.—Normal.

The gland on the head of the pancreas contained a caseous and softened nodule the size of a large pea.

Kidneys.—On the surface of the left kidney three or four small grey foci were seen.

The right kidney showed on the surface about a dozen grey translucent tubercles ranging up to 1· mm. in diameter, two of the larger ones having slightly opaque centres; one tubercle was seen in the depth.

Suprarenal Bodies.—Normal.

Alimentary Tract.

Tongue, Pharynx, Tonsils—Normal.

Retro-pharyngeal Glands.—Normal.

Submaxillary Glands.—The one on the left side was a centimetre in diameter, and was yellow caseous and softened throughout.

The right was normal.

Intestines.—Two coils of the small intestine were adherent together and to the descending colon; when torn asunder the adherent surfaces were found to be covered with yellow fibrino-pus.

The mucous membrane of the small intestine showed four transverse tuberculous ulcers with thickened bases and caseous margins; the base of one of these was adherent to another coil of the small intestine, and also to the large intestine.

The large intestine was normal.

Gastric Glands.—One in the great omentum near the pylorus contained a small pea-sized caseous nodule; one in the lesser curvature contained a caseous tubercle 2 mm. in diameter.

Mesenteric Glands.—Two the size of large peas were caseous and softened throughout, another contained a few small caseous tubercles.

Ileo-Colic Glands.—On one side there was a caseous and softened gland the size of a pea. On the other there was a similar gland which was closely adherent to the wall of the intestine.

Colic Glands.—Four were affected containing caseous nodules varying in size from a millet seed to that of a pea.

In the subcutaneous tissues of the abdominal wall near the umbilicus, there was a millet-seed sized caseous tubercle.

Inguinal Glands.—Normal.

Brain.—Normal.

Microscopical Examination.

Emulsion of Spleen Tubercle.—A few tubercle bacilli.

RHESUS MONKEY 137. Virus H. 53. "D.H." (*a*).

(A young animal.)

Subcutaneous inoculation of culture derived from the original material through Guinea-pig 1482.

Dose—1·0 milligramme.

Date of Inoculation—February 6, 1908.

Killed when very ill—May 8, 1908. [92 days after inoculation.]

Clinical Notes.

The animal was first noticed to be unwell three weeks before it was killed, and it got gradually worse every day. It showed weakness, loss of appetite, and emaciation, but the respiration was not accelerated. When killed on May 8 it was very ill, and the temperature was subnormal—below 35·0° C

Temperature.

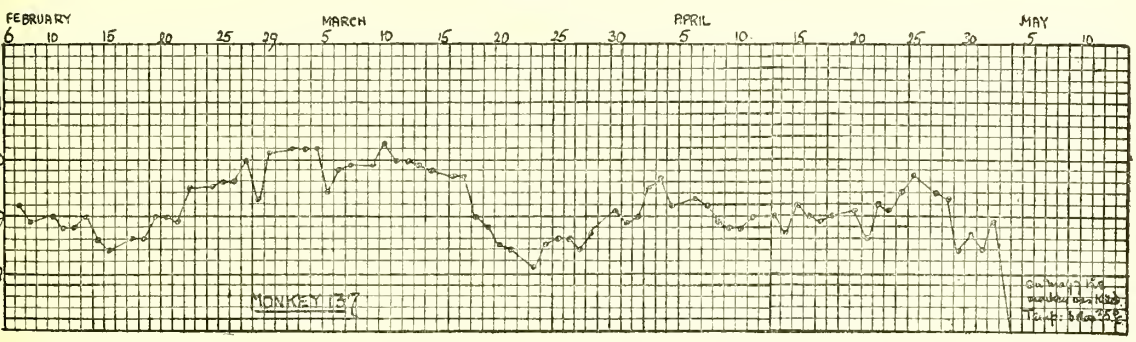

Weight.

At death—2300 grammes.

POST-MORTEM EXAMINATION.

The carcass was very thin.

Local Lesion.—On the right side just posterior to the angle of the scapula there was a flat swelling measuring 6 by 4 by 0·9 cm. The skin over it was adherent, and showed small dry ulcers.

On section the tumour was composed of yellow caseous areas, some softened, surrounded by translucent fibroid tissue.

Axillary Glands.—On the right side one, 1·5 cm. in diameter, was caseous and softened throughout. Three smaller ones showed the substance almost completely replaced by softened caseous nodules, and in another enlarged congested gland there was a softened caseous tubercle.

The glands on the left side were slightly enlarged oedematous and congested, but showed no sign of caseation.

Cervical Glands.—A cervical gland behind the right clavicle contained a miliary caseous tubercle.

There were no tubercles in the other cervical glands.

Vertebral Glands.—On the right side, extending backwards from the 7th interspace, there was a chain of four enlarged glands, the largest 1·5 cm. in diameter, which were caseous and softened throughout.

On the left side there were three glands not so large though caseous and softened throughout.

Thorax.

Lungs.—The lungs were crepitant and adherent to the enlarged vertebral glands, the right caudal lobe along its dorsal border being infiltrated with firm greyish tuberculous tissue. They contained scattered evenly distributed shotty grey nodules varying in diameter from 1 up to nearly 3 mm., small ones being most numerous; the majority were homogeneous, a few showed caseous foci, and here and there a caseous tubercle was seen.

Thoracic Glands.—The praetracheo-bronchial glands were slightly enlarged congested and contained altogether three softened caseous nodules up to 2 mm. in diameter. The intertracheo-bronchial glands showed a greater degree of enlargement and contained more numerous and larger softened caseous nodules.

Heart and Pericardium.—There was an excess of fluid in the pericardial sac.

The heart was flabby, the cavities were dilated and filled with anaemic blood-clot.

Larynx and Trachea.—Normal.

Pleura.—The pleura was normal except in the neighbourhood of the enlarged vertebral glands.

Abdomen.

Omentum and Peritoneum.—The omentum contained four softened caseous tubercles, the largest 2 mm. in diameter; there were two caseous tubercles on the meso-colon. The parietal peritoneum was normal.

Spleen.—The spleen was enlarged, measuring 5 by 3·5 cm. by 1·7 cm. in thickness. On section it contained only a moderate number of softened caseous nodules with grey fibrous margins varying from 1 to 3 mm. in diameter; they were much less numerous than is usual in the more acute cases of tuberculosis. Twenty-four were counted on one cut surface after longitudinal section.

Splenic Lymphatic Glands.—The splenic glands were enlarged and deeply congested; one contained three caseous nodules the largest 2·5 mm. in diameter similar to those in the spleen, another contained a caseous tubercle; the rest were normal.

Liver.—The liver contained five caseous and softened nodules, the largest 2 mm. in diameter, and a grey miliary tubercle with an opaque centre; otherwise the liver was normal.

Portal and Pancreatic Glands.—Three glands, the largest 1·7 cm. in greatest diameter, situated just in front of the pancreas between the latter and the liver, were closely beset with yellow caseous and softened nodules with thin grey capsules, the largest 3 mm. in diameter.

In the groove on the ventral surface of the liver at the bottom of which the suspensory ligament is attached, there were two large pea-sized glands which were closely beset with softened caseous nodules similar to those in the portal gland.

Kidneys.—On the surface of the left kidney half a dozen caseous tubercles ranging from 0·5 to 1 mm. in diameter were seen. There were two caseous tubercles in the depth of the cortex.

There were half a dozen similar caseous tubercles in the cortex of the right kidney.

Suprarenal Bodies.—There was a softened caseous nodule in the cortex of the left suprarenal body; the right was normal.

Lumbar Glands.—One lumbar gland contained a millet-seed sized caseous tubercle.

Alimentary Tract.

Tongue, Tonsils, Pharynx.—Normal.

Submaxillary Glands.—Two submaxillary glands on the right side each contained a softened caseous tubercle 1·5 mm. in diameter.

One of the glands on the left side contained a hemp-seed sized caseous nodule; another contained two pinhead-sized caseous tubercles.

Pharyngeal Glands.—The right pharyngeal gland contained a softened caseous nodule 2 mm. in diameter.

The left was normal.

Small Intestine.—Normal.

Large Intestine.—The mucous membrane of the ascending colon showed some patches of adherent grey congested membrane.

Gastric Glands.—Congested, otherwise normal.

Mesenteric and Ileo-Colic Glands.—The mesenteric and ileo-colic glands were slightly enlarged and congested, but there were no tubercles in them.

Colic Glands.—Four colic glands were enlarged and contained each a caseous nodule, the largest the size of a hemp seed.

Inguinal Glands.—One right inguinal gland contained a pinhead-sized caseous tubercle, and there was a hemp-seed sized caseous nodule in one of the left inguinal glands.

Scattered about in the subcutaneous tissues of the trunk there were half-a-dozen caseous nodules, the largest about 2 mm. in diameter.

In the subcutaneous tissues of the inside of the right thigh there was a millet-seed sized caseous tubercle.

Microscopical Examination.

Nodule from left Suprarenal Body.—Very numerous tubercle bacilli.

Smear from congested membrane of Large Intestine.—No tubercle bacilli.

RHESUS MONKEY 131. Virus H. 53. "D.H." (*a*).

(A young animal.)

Fed once with culture derived from the original material through guinea-pig 1482.

Dose—1·0 milligramme.

Date of Feeding—February 6, 1908.

Killed when in good health—November 26, 1908. [294 days after feeding.]

Clinical Notes.

The monkey remained well during the experiment. The weight at death was 2,400 grammes.

Temperature.

From February to the middle of September the temperature was normal. A period of irregular pyrexia then ensued and lasted until the animal was killed on November 26. The maximum temperature recorded during this period was 40·2° C.; the minimum, 37·5° C.

Tuberculin Test.

November 25, 1908. [293 days after inoculation.] Dose 2·0 cc. No reaction. Rise of temperature, 0·4° C.

POST-MORTEM EXAMINATION.

The carcass was in good condition.

Alimentary Tract.

Tongue, Tonsils, and Pharynx.—Normal.

Submaxillary Glands.—A submaxillary gland on the left side, the size of a pea, was caseous and softened throughout. One on the right side contained a hempseed-sized caseous nodule.

Pharyngeal Glands.—The left pharyngeal gland contained three millet-seed sized caseous tubercles. The right was normal.

Cervical Glands.—A cervical gland in the middle of the neck contained a softened caseous nodule. The rest were normal.

Small Intestine.—The small intestine was perfectly normal.

Large Intestine.—Near the ileo-caecal valve the mucous membrane of the colon showed two small ulcers with smooth fibrous floor and slightly raised thickened margins ; several inches further down there was a group of ulcers of various sizes similar to the above ; two were rather more than 1 cm. in greatest diameter, the rest were small.

Colic Glands.—In the meso-colon at its attachment to the colon and situated near the group of ulcers was a mass the size of a broad bean composed of caseous and softened areas separated by fibrous tissue.

Other colic glands were normal.

Gastric Glands.—One near the cardiac end of the stomach contained a softened caseous nodule, 2 mm. in diameter.

Mesenteric Glands.—Most of the mesenteric glands were slightly enlarged ; some were normal in size and appearance. Two of the affected glands at the anterior part of the mesentery were caseous and softened throughout ; those more posterior were closely beset with caseous and softened nodules up to a pea in size.

Ileo-Colic Glands.—One ileo-colic gland contained one millet seed sized caseous tubercle ; another on the opposite side of the ileum contained two miliary caseous tubercles.

Thorax.

Lungs.—The left cephalic lobe was collapsed and consolidated, and was composed of tough fibroid slightly pigmented tissue containing softened caseous patches and foci. The other lobes were crepitant throughout and contained sparsely scattered shotty tubercles varying from 1·0 to 2 mm. in diameter. These tubercles had caseous centres and fibrous margins.

Bronchial Glands.—The praetracheo-bronchial gland on the left side, and the inter-bronchial, were much enlarged caseous and softened throughout.

The right praetracheo-bronchial gland contained two millet-seed sized caseous tubercles.

Heart Muscle and Valves.—Normal.

There was an excess of fluid in the pericardial sac.

Pleura.—The pleura on the left side near the apex showed two caseous tubercles.

Abdomen.

Omentum and Peritoneum.—The omentum contained about three dozen caseous nodules with fibrous walls, varying in size from a pin's head to a barley grain. No tubercles were seen on the peritoneum.

Spleen.—The spleen was adherent to the parietal wall and showed on the convex surface several small projecting nodules with fibrous walls. It was slightly enlarged, measuring 4·5 by 3 by 1·5 cm., and showed in the pulp a moderate number of discrete softened caseous nodules, irregular in outline, varying from 1 mm. to 3 mm. in diameter. There was also one large softened caseous nodule, nearly a centimetre in diameter.

Splenic Lymphatic Glands.—Three were slightly enlarged ; two contained each one softened caseous nodule, the other a number of caseous tubercles.

Liver. — The liver contained, evenly distributed throughout its substance, a number of thin walled cysts ranging up to a pea in size, filled with greenish muco-purulent substance ; there were also several small greyish-white tubercles and one caseous nodule 2 mm. in diameter.

Two glands on the head of the pancreas each contained scattered miliary caseous tubercles.

Kidneys.—The left kidney showed in the cortex a minute grey tubercle. In that of the right there were two greyish-white tubercles the size of a pin's head, and one the size of a millet-seed, with caseous centre and grey margins.

Suprarenal Bodies.—Normal.

Inguinal and Axillary Glands.—Normal.

Microscopical Examination.

Smear from an Emulsion made from the Spleen.—A few tubercle bacilli.

RHESUS MONKEY 243. Virus H. 53. "D.H." (*a*).

(A young animal.)

Subcutaneous inoculation of culture derived from the spleen of Monkey 135.

Dose—1·0 milligramme.

Date of Inoculation—November 5, 1908.

Died—January 22, 1909. [78 days after inoculation.]

Clinical Notes.

The course of the disease was similar to that usually seen in monkeys suffering from severe generalized tuberculosis.

The weight at death was 1900 grammes.

POST-MORTEM EXAMINATION.

The carcass was emaciated.

Local Lesion.—The skin over the right scapula showed an ulcer 3 cm. in diameter, with irregular undermined margins, and floor covered with caseous substance, dry where exposed to the air ; the muscles beneath the ulcer were thickened and closely beset with caseous nodules.

Extending in the muscles from the base of the ulcer to the axillary glands there was a chain of caseous glands.

Axillary Glands.—In the right axilla there was a group of four caseous and softened glands, the largest 1·5 cm. in greatest diameter.

On the left side, one the size of a pea was caseous almost throughout.

Cervical Glands.—In the posterior triangle on one side there were three, and on the other two, caseous and softened glands, the largest 1·5 cm. in diameter.

Behind the sterno-clavicular joint there was a pea-sized caseous gland.

In the middle of the neck on each side there was a small caseous gland.

Vertebral Glands.—Extending from the 7th to the 10th interspaces on the right side there was a chain of enlarged softened and caseous glands.

Thorax.

Pleura.—There were a few tubercles on the dorsal mediastinal pleura, and two on the parietal pleura.

Lungs.—The lungs were crepitant and showed patches of congestion ; they contained moderately numerous evenly distributed shotty caseous nodules varying from 1 to nearly 3 mm. in diameter.

Bronchial Glands. — The bronchial glands were slightly enlarged and contained discrete and softened caseous nodules the largest 5 mm. in diameter.

Heart and Pericardium.—Normal.

Abdomen.

The peritoneal cavity contained a slight excess of clear serous fluid.

Omentum.—The omentum was very closely beset with caseous nodules ranging from 1 or rather less to 2·5 mm. in diameter; the nodules were in places aggregated together especially in the neighbourhood of the spleen and along the free border. The omentum was adherent to the meso-colon, to the spleen, and slightly to the parietal peritoneum near the spleen; it completely surrounded the spleen and when removed from it caused the rupture of many of the projecting splenic nodules.

The *Meso-colon* showed numerous caseous nodules ranging in size up to that of a hempseed.

On the *Mesentery* there were scattered caseous tubercles, and there were caseous tubercles on the parietal peritoneum.

Spleen.—The spleen was greatly enlarged, measuring 7 by 4·5 by 2·5 cm., and was packed as closely as possible with softened yellow caseous nodules, the largest 5 mm. in diameter.

Some small glands in the hilum of the spleen contained each one or two caseous nodules.

Liver.—The liver showed on the surface under the capsule as well as in the depth a moderate number of caseous tubercles varying in diameter up to 2 mm.

Between the head of the pancreas and the hilum of the liver there were three enlarged glands which were composed practically throughout of softened caseous confluent nodules.

Kidneys.—Each kidney showed in the cortex scattered caseous tubercles the largest 2 mm. in diameter.

Suprarenal Bodies.—The right suprarenal body contained about half-a-dozen softened caseous nodules up to 3 mm. in diameter; there was about the same number of similar nodules in the left suprarenal.

Lumbar Glands.—One the size of a pea was caseous practically throughout.

Alimentary Tract.

Tongue.—At the base of the tongue near the right tonsil there was a submucous caseous tubercle.

Pharynx.—Normal.

Submaxillary and Pharyngeal Glands. — These glands contained caseous nodules.

Small Intestines.—The mucous membrane of the small intestine showed throughout its whole length numerous raised caseous nodules, the largest 2 to 3 mm. in diameter, the majority of which were ulcerated; there were also two tuberculous ulcers with thickened margins, the largest 1 cm. in diameter.

Large Intestine.—The mucous membrane of the caecum and colon also showed ulcerated caseous nodules not so numerous as in the small intestine.

Mesenteric Glands. — The mesenteric glands were slightly enlarged, those in the upper half were caseous practically throughout, the rest contained caseous nodules and patches in the cortex.

The Ileo-Colic and Colic Glands with few exceptions contained caseous nodules.

Larynx and Trachea.—Normal.

Inguinal Glands.—One on the right side contained a caseous tubercle, those on the left side were normal.

Near the inguinal glands on each side in the subcutaneous tissues there was a softened caseous nodule the size of a hempseed.

Eyes and Brain.—Normal.

Microscopical Examination.

Emulsion of Spleen.—Tubercle bacilli very numerous.

RHESUS MONKEY 245. Virus H. 53. "D.H." (*a*).

(A young animal.)

Subcutaneous inoculation of culture derived from the spleen of Monkey 135.

Dose—1·0 milligramme.

Date of Inoculation—November 5, 1908.

Killed when moribund—January 22, 1909. [78 days after inoculation.]

Clinical Notes.

The course of the disease was similar to that frequently seen in monkeys suffering from severe generalized tuberculosis, the symptoms being loss of appetite, increasing weakness and emaciation, and respiratory difficulty.

The weight at death was 2,000 grammes.

POST-MORTEM EXAMINATION.

The carcass was emaciated.

Local Lesion.—The skin over the right scapula showed an oval ulcer measuring 2·5 by 1·5 cm. with dry caseous floor and caseous base and margins.

Axillary Glands.—On the right side there were four enlarged completely caseous glands, the largest the size of a thrush's egg; a fifth contained discrete caseous tubercles.

On the left side one gland contained a hempseed-sized caseous nodule; another, a pinhead sized caseous tubercle.

Cervical Glands.—In the posterior triangle on the right side there were three caseous and softened glands, the largest 1 cm. in diameter. The rest were normal.

Vertebral Glands.—On the right side one in the fourth interspace, the size of a split pea, was caseous throughout; one in the ninth and one in the tenth contained each a caseous tubercle

Thorax.

Lungs.—The left lung was completely collapsed, the right was crepitant and mottled with patches of collapse; both lungs were closely beset with shotty caseous tubercles, the largest 2 mm. in diameter, in many places aggregated together and confluent.

Bronchial Glands.—The bronchial glands were slightly enlarged and contained softened caseous nodules up to a hempseed in size.

Heart and Pericardium.—Normal

Pleura.—Normal.

Abdomen.

The peritoneal cavity was filled with clear serous fluid.

Omentum.—The omentum was very closely beset with yellow caseous nodules up to 2 mm. in diameter. Along the free border they were aggregated together to form a mass of tuberculous tissue and in the rest of the omentum the nodules had in many places coalesced; the omentum was adherent to the floor of the abdomen and intimately adherent to the spleen which it completely surrounded forming around it a false capsule.

There were a few caseous tubercles on the *Mesentery*, and numerous caseous nodules similar to those in the omentum on the *Meso-colon*.

On the *Parietal Peritoneum* chiefly near the spleen were scattered caseous tubercles.

Spleen.—The spleen was greatly enlarged measuring 7 by 5 by 2·5 cm. The omentum was so closely adherent to the nodules projecting from the surface that it was impossible completely to separate it. The spleen itself was composed almost entirely of softened yellow caseous nodules varying up to 4 mm. in diameter.

Splenic Lymphatic Glands.—One small one was caseous throughout, two others contained each a caseous tubercle.

Liver.—The liver was pale and contained scattered caseous tubercles varying in size up to that of a millet seed.

Two glands near the head of the pancreas were closely beset in the cortices with caseous tubercles becoming confluent.

Kidneys.—The left kidney showed in the cortex eight tubercles, the largest 2 mm. in diameter, some caseous, others grey with caseous centres.

In the cortex of the right kidney there were a dozen caseous tubercles, the largest 2·5 mm. in diameter.

Suprarenal Bodies.—Normal.

Lumbar Glands.—Two lumbar glands were slightly enlarged and partly caseous.

Alimentary Tract.

Tongue, Tonsils, Larynx, Pharynx, and Trachea.—Normal.

Submaxillary Glands.—One on the left side contained a millet-seed sized caseous tubercle.

Pharyngeal Glands.—One on the right side contained a millet-seed sized caseous tubercle.

Small Intestines.—All the lymphoid follicles in the small intestine were slightly enlarged and showed minute central ulcers; the majority were caseous in the centre; there were caseous tubercles, the majority ulcerated, in the Peyer's patches.

Large Intestines.—The mucous membrane showed small ulcers without caseation.

Mesenteric Glands.—There were seven softened caseous nodules up to 2 mm. in diameter in the mesenteric glands.

Ileo colic Glands.—Two ileo-colic glands contained each one caseous tubercle.

Colic Glands.—Several of the colic glands were caseous throughout; others contained caseous nodules.

Inguinal Glands.—One on the right side contained a caseous tubercle

Eyes.—Normal.

Brain.—Normal.

Microscopical Examination.

Emulsion of Spleen.—A few tubercle bacilli seen.

Enlarged follicle from Small Intestine.—Very numerous tubercle bacilli.

RHESUS MONKEY 273. Virus H. 53. "D.H." (*a*).

(A young animal.)

Subcutaneous inoculation of culture derived from the spleen of Monkey 131.

Dose—1·0 milligramme.

Date of Inoculation—March 12, 1909.

Died—May 11, 1909. [60 days after inoculation.]

Clinical Notes.

The course of the disease was similar to that usually seen in monkeys suffering from general tuberculosis. The weight at death was 1700 grammes.

POST-MORTEM EXAMINATION.

The carcass was very emaciated.

Local Lesion.—Over the right scapula there was an oval ulcer 4 cm. in length covered with a dry scab through openings in which caseo-pus exuded; on removal of this the floor which was formed by granulation tissue was found to be covered with caseo-pus.

Axillary Glands.—On the right side one very large gland was caseous throughout, another only slightly smaller was beset with caseous nodules, a third rather small one contained discrete caseous nodules.

The glands on the left side contained discrete caseous tubercles.

Cervical Glands.—In the right posterior triangle there were two large pea-sized glands which were caseous throughout. A cervical gland on the left side showed one caseous tubercle.

Vertebral Glands.—One on the right side in the 10th interspace contained half-a-dozen caseous tubercles; two on the left side contained three caseous tubercles.

Thorax.

Lungs.—The right middle lobe and portions of the right caudal were red and consolidated. The lung parenchyma contained moderately numerous caseous tubercles with grey margins, the largest rather larger than a millet-seed.

Bronchial Glands.—The bronchial glands were enlarged and contained discrete caseous nodules up to 2·5 mm. in diameter.

Heart and Pleura.—Normal.

Abdomen.

Omentum and Peritoneum.—The omentum contained about half-a-dozen caseous tubercles up to a millet-seed in size.

The parietal peritoneum was normal: there were a few discrete caseous tubercles on the mesentery and mesocolon.

Spleen.—The spleen was much enlarged measuring 5·5 by 3·5 by 2 cm. and closely beset with caseous and softened tubercles up to 2 mm. in diameter; they were mostly discrete and only here and there had become confluent.

Liver.—The liver contained moderately numerous evenly distributed caseous tubercles ranging in size from a point to a millet-seed.

Two glands on the head of the pancreas were enlarged and their cortices composed of confluent caseous and softened nodules.

Kidneys.—In the cortex of each scattered caseous tubercles were seen on the surface, about half-a-dozen in one and ten to twelve in the other; similar tubercles were seen in the depth of the cortex.

Suprarenal Bodies.—Normal.

Lumbar Glands.—The lumbar glands were enlarged and contained a number of yellow caseous nodules up to 2 mm. in diameter.

Iliac Glands.—There were two or three tubercles in each of these glands.

Alimentary Tract.

Tongue, Pharynx, Tonsils.—Normal.

The Submaxillary and Retro-pharyngeal Glands contained discrete caseous tubercles.

Intestines.—One caseous tubercle was seen under the mucous membrane of the small intestine.

Mesenteric Glands.—There were half-a-dozen caseous nodules in the mesenteric glands.

Ileo-colic Glands.—One contained two caseous nodules.

Colic Glands.—Three colic glands contained each a caseous tubercle.

Rectal Glands.—Two rectal glands contained two or three caseous tubercles up to 2 mm. in diameter.

Inguinal Glands.—The glands on each side contained a number of caseous nodules up to 2 mm. in diameter.

Microscopical Examination.

Emulsion of Spleen.—Tubercle bacilli very numerous.

RHESUS MONKEY 275. Virus H. 53. "D.H." (*a*).

(A young animal.)

Subcutaneous inoculation of culture derived from the spleen of Monkey 131.

Dose—1·0 milligramme.

Date of Inoculation—March 12, 1909.

Died—May 2, 1909. [51 days after inoculation.]

Clinical Notes.

The illness was similar to that usually seen in monkeys suffering from general tuberculosis, and was characterised by extreme weakness and emaciation.

The weight at death was 1320 grammes.

POST-MORTEM EXAMINATION.

Local Lesion.—The skin just behind the angle of the left scapula showed an ulcer measuring 3·5 by 2·5 cm. in diameter with dry red floor and considerably undermined margins; under the margins of the skin there was a small quantity of caseo-pus.

Axillary Glands.—In the left axilla there was a group of six enlarged completely caseous and softened glands. The glands on the right side contained six nodules up to a hempseed in size.

Cervical Glands.—On the left side several glands behind the clavicle, the largest the size of a pea, were caseous. On the right side two glands contained each one caseous nodule the largest 2 mm. in diameter.

Vertebral Glands.—The glands in the 8th and 9th interspaces on the left side were enlarged and caseous throughout; those in the 10th and 11th interspaces contained each one caseous tubercle.

Thorax.

Lungs.—The lungs were crepitant and contained very sparsely scattered miliary tubercles, some grey, some with caseous centres; in the right lung there were also two caseous tubercles 1·5 mm. in diameter; in this lung eight tubercles were counted on the surface, and there was a smaller number on that of the left.

Bronchial Glands.—The bronchial glands were enlarged and contained caseous and softened nodules up to a hempseed in size.

Mediastinal Glands.—Three glands in the anterior part of the dorsal mediastinum, the largest the size of a pea, were caseous throughout.

Heart and Pleura.—Normal.

Abdomen.

Omentum.—The omentum showed about half-a-dozen caseous tubercles, the largest the size of a millet-seed.

Peritoneum.—Normal.

Spleen.—The spleen was enlarged (5·5 by 3 by 1·5 cm.) and packed as closely as possible with softening caseous nodules the largest 3 mm. in diameter; there was extremely little red splenic tissue around the nodules, all of which were facetted by pressure with their neighbours.

The splenic lymphatic glands were slightly enlarged and contained caseous nodules.

Liver.—The liver contained a moderate number of caseous tubercles varying up to a millet-seed in size scattered fairly evenly throughout the substance; from four to six were counted in areas on the surface two centimetres square.

In the hilum of the liver there was a gland 1 cm. in diameter which was caseous throughout.

In the neighbourhood of the head of the pancreas, between it and the liver, there were three enlarged glands the substance of which was completely replaced by softened caseous nodules.

Kidneys.—The left kidney showed on the surface two pinhead-sized caseous tubercles and in the depth of the cortex one millet-seed sized caseous tubercle. On the surface of the right there were two caseous tubercles; there was none in the depth.

Suprarenal Bodies.—Normal.

Lumbar Glands.—The lumbar glands were closely beset with caseous nodules.

Iliac Glands.—These were slightly enlarged and contained discrete caseous nodules up to a hempseed in size.

Alimentary Tract.

Tongue, Pharynx, Tonsils.—Normal.

The Submental and Submaxillary Glands contained discrete caseous nodules.

Retro-pharyngeal Glands.—In each there was a caseous and softened nodule.

Intestines.—Normal.

Mesenteric Glands.—There were four caseous nodules in the mesenteric glands.

Ileo-colic Glands.—Normal.

Colic Glands.—The glands of the descending colon and the rectum were enlarged and contained caseous nodules or were caseous throughout.

Inguinal Glands.—The glands on each side contained caseous nodules; from six to eight were seen in each group.

BABOON 7 [East African]. Virus H. 53. "D.H." (*a*).

(A young animal.)

Subcutaneous inoculation of culture derived from the original material through guinea-pig 1482.

Dose—1·0 milligramme.

Date of Inoculation—October 28, 1907.

Died—December 2, 1907. [35 days after inoculation.]

Clinical Notes.

A soft fluctuating tumour developed at the seat of inoculation in the back (on the left side); this broke down 10 days after inoculation and discharged its caseo-purulent contents. The axillary glands on the left side became much enlarged.

The baboon was first noticed to be ill about a fortnight after inoculation. It gradually got worse, losing

appetite, strength, and flesh, and then became collapsed. For two days before death it existed in a semi-comatose condition, taking very little food.

Temperature.

On the 16th day the temperature, which had hitherto been approximately normal, fell to 35·8° C. On the 24th day it was 35·4° C., and the following day it could not be recorded by the clinical thermometer, being below 35° C. The temperature remained subnormal (below 35° C.) until the baboon died.

Weight.

At death—4450 grammes.

POST-MORTEM EXAMINATION.

Local Lesion.—The skin of the back over the last few ribs on the left side showed an irregular ulcer measuring 4 by 3 cm., with undermined edges and congested floor to which adhered some masses of haemorrhagic dried discharge; the base was formed by the muscles of the back which were not apparently thickened or infiltrated; under the margins of the ulcer, which were a little raised, there was a small amount of breaking-down caseous substance.

Axillary Glands.—Of the glands in the left axilla one was the size of a pigeon's egg and was filled with blood-stained ill-formed pus and caseo-necrotic masses, another about the size of a sparrow's egg was similar on section. A third the size of a broad bean was closely beset with discrete caseous foci. There were besides several smaller glands which contained a varying number of caseous foci.

The right axillary glands were normal.

Inguinal Glands.—One of the left inguinal glands showed in its centre a softened caseous nodule about 5 mm. in diameter.

The right inguinal glands were normal.

Thorax.

Pleura, Heart and Pericardium, Bronchial Glands.—Normal.

Lungs.—The lungs were a little congested, slightly pigmented, and crepitant throughout, except for a few small collapsed areas along the dorsum; they contained shotty cascating tubercles, the largest about 1 mm. in diameter, evenly though sparsely distributed throughout the parenchyma.

Abdomen.

Omentum and Peritoneum.—Normal.

There was a slight excess of fluid in the peritoneal cavity.

Spleen.—The spleen was not apparently enlarged. It showed on section sparsely scattered minute greyish-yellow tubercles, the largest not more than 0·5 mm. in diameter.

Liver.—The liver, normal in colour and texture, showed sparsely scattered throughout the substance greyish-white tubercles ranging from a mere point up to rather less than 1 mm. in diameter.

Kidneys and Suprarenal Bodies.—Normal.

Abdominal Glands.—There was no naked-eye evidence of tuberculosis in the portal, coeliac, lumbar, or mesenteric glands. One of the left iliac glands was enlarged, but showed no sign of caseation; the right were normal.

Alimentary Tract.

Tongue, Pharynx, Tonsils; Submaxillary, Pharyngeal, and Cervical Glands, Intestines.—Normal.

BABOON 5 [Chacma]. Virus H. 53. "D.H." (*a*).

(A young animal.)

Fed once with culture derived from the original material through Guinea-pig 1482.

Dose—1·0 milligramme.

Date of Feeding—October 28, 1907. [A young animal.]

Died—January 6, 1908. [70 days after feeding.]

Clinical Notes.

The baboon first appeared to be unwell about December 27, 60 days after feeding; he was less lively, his appetite was poor and his temperature subnormal. There were no other signs of ill-health; the respiration was quite normal.

On the 66th day the temperature had fallen to below 35° C. and for the remaining four days of life could not be recorded by the clinical thermometer; on the morning of January 6th, the 70th day after feeding, he was found dead.

Temperature.

The temperature was fairly normal, though irregular, for sixty days after the commencement of the experiment, the maximum range of variation being 1·8° C. (36·4° C.–38·2° C.). Subsequently it was subnormal (see clinical notes).

Tuberculin Test.

The baboon was not tested subsequent to inoculation.

Weight.

At death—4670 grammes.

POST-MORTEM EXAMINATION.

The carcass was in good condition. The cause of death was not apparent.

Alimentary Tract.

Tonsils.—In one tonsil there was a soft whitish focus; the other was normal.

Thorax.

Lungs.—The lungs were crepitant; the right lung contained about half-a-dozen hard nodules, the largest nearly the size of a hemp seed, with fibrous margins and softened yellow centres; the left caudal lobe was normal; in the thin margin of the left cephalic lobe there were two hard nodules, the larger the size of a small haricot bean; they had pearly-white fibrous margins and yellow softened interiors.

Bronchial Glands.—All were deeply pigmented; one on the left side contained half-a-dozen yellow softened foci, the largest the size of a millet seed; the rest appeared normal.

In the right axilla and in the loose tissues between the muscles of the right forearm were several whitish oval cysts, the largest about 1 cm. in length, each of which contained a tapeworm.

The remaining organs and glands were examined and found normal.

Microscopical Examination.

Focus from Tonsil.—No tubercle bacilli; numerous organisms stained blue.

Nodules from Lung. (1) No tubercle bacilli. A few bacilli and cocci stained blue.
(2) [culture emulsion]. No tubercle bacilli.

Focus from Bronchial Gland.—Two tubercle bacilli seen.

VIRUS H. 53. "D.H." (*a*).

ABSTRACTS OF POST-MORTEM NOTES OF RABBITS INOCULATED WITH CULTURES OR TISSUE EMULSIONS OBTAINED FROM THE ANIMALS USED IN THE VARIOUS PASSAGE EXPERIMENTS WITH THE VIRUS.

1.—Subcutaneous Inoculations with Cultures.

Source of Culture Inoculated.	Dose in Milli-grammes.	Number of Rabbit.	Weight in Grammes.		Duration of Life.	Result.
			Initial.	Final.		
Calf Passage. Series *a*.						
Calf 1257 (3rd Calf) Prescapular gland.	10·0 mg.	1607	1,550	2,000	Died 459 days	Slight generalised tuberculosis. The cause of death was not apparent. There was a dry caseous local lesion the size of a walnut; the adjacent glands were caseous softened and gritty. The lungs showed (in the thin margins) ten irregular firm caseous patches. There were two fibro-caseous nodules on the pleura and one small one on the pericardium, and a few tubercles in the substance of the heart. There was no tuberculosis elsewhere.
	10·0 mg.	1608	1,300	1,330	Died 100 days	General tuberculosis. There was a large ulcerated caseous local lesion and the nearest glands were caseating. The lungs were crepitant and contained fairly numerous discrete caseating tubercles. mostly very minute; around the margins were some caseating patches. The tracheal glands were partly caseous. The spleen contained half-a-dozen caseous miliary tubercles (smear, very numerous T.B.). The kidneys showed in the cortex numerous caseating nodules up to a pea in size; the larger ones projected from the surface and many extended into the medulla; in the medulla there were scattered caseous tubercles and streaks.
Calf 1257 ... ... Spleen. (through G.P. 2703).	10·0 mg.	1697	1,550	1,000	Died 195 days	General tuberculosis. There was a caseous and softened local lesion, and the adjacent gland was partly caseous. The lungs were crepitant and contained moderately numerous caseous gritty miliary tubercles, and caseous gritty patches around the margins. There were numerous nodules in the omentum (some confluent) and several on the mesentery and meso-colon, a number of miliary caseous tubercles on the surface of the spleen, and flattened caseating growths on the surface of the liver. The kidneys showed on the surface pits and a moderate number of caseous tubercles, and on section caseous streaks; one also showed on the surface a large grey mass with caseous foci, and caseo-pus in the pelvis.
	5·0 mg.	1698	1,450	950	Died 206 days	Slight generalised tuberculosis. The cause of death was not apparent. There was a large caseous and softened local lesion, and the adjacent glands were caseous. The lungs showed on the surface some greyish-white tubercles and in the substance five small gritty caseous nodules and a few minute grey tubercles. There was a fine caseous streak or two in each kidney. The dorsal part of the costal pleura was covered with reddish granulation tissue and elsewhere on the pleura a few caseous nodules were seen. There was no tuberculosis elsewhere.
Calf 1333 (4th calf) Prescapular gland.	10·0 mg.	1953	1,400	1,400	Died 174 days	Generalised tuberculosis, not very severe. There was a large thin-walled cyst at the seat of inoculation filled with caseo-pus; the nearest glands were normal, but two tracheal glands contained softened caseous nodules. About half the cephalic and a third of the caudal lobes of the lungs was composed of firm caseous masses; the rest of the lungs was crepitant and contained discrete caseous nodules (up to 1 cm.). On the surface of one kidney there was a scar with two caseating tubercles in it. There was no tuberculosis elsewhere.

	10·0 mg.	1954	1,250	1,520	Died 204 days	General tuberculosis. The local lesion was nodular and caseous, and the nearest glands were caseous. The lungs filled the chest and were solid and caseating almost throughout. The cortices of the kidneys were closely beset with projecting caseous nodules up to a large pea in size. There were numerous tubercles on the omentum.

Calf Passage. Series β.

Calf 1555 (1st calf) Lung.	10·0 mg.	1504	900	1,120	Killed 199 days (when ill).	Chronic general tuberculosis, not severe. There was a large thin-walled abscess with caseo-purulent contents at the seat of inoculation; the adjacent gland was partly caseo-purulent. Scattered around the margins of the lungs were small firm grey patches with caseous foci and the ventral half of one middle lobe was composed of similar tissue; in the rest of the lungs were fairly numerous submiliary grey tubercles. Each tracheal gland contained a calcareous patch. Both kidneys were extensively scarred; one showed a large projecting nail shaped nodule, and several smaller ones which extended into the substance as caseous streaks; in the papillary zone were several caseous tubercles. The other kidney showed one caseous tubercle in the cortex, and the calyces and pelvis were distended with thick caseo-pus. One testicle was enlarged and caseo-necrotic (smear, a few T.B.). The right eye was tuberculous.
Precrural gland.	10·0 mg.	1501	1,100	1,060	Died 163 days	Chronic general tuberculosis. There was a lobulated thin-walled caseous and softened local lesion; the adjacent glands were caseous and gritty. The lungs contained scattered grey miliary tubercles some caseous, and in the margins a few caseating patches. There was rather severe omental and peritoneal tuberculosis. The kidneys showed numerous small pits on the surface and caseous tubercles in the cortex; there were a few tubercles in the medulla. There were tubercles in the iris and choroid of both eyes and the lachrymal glands contained caseous nodules.
Calf 1231 (2nd calf) Prescapular gland.	One serum culture 10–15·0 mg.	1609	1,400	1,140	Died 310 days	Chronic general tuberculosis. The local lesion was nodular caseous and softened, the size of a pigeon's egg; the nearest glands were caseous. The margins of the lungs were caseous and there was a caseous band on the dorsal surface of one caudal lobe; the rest of the lungs was crepitant and contained scattered miliary caseous tubercles. There were two or three insignificant foci in each kidney. There was extensive tuberculous pericarditis. The left elbow and wrist joints were distended with caseo-pus and the muscles of the forearm between the joints were replaced by caseo-pus; the right wrist and left knee joints were also distended with pus.
	One serum culture 10–15·0 mg.	1610	1,450	1,190	Died 197 days	General tuberculosis. There was a very large thin-walled lobulated tumour containing caseo-pus at the seat of inoculation; the adjacent glands contained softened caseous nodules. The lungs were extensively infiltrated (superficially) with coalescing caseous tracts and nodules; the substance of the lung was crepitant and discrete nodules were seen in it. There were a few caseous tubercles on the pleura and one in the heart. The kidneys showed several very large projecting nail-shaped nodules (the largest 1 cm.) composed of grey tissue beset with caseous foci, and contained also a number of miliary caseous tubercles.
Calf 1367 (4th calf) Thoracic gland.	10·0 mg.	2050	2,000	1,550	Died 162 days	General tuberculosis. The thin margins of the lungs were yellow and caseous; the rest of the lungs was crepitant and contained miliary caseating tubercles, numerous on the surface scanty in the depth. The pleura (costal and diaphragmatic), was covered with flat caseating growths. The kidneys showed numerous grey nodules with slightly caseous centres, up to a hemp seed in size, and several of the calyces contained caseo-pus. A few grey foci were seen in the liver, and numerous yellow miliary foci in the appendix and dilated end of the ileum.

VIRUS H. 53. "D.H." (*a*)—*continued.*

ABSTRACTS OF POST-MORTEM NOTES OF RABBITS INOCULATED WITH CULTURES OR TISSUE EMULSIONS OBTAINED FROM THE ANIMALS USED IN THE VARIOUS PASSAGE EXPERIMENTS WITH THE VIRUS—*continued.*

1.—SUBCUTANEOUS INOCULATIONS WITH CULTURES—*continued.*

Source of Culture Inoculated.	Dose in Milli-grammes.	Number of Rabbit.	Weight in Grammes.		Duration of Life.	Result.
			Initial.	Final.		
Calf 1367 (4th calf) Thoracic gland—*continued.*	10·0 mg.	**2051**	2,000	1,400	Died 74 days	General tuberculosis. There was a firm caseous local lesion and the adjacent glands contained caseous patches. The lungs were congested and showed discrete caseating tubercles and a few caseating patches. There were numerous early tubercles in the omentum and a few on the surface of the liver. The kidneys were enlarged and the cortices very closely beset with caseating nodules (up to 4 mm.) projecting from the surface. The iliac and portal glands contained caseous foci.
						Rhesus Monkey Passage. *β.*
Rhesus Monkey 131 (1st monkey) Spleen.	10·0 mg.	**2190**	2,000	1,800	Died 95 days	Chronic general tuberculosis, not severe. There was a caseous and softened local lesion, and the nearest glands contained caseous nodules. The thin margins of the lungs were caseating and there were scattered tubercles elsewhere. The bronchial glands contained caseous tubercles. The kidneys showed in the cortices numerous caseating tubercles. There were a few miliary tubercles in the areolar tissue around the kidneys.
	10·0 mg.	**2191**	1,720	1,800	Died 113 days	Slight chronic general tuberculosis; the cause of death was not apparent. There was a small caseous local lesion and the nearest glands were partly caseo-calcareous. The thin margins of the lungs, and the dorsal surface of one caudal lobe, were caseo-calcareous; there were scattered tubercles in the rest of the lungs. There were three small caseating nodules in the kidneys, gritty foci in the portal glands, caseous gritty nodules in the iris of one eye, and a nodule in the corresponding lachrymal gland.
						Goat Passage.
Goat 57 (2nd goat) Mediastinal gland.	10·0 mg.	**2005**	2,090	1,520	Died 162 days	Chronic general tuberculosis, insufficient to account for death. There was a small caseous local lesion and the nearest gland was caseous. The lungs were crepitant except for one lobe which was red and solid; they contained scattered tubercles mostly grey, a few caseous. There was early tuberculosis of the pleura. One kidney was atrophied and calcareous, the other was normal in size and showed in the cortex a moderate number of grey nodules up to a hemp seed in size with caseous centres.
	10·0 mg.	**2006**	1,640	1,450	Died 136 days	General tuberculosis. The local lesion was caseous and softened, and ulcerated; the adjacent glands contained caseous nodules. The thin margins of the lungs were caseous, the rest of the lungs was crepitant but contained numerous glassy tubercles and a few larger caseating tubercles. The kidneys were much enlarged and were closely beset with grey tubercles some slightly projecting, the majority with caseous centres; on section numerous caseous streaks were seen, and caseo-pus in the pelves. The testicles and epididymes were caseous; the spleen contained one tubercle; there were caseous softened nodules on the parietal peritoneum, mesentery, and in the areolar tissues of the groin.

2.—Intravenous Inoculations with Cultures.

				Calf Passage. Series *α*.		
Calf 1135 (1st calf) Prescapular gland.	1·0 mg.	1322	1,400	1,020	Died 19 days	General tuberculosis.
	1·0 mg.	1323	1,730	1,070	Died 21 days	General tuberculosis.
Calf 1257 (3rd calf) Spleen, through G.P. 2703.	1·0 mg.	1695	2,200	1,320	Died 25 days	General miliary tuberculosis.
	0·1 mg.	1696	2,250	1,820	Died 32 days	General miliary tuberculosis.
Calf 1295 (4th calf) Portal gland.	1·0 mg.	1817	1,590	1,200	Died 17 days	General tuberculosis, complicated by pseudo-tuberculosis.
	0·1 mg.	1818	1,820	1,010	Died 71 days	General tuberculosis, not severe.
	0·01 mg.	1819	1,520	1,000	Died 71 days	General tuberculosis.
Calf 1333 (4th calf) Prescapular gland.	1·0 mg.	1950	2,400	1,550	Died 27 days	General miliary tuberculosis.
	0·1 mg.	1951	1,750	1,450	Died 38 days	General miliary tuberculosis.
	0·01 mg.	1952	1,420	1,110	Died 133 days	Chronic general tuberculosis, not very severe.
				Calf Passage. Series *β*.		
Calf 1155 (1st calf) Lung.	1·0 mg.	1502	850	750	Died 21 days	General miliary tuberculosis and coccidiosis of the liver.
Precrural gland.	1·0 mg.	1499	1,800	1,230	Died 26 days	General miliary tuberculosis.
				Rhesus Monkey Passage. *α*.		
Rhesus Monkey 135 (1st monkey). Spleen.	1·0 mg.	2059	2,150	1,550	Died 25 days	General tuberculosis.
	0·1 mg.	2060	2,250	1,450	Died 50 days	General miliary tuberculosis.
	0·01 mg.	2061	2,250	1,700	Died 71 days	General tuberculosis.
				Pig Passage.		
Pig 119 ... ... Bronchial gland.	1·0 mg.	2062	1,400	1,240	Died 19 days	Acute tuberculosis.
	0·1 mg.	2063	2,200	1,450	Died 33 days	General tuberculosis.
	0·01 mg.	2064	1,800	1,450	Died 107 days	Chronic general tuberculosis.

VIRUS H. 53. "D.H." (*a*)—*continued.*

ABSTRACTS OF POST-MORTEM NOTES OF RABBITS INOCULATED WITH CULTURES OR TISSUE EMULSIONS OBTAINED FROM THE ANIMALS USED IN THE VARIOUS PASSAGE EXPERIMENTS WITH THE VIRUS—*continued.*

3.—Intraperitoneal Inoculations with Cultures.

Source of Culture Inoculated.	Dose in Milli-grammes.	Number of Rabbit.	Weight in Grammes.		Duration of Life.	Result.
			Initial.	Final.		
Calf Passage. Series *β*.						
Calf 1155 (1st calf) Lung.	1·0 mg.	1503	800	700	Died 32 days	General tuberculosis.
Precrural gland.	1·0 mg.	1500	1,150	1,120	Died 152 days	General tuberculosis (the injection had probably been made into the colon.

4.—Subcutaneous Inoculations with Tissue Emulsions.

Source of Tissue Emulsion Inoculated.	Dose of Emulsion.	Number of Rabbit.	Weight in Grammes.		Duration of Life.	Result.
			Initial.	Final.		
Calf Passage. Series *a*.						
Calf 1135 (1st calf) E. of prescapular gland.	1·0 cc. (31,760,000 T.B.)	1244	1,420	2,700	Killed 161 days	Slight chronic general tuberculosis. The local lesion was a thin-walled baggy cyst filled with caseo-pus. The nearest glands were normal. The lungs contained scattered miliary caseous tubercles with grey margins and a group of caseo-calcareous nodules. The surfaces of the kidneys showed three large scars two of which contained each a calcareous grain, the third a wedge-shaped caseo-calcareous nodule. Two tubercles were seen in the spleen. There was no tuberculosis elsewhere.
Calf 1199 (2nd calf) E. of prescapular gland.	4·0 cc. (T.B. in moderate numbers).	1412	1,700	2,850	Killed 232 days	Chronic general tuberculosis, not severe. There was a small flat thin-walled cyst filled with turbid fluid at the seat of inoculation; the nearest glands were normal. Part of the caudal lobe of each lung was occupied by a thin-walled caseo-purulent mass; in the thin margins there were several firm grey patches beset with caseous foci; the rest of the lungs was crepitant and contained two or three caseous nodules. One kidney showed a grey nail-shaped caseating nodule. There were early tuberculous growths along the margins of some of the ribs.
E. of bronchial gland.	—	1413	1,200	1,570	Died 124 days	Local tuberculosis and slight tuberculosis of lungs. Death was the result of cellulitis of the back following injuries. The glands nearest to the seat of inoculation in the back were enlarged but not caseous. The lungs contained scattered firm irregular caseous nodules and the tips of the caudal lobes were replaced by confluent nodules. The abdominal organs and glands were normal.

Calf 1257 (3rd calf) E. of prescapular gland.	5·0 cc. (T.B. moderately numerous).	1557	1,350	1,670	Died 117 days	General tuberculosis. The local lesion consisted of a large ulcer at the margin of which was a thin-walled cyst with caseo-purulent contents; the nearest glands contained caseous nodules. The lungs contained a moderate number of tubercles some grey, some caseous in the centre; there were some flat caseous patches in the margins, and several loosely-attached caseous tubercles on the surface. On the pleura numerous small tuberculous growths were seen. The kidneys contained numerous large prominent firm caseating nodules extending into the substance in a wedge-shaped manner (smear, T.B. numerous).
	5·0 cc.	1558	1,300	2,450	Killed 117 days	Slight general tuberculosis. The local lesion was a very large thin-walled lobulated baggy cyst. The scapular glands were irregularly caseated. The lungs contained a few minute tubercles and one miliary caseous tubercle; the margin of one lobe was greyish-red and contained caseous foci. There were clusters of miliary tubercles on the diaphragmatic pleura. Each kidney contained two grey tubercles.
E. of tuberculous tissues from G.P.'s 2836–2838. [From Calf 1257, E. of bronchial gland.]	3·0 cc. (T.B. extremely numerous).	1653	2,270	1,750	Died 58 days	Early generalised tuberculosis. There was an empty cavity at the seat of inoculation, the skin over which was ulcerated; the nearest glands contained caseo-purulent nodules. The lungs were crepitant and contained fairly numerous irregular grey tubercles the largest with definitely caseous centres, and several larger caseous nodules. The kidneys contained scattered submiliary caseating tubercles and a few caseous streaks.
	3·0 cc.	1654	1,850	1,570	Died 71 days	Local tuberculosis, and tuberculosis of lungs and kidneys. There was a caseous ulcer at the seat of inoculation and the nearest glands were caseous or contained caseous tubercles. The dorsal surfaces of the caudal lobes were extensively replaced by firm caseous patches, and the margins of the anterior lobes were occupied by a broad band of similar tissue; elsewhere the lungs were crepitant and showed fairly numerous caseating nodules (up to 5 mm.). The kidneys contained fairly numerous tubercles (up to 1·5 mm.) the majority with caseous centres.
Calf Passage. Series β.						
Calf 1155 (1st calf) E. of prescapular gland.	—	1329	1,550	3,600	Killed 242 days	Slight generalised tuberculosis. There were two thin-walled cysts at the seat of inoculation. The lungs contained scattered minute grey tubercles, and a third of one caudal lobe was replaced by a solid reddish-grey mass containing caseous streaks and foci. There was one grey tubercle in each kidney.
	—	1330	1,450	1,150	Died 146 days	General tuberculosis. There was a large flat lobulated thin-walled tumour at the seat of inoculation filled with caseo-pus, and the adjacent glands were caseous. The lungs were firm congested and closely beset with miliary caseous tubercles everywhere becoming confluent. The bronchial and many abdominal glands contained small caseous tubercles or foci. The right kidney contained numerous grey tubercles with caseous centres and about half-a-dozen wedge-shaped caseous nodules up to a pea in size; the left kidney was similarly affected but the nodules were larger.
Calf 1231 (2nd calf) E. of prescapular gland.	3·0 cc. (T.B. numerous).	1510	1,560	1,920	Killed 224 days	Local tuberculosis, and tuberculosis of lungs and kidneys. The local lesion was a flat thin-walled tumour with softened caseous contents; the nearest gland was caseous and softened. The lungs contained fairly numerous irregular caseous gritty nodules up to a pea in size, in places confluent. Each kidney showed in the cortex numerous caseous tubercles some extending deeply into the medulla, and two or three larger caseating nodules. There was no tuberculosis elsewhere.
	3·0 cc.	1511	1,580	1,220	Died 224 days	Chronic general tuberculosis. There was a collapsed cyst at the seat of inoculation and the nearest glands were caseous. The lungs contained fairly numerous yellow caseous tubercles with grey margins. Each kidney showed on the surface numerous caseous nodules with grey margins (up to 2·5 mm.) and two or three larger masses, reddish-grey in colour and mottled with caseous patches; on section numerous long caseous streaks were seen, and in the calyces of one kidney there was caseo-pus. The left testicle was enlarged and caseous throughout and the epididymis was caseous; the right contained a caseous patch; there were tubercles on the meso-testis. The omentum contained scattered caseous tubercles and there were numerous caseous nodules on the mesentery.

VIRUS H. 53. "D.H." (*a*)—*continued.*

ABSTRACTS OF POST-MORTEM NOTES OF RABBITS INOCULATED WITH CULTURES OR TISSUE EMULSIONS OBTAINED FROM THE ANIMALS USED IN THE VARIOUS PASSAGE EXPERIMENTS WITH THE VIRUS—*continued.*

4.—SUBCUTANEOUS INOCULATIONS WITH TISSUE EMULSIONS—*continued.*

Source of Tissue Emulsion Inoculated.	Dose of Emulsion.	Number of Rabbit.	Weight in Grammes.		Duration of Life.	Result.
			Initial.	Final.		
Calf 1269 (3rd calf) E of prescapular gland.	2·0 cc. (T.B. not numerous).	1730	1,350	1,250	Killed 250 days	Chronic general tuberculosis, not apparently progressive. There was a large ulcerated local lesion, and the nearest glands were partly caseo-purulent. The lungs contained scattered caseo-calcareous nodules up to a pea in size, and a few greyish foci indefinite in outline (? healed tubercles) were seen under the pleura. The bronchial glands were calcareous. The kidneys were enlarged and showed on the surface cicatricial patches and numerous miliary tubercles the smaller ones grey the larger caseous or calcareous, and also a few grey nodules containing caseous foci which extended inwards as caseous wedges.
	2·0 cc.	1731	1,100	800	Died 140 days	Local tuberculosis and tuberculosis of lungs and kidneys. There was a moderately large ulcerated caseous and softened local lesion and the nearest glands were caseous. The lungs contained a moderate number of irregular firm caseous nodules up to a pea in size and round the thin margins there was a narrow fringe of caseated tissue. The kidneys showed a moderate number of firm caseous nodules ; a few were elongated, and one in each kidney had infected the capsule producing a thin caseous plaque.
Goat Passage.						
Goat 65 (1st goat) E. of lung.	4·0 cc. (T.B. not numerous).	1772	960	1,550	Died 195 days	Chronic general tuberculosis, not severe. The local lesion was flat and caseous, and rather large ; the nearest glands were caseous. Two or three minute tubercles were seen in the lungs. The right kidney contained two grey caseating nodules and several caseous foci and streaks, the left a few grey nodules and caseous foci. There was enlargement and caseation of the joints of both fore feet and ankles.

5.—Intraperitoneal Inoculation with a Tissue Emulsion.

Calf Passage. Series *a*.						
Calf 1135 (1st calf) E. of prescapular gland.	1·0 cc. (31,760,000 T.B.).	1243	1,400	1,270	Killed 161 days	General tuberculosis. There was slight tuberculosis of the omentum and mesocolon. The testicles were caseous throughout, the vas deferens and the vesiculae seminales were filled with caseo-pus, and there were large caseous nodules in the meso-testis. Around the margins of the lungs there was a caseous gritty band, the rest of the lungs was crepitant and rather closely beset with caseous tubercles, and showed also one large caseous nodule. Each kidney contained caseous tubercles with grey margins, numerous on the surface, scanty in the depth. There was one tubercle in the liver, and one in a bronchial, a coeliac and a mesenteric gland.

VIRUS H. 53. "D.H." (*b*).

LUPUS.

VIRUS H. 53. "D.H." (*b*).

CULTURE INOCULATIONS, AND CALF PASSAGE EXPERIMENT (A).

CULTURE.

The strain was derived from the original material through Guinea-pig 3215, and was inoculated on November 14, 1908, when it had been 63 days in artificial cultivation.

The culture used was the 6th generation, 18 days old.

CALF 1507.

Subcutaneous.

Dose : 50·0 mg.

Killed when moribund : Jan. 16, 1909. 63 days.

P.M.—General tuberculosis.

RABBITS.

Number.	Method.	Dose.	Duration of Life.	Result.
2065	Intrav.	1·0 mg.	D. 27 days	General miliary T.
2066	Intrav.	0·1 mg.	D. 36 „	
2067	Intrav.	0·1 mg.	D. 25 „	
2068	Intrav.	0·01 mg.	D. 136 „	G. T.

CULTURE

Derived from the portal gland of Calf 1507.

The 4th generation, 15 days old, was used for inoculation on March 2, 1909. Duration of artificial cultivation : 45 days.

CALF 1555.

Subcutaneous.

Dose : 50·0 mg.

Died of pneumonia : March 28, 1909. 26 days.

P.M.—Local tuberculosis and early tuberculosis of lungs and thoracic glands ; T.B. were seen in smears from liver (few) spleen and a popliteal gland (numerous).

RABBITS.

Number.	Method.	Dose.	Duration of Life.	Result.
2182	Subcut.	10·0 mg.	D. 125 days	Slight chronic and not obviously progressive G. T.
2183	Subcut.	10·0 mg.	D. 169 „	Local T., and slight T. of lungs and kidneys.

CULTURE

Derived from the small mediastinal gland of Calf 1555.

The 5th generation, 10 days old, was used for inoculation on May 22, 1909.

Duration of artificial cultivation : 55 days.

CALF 1563.

Subcutaneous.

Dose : 50·0 mg.

Killed when very ill : August 17, 1909. 87 days.

P.M.—General tuberculosis, severe.

RABBITS.

Number.	Method.	Dose.	Duration of Life.	Result.
2352	Intrav.	0·1 mg.	D. 34 days	G. T.
2353	Intrav.	0·1 mg.	D. 22 „	General miliary T.
2355	Subcut.	47·0 mg.	D. 61 „	G. T., not severe.
2354	Subcut.	10·0 mg.	D. 123 „	Chronic G.T., not severe.

CULTURE

Derived from the popliteal gland of Calf 1563. The 3rd generation was used for inoculation on October 6, 1909, when 13 days old. Duration of artificial cultivation : 50 days.

CALF 1599.

Subcutaneous.

Dose : 50·0 mg.

Killed : January 19, 1910.

105 days.

P.M.—Slight retrogressive generalised tuberculosis.

RABBITS.

Number.	Method.	Dose.	Duration of Life.	Result.
2464	Subcut.	10·0 mg.	D. 191 days	Slight chronic G. T.
2462	Subcut.	5·0 mg.	K. 192 „	Local T., T. of lungs (not severe) and kidneys (slight).
2463	Subcut.	5·0 mg.	D. 134 „	

The 9th generation, 14 days old, was used for inoculation on April 29, 1909. Duration of artificial cultivation : 103 days.

CALF 1559.
Subcutaneous.
Dose : 50·0 mg.
Killed : August 18, 1909.
111 days.
P.M. — Slight generalised tuberculosis.

RABBITS.

Number.	Method.	Dose.	Duration of Life.	Result.
2346	Intrav.	1·0 mg.	D. 15 days	G. T.
2345	Intrav.	0·1 mg.	D. 19 „	G. T.
2344	Intrav.	0·01 mg.	D. 73 „	General miliary T.

The 6th generation, 11 days old, was used for inoculation on March 26, 1909. Duration of artificial cultivation : 69 days.

RABBIT 2224.
Subcutaneous.
Dose : 10·0 mg.
Died : 103 days.
P.M.—General tuberculosis.

MONKEY 277.
Subcutaneous.
Dose : 1·0 mg.
Died : May 16, 1909. 51 days.
P.M. — General tuberculosis, severe in spleen.

MONKEY 279.
Subcutaneous.
Dose : 1·0 mg.
Died : May 22, 1909. 57 days.
P.M. — General tuberculosis, severe.

RHESUS MONKEY 325.
Subcutaneous.
Dose : 1·0 mg.
Died : July 20, 1909. 59 days.
P.M.—General tuberculosis, severe.

RHESUS MONKEY 327.
Subcutaneous.
Dose : 1·0 mg.
Died : July 29, 1909. 68 days.
P.M.—General tuberculosis, severe.

VIRUS H. 53. "D.H." (*b*).

CULTURE INOCULATIONS, AND CALF PASSAGE EXPERIMENT (B).

CULTURE.

The strain was derived from the original material through Guinea-pig 3216, and was inoculated on January 21, 1909, when it had been 120 days in artificial cultivation.

The culture used was the 10th generation, 16 days old.

CALF 1545.
Subcutaneous.
Dose : 50·0 mg.
Died : March 14, 1909.
52 days.
P.M. — General tuberculosis.

CULTURE
Derived from the portal gland of Calf 1545. The 4th generation, 13 days old, was used for inoculation on May 6, 1909. Duration of artificial cultivation : 53 days.

CALF 1561.
Subcutaneous.
Dose : 50·0 mg.
Killed : June 14, 1909 (when dying).
39 days.
P. M. — General tuberculosis.

CULTURE
Derived from the small mediastinal gland of Calf 1561. The 3rd generation was used for inoculation on July 15, 1909, when 8 days old. Duration of artificial cultivation : 31 days.

CALF 1571.
Subcutaneous.
Dose : 50·0 mg.
Killed : November 3, 1909.
111 days.
P.M.—Local tuberculosis, with a few disseminated lesions.

CALF 1535.
Subcutaneous.
Dose : 50·0 mg.
Killed : May 4, 1909.
103 days.
P.M.—Slight generalised tuberculosis.

RABBITS.

Number.	Method.	Dose.	Duration of Life.	Result.
2122	Intrav.	1·0 mg.	D. 20 days	General miliary T.
2123	Intrav.	0·1 mg.	D. 24 „	
2124	Intrav.	0·01 mg.	D. 70 „	G. T.
2125	Subcut.	10·0 mg.	D. 56 „	Local T. and T. of lungs and kidneys (not severe).
2126	Subcut.	10·0 mg.	D. 44 „	Slight G. T. (insufficient to account for death).

RABBITS.

Number.	Method.	Dose.	Duration of Life.	Result.
2350	Intrav.	0·1 mg.	D. 17 days	G. T.
2349	Intrav.	0·01 mg.	D. 44 „	General miliary T.
2351	Subcut.	10·0 mg.	D. 106 „	Very slight G. T.

RHESUS MONKEY 317.
Subcutaneous.
Dose : 1·0 mg.
Died : June 21, 1909.
46 days.
P. M. — General tuberculosis.

RABBITS.

Number.	Method.	Dose.	Duration of Life.	Result.
2394	Subcut.	10·0 mg.	K. 130 days	Slight G. T.
2393	Subcut.	9·0 mg.	D. 116 „	Local T. and T. of lungs and kidneys (not severe).

RHESUS MONKEY 349.
Subcutaneous.
Dose : 1·0 mg.
Died : August 24, 1909.
40 days.
P. M. — General tuberculosis not severe, and apparently insufficient to account for death.

RHESUS MONKEY 265.
Subcutaneous.
Dose : 1·0 mg.
Died : February 4, 1909.
14 days.
P.M. — Small local lesion only. Cause of death not apparent.

RHESUS MONKEY 267.
Subcutaneous.
Dose : 1·0 mg.
Died : February 23, 1909.
33 days.
P.M.—Slight generalised tuberculosis. Cause of death not apparent.

GUINEA-PIGS.

Number.	Method.	Dose.	Duration of Life.	Result.
3432	Intrap.	0·1 mg.	D. 39 days	G. T.
3433	Subcut.	0·1 mg.	D. 82 „	G. T.

RHESUS MONKEY 319.
Subcutaneous.
Dose : 1·0 mg.
Died : June 29, 1909.
54 days.
P. M. — General tuberculosis

GUINEA-PIGS.

Number.	Method.	Dose.	Duration of Life.	Result.
3759	Subcut.	1·0 mg.	D. 71 days	G. T.
3760	Subcut.	1·0 mg.	D. 60 „	G. T.

RHESUS MONKEY 351.
Subcutaneous.
Dose : 1·0 mg.
Died : August 17, 1909.
33 days.
P. M. — General tuberculosis.

VIRUS H. 53. "D.H." (*b*).

ADDITIONAL INOCULATION EXPERIMENTS WITH CULTURES DERIVED FROM THE ORIGINAL MATERIAL.

February 12, 1909.

The strain was derived from the original material through Guinea-pig 3218, and had been 94 days in artificial cultivation.

The culture used was the 6th generation, 22 days old.

RABBITS.

Number.	Method.	Dose.	Duration of Life.	Result.
2169	Intrav.	1·0 mg.	D. 25 days	General miliary T.
2170	Intrav.	0·1 mg.	D. 80 „	G. T.
2171	Intrav.	0·01 mg.	D. 43 „	G. T.
2172	Subcut.	10·0 mg.	D. 95 „	G. T.
2173	Subcut.	10·0 mg.	D. 111 „	G. T.

GUINEA-PIGS.

Number.	Method.	Dose.	Duration of Life.	Result.
3495	Intrap.	0·1 mg.	D. 23 days	G. T. not severe.
3496	Subcut.	0·1 mg.	D. 7 „	No apparent cause of death.

April 1, 1909.

The strain was derived from the original material through Guinea-pig 3216, and had been 190 days in artificial cultivation.

The culture used was the 13th generation, 17 days old.

RABBITS.

Number.	Method.	Dose.	Duration of Life.	Result.
2248	Subcut.	1·0 mg.	K. 201 days	Local T. and slight T. of lungs.
2249	Subcut.	5·0 mg.	D. 81 „	Slight G. T.

RHESUS MONKEY 289.

Subcutaneous.

Dose: 1·0 mg.

Died: May 6, 1909.

35 days.

P.M.—Local tuberculosis; T.B. in organs. Death apparently from cold.

RHESUS MONKEY 291.

Subcutaneous.

Dose: 1·0 mg.

Died: May 5, 1909.

34 days.

P.M.—Local T. and a few disseminated lesions. Death probably from cold.

CALF 1507. Virus H. 53. "D.H." (*b*).

Subcutaneous inoculation of culture derived from the original material through Guinea-pig 3215.

Dose—50·0 milligrammes.

Date of Inoculation—November 14, 1908. [Age about 4 months.]

Killed when dying—January 16, 1909. [63 days after inoculation.]

Clinical Notes.

The respirations began to be increased in the 4th week after inoculation and the calf was obviously unwell. The respirations gradually increased in frequency and became more laboured (ending in the usual grunt); the calf lost appetite and became very weak and emaciated; it was killed when in a moribund condition nine weeks after inoculation.

Temperature.

During the whole period of the experiment the temperature was raised and irregular, fluctuating for the most part between 39·5° and 40·5° C. The maximum temperature recorded was 40·8° C.; the minimum 38·9° C.

Weights.

	cwt.	qrs.	lbs.
November 14, 1908	1	1	24
January 16, 1909	1	0	16

Total loss of weight.—1 qr. 8 lbs.

Average rate of loss per week.—4 lbs.

POST-MORTEM EXAMINATION.

The carcass was emaciated.

Local Lesion.—In the muscles on the left side of the neck there was a well-defined dense yellow caseous mass measuring 10 by 9 by 3 cm.

Left Prescapular Gland. — The left prescapular gland measured 8·5 by 4·5 by 2·5 cm. and was composed practically throughout of dense caseous substance similar to that composing the local lesion. In each caseo the caseous substance showed a few minute calcareous foci.

Between the local lesion and the prescapular gland there was a chain of dense caseous nodules, the largest the size of a kidney bean.

Right Prescapular Gland.—The right prescapular gland measured 4·7 by 1·8 by 1 cm. was very oedematous and showed in the cortex scattered irregular caseous foci.

Prepectoral Glands.—On the left side one measured 2 cm. in greatest diameter and on sectiou resembled the prescapular glaud. Another contained half-a-dozen caseous tubercles; iu a third there was one caseous tubercle.

On the right side one contained one, another four, small caseous tubercles.

Cervical Glands.—On the left side one in the lower part of the neck was much enlarged measuring 4 cm. in greatest diameter and was composed almost throughout of dense yellow caseous substance; other cervical glands were oedematous, oue contained a patch of caseous tubercles, the rest one or two caseous tubercles.

Axillary Glands.—Each contained a number of small caseous tubercles.

Thorax.

Lungs.—The lungs collapsed partially and when removed appeared to be about twice the normal in size; they weighed 5 lbs. 2 ozs.

The outer surface of each lung showed extensive areas of red hepatization, the left being more severely affected than the right; there were similar areas on the ventral surface but not so widespread and containing isolated crepitant lobules; the rest of the lungs (*i.e.* the dorsal borders, anterior part of the cephalic lobes and posterior parts of the caudal) showed crepitant and emphysematous tissue mottled with irregular patches of consolidation varying in size; the red areas in many places, especially on drying, had a granular appearance and showed opaque whitish points, but no definite tubercles were seen in them from the surface; in the crepitant parts however discrete tubercles were seen.

On section the greater part of the left lung was consolidated; the right lung was also extensively consolidated but contained more crepitant lung tissue than the left; most of the consolidated tissue was distinctly composed of aggregated tubercles many with caseous centres, the rest was more homogeneous but contained scattered caseous foci; in the crepitant tissue there were discrete miliary caseating tubercles not numerous. All the larger bronchi appeared to be plugged with yellow tenacious muco-pus.

Thoracic Glands. — The bronchial and dorsal mediastinal glands were much enlarged, together weighing 8 oz.; they were firm and showed their cortices composed of dense yellowish-white slightly gritty caseous patches in a reddish-grey matrix; in places the cortex of some of the glands was almost uniformly caseous only a few small islands of grey tissue being seen; the other glands were not so extensively caseous and resembled the portal.

Heart, Pericardium and Pleura.—Normal.

Abdomen.

Omentum.—On the ventral surface there were two or three grey tubercles.

Parietal Peritoneum.—Normal.

Spleen.—The spleen was slightly enlarged, the vessels on the surface were congested, the pulp was closely beset with caseous tubercles with grey margins varying from 1 to rather more than 1·5 mm. in diameter.

Liver.—The liver was normal in size and general appearance; it showed under the capsule altogether about a dozen minute grey tubercles. On section a few minute tubercles were seen in the depth, some grey others caseous.

Portal Glands.—The portal glands were considerably enlarged; on section their cortices were composed of firm grey tissue mottled with small irregular yellow caseous patches containing here and there calcareous grains.

Kidneys.—In the cortex of each kidney on the surface as well as iu the depth there were scattered grey miliary tubercles with slightly opaque centres; twenty-five were counted on the surface of the left and seventeen on that of the right.

Suprarenal Bodies.—In the cortex of the left there were four and in that of the right nine small caseous tubercles.

Coeliac Glands.—Two were slightly enlarged and beset with caseous tubercles, another contained a few tubercles.

Renal Gland.—This gland was beset with discrete caseous tubercles.

Lumbar Glands.—One was beset with caseous tubercles others contained a few only.

Iliac Glands.—Each contained one or two caseous tubercles.

Alimentary Tract.

Tongue, Tonsils and Pharynx.—Normal.

Submaxillary Glands.—Each contained discrete caseous tubercles.

Retro-pharyngeal Glands. — The retro-pharyngeal glands contained a moderate number of irregular caseous tubercles up to 2 mm. in diameter.

Parotideal Glands.—There were a few caseous tubercles in each.

Intestines.—Throughout the whole length of the small intestine there were caseous tubercles in the Peyer's patches and under the mucous membrane.

They were rather numerous in the last few feet of the ileum, less numerous elsewhere, and in some parts very sparsely scattered.

There were a few caseous tubercles in the large intestine.

Mesenteric Glands.—All the mesenteric glands were enlarged to about twice the normal and showed their cortices composed of firm translucent grey tissue infiltrated with irregular yellow caseous patches and foci in some glands forming a coarse network; the medullary portions were oedematous.

Gastric Glands } These resembled the mesenteric
Ileo-colic Glands } glands.

Various Lymphatic Glands.

Precrural Glands.—The left showed in the cortex three, the right several caseous foci.

Popliteal Glands.—In the cortex of each there were scattered irregular yellow caseous foci.

Pudic Glands.—In the cortex of each there was a number of caseous tubercles.

Larynx and Trachea.—Normal.

Testicles.—Normal.

Microscopical Examination.

Emulsion of Bronchial Gland.—Tubercle bacilli moderately numerous.

Emulsion of Portal Gland.—Tubercle bacilli mode rately numerous.

Smear from a Tubercle from the Liver.—A few tubercle bacilli seen.

Muco-pus from a Bronchus.—Tubercle bacilli moderately numerous.

CALF 1535. Virus H. 53. "D.H." (*b*).

Subcutaneous inoculation of culture derived from the original material through Guinea-pig 3216.

Dose—50·0 milligrammes.

Date of Inoculation—January 21, 1909. [Age about 13 weeks.]

Killed when in good health—May 4, 1909. [103 days after inoculation.]

Clinical Notes.

The calf remained well during the experiment and increased normally in weight and size.

Temperature.

From the 4th to the 8th day following the inoculation the temperature was irregular; from the 9th to the 22nd day it was high (maximum 40·4° C.); from the 23rd to the 37th day the temperature was again irregular (maximum 39·8° C., minimum 38·1° C.). From the 38th day onwards until the animal was killed on the 103rd day the temperature was perfectly normal.

Weights.

	cwts.	lbs.
January 21, 1909	1	18
May 4, 1909	2	17

Total gain of weight.—3 qrs. 27 lbs.

Average rate of gain per week.—7·5 lbs.

POST-MORTEM EXAMINATION.

The carcass was fat.

Local Lesion.—At the seat of inoculation on the left side of the neck there was a pear-shaped fluctuating swelling measuring 16 by 10·5 by 7 cm.; on section it was thin-walled and filled with caseo-pus and breaking-down caseous masses. The skin was intact but very thin at one point.

Left Prescapular Gland.—The left prescapular gland measured 7 by 4·5 by 3·5 cm. and was composed throughout of dense pinkish-yellow caseous substance gritty around the margins; the capsule was much thickened all around the gland.

Right Prescapular Gland.—The right prescapular gland measured 5 by 2 by 1 cm. and contained two caseous nodules the largest the size of a hemp seed.

Prepectoral Glands.—On the left side one gland contained one minute calcareous tubercle, another a minute calcareous tubercle and a millet-seed sized caseo-calcareous tubercle.

On the right side one contained three calcareous tubercles, another contained two miliary caseo-calcareous tubercles.

Cervical Glands.—On the left side two of the lower cervical glands contained each one caseous tubercle; the upper cervical gland showed two caseous nodules the largest 2·5 mm. On the right side three glands contained each one caseous tubercle.

Thorax.

Lungs.—The lungs were crepitant and showed under the pleura very sparsely scattered minute calcareous tubercles, and also some minute grey foci which were not calcareous. No tubercles were seen on section.

Thoracic Glands.—The bronchial and mediastinal glands were not enlarged; they showed on section moderately numerous calcareous tubercles, in some of the glands aggregated together into small groups.

Pleura and Heart.—Normal.

Abdomen.

Omentum and Peritoneum.—Normal.

Spleen.—The spleen was normal in size; the pulp contained scattered calcareous tubercles the largest the size of a millet seed; the spleen was cut up into thin sections and altogether 35 tubercles were counted.

Liver.—No tubercles were seen on the surface or on section.

Portal Glands.—The portal glands were not enlarged, but contained moderately numerous small discrete calcareous tubercles.

There were similar tubercles in the pancreatic glands.

Coeliac Glands.—One, not enlarged, contained several minute calcareous tubercles.

Kidneys and Suprarenal Bodies.—Normal.

Renal Glands.—The renal glands contained scattered calcareous tubercles.

Lumbar Glands.—In each of four of the glands one or two calcareous foci were seen.

Iliac Glands.—In the left there were several minute calcareous tubercles; in the right there were four calcareo-caseous tubercles the largest the size of a millet seed.

Alimentary Tract.

Tongue, Pharynx, Tonsils.—Normal.

Retro-pharyngeal Glands.—In the right there was one and in the left about half-a-dozen caseous gritty tubercles.

Parotideal Glands.—The right contained about half-a-dozen, the left two, caseous nodules up to a hempseed in size.

Submaxillary Glands.—In the right there was one and in the left two caseo-calcareous tubercles.

Small Intestines.—The long Peyer's patch showed two foci of yellow pus; in another there was a millet-seed sized caseo-calcareous focus; in each of three others there was a small ulcer with calcareous particles projecting from the floor and another contained several yellow foci. Scattered about the mucous membrane of the intestine were slightly raised nodules with a small central ulcer and no sign of caseation.

Large Intestines.—The mucous membrane showed several small ulcers with raised thickened margins.

Mesenteric Glands.—Each mesenteric gland contained a few calcareous tubercles and in some there were small calcareous patches.

Ileo-colic Glands.—The ileo-colic glands contained a moderate number of small irregular calcareous tubercles.

Various Lymphatic Glands.

Axillary Glands.—In the left there were two small calcareous tubercles, in the right there were two millet-seed sized caseo-calcareous tubercles.

Precrural Glands.—The right showed in the cortex four caseous gritty nodules varying up to 2 mm. in diameter; in the left there were four similar nodules but the largest of these was 3 mm. in diameter.

Popliteal Glands.—In the left there were two and in the right four gritty caseous nodules the largest 2 mm. in diameter.

Ischiatic Glands.—In the right there was one calcareo-caseous tubercle; the left was normal.

Gluteal Glands.—There were three caseous gritty tubercles in the left; the right was normal.

Mamma.—The mamma was small; no tubercles were seen in the substance of the gland which for examination was cut up into thin strips.

The milk sinuses of the right fore quarter contained two or three cubic centimetres of purulent fluid; the fluid contained yellow shreds which were casts of the smaller ducts; on standing these fell to the bottom of the fluid leaving a slightly turbid supernatant fluid. There was no pus in the other quarters of the udder.

Supramammary Lymphatic Glands.—These showed in the cortices altogether ten caseous gritty nodules the largest 2 mm. in diameter.

About 10·0 cc. of saline solution were injected into the milk sinus of the left fore quarter, previous to the post-mortem examination, and about 5·0 cc. of slightly turbid fluid was recovered.

From the right fore (into which no saline was injected) less than 1·0 cc. of purulent fluid was obtained, previous to the post-mortem examination.

The milk sinuses of the hind quarters were washed out with saline and altogether about 4·0 cc. were recovered.

With these various fluids culture tubes were sown and guinea-pigs inoculated.

Smear Preparations.

Pus from R.F. quarter.—The pus consisted of leucocytes, lymphocytes and alveolar cells; the latter kind was nearly as numerous as the other two combined. Tubercle bacilli was sparsely scattered and one was found inside a leucocyte.

Saline fluids recovered from the hind quarters.—No tubercle bacilli in either.

Guinea-pigs Inoculated.

With pus from the R.F. quarter.—3749 Intrap.
With washings from the L.F. quarter.—3750 Intrap.
With washings from the R.H. quarter. { 3751 Intrap. / 3752 Intrap.

No. 3749 died in 77 days of general tuberculosis; the others were killed after 97 days and found healthy.

CALF 1545. Virus H. 53. "D.H." (*b*).

Subcutaneous inoculation of culture derived from the original material through Guinea-pig 3216.

Dose—50·0 milligrammes.

Date of Inoculation—January 21, 1909. [Age about 13 weeks.]

Died—March 14, 1909. [52 days after inoculation.]

Clinical Notes.

The course of the disease was similar to that usually seen in calves suffering from acute tuberculosis.

Temperature.

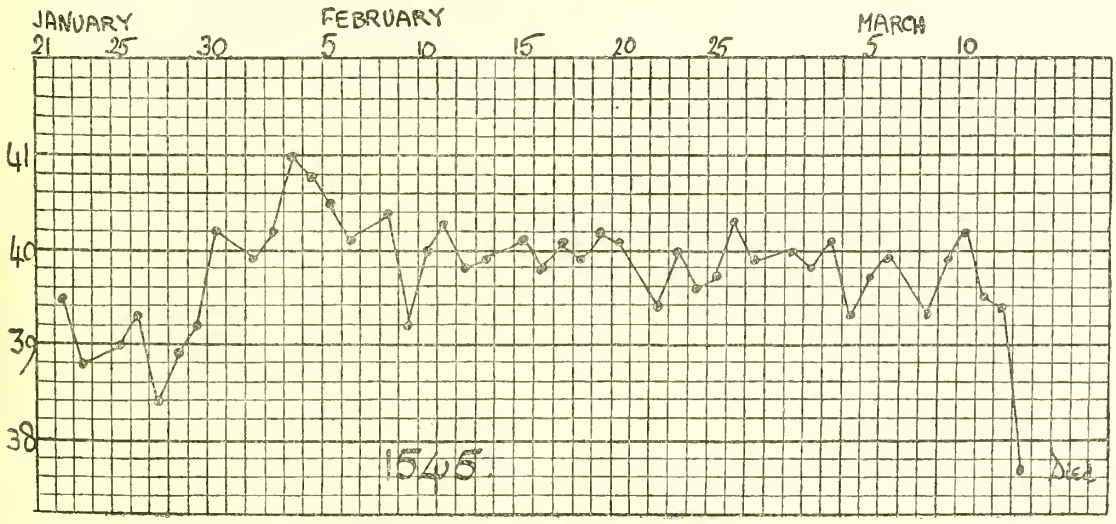

Weights.

	qrs.	lbs.
January 21, 1909	3	26
March 14, 1909	3	1

Total loss of weight.—25 lbs.

Average rate of loss per week.—3·3 lbs.

POST-MORTEM EXAMINATION.

The carcass was emaciated.

Local Lesion.—At the seat of inoculation on the left side of the neck there was a firm tumour measuring 16 cm. in length, 9 cm. in breadth, and 3·5 cm. in greatest thickness; it was composed of yellow caseo-necrotic substance containing irregular spaces filled with serous fluid; the mass was adherent to the skin and muscles both of which were infiltrated to a slight extent.

Left Prescapular Gland.—The left prescapular gland measured 9 by 5·8 by 4 cm. and was dense yellow and caseous practically throughout.

Right Prescapular Gland.—The right prescapular gland measured 4·7 by 2 by 1 cm., and showed in the cortex numerous irregular congested caseating nodules up to 3 mm. in diameter.

Prepectoral Glands.—On the left side the glands were slightly enlarged, deeply congested, and contained discrete irregular caseating nodules up to 3 mm. in diameter. The right prepectoral glands were similar.

Cervical Glands.—On the left side two, slightly enlarged, showed the cortices composed of confluent caseating nodules; the rest contained discrete caseating nodules; the glands on the right side contained caseating nodules similar to those on the left.

Thorax.

Pleura.—The fringes along the margins of the ribs were slightly hypertrophied and congested in places; no tubercles were visible.

Lungs.—The lungs weighed 4 lbs. 6 ozs. and were extensively hepatised, only a very little crepitant lung tissue remaining in the posterior parts of the caudal lobes and in the thin margins of the cephalic lobes: numerous yellowish foci were seen beneath the pleura. On section the lung substance was very closely beset with discrete yellowish tubercles ranging from a mere point up to 1 mm. in diameter; the tubercles appeared to be rather more numerous in the red solid parts than in the crepitant areas.

Thoracic Glands.—The bronchial and dorsal mediastinal glands were moderately enlarged; their cortices were firm and grey and closely infiltrated with irregular yellow caseous foci varying in size, in places forming a coarse network; the margins of the caseous foci were sharply defined.

Heart.—The endocardium of the right auricle showed two groups of greyish-white tubercles.

Abdomen.

Omentum.—Normal.

Peritoneum.—The peritoneum over the diaphragm showed one millet-seed-sized grey tubercle.

Spleen.—The spleen was slightly enlarged; there were no tubercles on the surface; the pulp contained moderately numerous yellow tubercles with grey margins, the largest the size of a millet seed; the trabeculae of the spleen were thickened and very stiff, cutting with difficulty.

Liver.—The liver was pale and firm; no tubercles were seen on the surface; on section one minute grey tubercle was seen.

Portal Glands.—The portal glands were enlarged; the cortices were grey and translucent and closely beset with yellow caseous tubercles.

Kidneys.—On the surface of each kidney there were scattered grey translucent submiliary tubercles; a few similar tubercles were seen on section in the depth of the cortex: in the medullary zones there were scattered grey miliary tubercles with opaque yellow centres up to a millet seed in size.

Suprarenal Bodies.—The cortex of the right contained seven, that of the left four grey miliary tubercles with minute opaque centres.

Alimentary Tract.

Pharynx.—The corrugated mucous membrane of the pharynx contained numerous caseous nodules.

Tonsils.—Each tonsil contained several caseous nodules up to 2·5 mm. in diameter.

Larynx and Trachea.—The mucous membrane of the larynx and trachea was congested but showed no tubercles.

The Submaxillary, Parotideal and Retro-pharyngeal Glands were deeply congested and contained numerous nodules with irregular yellow caseous centres and greyish-red margins; the nodules varied up to 3 and 4 mm. in diameter, and were in places becoming confluent.

Intestines.—All the Peyer's patches in the small intestine contained yellow caseous foci larger in the long terminal patch than in the others.

The mucous membrane of the large intestine showed scattered raised reddish spots, but there was no sign of caseation in the submucous tissue beneath.

Mesenteric Glands.—All the mesenteric glands were slightly enlarged; on section the cortices were firm grey and beset with caseous foci; they resembled the portal glands, but were not so advanced in caseation.

The Ileo-Colic Glands were similar to the mesenteric.

Various Lymphatic Glands.—All the peripheral lymphatic glands showed in the cortex numerous yellow caseous nodules with reddish-grey margins varying up to 3 mm. in diameter.

Lumbar and Renal Glands.—The nodules in these glands were more numerous than in the peripheral glands and had become confluent.

Eyes.—Normal.

Testicles.—Normal.

Microscopical Examination.

Focus from a Peyer's Patch in the Small Intestine.—Very numerous tubercle bacilli.

Scraping from the Liver.—No tubercle bacilli seen.

Emulsion of Portal Gland.—Very numerous tubercle bacilli.

CALF 1555. Virus H. 53. "D.H." (*b*).

Subcutaneous inoculation of culture derived from the portal gland of Calf 1507.

Dose—50·0 milligrammes.

Date of Inoculation—March 2, 1909.

Died (of pneumonia)—March 28, 1909. [26 days after inoculation.]

Temperature.

The temperature rose to 40·1° C. on the 13th day after inoculation and reached a maximum of 41·2° C. on the 16th day; it then fell rapidly to 37·5° C. (on the 25th day) and death ensued within 24 hours.

Weights.

	qrs.	lbs.
March 2, 1909	3	22
March 28, 1909	2	27

Loss of weight.—23 lbs.

POST-MORTEM EXAMINATION.

The carcass was emaciated.

Local Lesion.—In the subcutaneous tissues on the left side of the neck there was a flat patch of yellow caseo-necrotic substance, measuring 9 by 6·5 by 1·5 cm.; it was adherent to the skin and muscles, both of which were infiltrated to a slight extent.

Left Prescapular Gland.—The left prescapular gland measured 6·5 by 3·5 by 2 cm. and showed about half the cortex dense and caseating; the rest of the cortex was congested and contained scattered yellow foci.

Right Prescapular Gland.—The right prescapular gland measured 4·4 by 1·5 by 0·7 cm. The substance was congested but no tubercles were seen in it.

Prepectoral Glands.—The glands on the left side appeared normal, also those on the right.

Cervical Glands.—On the left side one in the lower part of the neck the size of a broad bean showed rather more than half its substance dense yellow and caseous; another near it had a small grey patch in the cortex; the rest appeared normal.

Thorax.

Lungs.—The cephalic lobes, the major portion of the right middle, and the left caudal lobes were dark red, firm, and quite airless; the rest of the lungs was crepitant, except for a small solid lobule here and there, and congested; there was a sharp line of demarcation between the crepitant and consolidated parts. The crepitant tissue showed on the surface numerous dark grey points and on section numerous just visible transparent points and early tubercles. The solid tissue was reddish-grey and in it no tubercles were visible.

Thoracic Glands.—The bronchial and dorsal mediastinal glands were moderately enlarged; all except the left bronchial were congested and firmer than normal; the left bronchial was soft. All the glands showed chiefly in the superficial part of the cortex scattered irregular yellow foci, many very ill-defined, and here and there patches composed of a fine yellow network.

Abdomen.

Spleen.—The spleen was small, soft, and atrophied; no tubercles were seen on section.

Intestines.—The mucous membrane of the small intestine was congested; no tubercles were seen. The large intestine was normal.

Mesenteric Glands.—The mesenteric glands showed on section scattered translucent grey bodies which stood up from the cut surface.

All the organs and glands not hitherto mentioned were examined and appeared normal.

Microscopical Examinations.

Scraping from solid Lung.—A moderate number of tubercle bacilli and blue bacilli.

Scraping from the Liver.—A few tubercle bacilli.

Scraping from the Spleen pulp.—Moderately numerous tubercle bacilli.

Scraping from the long Mediastinal Gland.—Very numerous tubercle bacilli.

Emulsion of a small Mediastinal Gland.—Very numerous tubercle bacilli.

Scraping from a Popliteal Gland.—Moderately numerous tubercle bacilli.

CALF 1559. Virus H. 53. "D.H." (*b*).

Subcutaneous inoculation of culture derived from the portal gland of Calf 1507.

Dose—50·0 milligrammes.

Date of Inoculation—April 29, 1909. [Age about 9 weeks.]

Killed when in good health—August 18, 1909. [111 days after inoculation.]

Clinical Notes.

The calf remained well during the experiment.

Temperature.

On the 9th day after inoculation the temperature rose to 40·4° C.; it remained above 40·0° C. for four days, and then slowly returned to the normal; the pyrexia lasted 12 days in all. Subsequently the temperature remained normal.

Tuberculin Test.

August 16, 1909. [109 days after inoculation.] Slight reaction. Rise of temperature, 0·8° C.

Weights.

	cwt.	qrs.	lbs.
April 29, 1909	1	0	7
August 18, 1909...	2	0	3

Total gain of weight.—3 qrs. 24 lbs.

Average rate of gain per week.—6·7 lbs.

POST-MORTEM EXAMINATION.

The carcass was in good condition.

Local Lesion.—At the seat of inoculation there was a firm lesion measuring 8 by 4·5 by 2 cm. composed of thickened skin 1 cm. in thickness and fibroid tissue beset with caseo-calcareous nodules; in the skin there was a healing ulcer.

Left Prescapular Gland.—The left prescapular gland measured 5·2 by 3 by 2·6 cm. and showed about half its cortex dense caseous and calcareous.

Right Prescapular Gland.—The right prescapular gland was enlarged (recent tuberculin test), measuring 5·5 by 2·4 by 1·2 cm., and showed in the cortex four caseous nodules up to a hemp seed in size.

Prepectoral Glands.—One on the left side contained a few caseous tubercles, two on the right each contained one calcareous tubercle.

Cervical Glands.—In each cervical gland there was a caseo-calcareous tubercle or two.

Thorax.

Lungs.—The lungs were crepitant throughout; just under the pleura one small calcareous tubercle was found; there were also three transparent bodies of a doubtful nature. On section the lungs were normal.

Thoracic Glands.—The bronchial and mediastinal glands were normal in size; they showed on section moderately numerous calcareo-caseous tubercles here and there aggregated together.

Heart and Pleura.—Normal.

Abdomen.

Omentum and Peritoneum; Spleen and Liver.—Normal.

Kidneys.—In the cortex of the left near the surface there were two small grey tubercles; the right was normal.

Suprarenal Bodies.—In the cortex of the right there was a millet-seed sized grey tubercle with a minute calcareous centre; the left was normal.

Portal Glands.—The portal glands were normal in size and showed on section scattered calcareous tubercles.

Coeliac Glands.—There were two miliary caseous tubercles in one and about half a dozen in another.

The Renal and Lumbar Glands each contained a few calcareo-caseous tubercles.

Iliac Glands.—There was one caseous tubercle in the gland on the left side; the right was normal.

Alimentary Tract.

Tongue, Pharynx, Tonsils.—Normal.

The Retro-pharyngeal, Parotideal, and the Left Submaxillary Glands contained each from one to three caseo-calcareous tubercles. The right submaxillary gland was normal.

Intestines.—In nine of the small Peyer's patches there were altogether twenty-four caseous tubercles; in the large patch there were scattered caseous tubercles.

The large intestine was normal.

Mesenteric Glands.—All these glands showed irregular calcareous tubercles in the cortex; in the glands at the extremities they were moderately numerous; in the others they were sparsely scattered.

Ileo-colic Glands.—These resembled the terminal mesenteric glands.

Testicles.—Normal.

Various Lymphatic Glands.

Axillary Glands.—Each contained a few minute tubercles.

Gluteal Glands.—The left contained two, the right three, caseo-calcareous tubercles.

Ischiatic Glands.—Normal.

Popliteal Glands.—There were about a dozen caseous tubercles up to a millet-seed in size in the right gland and rather more in the left.

Precrural Glands.—These were similar to the popliteal glands.

Pudic Gland.—One contained a millet-seed sized caseous tubercle.

CALF 1563. Virus H. 53. "D.H." (*b*).

Subcutaneous inoculation of culture derived from the small mediastinal gland of Calf 1555.

Dose—50·0 milligrammes.

Date of Inoculation—May 22, 1909. [Age about 7 weeks.]

Killed when very ill—August 17, 1909. [87 days after inoculation.]

Clinical Notes.

The calf was unwell during the latter period of the experiment; it looked thin and did not grow well, and had a poor appetite; the respirations had been gradually increasing in frequency during the last week or two of life. On the day it was killed it was very ill, and was unable to walk.

Temperature.

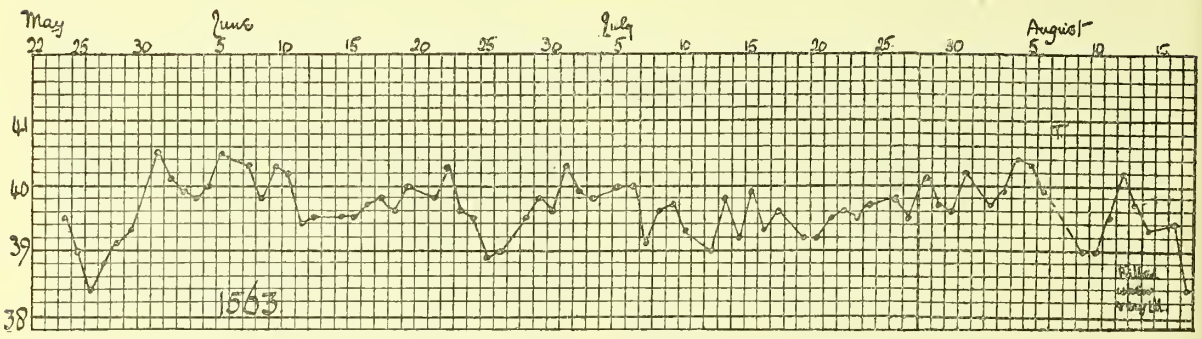

Weights.

	qrs.	lbs.
May 22, 1909	2	26
August 17, 1909	3	8

Total gain of weight.—10 lbs.

POST-MORTEM EXAMINATION.

The carcass was thin.

Local Lesion.—The lesion at the seat of inoculation was a lenticular mass of yellow caseo-necrotic substance measuring 11·5 by 8·5 by 4 cm. The muscle was infiltrated and the skin also, the latter nearly to the surface; the tumour showed in the centre a series of spaces filled with serous fluid.

Left Prescapular Gland.—The left prescapular gland measured 9·5 by 6 by 4 cm. and was composed throughout of dense pinkish-yellow gritty caseo-necrotic substance; the capsule was thickened.

Right Prescapular Gland.—The right prescapular gland measured 5 by 2 by 1·2 cm. and showed in the cortex a dozen or more firm yellow caseous nodules up to 6 mm. in diameter.

Prepectoral Glands.—On the left side one nearly 1·5 cm. in diameter was beset with caseous miliary tubercles; two others contained discrete caseous nodules. Those on the right side contained each a few caseous nodules.

Cervical Glands.—On the left side two, one the size of a walnut, the other about half that size, were dense and caseous throughout; the others were normal in size and contained a caseous nodule or two.

Axillary Glands.—In each there was a caseous tubercle or two.

Thorax.

Pleura.—The costal pleura was normal, the diaphragmatic pleura showed one grey tubercle.

Lungs.—The lungs weighed 3 lbs. 10 ozs.; the greater part of the right anterior lobe was firm dark red and airless, the ventral half of the right middle lobe was in a similar condition, in the other lobes lobules here and there were red and airless.

The lung parenchyma was moderately closely beset with caseating tubercles and nodules ranging from

1 to 3 or 4 mm. in diameter; the surfaces of the anterior lobes were studded with raised greyish-yellow nodules in places confluent; there were similar raised nodules on the surfaces of the caudal lobes, but less numerous. On section there were in different parts of the lung firm caseating masses affecting the whole or parts of lobules.

Thoracic Glands.—The bronchial and dorsal mediastinal glands together weighed 7 ozs.; their cortices were composed practically throughout of dense caseous gritty substance, only a small amount of oedematous gland tissue remaining.

Heart.—On the endocardium of the right auricle there was a number of minute grey tubercles; there were a few on the endocardium of the right ventricle. The heart muscle was normal.

Abdomen.

Omentum and Peritoneum.—The lymphatic fringes of the omentum were a little hypertrophied, there were no tubercles. The peritoneum was normal.

Spleen.—The spleen was small and contained numerous tubercles from 1 to 2 mm. in diameter, the pulp was atrophied and the trabeculae were stiff and thickened.

Liver.—The liver was closely and evenly beset with greyish-yellow tubercles varying from 0·5 to 1·5 mm. in diameter.

Portal Glands.—The portal glands were much enlarged and their cortices were composed of dense yellow caseous slightly gritty substance showing a scanty matrix of translucent grey tissue.

Coeliac Glands.—One was moderately large and was dense and caseous practically throughout and slightly gritty from calcification; five others much smaller showed more than half their substance replaced by firm caseous patches.

Kidneys.—The surface of each kidney was speckled with grey points which on section were found to be the terminations of fine grey streaks in the cortex; the cortex showed also scattered miliary caseous tubercles with grey margins.

Suprarenal Bodies.—There were four caseous slightly gritty tubercles (up to 1·5 mm.) in the cortex of the left and five in that of the right.

Alimentary Tract.

Tongue.—Normal.

Tonsils.—In each tonsil there were a few caseous nodules.

Pharynx.—In the corrugated mucous membrane of the pharynx there were a few caseous nodules.

The Submaxillary, Retro-pharyngeal and Parotideal Glands were enlarged and beset with caseous nodules in many places confluent.

Intestines.—All the Peyer's patches contained caseous nodules, the mucous membrane over the majority of which was ulcerated; there were also moderately numerous submucous nodules.

Under the mucous membrane of the large intestine there were numerous caseous tubercles distributed along its whole length.

The Gastric, Mesenteric, Ileo-colic, and Colic Glands were much enlarged; on section their cortices were caseating practically throughout; they closely resembled the portal glands.

Eyes.—In the iris of the right eye there was a caseous tubercle.

Larynx and Trachea.—Normal.

Various Lymphatic Glands.

Precrural Glands.—Each contained scattered firm caseous slightly gritty nodules, irregular in outline, ranging up to 3 mm. in diameter.

The Gluteal and Ischiatic Glands showed similar nodules.

Popliteal Glands.—There were similar nodules in these glands, the largest 4 mm. in diameter.

Iliac and Pudic Glands.—These contained nodules similar to those in the precrural glands, but more numerous.

Renal and Lumbar Glands.—In these glands the nodules were still more numerous and in places confluent.

Microscopical Examination.

Emulsion of Bronchial Gland.—Numerous tubercle bacilli.

Emulsion of Popliteal Gland.—Numerous tubercle bacilli.

Caseous Tubercle from Eye.—A moderate number of tubercle bacilli.

CALF 1599. Virus H. 53. "D.H." (*b*).

Subcutaneous inoculation of culture derived from the popliteal gland of Calf 1563.

Dose—50·0 milligrammes.

Date of Inoculation—October 6, 1909.

Killed when in good health—January 19, 1910. [105 days after inoculation.]

Clinical Notes.

The calf remained well during the experiment.

Temperature.

On the 10th day after inoculation the temperature rose to 39·9° C., and it reached 41·3° C. on the 15th day; the temperature then quickly fell and on the 21st day it was almost normal (39·2° C.). For a further period of over four weeks there was slight pyrexia (maximum 39·5° C.); during the remaining period of the experiment (7 weeks) the temperature was normal.

Weights.

	cwt.	qrs.	lbs.
October 6, 1909	1	1	7
January 19, 1910	2	0	3

Total gain of weight.—2 qrs. 24 lbs.

Average rate of gain per week.—5·3 lbs.

POST-MORTEM EXAMINATION.

The carcass was fat.

Local Lesion.—The local lesion measured 14 by 8·5 by 3·5 cm.; it was composed of a subcutaneous mass of fibroid tissue beset with calcareous tubercles and containing a small cavity or two filled with caseo-pus; the skin over it was thickened and the muscles under it were slightly infiltrated.

Left Prescapular Gland.—The left prescapular gland measured 7·5 by 4 by 3 cm.; the greater part (over three-quarters) was partly dense and caseous and partly fibrous and calcareous.

Right Prescapular Gland.—The right prescapular gland measured 4·5 by 2 by 1 cm. and was normal on section.

Prepectoral Glands.—On the left side one the size of a walnut was dense and caseating throughout; two others contained each a fibro-calcareous nodule.

Cervical Glands.—On the left side two were slightly enlarged and partly fibroid and calcareous; the rest were normal.

Thorax.

Lungs.—The lungs were crepitant throughout and showed on the surface a moderate number of evenly-distributed grey tubercles up to 1 mm. the majority

calcareous in the centre; the tubercles were much less numerous in the depth than on the surface.

Thoracic Glands.—The dorsal mediastinal and bronchial glands were slightly enlarged and showed scattered calcareous tubercles mostly minute and occurring chiefly in groups.

Abdomen.

Spleen.—The pulp showed moderately numerous grey translucent bodies up to a millet-seed in size, a few of which had calcareous centres.

Liver.—The liver showed throughout its substance numerous irregular yellow foci, some star-shaped, some with ill-defined margins; they appeared to be foci of fatty degeneration; besides these there were also sparsely-scattered submiliary calcareous tubercles with fibrous margins. Within a thickened bile-duct there was a parasite which appeared to be a small liver fluke.

Coeliac Glands.—Two small glands contained a group or two of calcareous tubercles, two others a few calcareous grains.

Portal Glands.—In the cortex of each there were scattered calcareous tubercles.

Kidneys.—In the medulla of the right kidney there was a millet-seed sized grey tubercle; the left was normal.

Suprarenal Bodies.—In the cortex of the left there was a hempseed-sized caseous nodule with grey fibrous margin. In that of the right there were two nodules smaller than a hempseed.

Lumbar and Renal Glands.—A few calcareous tubercles were found in each.

Alimentary Tract.

Intestines.—The small intestines were normal. In the upper part of the large intestines several small ulcers with raised thickened margins and clean floors were seen.

Mesenteric and Ileo-colic Glands.—Each contained a few calcareous tubercles, occurring chiefly in small groups.

The remaining organs (including the mamma) and glands were examined and found normal.

Microscopical Examination.

Irregular Foci from Liver.—No tubercle bacilli.

Calcareous Tubercle from Liver.—No tubercle bacilli.

A very small amount of opalescent fluid was obtained from each of the mammary sinuses.
- *Fluid from L.F. Quarter of Udder.*—No tubercle bacilli.
- *Fluid from R.F. Quarter of Udder.*—No tubercle bacilli.
- *Fluid from L.H. Quarter of Udder.*—One tubercle bacillus seen.
- *Fluid from R.H. Quarter of Udder.*—No tubercle bacilli.

CALF 1561. Virus H. 53. "D.H." (*b*).

Subcutaneous inoculation of culture derived from the portal gland of Calf 1545.

Dose—50·0 milligrammes.

Date of Inoculation—May 6, 1909. [Age 10 weeks.]

Killed when dying—June 14, 1909. [39 days after inoculation.]

Clinical Notes.

About the beginning of the third week after inoculation the respiration began to increase in frequency and the animal was noticed to be ill. It gradually lost flesh and appetite and on May 30 presented all the usual signs of an acute tuberculous infection. The calf remained very ill for three days; on the fourth day there was a slight improvement in its general condition, which was maintained for several days. At the beginning of the second week in June the calf again became very ill, the respiration was rapid and the animal emaciated, and it was killed when in a dying condition on June 14.

Temperature.

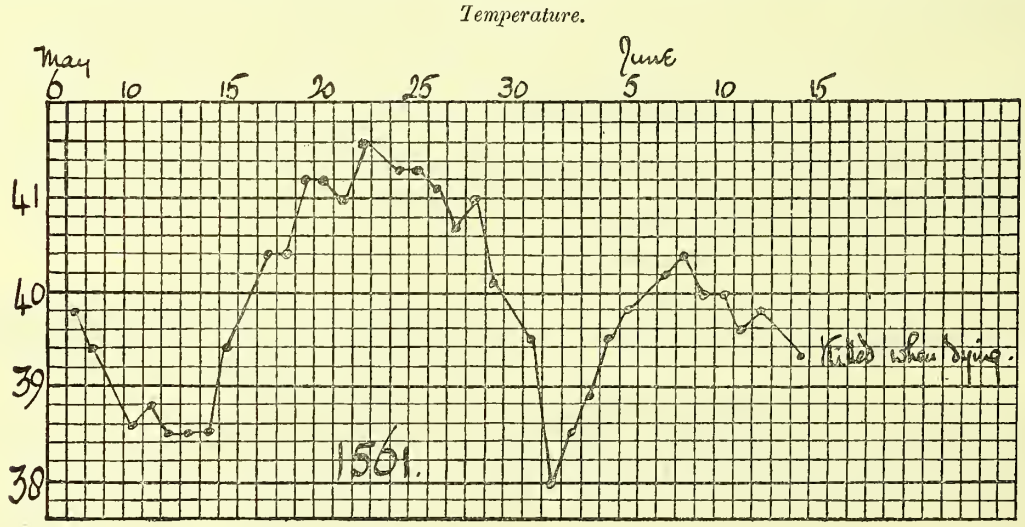

Weights.

	cwt.	qrs.	lbs.
May 6, 1909	1	0	18
June 14, 1909	0	3	24

Total loss of weight.—22 lbs.

Average rate of loss per week.—4 lbs.

POST-MORTEM EXAMINATION.

The carcass was emaciated.

Local Lesion.—On the left side of the neck at the seat of inoculation there was an elongated firm tumour measuring 16 by 5·5 by 2 cm. composed of firm yellow caseo-necrotic substance infiltrating skin and muscles.

Left Prescapular Gland.—The left prescapular gland measured 9 by 5 by 2·7 cm. and was composed partly of dense homogeneous pinkish-yellow caseous necrotic substance, partly of firm grey tissue closely beset with caseous foci, and partly of oedematous glandular tissue; more than three-quarters of the gland was tuberculous.

Right Prescapular Gland.—The right prescapular gland measured 4·2 by 1·5 by 0·9 cm. and showed in the cortex a moderate number of caseous tubercles.

Prepectoral Glands.—On the left side one gland contained a caseous tubercle. On the right side two glands contained one caseous tubercle each.

Cervical Glands.—On the left side the lower gland was slightly enlarged and showed in the cortex grey patches closely beset with caseous tubercles; the upper cervical glands contained several caseating tubercles up to 2 mm.; in the rest which were not enlarged there were one or two small tubercles.

Thorax.

Pleura.—There were six caseating tubercles on the costal pleura.

Lungs.—The lungs did not collapse on opening the chest; they were heavy, weighing six pounds. The lung parenchyma was packed almost as closely as possible with grey miliary tubercles with caseous centres; nearly the whole of the cephalic lobes and more than half of each caudal lobe was red solid and airless; along the dorsal borders of each lung and in the posterior parts of each caudal lobe the tissue was air-containing and the tubercles did not appear to be so numerous as in the solid portions; they were however in many places closely aggregated together and replaced most of the tissue of many of the lobules.

Thoracic Glands.—The bronchial and mediastinal glands were much enlarged together weighing 9 ozs.; they were firm and their cortices were composed of reddish-grey tissue closely infiltrated with irregular caseous foci forming everywhere a coarse yellow network.

Heart.—There were three millet-seed sized caseating tubercles in the wall of the right auricle.

Abdomen.

Omentum.—There were five loosely-attached grey tubercles on the omentum.

Peritoneum.—Normal.

Spleen.—The spleen was normal in size; the trabeculae were thickened and the pulp contained moderately numerous tubercles with caseous centres and grey margins, the largest the size of a millet seed.

Liver.—The substance of the liver was closely and evenly beset with opaque greyish-white submiliary tubercles.

Portal Glands.—The portal glands were enlarged and very oedematous; their cortices were composed of firm grey tissue closely infiltrated with irregular caseous foci.

Coeliac Glands.—The coeliac glands were slightly enlarged, the cortices were grey and in a state of early caseation.

Kidneys.—In the cortex of each kidney there was a moderate number of grey tubercles 1–2 mm. in diameter, the smaller ones slightly opaque in the centre, the larger ones definitely caseous.

Suprarenal Bodies.—In the cortex of the right there was one and in that of the left three yellow caseous tubercles.

Lumbar and Renal Glands.—The cortices of these glands were closely beset with irregular caseous tubercles.

Iliac Glands.—The iliac glands showed in the cortices a moderate number of caseating tubercles ranging up to 2 mm. in diameter.

Alimentary Tract.

Tongue, Tonsils.—Normal.

Pharynx.—There was one submucous tubercle in the pharynx.

The Parotideal, Submaxillary and Retro-pharyngeal Glands contained moderately numerous caseating tubercles tending to occur in groups.

Intestines.—Almost every Peyer's patch contained scattered caseous tubercles.

The large intestine was normal.

Mesenteric Glands.—Each gland contained moderately numerous caseating tubercles and in some there were caseating nodules and grey caseating patches.

The Ileo-colic and Colic Glands contained similar tubercles.

Testicles.—In the right testicle there was one grey miliary tubercle; the left was normal.

Eyes.—Normal.

Various Lymphatic Glands.

The Precrural and Popliteal Glands and Gluteal and Ischiatic Glands each showed in the cortices a moderate number of caseating tubercles ranging up to 2 mm. in diameter.

The Axillary and Pudic Glands each contained a moderate number of grey miliary tubercles with caseous centres.

Many haemo-lymph glands contained a tubercle or two.

Microscopical Examination.

Emulsion of small Mediastinal Gland.—Tubercle bacilli moderately numerous.

CALF 1571. Virus H. 53. "D.H." (*b*).

Subcutaneous inoculation of culture derived from the small mediastinal gland of Calf 1561.

Dose—50·0 milligrammes.

Date of Inoculation—July 15, 1909. [Age about 15 weeks.]

Killed when in good health—November 3, 1909. [111 days after inoculation.]

Clinical Notes.

The calf remained well during the experiment and grew normally.

Temperature.

The temperature remained normal, the range of variation for the four months during which the experiment lasted being only 1·2° C. (maximum 39·2° C., minimum 38·0° C.).

Tuberculin Tests.

August 16, 1909. [32 days after inoculation.] Dose: 2·0 cc. Reacted. Rise of temperature: 1·6° C.

October 29, 1909. [106 days after inoculation.] Dose: 2·0 cc. Reacted. Rise of temperature: 1·3° C.

Weights.

	cwt.	qrs.	lbs.
July 15, 1909	1	1	4
November 3, 1909	2	2	0

Total gain of weight.—1 cwt. 0 qrs. 24 lbs.

Average rate of gain per week.—8·5 lbs.

POST-MORTEM EXAMINATION.

The carcass was fat.

Local Lesion.—On the left side of the neck there was a small swelling measuring 6 by 4 by 3 cm.; on section it was composed of skin 1 cm. in thickness and a cyst with thick fibrous walls and caseous partially softened contents.

Left Prescapular Gland.—The left prescapular

gland measured 6·8 by 3·5 by 2 cm. and showed about two-thirds of its substance, mainly the medulla, caseo-calcareous and partially softened; in the normal parts of the cortex there were scattered calcareous foci.

Right Prescapular Gland.—The right prescapular gland measured 6·5 by 2·9 by 1·3 cm.; it was oedematous and showed no tubercles (enlargement due to recent tuberculin inoculation).

Prepectoral Glands.—On the right side one contained a calcareous focus, the rest were normal.

Cervical Glands.—One of the lower cervical glands on the left side the size of a small pea showed a small calcareous patch in the cortex. The rest were normal.

Thoracic Glands.—The thoracic glands were normal in size; the bronchial and dorsal mediastinal glands each contained very sparsely scattered minute calcareous foci, the majority just visible to the naked eye.

Spleen.—The spleen pulp showed two pinhead-sized tubercles with calcareous centres and one grey tubercle without a calcareous centre.

Portal Glands.—A minute calcareous focus was found in each of two of the glands.

Coeliac Glands.—One contained a minute calcareous focus.

Suprarenal Bodies.—In the cortex and partly in the medulla of the right suprarenal body there was a caseous gritty nodule with a broad grey margin, 5 mm. in diameter.

Ileo-colic Glands.—Two minute caseous foci were found in these glands.

There was no sign of tuberculosis in the organs and glands not mentioned above.

Microscopical Examination.

Saline was injected into the milk sinus of each quarter of the udder previous to the post-mortem examination, and the fluid which was recovered was examined microscopically. The four smears examined (one from the fluid from each quarter) all showed numerous cells, mainly glandular, a few squamous; there were no tubercle or other bacilli.

Guinea-pigs Inoculated.

Nos. 3900 (intrap.) and 3901 (subcut.) were inoculated with an emulsion of a portion of the left caudal lobe of the lung (dose 5·0 cc. each).

Nos. 3902 (intrap.) and 3903 (subcut.) were inoculated with an emulsion of a portion of the right caudal lobe (dose 4·5 cc. each).

One died in 5 days of an acute infection, the other three were killed after 63 days and found healthy.

Four guinea-pigs were each inoculated intraperitoneally with rather less than 1·0 cc. of fluid recovered from the milk sinuses of Calf 1571 after injecting about 3·0 cc. of saline solution. The recovered fluid was very slightly milky.

Fluid from R.F. quarter. 3904.
Fluid from R.H. quarter. 3906.
Fluid from L.F. quarter. 3907.
Fluid from L.H. quarter. 3905.

No. 3904 died in 13 days, the remaining three were killed after 62 days; all were free from tuberculosis.

RHESUS MONKEY 265. Virus H. 53. "D.H." (*b*).

Subcutaneous inoculation of culture derived from the original material through Guinea-pig 3216.

Dose—1·0 milligramme.

Date of Inoculation—January 21, 1909.

Died—February 4, 1909. [14 days after inoculation.]

POST-MORTEM EXAMINATION.

Nothing was found to account for the death of the animal.

In the subcutaneous tissues of the back there was a small patch of yellow caseo-pus.

The nearest glands were normal

The organs and glands of the thorax and abdomen were perfectly normal to the naked eye.

RHESUS MONKEY 267. Virus H. 53. "D.H." (*b*).

Subcutaneous inoculation of culture derived from the original material through Guinea-pig 3216.

Dose—1·0 milligramme.

Date of Inoculation—January 21, 1909.

Died—February 23, 1909. [33 days after inoculation.]

Clinical Notes.

The monkey died after a week's illness, characterized by extreme weakness and loss of appetite.

The weight at death was 1950 grammes.

POST-MORTEM EXAMINATION.

The carcass was in poor condition.

Local Lesion.—Near the angle of the right scapular there was an oval ulcer 4 cm. in length with considerably undermined margins and pale granular floor covered with ill formed pus.

Axillary Glands.—On the left side there were two glands the size of kidney beans which were caseous and softened practically throughout. Two other glands were slightly enlarged but were otherwise normal.

On the left side the glands were normal.

Cervical Glands.—On the right side one the size of a hemp seed was caseous throughout. Other cervical glands were normal.

Vertebral Glands.—On the right side the gland in the 7th interspace the size of a split pea was caseous throughout; one in the 8th and one in the 9th interspaces on this side contained each a caseous tubercle. The rest were normal.

Thorax.

Lungs.—The lungs were crepitant throughout, and contained sparsely scattered caseous tubercles the largest the size of a millet seed.

Bronchial Glands.—The bronchial glands were not enlarged, they contained each a few miliary caseous tubercles.

Abdomen.

The peritoneal cavity contained a slight excess of clear fluid.

Spleen.—The spleen was normal in size and showed in the pulp a moderate number of miliary tubercles, a few caseous, the rest grey and translucent.

Liver.—The liver contained a moderate number of evenly distributed caseous tubercles, the largest 1 mm. in diameter.

Pancreatic Glands.—Three glands near the head of the pancreas were slightly enlarged and contained discrete caseous tubercles.

The remaining organs and glands were examined and found normal.

RHESUS MONKEY 289. Virus H. 53. "D.H." (*b*).

(A young animal.)

Subcutaneous inoculation of culture derived from the original material through Guinea-pig 3216.

Dose—1·0 milligramme.

Date of Inoculation—April 1, 1909.

Died—May 6, 1909. [35 days after inoculation.]

Clinical Notes.

The monkey died prematurely, apparently of cold. The weight at death was 1170 grammes.

POST-MORTEM EXAMINATION.

The carcass was thin.

Local Lesion.—The skin over the right scapula showed an elongated ulcer 5·5 cm. in length and 2·5 cm. in greatest breath; the skin around the margins was in places considerably undermined; the exposed floor of the ulcer was dry and covered with a thin dry scab; the floor concealed by skin was granular and showed caseo-pus.

Axillary Glands.—On the right side one the size of a pea was caseous throughout, another rather larger was partly caseous. The glands on the left side were normal.

Cervical Glands.—On each side in the posterior triangle there was a hemp-seed sized caseous gland.

Vertebral Glands.—On the right side in the 7th to 9th interspaces there were three caseous glands, the largest 5 mm. in diameter.

Inguinal Glands.—One on the right side showed an early caseous patch in the cortex; the rest were normal.

There was no sign of tuberculosis elsewhere.

Microscopical Examinations.

Smears from cut surface of Spleen.—Tubercle bacilli numerous.

Smear from cut surface of Liver.—Tubercle bacilli sparsely scattered.

Smear from cut surface of Lung.—A moderate number of tubercle bacilli.

Cerebral Fluid.—A few tubercle bacilli.

RHESUS MONKEY 291. Virus H 53. "D.H." (*b*).

(A young animal.)

Subcutaneous inoculation of culture derived from the original material through Guinea-pig 3216.

Dose—1·0 milligramme.

Date of Inoculation—April 1, 1909.

Died—May 5, 1909. [34 days after inoculation.]

Clinical Notes.

The monkey died after a short illness, probably of cold. The weight at death was 1250 grammes.

POST-MORTEM EXAMINATION.

The carcass was thin.

Local Lesion.—In the subcutaneous tissues over the right scapula there was a large abscess filled with caseo-pus and caseo-necrotic masses; the skin over it was thinned and showed a small opening discharging pus.

Axillary Glands.—On the right side two were enlarged, the largest being the size of a pea and partly caseous; the others showed no sign of caseation.

Cervical Glands.—In the right posterior triangle there was a caseous and softened gland 8 mm. in diameter; another near it was enlarged but not caseous. Other cervical glands were normal.

Vertebral Glands.—On the right side there was a chain of caseous and softened glands extending from the first to the ninth rib; the largest was 1 cm. in diameter.

Lungs.—The lungs were crepitant and showed on the surface three small grey tubercles; none was seen on section.

Tracheal Gland.—On the right side of the trachea there was an enlarged caseous and softened gland.

Spleen.—The spleen was normal in size and showed in the pulp sparsely scattered submiliary grey tubercles.

There was no sign of disease elsewhere.

Microscopical Examination.

Smear from a Spleen Tubercle.—Tubercle bacilli moderately numerous. Large diplo-bacilli and slender bacilli stained blue were seen, the large bacilli appeared to be capsulated.

RHESUS MONKEY 277. Virus H. 53. "D.H." (*b*).

(A young animal.)

Subcutaneous inoculation of culture derived from the portal gland of Calf 1507.

Dose—1·0 milligramme.

Date of Inoculation—March 26, 1909.

Died—May 16, 1909. [51 days after inoculation.]

POST-MORTEM EXAMINATION.

The carcass was emaciated; its weight was 1550 grammes.

Local Lesion.—At the seat of inoculation, just below the right scapula, there was an ulcer measuring 5 by 5 cm., the floor of which was covered with soft greenish-brown substance; the skin at the margins of

the ulcer was slightly thickened and inverted; the skin and muscles were not infiltrated.

Axillary Glands.—The axillary glands on both sides were enlarged. Two on the right together measured 2 cm. in diameter and were soft and caseous throughout; one on the left measured 1·2 cm. and was similar to those on the right, another contained in the cortex two millet-seed sized caseous tubercles.

Cervical Glands.—In the right posterior triangle there was a pea-sized caseous gland and one which contained a millet-seed sized caseous tubercle; the glands on the left side were normal.

Vertebral Glands.—On the right side the glands in the 7th and 8th interspaces were enlarged, each measuring 9 mm. in diameter, and yellow softened and caseous throughout.

Thorax.

Lungs.—The lungs were crepitant; on their surfaces and throughout their substance were moderately numerous evenly distributed tubercles varying in size from a small translucent grey point up to about 1·5 mm., the majority being about 1 mm. in diameter, yellowish with grey margins.

Bronchial Glands.—The bronchial glands were enlarged, one contained a softened caseous nodule a little larger than a hemp seed, others contained discrete and confluent caseous tubercles in their cortices.

Heart and Pleura.—Normal.

Abdomen.

Omentum and Meso-colon.—In the omentum and meso-colon there were about half-a-dozen opaque caseous tubercles, varying in diameter from 1 to 1·5 mm.

The Parietal Peritoneum was normal.

Spleen.—The spleen was much enlarged and measured 7 by 3·6 by 1·6 cm.; the pulp was packed with soft yellowish-white caseous nodules ranging from 1 to 3 mm. in diameter.

Splenic Lymphatic Glands.—One contained a millet-seed sized caseous tubercle.

Liver.—The liver showed a moderate number of yellow caseous tubercles scattered over the surfaces, the majority being rather less than 1 mm., and a few rather more than 1 mm. in diameter. Section showed a moderate number of similar tubercles, the larger ones were somewhat firm with a soft caseous centre.

Portal Glands.—The portal glands were enlarged and closely beset with discrete miliary caseous tubercles.

Pancreatic Glands.—One showed a millet-seed sized caseous tubercle, and the other was composed of confluent caseous tubercles throughout.

Kidneys.—On the surface of the left 12 yellowish miliary tubercles were counted, and there were five seen in the cortex on section.

On the surface of the right there were six similar tubercles, and there were two in the depth of the cortex.

Suprarenal Bodies.—Normal.

Alimentary Tract.

Tongue, Pharynx, Tonsils.—Normal.

The Submaxillary Gland on either side contained a millet-seed sized caseous tubercle.

Intestines.—Normal.

The Mesenteric Glands were not enlarged and showed four caseous tubercles from 1 to 2 mm. in diameter.

Ileo-Colic Glands.—Four contained each one millet-seed sized caseous tubercle.

Colic Glands.—One contained a single similar tubercle, the rest were normal.

Inguinal Glands.—The inguinal glands were enlarged; in the right there were five yellowish-white caseous tubercles, the largest measuring 2 mm. in diameter, and one similar tubercle 1 mm. in diameter was seen in the left.

RHESUS MONKEY 279. Virus H. 53. "D.H." (*b*).

(A young animal.)

Subcutaneous inoculation of culture derived from the portal gland of Calf 1507.

Dose—1·0 milligramme.

Date of Inoculation—March 26, 1909.

Died—May 22, 1909. [57 days after inoculation.]

POST-MORTEM EXAMINATION.

The carcass was emaciated; its weight was 1850 grammes.

Local Lesion.—The skin over the right scapula showed a dry circular ulcer 3 cm. in diameter the margins of which were undermined, the undermined skin concealing caseo-pus; in the subcutaneous and muscular tissues around the margins of the ulcer were discrete caseous tubercles.

Axillary Glands.—On the right side one 2 cm. in greatest diameter was caseous throughout, another about the same size was partly caseous, two others were beset with discrete caseous tubercles.

On the left side two contained each a few caseous tubercles.

Cervical Glands.—On the right side two the size of small peas were caseous throughout, three others contained discrete caseous tubercles. The glands on the left side were normal.

Vertebral Glands.—Not noted.

Thorax.

Lungs.—The lungs were expanded and showed no areas of collapse; the tissue was firmer than normal and closely beset with discrete shotty caseous tubercles with grey margins 1 to 2 mm. in diameter.

The Bronchial Glands were slightly enlarged and contained discrete caseous tubercles.

Heart.—There was one millet-seed sized caseous tubercle in the muscle of the left ventricle.

Abdomen.

Omentum.—The omentum showed very numerous tubercles ranging up to a pin's head in size, the larger ones caseous in the centre, the smaller ones which were the most numerous grey and translucent.

The Parietal Peritoneum and the Mesentery were normal.

On the Mesocolon there were moderately numerous tubercles similar to those in the omentum.

Spleen.—The spleen was enlarged measuring 5·5 by 3 by 2 cm. and showed on the surface numerous projecting caseous nodules up to 2·5 mm. in diameter to which the omentum was adherent ; on section the pulp showed numerous discrete softened caseous nodules, the largest 2·5 mm. in diameter.

Splenic Lymphatic Glands.—Normal.

The Gastric, Cardiac and Pyloric Glands and the gland on the head of the pancreas were enlarged and their cortices closely beset with caseous tubercles.

Liver.—The liver was normal in colour and firmness and contained a moderate number of evenly distributed yellow caseous tubercles the largest the size of a millet seed.

Kidneys.—In the cortex of each kidney there was a moderate number of tubercles up to 1·5 mm. in diameter showing a varying amount of central caseation ; twenty were counted on the surface of the left, and there were rather more on that of the right.

Suprarenal Bodies.—Normal.

Iliac and Lumbar Glands.—There were two or three minute grey tubercles in the iliac glands.

The lumbar glands were slightly enlarged and showed in the cortex discrete caseous tubercles.

Alimentary Tract.

Tongue, Pharynx, Tonsils.—Normal.

Submaxillary Glands.—Those on the right side contained a few caseous tubercles ; those on the left were normal.

Retro-pharyngeal Glands.—The left contained a caseous tubercle ; the right was normal.

Intestines.—Normal.

Mesenteric Glands.—The mesenteric glands were not enlarged : they contained two or three yellow caseous tubercles.

The Ileo-colic and Colic Glands appeared normal.

The Right Inguinal Glands contained a few small caseous tubercles.

RHESUS MONKEY 325. Virus H. 53. "D.H." (*b*).

(A young animal.)

Subcutaneous inoculation of culture derived from the small mediastinal gland of Calf 1555.

Dose—1·0 milligramme.

Date of Inoculation—May 22, 1909.

Died—July 20, 1909. [59 days after inoculation.]

POST-MORTEM EXAMINATION.

The carcass was emaciated. Its weight was 1350 grammes.

Local Lesion.—The skin over the right scapula showed an ulcer 3 by 2 cm. in area, with thickened slightly undermined margins, dry glazed floor, and base formed by muscles closely beset with caseous tubercles confluent under the skin margins.

Axillary Glands.—On the right side there were six enlarged completely caseous glands ranging from 0·7 to 1·5 cm. in diameter. On the left side one the size of a pea was three-quarters caseous.

Cervical Glands.—On the right side in the posterior triangle there were two pea-sized caseous glands.

On the left side one in a similar situation the size of a small pea was partly caseous.

Vertebral Glands.—The gland in the seventh interspace on the right side the size of a split pea was caseous throughout.

Thorax.

Pleura.—There was one minute caseous tubercle on the costal pleura.

Lungs.—The lungs were voluminous and completely filled the thorax. They were firm, emphysematous around the margins, and irregularly but extensively consolidated ; they were closely beset with caseous tubercles with grey margins, the largest 2 mm. in diameter.

Bronchial Glands.—The bronchial glands were slightly enlarged and congested and contained each two or three yellow caseous tubercles.

Heart and Pericardium.—The heart muscle and valves were normal. The pericardial sac contained an excess of fluid.

Abdomen.

Omentum and Peritoneum.—The omentum showed sparsely scattered miliary grey tubercles. The parietal peritoneum was normal.

Spleen.—The spleen was greatly enlarged measuring 8 by 4 by 2·3 cm. and was packed almost as closely as possible with caseous and softened nodules ranging up to 5 mm. in diameter in many places confluent.

The splenic lymphatic glands were slightly enlarged and contained each a few caseous tubercles.

Liver.—The liver was normal in colour and showed moderately numerous evenly distributed caseous tubercles ranging up to a millimetre in diameter.

The gland on the head of the pancreas was slightly enlarged and showed in the cortex discrete miliary caseous tubercles.

Kidneys.—The left kidney showed in the cortex just beneath the capsule two minute caseous tubercles ; in the right there were about half-a-dozen tubercles, the largest the size of a millet seed.

Suprarenal Bodies.—Normal.

Lumbar and Iliac Glands.—The lumbar glands contained a few caseous tubercles and there was one in one of the iliac glands.

Mesenteric Glands.—The mesenteric glands contained two or three caseous tubercles.

Colic Glands.—One contained a caseous tubercle.

Submaxillary Glands.—The submaxillary glands on each side contained two or three caseous tubercles.

Other organs and glands were examined and found normal.

RHESUS MONKEY 327. Virus H. 53. "D.H." (*b*).

(A young animal.)

Subcutaneous inoculation of culture derived from the small mediastinal gland of Calf 1555.

Dose—1·0 milligramme.

Date of Inoculation—May 22, 1909.

Died—July 29, 1909. [68 days after inoculation.]

POST-MORTEM EXAMINATION.

The carcass was emaciated; its weight was 1700 grammes.

Local Lesion.—In the subcutaneous tissues over the right scapula there was a large flat space 5 cm. in diameter containing a small quantity of ill-formed pus; the skin over it was thinned and showed many ulcerous openings; the muscles under it and for some distance around it were beset with caseous nodules.

Axillary Glands.—On the right side two were enlarged to the size of a thrush's egg and were caseous and softened throughout. Those on the left side were normal.

Cervical Glands.—In the right posterior triangle two the size of large peas were caseous and softened throughout; in the left one gland contained a pinhead-sized caseous tubercle; a small midcervical gland on the left side was partly caseous.

Vertebral Glands.—The vertebral glands on the right side in the 4th to the 10th interspaces were much enlarged (especially those in the 8th, 9th and 10th), caseous and softened thoughout; on the left side one in the 7th and one in the 11th interspaces contained each a hemp-seed sized caseous nodule.

Thorax.

Lungs.—The lungs were voluminous and crepitant throughout with the exception of a few irregular patches of collapse. The right caudal lobe was adherent to the enlarged vertebral glands. The lung parenchyma was closely and evenly beset with shotty miliary caseous tubercles which stood up from the cut surface.

Bronchial Glands.—The bronchial glands were slightly enlarged and contained each a few caseous nodules up to 2·5 mm. in diameter.

Abdomen.

Omentum.—The omentum showed numerous pearly-grey tubercles.

Spleen.—The spleen was much enlarged measuring 7 by 4·5 by 2 cm. and was beset almost as closely as possible with softened caseous nodules up to 3 mm. in diameter.

One splenic lymphatic gland contained a caseous tubercle.

Liver.—The liver contained a moderate number of caseous tubercles ranging from a mere point up to 1·5 mm. in diameter.

The Gastric Glands and the glands on the head of the pancreas were enlarged and their cortices closely beset with caseous nodules.

The Lumbar Glands resembled the gastric.

Kidneys.—The left kidney showed in the cortex about half-a-dozen caseous tubercles the largest the size of a millet seed; in the right there were caseous tubercles up to 2 mm. in diameter twice as numerous as in the left.

The Iliac Glands contained about half-a-dozen caseous tubercles.

Alimentary Tract.

Tongue.—Normal.

Tonsils.—The left tonsil was caseous, the right was normal.

Retro-pharyngeal and Submaxillary Glands.—Both pharyngeal glands contained caseous tubercles; there were two caseous tubercles in the submaxillary glands on the left side and three in those on the right; the left submaxillary salivary gland contained a pinhead-sized caseous tubercle.

Intestines.—Normal.

Mesenteric, Ileo-colic, and Colic Glands.—The mesenteric gland contained four caseous nodules; one ileo-colic gland contained a millet-seed sized caseous tubercle, and two or three of the colic glands each contained a tubercle.

On the dura mater between it and the left parietal bone there was a caseous tubercle. The brain was normal.

Inguinal Glands.—There was a caseous tubercle in each group of inguinal glands.

The remaining organs and glands were examined and found normal.

RHESUS MONKEY 317. Virus H. 53. "D.H." (*b*).

(A young animal.)

Subcutaneous inoculation of culture derived from the portal gland of Calf 1545.

Dose—1·0 milligramme.

Date of Inoculation—May 6, 1909.

Died—June 21, 1909. [46 days after inoculation.]

POST-MORTEM EXAMINATION.

The carcass was thin; its weight was 2000 grammes.

Local Lesion.—The skin over the last dorsal vertebrae showed an irregular ulcer measuring 3·5 by 2 cm. with undermined thickened margins and smooth reddish floor; in the tissues under the skin margins there were a few softened and caseous nodules.

Axillary Glands.—Two glands on each side were much enlarged, caseous and softened throughout; several others contained discrete caseous nodules.

Cervical Glands.—One cervical gland on each side in the posterior triangle contained a caseous tubercle.

Vertebral Glands.—On the right side three glands in the 10th to the 12th interspaces were enlarged, caseous, and softened throughout, the largest measuring 1·5 cm. in greatest diameter.

On the opposite side there were two slightly-enlarged glands; one was partly caseous, the other contained a millet-seed sized caseous tubercle.

Thorax.

Lungs.—The lungs were crepitant throughout, and showed moderately numerous evenly-distributed caseous tubercles with grey margins, the largest the size of a millet seed.

Thoracic Glands. — The intertracheo-bronchial glands were slightly enlarged and beset with caseous tubercles.

The praetracheo-bronchial glands were of about normal size and contained each a few miliary caseous tubercles.

Heart, Pleura, and Pericardium.—Normal.

Abdomen.

Omentum.—The omentum contained scattered tubercles the largest the size of a millet-seed, the smaller ones were translucent, the larger caseous.

Peritoneum.—Normal.

Spleen.—The spleen was much enlarged, measuring 6·5 by 4 by 2·5 cm., and was closely beset with softened caseous nodules the largest 2·5 mm. in diameter.

The splenic lymphatic glands were slightly enlarged and contained discrete caseous tubercles.

Liver.—The liver contained moderately numerous evenly-distributed caseous tubercles the largest the size of a millet seed.

The gland on the head of the pancreas was enlarged and its cortex closely beset with softened and caseous nodules up to 2·5 mm. in diameter.

The pyloric gland was caseous practically throughout.

Kidneys.—There was one caseous tubercle in the cortex of each kidney.

Suprarenal Bodies.—Normal.

Lumbar and Iliac Glands.—The lumbar glands were slightly enlarged and each contained several caseous tubercles.

One iliac gland contained two caseous tubercles.

Alimentary Tract.

Tongue, Pharynx, Tonsils.—Normal.

Submaxillary and Retro-pharyngeal Glands.—There were two or three minute caseous tubercles in each submaxillary gland, and a caseous tubercle or two in each pharyngeal gland.

Intestines.—Normal.

Mesenteric, Ileo-colic, and Colic Glands.—The mesenteric glands contained a few caseous tubercles, one ileo-colic gland contained two. The colic glands were slightly enlarged but were not otherwise abnormal.

Inguinal Glands.—There were a few caseous tubercles in each inguinal gland.

RHESUS MONKEY 319. Virus H. 53. "D.H." (*b*).

(A young animal.)

Subcutaneous inoculation of culture derived from the portal gland of Calf 1545.

Dose—1·0 milligramme.

Date of Inoculation—May 6, 1909.

Died—June 29, 1909. [54 days after inoculation.]

POST-MORTEM EXAMINATION.

The carcass was in fair condition ; its weight was 2200 grammes.

Local Lesion.—In the subcutaneous and muscular tissues of the back, over the last four ribs on the right side, there was a thin tuberculous patch composed of fibroid tissue beset with small caseous nodules and showing in the centre a cavity about 1 cm. in diameter containing caseo-pus, which communicated externally through a small opening in the skin.

Axillary Glands.—On the right side there were four slightly enlarged glands ; one the size of a large pea was more than three-quarters caseous, another showed numerous discrete caseous tubercles in the cortex, the other two were congested but showed no sign of caseation.

The glands on the left side were slightly enlarged but were free from tubercles.

Cervical Glands.—In each posterior triangle there was a slightly enlarged gland without caseous tubercles ; other cervical glands were normal.

Vertebral Glands.—On the right side in the 10th interspace there was a gland measuring 1·2 cm. in greatest diameter which was caseous throughout. The 8th and 9th interspaces showed each one slightly enlarged gland containing one or two caseous tubercles.

On the left side one gland in the 10th interspace contained a few caseous tubercles.

Thorax.

Pleura.—The pleura was normal. On the pleural surface of the pericardium there were two millet-seed sized caseous tubercles.

The pericardial sac contained an excess of clear fluid.

Heart (muscle and valves).—Normal.

Lungs.—The right middle lobe was much enlarged firm reddish-grey (beginning grey hepatisation) and quite airless, and showed scattered grey miliary tubercles with caseous centres ; the lobes on the left side were mottled with small irregular red patches of collapse ; other lobes were crepitant ; they contained moderately numerous shotty tubercles up to a millet seed in size, the larger ones caseous, the smaller ones homogeneous or with minute caseous centres.

Bronchial Glands. — The bronchial glands were moderately large congested and showed scattered small caseous tubercles.

Abdomen.

Omentum.—In the omentum there were about half-a-dozen millet-seed-sized caseous tubercles. There was one similar tubercle on the mesentery.

Parietal Peritoneum.—Normal.

Spleen.—The spleen was slightly enlarged measuring 5·5 by 3·7 by 1·4 cm., and showed on section moderately numerous yellow softened caseous nodules with grey margins ranging from 1 to 2 mm. in diameter.

The splenic lymphatic glands were slightly enlarged but showed no sign of caseation.

Liver.—The liver was normal in colour and texture and showed on the surface scattered grey miliary tubercles, many slightly raised and "mushroomed," and in the substance under the capsule grey miliary tubercles with minute caseous centres. On section similar grey tubercles and tubercles with caseous centres were seen.

The gland on the head of the pancreas was not enlarged and contained sparsely scattered pinhead-sized caseous tubercles, other glands on the pancreas were normal.

Kidneys.—The right kidney showed in the cortex four grey miliary tubercles, two of which had minute caseous centres ; in the cortex of the left kidney there were two millet-seed sized caseous tubercles with grey margins.

Lumbar Glands.—One was enlarged and contained a hemp-seed sized caseous nodule.

Mesenteric Glands.—One contained a small caseous tubercle, the rest were normal.

Inguinal Glands.—One inguinal gland on the right side contained a millet-seed sized caseous tubercle.

The remaining organs and glands were examined and found normal.

RHESUS MONKEY 349. Virus H. 53. "D.H." (*b*).

(A young animal.)

Subcutaneous inoculation of culture derived from the small mediastinal gland of Calf 1561.

Dose—1·0 milligramme.

Date of Inoculation—July 15, 1909.

Died—August 24, 1909. [40 days after inoculation.]

POST-MORTEM EXAMINATION.

The carcass was in good condition, there was plenty of subcutaneous and abdominal fat ; its weight was 2850 grammes. The cause of death was not apparent.

Local Lesion.—Over the posterior ribs on the right side there was an ulcer measuring 5 by 2 cm. with undermined margins and pinkish-red granular floor covered with yellow pus.

Axillary Glands.—On the right side one the size of a broad bean was three-quarters caseous ; three others were enlarged but not caseous. On the left side one contained a millet-seed sized caseous tubercle.

Cervical Glands.—The cervical glands appeared normal.

Vertebral Glands. On the right side one in the 5th and three in the 8th to the 10th interspaces were enlarged the largest being 8 mm. in diameter, and were caseous and softened throughout.

Thorax.

Lungs.—The lungs were voluminous and crepitant throughout ; they showed a moderate number of evenly-distributed tubercles ranging in size up to that of a millet seed ; the larger ones were caseous the smaller ones grey with caseous centres.

Bronchial Glands.—The bronchial glands were slightly enlarged and each contained a few caseous tubercles, the intertracheo-bronchial containing the most.

Abdomen.

Omentum.—The omentum showed a few minute grey foci, early tubercles ?.

Spleen.—The spleen was slightly enlarged measuring 5 by 3 by 1·5 cm. and showed the pulp moderately closely beset with yellow caseous and softened nodules ranging from 1 to 2 mm. in diameter.

One splenic lymphatic gland contained a small tubercle.

Liver.—The liver was pale and showed scattered tubercles ranging from a mere point up to about 1·5 mm. in diameter, the larger ones caseous the smaller ones grey with caseous centres.

The gland on the head of the pancreas was slightly enlarged and showed a moderate number of tubercles arranged around the cortex.

The pyloric gland contained a few caseous tubercles.

Kidneys.—The right kidney showed in the cortex two pinhead-sized grey tubercles and a few minute grey foci, in the left there were two miliary tubercles with caseous centres and two or three grey foci.

One Mesenteric Gland contained a tubercle.

One Submaxillary Gland contained a caseous tubercle.

The remaining organs and glands were examined and found normal.

RHESUS MONKEY 351. Virus H. 53. "D.H." (*b*).

(A young animal.)

Subcutaneous inoculation of culture derived from the small mediastinal gland of Calf 1561.

Dose—1·0 milligramme.

Date of Inoculation—July 15, 1909.

Died—August 17, 1909. [33 days after inoculation.]

POST-MORTEM EXAMINATION.

The carcass was thin. Its weight was 1,570 grammes.

Local Lesion.—In the subcutaneous tissues over the posterior ribs on the right side there was a caseous abscess measuring 5 cm. in greatest diameter.

Axillary Glands.—On the right side four glands ranging up to 1 cm. in diameter were partly or wholly caseous. On the left side the glands were normal in size and only one contained a few caseous foci.

Cervical Glands.—In the right posterior triangle there were two caseous and softened glands the largest the size of a pea ; on the left side one small gland was caseous.

Vertebral Glands.—Four on the right side and three on the left in the middle of the back were caseous and softened throughout ; the largest one was 1 cm. in diameter.

Thorax.

Lungs.—The lungs were crepitant and contained scattered tubercles, the majority minute grey and translucent, a few of the larger ones caseous in the centre.

Bronchial Glands. — An intertracheo - bronchial gland was slightly enlarged and its cortex closely beset with caseous tubercles. The praetracheo-bronchial glands appeared normal.

Abdomen.

Omentum.—The omentum contained sparsely scattered caseous tubercles and there were a few caseous tubercles in the meso-colon.

Spleen.—The spleen was slightly enlarged, measuring 4·5 by 2·5 by 1·3 cm. ; the substance was firm and very closely beset with miliary caseating tubercles.

The splenic lymphatic glands were slightly enlarged and contained each a caseous tubercle or two.

Liver.—The liver was pale and showed moderately numerous evenly distributed caseous tubercles ranging from a point to a millet seed in size.

Portal Glands.—One gland on the head and another on the body of the pancreas were perhaps slightly enlarged and showed in the cortices numerous discrete caseous tubercles.

Kidneys.—There were two small caseous tubercles in the cortices of the right kidney ; in that of the left there were about half-a-dozen similar tubercles.

Lumbar Glands.—One lumbar gland contained a caseous nodule.

Mesenteric Glands.—The mesenteric glands contained a few caseous tubercles.

Inguinal Glands.—In the inguinal glands on the left side there were three caseous tubercles ; in one gland on the right side there was one.

Submaxillary Glands.—One gland on each side contained two or three caseous tubercles.

All other organs and glands were examined and found normal.

VIRUS H. 53. "D.H." (*b*).

ABSTRACTS OF POST-MORTEM NOTES OF RABBITS INOCULATED WITH CULTURES DERIVED FROM THE CALVES USED IN THE PASSAGE EXPERIMENTS WITH THE VIRUS.

(1.) Subcutaneous Inoculations.

Source of Culture Inoculated.	Dose in Milli-grammes.	Number of Rabbit.	Weight in Grammes.		Duration of Life.	Result.
			Initial.	Final.		
						Series *a*.
Calf 1507 (1st calf) Portal gland.	10·0 mg.	**2182**	2,300	1,220	Died 125 days	Slight chronic generalised tuberculosis; the cause of death was not apparent. There was a nodular caseous local lesion. The nearest glands contained caseous gritty nodules. On the surface of the lungs a moderate number of flattened caseous nodules were seen and in the thin margins a few flat caseous patches. There was a moderate number of caseous tubercles in the cortex of each kidney, and caseo-pus in the pelvis of one. There was no tuberculosis elsewhere.
	10·0 mg.	**2183**	1,850	1,250	Died 169 days	Local tuberculosis and slight tuberculosis of lungs and kidneys. The cause of death was not apparent. The local lesion was a large ulcerated thin-walled caseous abscess; the adjacent glands were caseous and softened. The lungs contained a few aggregated caseous nodules and sparsely scattered caseous miliary tubercles. There were pits or scars on the surface of each kidney and three or four caseous tubercles or nodules; the calyces of one kidney contained caseo-pus. There was no tuberculosis elsewhere.
	10·0 mg.	**2224**	2,150	1,350	Died 103 days	General tuberculosis. The local lesion was moderately large, caseous and softening, and the nearest glands were caseous. The lungs did not collapse and were moderately closely beset with caseous nodules, largest and becoming confluent on the surface. There were scattered grey foci in the liver and a moderate number of caseous miliary tubercles in the spleen. The kidneys showed moderately numerous caseating nodules some projecting from the surface. There were tubercles on the omentum, in the areolar tissues, on the pleura, and in most of the lymphatic glands. The appendix and the end of the ileum were closely beset with firm caseous nodules.
Calf 1555 (2nd calf) Small mediastinal gland.	47·0 mg.	**2355**	1,150	1,050	Died 61 days	General tuberculosis, not severe. The local lesion was a thin-walled cyst containing caseo-pus and the adjacent glands were caseous and softened or contained caseous nodules. The anterior halves of the lungs were solid, greyish red, with scattered caseous foci; the rest of the lungs was crepitant and contained a moderate number of caseous nodules. There were a few caseous tubercles in the spleen, and the kidneys showed moderately numerous grey miliary tubercles with caseous centres. There were caseous nodules in the portal glands.
	10·0 mg.	**2354**	1,050	1,750	Died 123 days	Chronic general tuberculosis, not severe. The local lesion was a large flat thin-walled cyst containing muco-pus, and the adjacent glands contained caseous nodules. The lungs showed scattered grey miliary tubercles the majority with whitish caseous centres. The liver contained a few yellow nodules with caseous gritty centres (smear, a few T.B.) and a few small tubercles (smear, a few T.B.). Each kidney showed on the surface about a dozen grey patches with small caseous tubercles; section showed caseous streaks extending inwards to the pelvis.

Calf 1563 (3rd calf) Popliteal gland.	10·0 mg.	2464	1,650	1,300	Died 191 days	Chronic general tuberculosis, not severe and insufficient to account for death. The local lesion was a thin-walled cyst filled with caseo-pus; the nearest glands were caseous. The lungs contained scattered caseous tubercles and small grey tubercles. The kidneys showed on the surface irregular scars, a few slightly projecting grey nodules containing caseous foci, and scattered tubercles. There were scattered caseous foci in appendix and lower end of ileum, and the popliteal and pudic glands showed a caseous tubercle or two.
	5·0 mg.	2462	1,550	2,000	Killed 192 days	Slight general tuberculosis. There was a caseous local lesion and the nearest gland was caseous. The lungs showed scattered caseo-calcareous tubercles and in the thin margins some larger caseo-calcareous nodules. In each kidney there were scattered miliary tubercles and in one a group of grey nodules projecting from the surface. There was no tuberculosis elsewhere.
	5·0 mg.	2463	1,700	1,450	Died 134 days	Slight general tuberculosis; the cause of death was not apparent. There was a caseous local lesion and the nearest gland was enlarged and caseous. The lungs showed scattered miliary caseous tubercles and a few caseous patches. One kidney contained a caseating nodule, the other a few miliary tubercles. There was no tuberculosis elsewhere.
						Series β.
Calf 1545 (1st calf) Portal gland.	10·0 mg.	2351	1,100	1,190	Died 106 days	Very slight generalised tuberculosis. There was a large caseous and softened local lesion, and the nearest glands were caseous. The thin margins of one lung were solid and caseating for a slight depth, and there were a few small caseous patches and scattered caseous tubercles in both lungs. One kidney showed two nail-shaped caseating nodules, the other a caseous focus. The portal glands contained caseo-calcareous tubercles.
Calf 1561 (2nd calf) Small mediastinal gland.	10·0 mg.	2394	1,950	2,500	Killed 130 days	Slight general tuberculosis. The local lesion was a thin-walled cyst filled with caseo-pus; the adjacent glands contained thin caseo-pus. The lungs contained a few small nodules with caseous centres. The mediastinal pleura showed early tuberculosis and there were some flattened tuberculous growths on the diaphragmatic pleura. In the cortex of one kidney a dozen nodules were seen (up to 3 mm.) the larger projecting; in the other kidney a few nodules were seen in the cortex and two tuberculous areas (grey with caseo-calcareous centres) in the medulla. No tuberculosis elsewhere
	9·0 mg.	2393	1,850	1,550	Died 116 days	Generalised tuberculosis, not severe; the cause of death was not apparent. The local lesion was large nodular and caseous, and the nearest glands contained caseous nodules. There were firm caseous nodules at the tip of each caudal lobe of the lungs and small caseous patches in the thin margins; elsewhere in the lungs were a moderate number of small caseous tubercles and some caseous nodules. The kidneys showed a moderate number of grey tubercles with minute caseous centres, one or two grey nodules with caseous foci, and some caseous streaks. There was no tuberculosis elsewhere.

2. Intravenous Inoculations.

						Series α.
Calf 1507 (1st calf) Portal gland.	1·0 mg.	2346	850	800	Died 15 days	Early general tuberculosis.
	0·1 mg.	2345	900	850	Died 19 days	General tuberculosis.
	0·01 mg.	2344	1,050	770	Died 73 days	General miliary tuberculosis.

VIRUS H. 53. "D.H." (*b*)—*continued.*

ABSTRACTS OF POST-MORTEM NOTES OF RABBITS INOCULATED WITH CULTURES DERIVED FROM THE CALVES USED IN THE PASSAGE EXPERIMENTS WITH THE VIRUS—*continued.*

(2.) INTRAVENOUS INOCULATIONS—*continued.*

Source of Culture Inoculated.	Dose in Milli-grammes.	Number of Rabbit.	Weight in Grammes.		Duration of Life.	Result.
			Initial.	Final.		
Calf 1555 (2nd calf) Small mediastinal gland.	0·1 mg.	2352	1,200	800	Died 34 days	General miliary tuberculosis.
	0·1 mg.	2353	1,300	900	Died 22 days	General miliary tuberculosis
				Series β.		
Calf 1545 (1st calf) Portal gland.	0·1 mg.	2350	1,150	840	Died 17 days	General tuberculosis.
	0·01 mg.	2349	1,100	1,000	Died 44 days	General miliary tuberculosis (not so severe as after 0·01 mg. of bovine tubercle bacilli).

VIRUS H. 71. "L.V." (*a*)

LUPUS.

VIRUS H. 71. "L.V." (*a*).

LUPUS.

(July 4, 1906.)

CULTURE INOCULATIONS, NOVEMBER 9, 1906.

The strain was derived from the original material, through G.P. 1937, and had been in artificial cultivation a total period of 2½ months.

The culture used was the 5th generation, 21 days old.

CALF 1163.

Subcutaneous.

Dose : 50·0 mg.

Killed : Feb. 12, 1907.

95 days.

P.M. — Cystic local tumour ; the nearest glands contained fibro - calcareous nodules with softened caseous patches. A dozen glassy tubercles were seen in the lungs.

RABBITS.

Number.	Method.	Dose.	Duration of Life.	Result.
992	Intrav.	1·0 mg.	K. 188 days	T. of kidneys and one testicle ; slight T. of lungs.
993	Intrav.	0·1 mg.	K. 188 „	Chronic G.T.
994	Intrap.	10 0 mg.	D. 50 „	G.T.
995	Intrap.	1·0 mg.	K. 188 „	Slight T. of peritoneum and kidneys.
996	Subcut.	50·0 mg.	K. 188 „	Local T. only.
997	Subcut.	10·0 mg.	K. 188 „	Local T. only.

GUINEA-PIGS.

Number.	Method.	Dose.	Duration of Life.	Result.
1989	Intrap.	1·0 mg.	D. 32 days	G.T.
1991	Intrap.	0·1 mg.	D. 37 „	G.T.
1990	Subcut.	1·0 mg.	D. 67 „	G.T.
1992	Subcut.	0·1 mg.	D. 86 „	G.T.

RATS.

Number.	Method.	Dose.	Duration of Life.	Result.
50	Intrap.	50·0 mg.	D. 28 days	Acute T.
51	Subcut.	50·0 mg.	D. 70 „	Local T. ? cause of death.

VIRUS H. 71. "L.V." (*a*)—*continued.*

CULTURE INOCULATIONS, NOVEMBER 9, 1906—*continued.*

CALF 1153.

Subcutaneous.

Dose : 50·0 mg.

Killed : Feb. 12, 1907.

95 days.

P.M. — Firm tumour composed mainly of thickened skin at seat of inoculation. Fibro-calcareous patch and a few calcareous tubercles in prescapular gland. Calcareous patches in thoracic glands, and calcareous foci in many abdominal glands. Very few glassy tubercles in lungs.

CULTURE

Derived from the bronchial gland. Inoculated on June 25, 1907, after 19 weeks artificial cultivation, into the following animals :—

RABBITS.

Number.	Method.	Dose.	Duration of Life.	Result.
1352	Subcut.	10·0 mg.	K. 143 days	Local lesion only.
1353	Subcut.	10·0 mg.	K. 143 „	Local lesion only.

RATS.

Number.	Method.	Dose.	Duration of Life.	Result.
58	Intrap.	20·0 mg.	D. 103 days	Generalised tuberculosis. T.B. numerous everywhere.
59	Intrap.	20·0 mg.	D. 344 „	T. of lungs ; T.B. in organs.

CAT 43 (Kitten).

Intraperitoneal.

Dose : 50·0 mg.

Died : 15 days.

P.M.—There was a small collection of caseo-pus in the sub-peritoneal tissues, but no naked-eye evidence of tuberculosis elsewhere. T.B. were found in the spleen, liver, and lungs. The cause of death was not apparent.

CALF 1153. Virus H. 71. "L.V." (*a*).

Subcutaneous inoculation of culture derived from the original material (lupus scrapings) through G.P. 1937.

Dose—50·0 milligrammes.

Date—November 9, 1906.

Weight at Inoculation—1 cwt. 1 qr. 17 lbs. [Age about 16 weeks.]

Killed when in good health—February 12, 1907. [95 days after inoculation.]

Clinical Notes.

A firm tumour developed at the seat of inoculation on the left side of the neck. At the end of the fourth week this was pear-shaped, adherent to the skin, and slightly adherent to the subjacent muscles. It measured 12·5 by 7·5 cm. by a little over 2·5 cm. in thickness. The adjacent prescapular gland was enlarged, measuring 9 cm. in length, and the left prepectoral gland was the size of a walnut. Subsequently both the tumour and the adjacent glands diminished in size.

The calf showed no sign of illness during the experiment, and was killed when fat and well on the 95th day after inoculation.

Temperature. (Chart to December 29.)

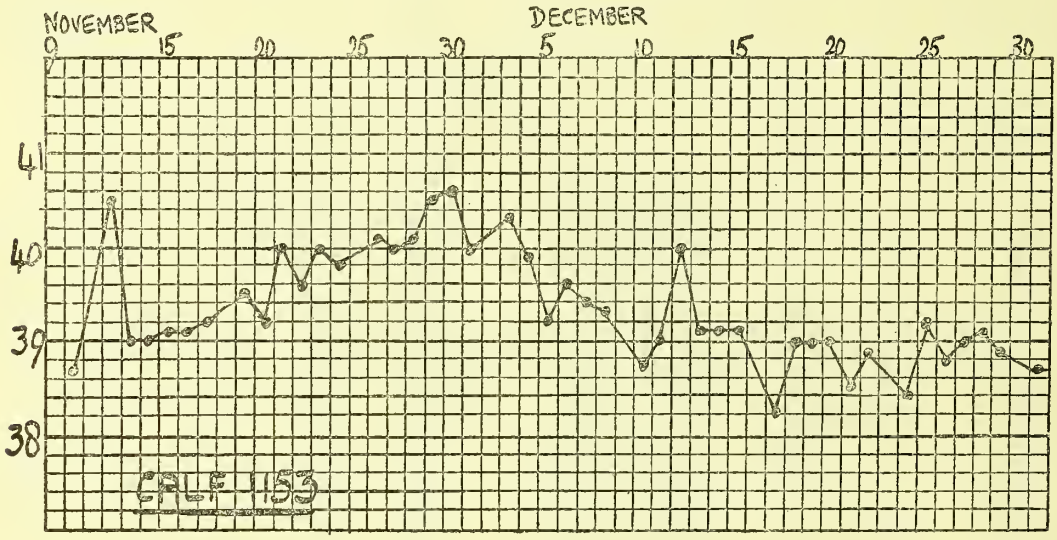

From December 29 to February 12 when the calf was killed, the temperature remained normal.

Tuberculin Test.

January 31. [83 days after inoculation.] Very slight reaction. Rise of temperature 0·5° C.

Weights.

The calf gained weight normally during the experiment.

	cwt.	qr.	lbs.
November 9, 1906	1	1	17
February 12, 1907	2	1	26

Total gain of weight.—1 cwt. 0 qr. 9 lbs.

Rate of gain per week.—9 lbs.

POST-MORTEM EXAMINATION.

General Condition.—Fat.

Local Lesion.—At the seat of inoculation, on the left side of the neck, there was a very firm tumour measuring about 9 by 7 cm. in superficial area ; on removal and section it was found to be composed of greatly thickened skin (1·5 cm. in greatest thickness), and a small subcutaneous mass measuring 6·5 by 4 by 2 cm., of dense brownish translucent fibroid tissue, with a small cavity (2 by 1 cm.) in the centre filled with yellow caseo-pus.

Left Prescapular Gland.—The left prescapular gland measured 5 by 3 by 1·8 cm. ; on section it showed a brownish translucent fibroid patch, measuring 3 by 1·5 by 1 cm., containing one or two calcareous tubercles and a few calcareous particles ; the rest of the gland was normal except for two calcareous tubercles and a few calcareous grains.

Right Prescapular Gland.—The right prescapular gland measured 5 by 2·5 by 1 cm. and was normal on section.

Prepectoral Glands.—The rounded prepectoral gland on the left side, 1 cm. in diameter, was mainly composed of brownish translucent fibroid tissue (similar to that in the left prescapular gland) containing a few calcareous particles.

Axillary Glands.—Normal.

Thorax.

Pleura.—Normal.

Lungs.—The lungs were crepitant and perfectly normal in general appearance ; they showed under the pleura about half a dozen transparent tubercles, the size of pins' heads ; no tubercles were seen on section.

Thoracic Glands.—The mediastinal and bronchial glands were not enlarged ; on section each showed in the cortex calcareous patches of various sizes, composed of closely aggregated calcareous particles ; these patches were largest in the left bronchial gland and in some of the small dorsal mediastinal glands.

Heart.—Normal.

Abdomen.

Omentum and Peritoneum.—Normal.

Spleen.—Normal.

Liver.—Normal.

Portal Glands.—The portal glands, normal in size, contained numerous irregular calcareous foci, embedded in normal looking gland tissue.

Pancreatic Glands.—The pancreatic glands were similar on section.

Coeliac Glands.—Three or four calcareous foci were found in the coeliac glands.

Kidneys.—Normal.

Suprarenals.—Normal.

Renal and Lumbar Glands.—Normal.

Iliac Glands.—One iliac gland on the right side contained a small calcified tubercle.

Alimentary Tract.

Tongue, Pharynx, Palate, and Tonsils.—Normal.

Pharyngeal, Submaxillary, Hyoid, and Subparotid Lymphatic Glands.—Normal.

Intestines.—Normal.

Mesenteric Glands. — All the mesenteric glands showed in the cortex irregular calcareous foci; in the glands at the extremity of the mesentery the foci were fairly numerous but in other glands were sparsely scattered.

Ileo-colic Glands.— These glands resembled the terminal mesenteric glands.

Gastric Glands.—Normal.

Genito-Urinary System.

Testes.—Normal.

Various Peripheral Lymphatic Glands.

Precrural, Popliteal, Gluteal, Ischiatic, Pudic.—Normal.

Microscopical Examination.

Emulsion of Bronchial Gland.—Tubercle bacilli scanty.

Animal Inoculated.

Guinea-pig 2250 inoculated intraperitoneally with an emulsion of the spleen, was killed after 58 days, and was found to be healthy.

CALF 1163. Virus H. 71. "L.V." (*a*).

Subcutaneous inoculation of culture derived from the original material (lupus scrapings) through G.P. 1937.

Dose—50·0 milligrammes.

Date—November 9, 1906.

Weight at Inoculation—1 cwt. 2 qrs. 16 lbs. [Age about 18 weeks.]

Killed when in good health—February 12, 1907. [95 days after inoculation.]

Clinical Notes.

A firm tumour of moderate size developed at the seat of inoculation. At the end of the fourth week this measured 11·5 by 5·5 cm. by about 2·5 cm. in thickness. The adjoining prescapular gland was enlarged, measuring 9 cm. in length. The temperature, which had been high for three weeks following the inoculation, was now normal, and the calf was quite well.

The tumour subsequently became soft and fluctuating. The calf was killed when fat and well on the 95th day after inoculation.

Temperature. (Chart to January 2.)

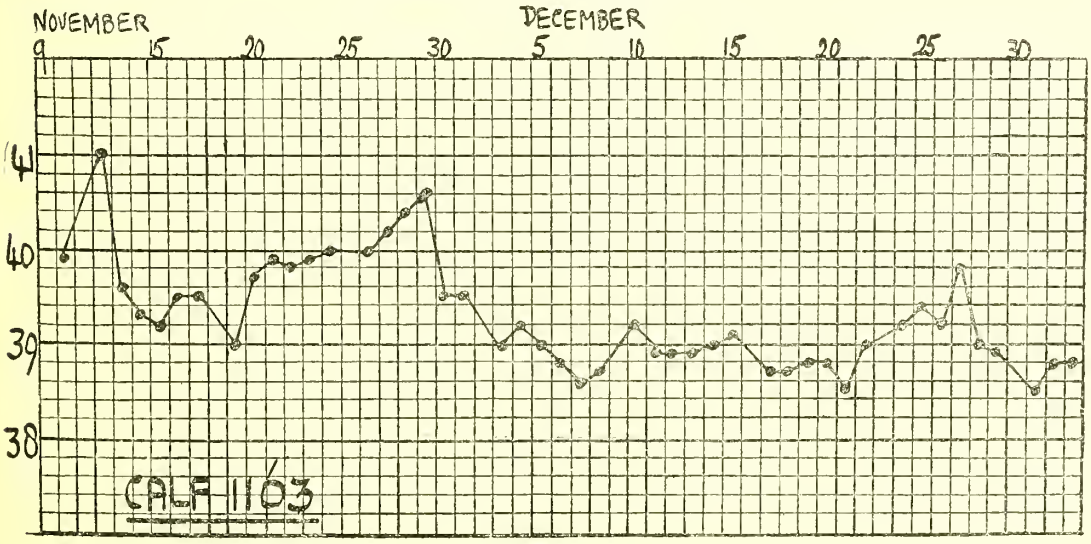

From January 3 to February 12 when the calf was killed, the temperature remained normal.

Tuberculin Test.

January 31, 1907. [83 days after inoculation.] Reacted. Rise of temperature, 1·7° C.

Weights.

The calf increased in weight normally during the experiment.

	cwt.	qrs.	lbs.
November 9, 1906	1	2	16
February 12, 1907	2	2	16

Total gain of weight.—1 cwt.
Average rate of gain per week.—8·3 lbs.

POST-MORTEM EXAMINATION.

General Condition.—Fat.

Local Lesion.—In the subcutaneous tissues on the left side of the neck there was a fluctuating swelling measuring 8 by 6 by 4 cm.; on section it was found to be a cyst with a pearly white fibrous wall 3 to 4 mm. in thickness and thick creamy caseo-purulent contents; the cyst-wall was lined with pale granulation tissue, containing gritty particles, and the cavity was crossed by fibrous trabeculae.

Left Prescapular Gland.—The left prescapular gland measured 6 by 3·5 by 2·5 cm., and showed on section two tuberculous nodules, one 3 cm. the other 2 cm. in greatest diameter; they were composed of a brownish translucent fibroid tissue containing calcareous grains and cavities of various sizes filled with creamy caseo-pus.

Right Prescapular Gland.—The right prescapular gland measured 5·5 by 2·5 by 1·5 cm. and was normal on section.

Prepectoral Glands.—The rounded prepectoral gland on the left side measured 1·5 cm. in diameter and on section was composed partly of fibro-calcareous substance and partly of thick caseo-pus. Other glands on this side and those on the right side were normal.

Axillary Glands.—Normal.

Thorax.

Pleura.—Normal.

Lungs.—The lungs were crepitant and had a perfectly normal general appearance; they showed under the pleura a very small number of glassy transparent tubercles, the largest the size of a pin's head; not more than a dozen were counted in both lungs; no tubercles were seen on section.

Thoracic Glands.—The long gland in the dorsal mediastinum contained a minute spherical focus, about the size of a grain of sand. Other mediastinal and the bronchial glands were normal.

Heart.—Normal.

All other organs and glands were examined and found healthy.

Microscopical Examination.

Focus from Thoracic Gland.—No tubercle bacilli.

Animal Inoculated.

Guinea-pig 2249, inoculated intraperitoneally with an emulsion of the spleen, was killed after 58 days and was found to be healthy.

CAT 43. [Kitten.] Virus H. 71. "L.V." (*a*).

Intraperitoneal inoculation of culture derived from the bronchial gland of Calf 1153.

Dose—50·0 milligrammes.

Date of Inoculation—June 25, 1907.

Died—July 10, 1907. [15 days after inoculation.]

Weights.

	grammes.
June 25, 1907	720
July 10, 1907	520

Loss of weight.—200 grammes.

POST-MORTEM EXAMINATION.

Local Lesion.—There was a small collection of caseo-pus in the subperitoneal tissues at the seat of inoculation.

Omentum and Peritoneum.—The omentum was slightly congested but was not thickened except perhaps along some of the vessels. The peritoneum was normal.

All the organs and lymphatic glands appeared normal to the naked eye.

Microscopical Examination.

(Smears from :—)

Spleen, *Liver.* } Tubercle bacilli fairly numerous.

Lung.—Tubercle bacilli not so numerous as in spleen and liver.

VIRUS H. 71. "L.V." (*b*).

LUPUS.

VIRUS H. 71. "L.V." (*b*).

CULTURE INOCULATIONS.

JULY 11, 1908.

The strain was derived from the original material through G.P. 3021 and had been in cultivation a total period of 63 days.

The culture used was the 4th generation, 22 days old.

RABBITS.

Number.	Method.	Dose.	Duration of Life.	Result.
1925	Intrav.	1·0 mg.	D. 4 days	No sign of disease.
1926	Intrav.	0·1 mg.	K. 161 „	Two or three tubercles in a lung and one in a kidney.
1927	Intrav.	0·01 mg.	K. 161 „	Slight T. of lungs and kidneys.
1928	Subcut.	66·0 mg.	K. 161 „	Local T. and one tubercle in the lung.
1929	Subcut.	10·0 mg.	K. 161 „	Local lesion only.

GUINEA-PIGS.

Number.	Method.	Dose.	Duration of Life.	Result.
3147	Intrap.	1·0 mg.	D. 30 days	G. T.
3148	Subcut.	1·0 mg.	D. 71 „	G. T.

RHESUS MONKEY 193.

Subcutaneous.

Dose : 0·01 mg.

Died : August 28, 1908.

48 days.

P.M.—Death was probably due to cold. There was a small local ulcer; two axillary, two vertebral and three cervical glands were slightly enlarged, caseous, and softened. The lung contained four grey tubercles; the spleen five and the liver two caseous nodules; one pancreatic gland contained a few caseous foci.

RHESUS MONKEY 195.

Subcutaneous.

Dose : 1·0 mg.

Died : August 16, 1908.

36 days.

P.M.—General tuberculosis, not severe, and not sufficient to account for death.

RHESUS MONKEY 195. Virus H. 71. "L.V." (*b*).

(A young animal.)

Subcutaneous inoculation of culture derived from the original material through Guinea-pig 3021.

Dose—1·0 milligramme.

Date of Inoculation—July 11, 1908.

Died—August 16, 1908. [36 days after inoculation.]

Clinical Notes.

The monkey remained well until within a few days of death. The character of the illness was similar to that frequently seen here: loss of appetite, great weakness, loss of flesh, no increase in respiration.

The weight at death was 1270 grammes.

POST-MORTEM EXAMINATION.

The carcass was thin.

Local Lesion.—The skin at the seat of inoculation over the left scapula showed a punched-out ulcer 1·5 cm. in greatest diameter, the floor of which was formed by muscle; the skin around the ulcer was considerably undermined, the space, 1 to 1·5 cm. broad, containing a small quantity of breaking-down caseous material.

Axillary Glands.—On the left side two glands, each a centimetre in diameter, were caseous and softened practically throughout. Another contained a hempseed-sized softened caseous nodule.

The right axillary glands were normal.

Cervical Glands.—Behind the right clavicle one gland, the size of a large pea, was caseous and softened throughout. The rest of the cervical glands were normal.

Vertebral Glands.—In each of the 7th, 8th, and 10th interspaces on the left side there was a caseous and softened gland, the largest 8 mm. in greatest diameter.

Thorax.

Pleura.—Normal.

Lungs.—The lungs were crepitant and collapsed normally; they contained scattered shotty tubercles ranging from about 0·5 up to 1·5 mm. in diameter. The smaller ones were grey and translucent, the larger ones caseous in the centre.

Thoracic Glands. — Altogether there were four miliary caseous tubercles in the bronchial glands.

Heart.—Normal.

Abdomen.

Omentum and Peritoneum.—There was one pinhead-sized grey tubercle with a caseous centre in the omentum, and one minute transparent tubercle on the meso-colon.

Spleen.—The spleen was normal in size, and showed in the pulp scattered grey tubercles up to 1 mm. in diameter, the larger caseous in the centre.

Splenic Lymphatic Glands.—Normal.

Liver.—The liver was pale and showed on the surface a moderate number of caseous tubercles ranging from less than 1 to rather more than 2 mm. in diameter, the larger ones being yellow and softened. Forty were counted on the anterior surface and twenty on the posterior. Similar tubercles were seen in the depth of the liver substance.

Portal, Lumbar, and Iliac Glands.—Normal.

Kidneys.—The right kidney showed in the cortex just under the capsule one greyish-white miliary tubercle.

On the surface of the left there was one minute grey tubercle, and in the depth of the cortex a miliary tubercle with a caseous centre.

Suprarenal Bodies.—Normal.

Alimentary Tract.

Tongue, Pharynx, Tonsils.—Normal.

Submaxillary and Pharyngeal Glands.—Normal.

Small Intestines.—Normal.

Large Intestines.—The caecum was normal in size and contained firm faeces; the wall was however thickened, the tissues between the serous and mucous coats being spongy crepitant and filled with gas; the mucous membrane was increased in thickness and was not ulcerated.

Mesenteric and Colic Glands.—Normal.

Brain.—Normal.

Inguinal Glands.—Normal.

Microscopical Examination.

Spleen Tubercle.—Tubercle bacilli moderately numerous.

Liver Tubercle.—Tubercle bacilli numerous.

RHESUS MONKEY 193. Virus H. 71. "L.V." (*b*).

(A young animal.)

Subcutaneous inoculation of culture derived from the original material through guinea-pig 3021.

Dose—0·01 milligramme.

Date of Inoculation—July 11, 1908.

Died—August 28, 1908. [48 days after inoculation.]

Clinical Notes.

The animal remained well until within a few days of death.

The illness was of the character frequently seen here—marked by loss of appetite and extreme weakness, with no increase in respiration or other symptoms; it seemed to be in this case caused by cold at night.

The weight at death was 950 grammes.

POST-MORTEM EXAMINATION.

The carcass was thin.

Local Lesion.—The skin over the right scapula showed a tuberculous ulcer, 1·5 cm. in diameter, covered with a scab; the margins of the ulcer were undermined, the floor was irregular and covered with caseo-purulent substance, the base was fibroid, 2 mm. thick, and showed caseous foci.

Axillary Glands.—On the right side two glands the size of peas were caseous and softened throughout. Those on the left side were normal.

Cervical Glands.—Behind the right clavicle there were three caseous and softened glands, one the size of a pea, the others that of a hemp seed.

The rest of the cervical glands were normal.

Vertebral Glands.—One in the 7th and one in the 9th interspaces were slightly enlarged caseous and softened throughout.

Thorax.

Pleura.—Normal.

Lungs.—The lungs were crepitant and collapsed normally ; they showed under the pleura four translucent grey tubercles, the largest the size of a pin's head. No tubercles were seen on section.

Bronchial Glands.—Normal.

Heart.—Normal.

Abdomen.

Omentum and Peritoneum.—Normal.

Spleen.—The spleen was normal in size and contained five softened caseous nodules, ranging from 1 to 2·5 mm. in diameter.

Liver.—The liver contained two caseous nodules, 1 and 1·5 mm. in diameter, and one doubtful grey tubercle.

The gland on the head of the pancreas showed three minute caseous foci.

Kidneys.—Normal.

Suprarenal Bodies.—Normal.

Iliac and Lumbar Glands.—Normal.

Alimentary Tract.

Tongue, Pharynx, Tonsils.—Normal.

Submaxillary and Retro-pharyngeal Glands.—Normal.

Intestines and Mesenteric Glands.—Normal.

Brain.—Normal.

Inguinal Glands.—Normal.

Microscopical Examination.

Nodule from Spleen.—Moderately numerous tubercle bacilli, long and beaded.

Nodule from Liver.—A few tubercle bacilli ; many organisms stained blue.

VIRUS H. 84. "M.S."

LUPUS.

VIRUS H. 84. "M.S."

LUPUS.

CULTURE INOCULATIONS.

I.—June 28, 1907.

The strain was derived from the original material through Guinea-pig 2277, and had been artificial cultivation a total period of 62 days.

The culture used was the 4th generation, 21 days old.

GUINEA-PIGS.

Number.	Method.	Dose.	Duration of Life.	Result.
2485	Intrap.	1·0 mg.	D. 50 days	G. T. (atypical).
2487	Intrap.	0·1 mg.	D. 59 „	G. T.
2486	Subcut.	1·0 mg.	D. 855 „	General healed tuberculosis.†
2488	Subcut.	0·1 mg.	D. 257 „	Chronic G. T.

RABBITS.

Number.	Method.	Dose.	Duration of Life.	Result.
1358	Intrav.	1·0 mg.	D. 8 days	Organs and glands healthy. (?) cause of death.
1359	Intrav.	0·1 mg.	K. 147 „	Three or four tubercles in the lungs and one in one kidney.
1360	Intrap.	10·0 mg.	K. 147 „	Local T. only.
1361	Subcut.	47·0 mg.	D. 4 „	Death from pseudo-tuberculosis.
1362	Subcut.	10·0 mg.	D. 8 „	Local T. only. (?) cause of death.

CULTURE.

Derived from the spleen of Guinea-pig 2486. Inoculated on January 1, 1910, after 59 days artificial cultivation. The culture used was the 4th generation, 11 days old.

RHESUS MONKEY 367.

Subcutaneous.

Dose: 1·0 mg.

Died: March 23, 1910.

81 days.

P.M. — General tuberculosis, severe in spleen only.

RABBITS.

Number.	Method.	Dose.	Duration of Life.	Result.
2503	Intrav.	1·0 mg.	K. 107 days	Very slight T. of lungs.
2504	Intrav.	1 0 mg.	D. 36 „	Very slight T. of lungs.

GUINEA-PIGS.

Number.	Method.	Dose.	Duration of Life.	Result.
3974	Subcut.	1·0 mg.	D. 22 days	Very slight G. T.
3975	Subcut.	1·0 mg.	D. 24 „	Slight G. T.
3976	Subcut.	1·0 mg.	K. 124 „	Chronic G. T.
3977	Subcut.	1·0 mg.	K. 124 „	Chronic G. T.
3978	Sucbut.	1·0 mg.	K. 124 „	Chronic G. T.
3979	Subcut.	1·0 mg.	D. 42 „	Slight G. T.
3980	Subcut.	1·0 mg.	K. 124 „	Chronic G. T.
3981	Subcut.	1·0 mg.	D. 57 „	Slight G. T.
3982	Subcut.	1·0 mg.	D. 114 „	Chronic G. T.
3983	Subcut.	1·0 mg.	D. 41 „	Slight G. T.

† Guinea-pigs 3908 and 3909 were inoculated intraperitoneally with an emulsion of a fibroid patch from the lung of Guinea-pig 2486. They were killed after 62 and 161 days, and showed respectively local tuberculosis and slight general tuberculosis.

VIRUS H. 84. "M.S."—*continued.*

CULTURE INOCULATIONS—*continued.*

II.—August 7, 1907.

The same strain. Total duration of artificial cultivation: 102 days. The culture used was the 7th generation, 21 days old.

CALF 1273.

Subcutaneous.

Dose: 50·0 mg.

Killed: Nov. 4, 1907.

89 days.

P.M.—At the seat of inoculation there was a cyst with caseo-purulent contents; the left pre-scapular gland contained two large caseo-calcareous masses; there was no tuberculosis elsewhere.

RABBITS.

Number.	Method.	Dose.	Duration of Life.	Result.
1414	Intrav.	1·0 mg.	D. 100 days	One tubercle in each kidney. (?) cause of death.
1415	Intrap.	1·0 mg.	K. 100 „	Very slight T. of omentum only.
1416	Subcut.	1·0 mg.	K. 100 „	Local lesion and one tubercle in the lung.

III.—January 18, 1908.

The same strain. Total duration of artificial cultivation: 266 days. The culture used was the 12th generation, 11 days old.

RABBIT 1683.

Intravenous.

Dose: 1·0 mg.

Killed: 334 days.

P.M.—Chronic general tuberculosis.

GUINEA-PIGS.

Number.	Method.	Dose.	Duration of Life.	Result.	
2896	Intrap.	1·0 mg.	D. 18 days	G. T.	Less severe than is usually produced by a human Group II. bacillus.
2894	Intrap.	0·1 mg.	D. 23 „	G. T.	
2897	Subcut.	1·0 mg.	D. 39 „	G. T.	
2895	Subcut.	0·1 mg.	D. 40 „	G. T.	

VIRUS H. 84. "M.S."—*continued.*

IV.—March 5, 1908.

The strain was derived from the original material through Guinea-pig 2277, and had been in cultivation a total period of 313 days.

The culture used was the 16th generation, 14 days old.

MONKEY 145.
Fed.
Dose: 1·0 mg.
Killed: July 22, 1908, when well.
139 days.
P.M. — General progressive tuberculosis of moderate severity.

MONKEY 141.
Subcutaneous.
Dose: 0·01 mg.
Died: June 8, 1908.
95 days.
P.M. — Small caseous local lesion. Two glands in the right axilla contained caseous nodules. There was one grey tubercle in the lung, caseous foci in a pancreatic gland, and no tuberculosis elsewhere. A smear from the spleen showed a few T.B.

MONKEY 143.
Subcutaneous.
Dose: 1·0 mg.
Died: June 23, 1908.
110 days.
P.M.—Chronic general tuberculosis.

RABBIT 1757
Subcutaneous.
Dose: 56·0 mg.
Killed after 344 days.
P.M. — Local lesion only.

GUINEA-PIGS.

Number.	Method.	Dose.	Duration of Life.	Result.
2985	Subcut.	1·0 mg.	D. 223 days	G. T.
2986	Subcut.	1·0 mg.	D. 256 „	Chronic T. of an unusual type.

CULTURE.

Derived from the lung of Monkey 145.

The 4th generation, 14 days old, was used on September 24, 1908, for inoculating:

MONKEY 231.
Subcutaneous.
Dose: 1·0 mg.
Died: October 25, 1908.
31 days.
P.M.—General tuberculosis.

MONKEY 233.
Subcutaneous.
Dose: 1·0 mg.
Died: September 27, 1908.
3 days.
P.M. — No cause of death found.

The 8th generation, 22 days old, was used on November 25, 1908, for inoculating:

GUINEA-PIGS.

Number.	Method.	Dose.	Duration of Life.	Result.
3382	Intrap.	1·0 mg.	D. 20 days	G. T.
3384	Subcut.	1·0 mg.	K. 21 „ (accidentally)	Early G. T.
3385	Subcut.	1·0 mg.	D. 29 „	G. T.

V.—April 27, 1908.

The strain was derived from the original material through Guinea-pig 2277, and had been in cultivation a total period of 366 days.

The culture used was the 8th generation, 17 days old.

RABBIT 1834.
Intravenous.
Dose: Slightly more than 9·0 mg.
Died in 329 days.
P.M.—Tuberculosis of lungs and kidneys, a lachrymal gland and a testicle

MONKEY 117.
Subcutaneous.
Dose: Slightly less than 10·0 mg.
Died: July 9, 1908.
73 days.
P.M.—General tuberculosis, not severe.

CALF 1273. Virus H. 84. "M.S."

Subcutaneous inoculation of culture derived from the original material through Guinea-pig 2277.

Dose—50·0 milligrammes.

Date of Inoculation—August 7, 1907. [Age about 12 weeks.]

Killed when in good health—November 4, 1907. [89 days after inoculation.]

Clinical Notes.

A small tumour developed at the seat of inoculation on the left side of the neck and the adjacent prescapular gland became slightly enlarged. The calf remained well during the experiment.

Temperature.—Normal.

Tuberculin Tests.

I. October 24, 1907. [78 days after inoculation.] Dose—2·0 cc. Reacted. Rise of temperature—1·4° C.

II. October 30, 1907. [84 days after inoculation.] Dose—2·0 cc. Reacted. Rise of temperature—0·9° C.

Weights.

	cwt.	qrs.	lbs.
August 7, 1907	1	0	20
November 4, 1907	1	2	25

Total gain of weight.—2 qrs. 5 lbs.

Average rate of gain per week.—4·8 lbs.

POST-MORTEM EXAMINATION.

The carcass was in good condition.

Local Lesion.—On the left side of the neck there was a prominent tumour, oval in outline, measuring 7 by 4 by 3 cm.; on section it was a fibrous walled cyst filled with thick creamy caseo-purulent contents; the cavity of the cyst was crossed by fibrous trabeculae and was lined with granulation tissue.

Left Prescapular Gland.—The left prescapular gland measured 5·5 by 3·4 by 1·7 cm., and showed on section two breaking-down caseo-calcareous masses, one 2·5 the other 2 cm. in greatest diameter; they replaced about two-thirds of the gland substance.

Right Prescapular Gland.—The right prescapular gland measured 5 by 2·4 by 1·2 cm. and was normal on section.

Prepectoral and Axillary Glands.—Normal.

Thorax.

Pleura, Lungs, Heart, Thoracic Glands.—Normal.

Abdomen.

Peritoneum. Liver and Portal Glands, Spleen, Kidneys, and Suprarenal Bodies.—Normal.

Alimentary Tract.

Tongue, Pharynx, Palate, Tonsils, Intestines, and Mesenteric Glands.—Normal.

All the lymphatic glands of the body, not hitherto mentioned, were normal.

Testes.—Normal.

Eyes.—Normal.

RHESUS MONKEY 141. Virus H. 84. "M.S."

(A young animal.)

Subcutaneous inoculation of culture derived from the original material through Guinea-pig 2277.

Dose—0·01 milligramme.

Date of Inoculation—March 5, 1908.

Died—June 8, 1908. [95 days after inoculation.]

Weight at death—1670 grammes.

POST-MORTEM EXAMINATION.

The carcass was in poor condition.

Local Lesion.—In the subcutaneous tissues at the lower angle of the scapula there was a small flat irregular caseous tumour, 2 cm. in greatest diameter. The caseous substance was for the most part firm, but in places could be readily scraped away with a scalpel. The skin over it was thin, pigmented, and showed three small scars.

Axillary Glands.—On the right side, one, the size of a pea, showed the substance almost completely replaced by yellow breaking-down caseous nodules. Another contained two caseous tubercles, the largest 2 mm. in diameter. The rest were normal.

The glands on the left side were normal.

Cervical Glands.—Normal.

Vertebral Glands.—Normal.

A gland on the left side behind the manubrium sterni contained a miliary caseous tubercle.

Thorax.

Lungs.—The lungs were crepitant throughout. In the right cephalic lobe there was one millet-seed sized grey shotty tubercle; otherwise the lungs were perfectly normal.

Bronchial Glands.—Normal.

Pleura, Heart, and Pericardium.—Normal.

Abdomen.

Omentum and Peritoneum.—Normal.

Spleen.—The spleen was normal in size, and showed no tubercles either on the surface or on section.

Liver.—Normal.

A gland on the anterior border of the head of the pancreas showed four opaque white caseous foci.

Another gland near the hilum of the liver was normal.

The Splenic, Lumbar, Iliac, and Inguinal Glands were normal.

Kidneys.—The kidneys were pale, but showed no tubercles.

Alimentary Tract.

Tongue, Pharynx, Tonsils.—Normal.

Submaxillary and Pharyngeal Glands.—Normal.

Small Intestines.—Nearly all the Peyer's patches showed small caseous areas, the mucous membrane over which was ulcerated.

Large Intestine.—The mucous membrane of the large intestine was extensively ulcerated, especially towards the lower end; in the ascending colon the ulcers were more or less circular, the margins being a little raised and thickened; in the descending colon they had coalesced and formed large areas with serpiginous margins; the bases were not thickened, and there was no sign that the ulcers were tuberculous.

Mesenteric Glands.—Most of the mesenteric glands were enlarged, though not greatly. They showed under the capsule yellow caseous patches and foci which did not extend deeply into the substance.

Colic Glands.—The colic glands appeared enlarged, but were not caseous.

Microscopical Examination

Tubercle from the Lung.—Very numerous tubercle bacilli.

Smear from the Spleen.—A few tubercle bacilli.

RHESUS MONKEY 143. Virus H. 84. "M.S."

(A young animal.)

Subcutaneous inoculation of culture derived from the original material through Guinea-pig 2277.

Dose—1·0 milligramme.

Date of Inoculation—March 5, 1908.

Died—June 23, 1908. [110 days after inoculation.]

Weight at death—1610 grammes.

POST-MORTEM EXAMINATION.

The carcass was emaciated.

Local Lesion.—At the seat of inoculation over the right scapula there was a large pear-shaped ulcer with thin well-defined edges in places a little undermined measuring 4·2 by 3·3 cm.; the stalk of the pear lay towards the axilla. The floor of the ulcer was pinkish yellow in colour, composed of a very thin layer of tough caseous substance, showing, when cut, beads of caseo-pus; beneath it was tough white fibroid tissue. When the lesion was dissected off several small caseo-purulent nodules were seen in the thin layer of muscle overlying the scapula, and a few larger ones in adjoining muscles.

Extending from the thin end of the ulcer into the right axilla were confluent caseo-purulent nodules which enveloped and infiltrated the scapular muscles and formed a large caseo-purulent mass in the axilla, close to the group of axillary glands.

Right Axillary Glands.—In the right axilla there was a large prominent swelling in the centre of which was a circular ulcer 1 cm. in diameter, with thin edges and caseous floor; close by was a similar but smaller ulcer.

On removing the skin the floors of the ulcers were found to be part of a large gland measuring 2 by 1·3 cm. which was almost entirely composed of confluent softening caseous nodules; adherent to it was a gland the size of a pigeon's egg composed of thick muco-purulent substance contained in a fibrous capsule. Two small attached glands contained each a caseous nodule; a third was apparently normal.

Left Axillary Glands.—In the left axilla there were four congested and pigmented glands the size of peas one of which contained a millet-seed-sized firm yellow caseous tubercle, another a group of small yellow foci. The others showed no tubercles.

In the fascia of the left pectoral muscle close to the axillary glands there was a yellow purulent nodule the size of a hempseed.

Cervical Glands.—Normal.

Submaxillary Glands.—Two right submaxillary glands, the largest measuring 1·7 by 1 cm., the other the size of a hempseed, were found. The former was composed of soft caseous nodules in a fibroid matrix, the latter of muco-pus contained in a thin translucent capsule.

The submaxillary salivary glands were normal.

Inguinal Glands.—A right inguinal gland the size of a large pea was composed of soft yellow caseous substance which shelled out from a fibrous capsule. Another contained a firm yellow nodule.

One left inguinal gland the size of a small pea contained two soft yellow foci; a slightly larger gland showed a soft yellow nodule 2 mm. in diameter. Other inguinal glands were normal.

Precrural Glands.—The right precrural glands were normal; a left precrural gland, slightly enlarged, contained a soft yellow nodule.

Vertebral Glands.—One small vertebral gland in the tenth interspace on the right side was yellow and caseous. Another in the seventh interspace contained a caseous focus. Other vertebral glands were normal.

Thorax.

Lungs.—The lungs were crepitant and normal in general appearance. Sparsely scattered small greyish translucent tubercles with opaque whitish centres were seen on the surfaces of both lungs (about twenty counted on the right lung). None was seen on section.

Bronchial Glands—Of a group of small glands situated at the bifurcation of the trachea one was caseous throughout, another contained a caseous tubercle.

Two other glands (praetracheo-bronchial) were affected: one contained a greyish white tubercle the size of a millet-seed, another contained a minute tubercle.

Heart.—Normal.

Pleura.—Normal.

The fourth rib on the left side was swollen close to its head. On section the bony tissue was thickened and showed a cavity containing caseo-purulent substance.

Abdomen.

Omentum and Peritoneum.—The omentum and parietal peritoneum were normal.

There was a prominent tubercle on the right side of the diaphragm, about 3 mm. in diameter, composed of softened caseous substance; it was adherent to the liver.

Spleen.—The spleen was enlarged, measuring 4·5 by 2·5 by 1·2 cm. The surface was rendered nodular by

the projection of nodules of various sizes. On section it showed numerous yellowish white caseo-purulent nodules ranging from 1 to 4 mm. in diameter. These nodules had thin translucent capsules.

Liver.—The liver showed on the surface about fifteen yellowish white tubercles, ranging up to 2·5 mm. in diameter, and also a moderate number of minute indefinite greyish-white foci unevenly distributed, being most numerous in the right lobe of the liver. These minute foci were here and there visible on section ; no larger tubercles were seen.

Portal Glands.—A group of several glands in the portal region measured 2 by 1·6 cm. On section they were all occupied to a large extent by softened caseous nodules.

Kidneys.—On the surface of the left kidney under the capsule four small yellowish-white tubercles were seen, and also two grey translucent tubercles with small opaque centres. Besides these a few grey foci were just visible.

On section about half-a-dozen yellowish tubercles were seen in the cortex similar to those on the surface.

On the surface of the right kidney seven small yellowish-white tubercles were counted, and there was one nodule which measured 3 by 2 mm. and was composed of firm caseous substance which did not shell out from the surrounding kidney tissue.

On section about half-a-dozen minute yellowish tubercles were seen in the cortex.

Suprarenal Bodies.—The left showed one minute yellowish tubercle. The right was normal.

Lumbar Glands.—These glands were enlarged and contained caseous tubercles.

Iliac Glands.—One on the left side contained a caseous tubercle. The right iliac gland was caseous throughout.

Alimentary Tract.

Tongue.—At the tip of the tongue there was a deep V-shaped ulcer, 0·7 cm. in diameter, the floor of which was composed of yellow caseous material which could be scraped away.

Tonsils.—Normal.

Parotideal Glands.—Normal.

Pharyngeal Glands.—The gland on the right side was very small and normal ; that on the left side was much enlarged, measuring 1·5 by 1 by 0·6 cm. On section it contained small smooth-walled cavities filled with muco-pus.

Small Intestine.—In the small intestine there were four or five small yellow caseous nodules situated under the mucous membrane ; one was ulcerated. The majority were in the duodenal end of the intestine.

The small intestine was otherwise normal.

Large Intestine. — The large intestine showed numerous ulcers throughout its entire length. The ulcers were small, irregular, and more numerous in some places than in others. They were covered with loosely attached ragged necrotic substance, which projected in the majority of cases beyond the margins of the ulcers to which it was adherent. When this was scraped away, in some cases one found an ulcer with raised congested margins, and in others a smooth floor from which apparently the mucous membrane had disappeared.

The peritoneal surface of the intestine was normal.

Mesenteric Glands.—The mesenteric glands were much enlarged, the largest measuring 1·1 by 1 cm. ; nearly all contained large yellowish nodules, some firm, the majority caseo-purulent.

Ileo-colic Glands. — The ileo-colic glands were swollen ; several showed yellowish tubercles in the cortex.

Brain.—On the cerebrum on the left side at the edge of one of the convolutions there was a firm raised nodule, about 2 mm. in diameter, yellowish in colour. On section it extended about 2·5 mm. into the grey matter.

Skull. — When the scalp was removed, several prominent yellow nodules were seen scattered over the surface of the skull, and two or three yellow patches were faintly seen through the bony wall. When the skull cap was removed, ten yellow patches and nodules in all were counted. The majority originated apparently in the cancellous tissue, the rest on the outer surface of the skull ; all penetrated the bony wall of the skull to some depth, and in one or two cases it was completely pierced.

The nodules were composed of softened caseous substance.

Muscles.—In the temporal muscle on the right side near its attachment there was a softened caseous nodule.

In the muscle of the abdominal wall on the right side there was a small soft yellow patch. Lying between the peritoneum and the muscle wall on the left side of the abdomen there was a large yellow mass measuring 1 by 0·5 cm., composed of caseo-purulent substance. Close by, in the muscle of the iliac region, there was a similar but smaller nodule.

Larynx and Trachea.—Normal.

Testes.—Normal.

Microscopical Examination.

Ulcer from Tongue.—Tubercle bacilli moderately numerous.

Necrotic Tissue from Large Intestine.—Tubercle bacilli numerous.

RHESUS MONKEY 145. Virus H. 84. "M.S."

(A young animal.)

Fed with culture derived from the original material through Guinea-pig 2277.

Dose—1·0 milligramme.

Date of Feeding—March 5, 1908.

Killed when well—July 22, 1908. [139 days after feeding.]

Clinical Notes.

The monkey remained quite well during the experiment.

Weight when killed 2300 grammes.

POST-MORTEM EXAMINATION.

The carcass was in good condition.

Alimentary Tract.

Tonsils.—The tonsils were not enlarged. There was a soft whitish focus in the right which readily shelled out.

There was a small quantity of secretion in the crypts of the left tonsil which was otherwise normal.

Tongue and Pharynx.—In the lymphoid tissue at the base of the tongue there were several whitish foci.

The buccal mucous membrane was normal.

Submaxillary Glands.—On the left side there was a large gland 3 cm. in length and 1·5 cm. in greatest thickness composed throughout of cheesy caseous substance slightly greenish in colour.

On the right side there was a gland the size of a

sparrow's egg which was also composed throughout of cheesy caseous substance.

Two other glands on this side were normal.

Retro-pharyngeal Glands.—The gland on each side was much enlarged (1·5 cm. in greatest diameter) and was composed throughout of greenish yellow caseo-pus surrounded by a thick fibrous capsule.

Cervical and Axillary Glands.—Normal.

Intestines.—Two Peyer's patches about the middle of the small intestine each contained a small fibrous tubercle; two others showed a small ulcer with slightly thickened margins and base; there was no sign of caseation; one of the latter patches also contained a pinhead-sized submucous tubercle with a whitish centre.

The large intestine was normal.

Mesenteric Glands.—The mesenteric glands were slightly enlarged and contained discrete caseous and softening nodules the largest the size of a hempseed. The caseous material readily shelled out and in no case replaced more than about half the gland substance.

Colic and Ileo-colic Glands.—One colic gland contained a hempseed sized caseous nodule. The ileo-colic and the rest of the colic glands were normal.

Thorax.

Lungs.—The lungs were pink and crepitant; the right caudal lobe showed near the dorsal surface a firm caseating nodule, 1 cm. in greatest diameter, softened in the centre. The rest of the lung contained sparsely scattered shotty tubercles with fibrous margins and caseous centres, the largest about 1·5 mm. in diameter.

Bronchial Glands. — An intertracheo - bronchial gland on the right side was the size of a kidney bean and showed more than half its substance yellow, caseous, and softened. The one on the left side was normal.

A praetracheo-bronchial gland on the right side contained a hempseed-sized caseous nodule, and one on the left a millet-seed sized caseous nodule.

Heart and Pleura.—Normal.

Abdomen.

Omentum and Peritoneum.—The omentum contained numerous discrete tubercles with caseous centres and grey margins, the largest the size of a millet seed. There were about half-a-dozen similar tubercles on the floor of the abdomen and similar sparsely-scattered tubercles on the mesentery and mesocolon.

Spleen.—The spleen was slightly enlarged, chiefly at one extremity where it contained two caseous and softened nodules, one 1 cm. in diameter, formed by the fusion of several small ones, and one the size of a small pea.

In the rest of the spleen pulp there were sparsely-scattered caseous nodules up to 2 mm. in diameter.

Splenic Glands.—One splenic lymphatic gland contained a hempseed sized caseous nodule, another a small caseous tubercle.

Liver.—The liver showed scattered miliary caseating tubercles and half-a-dozen larger yellow caseous nodules up to a pea in size.

The gland on the head of the pancreas showed a few caseous tubercles, other pancreatic glands were normal.

Kidneys and Suprarenal Bodies.—Normal.

Lumbar and Iliac Glands.—Normal.

Inguinal Glands.—Normal.

Microscopical Examination.

Smears from Lung (large nodule).—(1) A few tubercle bacilli. (2) A few tubercle bacilli.

Smear from Liver Tubercle.—A few tubercle bacilli.

Focus from Right Tonsil.—A few tubercle bacilli.

Focus from Tongue.—No tubercle bacilli.

RHESUS MONKEY 117. Virus H. 84. "M.S."

(A young animal.)

Subcutaneous inoculation of culture derived from the original material through Guinea-pig 2277.

Dose—Slightly less than 10·0 milligrammes.

Date of Inoculation—April 27, 1908.

Died—July 9, 1908. [73 days after inoculation.]

Clinical Notes.

The monkey remained fairly well until the end of June; he then lost appetite and became thin and ill-looking. Weakness and emaciation followed and the monkey died on July 9.

Weight at death—1,750 grammes.

Temperature.

On the ninth day after inoculation the temperature rose to 40·0° C.; a maximum of 41·2° C. was reached on the 23rd day. The temperature remained high (about 40·0° C.) for several weeks; from June 26th onwards it fell gradually to below 35·0° C.

POST-MORTEM EXAMINATION.

The carcass was emaciated.

Local Lesion.—The skin over the left scapula showed an ulcer measuring 4 by 2·5 cm. in diameter, with sinuous inverted and slightly undermined margins and smooth fibrous floor showing here and there small thin yellowish congested patches. The margins of the ulcer under the skin were slightly thickened but there was no sign of caseation.

Axillary Glands.—One on the right side contained a millet-seed sized caseous tubercle, the rest were normal. On the left side two, each about the size of a large pea, were fused together and were caseous and softened throughout.

Three smaller glands contained discrete yellowish-white caseous nodules.

Cervical Glands.—Two behind the right clavicle each contained a caseous tubercle, the larger the size of a millet seed.

Behind the clavicle on the left side two, the size of large peas, were cheesy and caseous throughout; two contained each a small caseous nodule.

A gland in the middle of the neck on the left side contained a caseous nodule 2 mm. in diameter.

Vertebral Glands.—Normal.

Thorax.

Lungs.—The lungs were pink and crepitant and slightly adherent to the dorsal pleura. They contained sparsely - scattered translucent grey shotty tubercles ranging from 1 to about 1·5 mm. in diameter; the majority were homogeneous throughout, but here and there one was caseous and slightly opaque in the centre.

Bronchial Glands.—The bronchial glands were

normal in size and showed altogether four caseous tubercles, the largest 1 mm. in diameter.

Heart and Pleura.—Normal.

Abdomen.

Omentum and Peritoneum.—The omentum showed a moderate number of minute translucent grey tubercles and two caseous tubercles the size of millet-seeds.

The peritoneum was normal.

Spleen.—The spleen was little if at all enlarged (5 by 2·2 by 1 cm.), and contained a moderate number of discrete yellow caseous nodules with grey fibrous margins, ranging in diameter up to 2 mm.; they were much less numerous than in the more acute cases.

Liver.—The liver was normal in colour, and contained only a moderate number of evenly distributed firm caseous nodules with grey margins, ranging from 1 to 3 mm. in diameter.

The gland between the head of the pancreas and the liver was not enlarged; it contained scattered caseous tubercles, the largest the size of a millet-seed. Other glands on the pancreas, the gastric glands and the iliac and lumbar glands, showed no tubercles.

Kidneys.—The left kidney showed on the surface one miliary caseous tubercle. The right was normal.

Suprarenal Bodies.—Normal.

Alimentary Tract.

Tongue, Pharynx.—Normal.

Tonsils.—The left tonsil contained a minute soft whitish focus.

Submaxillary Glands.—One submaxillary gland contained a pinhead-sized caseous tubercle.

Pharyngeal Glands.—Normal.

Intestines.—Normal.

Mesenteric Glands.—The mesenteric glands were a little enlarged and contained altogether two caseous tubercles, one a mere point, the other a millimetre in diameter.

Ileo-colic and Colic Glands.—The ileo-colic and colic glands were slightly enlarged and oedematous, but showed no tubercles.

Testicles.—Normal.

Brain.—Normal.

Microscopical Examination.

Tubercle from Omentum.—Exceedingly numerous tubercle bacilli.

Tubercle from a Mesenteric Gland.—Very numerous tubercle bacilli.

Focus from the Left Tonsil.—A few tubercle bacilli.

RHESUS MONKEY 231. Virus H. 84. "M.S."

(A young animal.)

Subcutaneous inoculation of culture derived from the lung of Monkey 145.

Dose—1·0 milligramme.

Date of Inoculation—September 24, 1908.

Died—October 25, 1908. [31 days after inoculation.]

Clinical Notes.

The course of the disease was similar to that usually seen in monkeys suffering from acute tuberculosis.

The weight at death was 1,830 grammes.

POST-MORTEM EXAMINATION.

The carcass was thin.

Local Lesion.—In the subcutaneous tissues over the right scapula there was an abscess 4·5 cm. in greatest diameter, the contents of which were light brownish yellow caseo-pus. The skin over it showed a small opening through which pus could be expressed.

Axillary Glands.—On the right side two moderately enlarged glands were caseous and softened practically throughout; another the size of a pea was partly caseous, and another contained a discrete caseous tubercle.

On the left side two contained each a few miliary caseous tubercles.

Cervical Glands.—On the right side behind the clavicle there were three caseous and softened glands the largest the size of a pea.

On the left side there was one gland about 5 mm. in diameter caseous throughout.

Other cervical glands were normal.

Vertebral Glands.—A gland in the 7th and one in the 9th interspace on the right side were enlarged (greatest diameter 7 mm.) and were each caseous and softened throughout. Two others in the 10th and 11th interspaces contained discrete caseous tubercles. Other vertebral glands were normal.

Thorax.

Lungs.—The lungs were pink and crepitant throughout. They contained sparsely-scattered miliary caseous tubercles. Ten were counted on the surface of the right and about a dozen on that of the left.

Bronchial Glands.—The bronchial glands were very slightly enlarged and contained each a few caseous tubercles, the largest the size of a millet-seed.

Pleura and Heart.—Normal.

Abdomen.

Omentum.—There were two small tubercles, one grey the other caseous, in the omentum, and a few minute grey points possibly early tubercles.

Peritoneum.—Normal.

Spleen.—The spleen was enlarged measuring 4·5 by 3·5 by 1·5 cm. and very closely beset with yellow caseous nodules, the largest 2·5 mm. in diameter.

The splenic lymphatic glands were slightly enlarged and contained each a few miliary caseous tubercles.

Liver.—The liver was enlarged, paler than normal, and contained moderately numerous evenly distributed opaque yellow caseous tubercles ranging from a mere point up to 1·5 mm. in diameter.

The glands on the head of the pancreas were enlarged and showed their cortices extensively replaced by yellow caseous and softened nodules.

Kidneys.—In the cortex of the left there was one pin-head sized yellow caseous tubercle. The right kidney was normal.

Suprarenal Bodies.—Normal.

Iliac and Lumbar Glands.—One iliac gland contained a pinhead-sized caseous tubercle. The lumbar glands were slightly enlarged and each contained several caseous tubercles.

Alimentary Tract.

Tongue, Tonsils, Pharynx.—Normal.

Retro-pharyngeal and Submaxillary Glands.—There was one caseous tubercle in a pharyngeal gland and each submaxillary gland contained a caseous tubercle or two.

Intestines.—Normal.

Mesenteric Glands.—There were three millet-seed sized caseous tubercles and a few very minute ones in the mesenteric glands.

Colic Glands.—One colic gland contained a caseous tubercle.

Inguinal Glands.—Two inguinal glands on each side contained each one pinhead-sized caseous tubercle.

Brain.—Not examined.

Microscopical Examination.

Emulsion of Spleen.—Tubercle bacilli numerous.

RHESUS MONKEY 233. Virus H. 84. "M.S."

Subcutaneous inoculation of culture derived from the lung of Monkey 145.

Dose—1·0 milligramme.

Date of Inoculation—September 24, 1908.

Died—September 27, 1908. [3 days after inoculation.]

POST-MORTEM EXAMINATION.

The body was in good condition and all the organs were healthy. Nothing was found to account for the death of the animal.

RHESUS MONKEY 367. Virus H. 84. "M.S."

(A young animal.)

Subcutaneous Inoculation of culture derived from the spleen of Guinea-pig 2486, inoculated with the original culture.

Dose—1·0 milligramme.

Date of Inoculation—January 1, 1910.

Died—March 23, 1910. [81 days after inoculation.]

POST-MORTEM EXAMINATION.

The carcass was emaciated. Its weight was 1,470 grammes.

Local Lesion.—Between the scapulae there was a hemispherical caseous tumour 4·5 cm. in greatest diameter the skin over which had just broken down.

Axillary Glands.—On the left side there were two and on the right one enlarged caseous and softened glands the largest 1·5 cm. in length.

Cervical Glands. — In the left posterior triangle there was a group of three and in that of the right two similar caseous glands. Other cervical glands were normal.

Inguinal Glands.—These glands contained altogether six caseous tubercles and a hempseed-sized caseous nodule.

Vertebral Glands.—On the right side two glands the size of split peas, and on the left one rather smaller, were caseous throughout.

Thorax.

Lungs.—The lungs were crepitant and contained a moderate number of grey miliary tubercles the majority with minute caseous centres.

Bronchial Glands. — The bronchial glands were slightly enlarged and contained discrete caseous nodules.

Heart and Pleura.—Normal.

Abdomen.

Omentum. — The omentum showed moderately numerous grey tubercles.

Spleen.—The spleen was enlarged measuring 6·5 by 3·5 by 1·8 cm. and beset with softened caseous nodules up to 4 mm. in diameter.

Splenic Lymphatic Glands.—There was a caseous tubercle in each of two glands.

Liver.—The liver was normal in general appearance and showed a few minute greyish-white tubercles.

Portal Gland.—The portal gland was slightly enlarged and showed in the cortex four softened caseous nodules.

Kidneys.—In the cortex of each there were scattered grey tubercles with caseous centres, the largest 2 mm. in diameter.

Lumbar and Iliac Glands.—Normal.

Alimentary Tract.

Tongue, Pharynx, Tonsils.—Normal.

Submaxillary Glands.—On the right side the glands contained three caseous nodules up to a hempseed in size ; those on the left were normal.

Retro-Pharyngeal Glands.—Normal.

Intestines.—There was a caseous tubercle or two in the wall of the small intestine, and a few in that of the large intestine.

Mesenteric Glands.—These contained a few caseous nodules.

Brain.—There were two millet-seed sized caseous tubercles in the cortex of the brain.

VIRUS H. 85. "H.B."

LUPUS.

CULTURE INOCULATIONS.

I.—August 20, 1907.

The strain was derived from the original material through G.P. 2363, and had been in artificial cultivation a total period of 83 days.

The culture used was the 5th generation, 22 days old.

GUINEA-PIGS.

Number.	Method.	Dose.	Duration of Life.	Result.
2574	Intrap.	1·0 mg.	D. 26 days	G. T.
2575	Subcut.	1·0 mg.	D. 140 „	G. T.

RABBITS.

Number.	Method.	Dose.	Duration of Life.	Result.
1474	Intrav.	1·0 mg.	D. 11 days	S. T. of lungs. Death from psorospermosis.
1473	Intrav.	0·1 mg.	D. 39 „	General miliary T.
1475	Intrap.	1·0 mg.	D. 41 „	General miliary T.
1476	Subcut.	10·0 mg.	K. 153 „	Slight chronic G. T., apparently progressive in the lungs.

CALF 1289.

Subcutaneous.

Dose: 50·0 mg.

Killed: November 22, 1907.

94 days.

P.M.—The local tumour was a cyst with caseo-purulent contents. The prescapular gland was partly dense and caseous, partly calcareous. The thoracic, ileocolic, and portal glands contained calcareous patches; nearly all the other glands in the body contained a varying number of calcareous or caseous tubercles. There was one tubercle in the lung, moderately numerous miliary tubercles in the spleen, one in a suprarenal body, and a few small tubercles in the Peyer's patches.

II.—September 13, 1907.

The strain was derived from the original material through G.P. 2365, and had been in artificial cultivation a total period of 98 days.

The culture used was the 5th generation, 22 days old.

RABBITS.

Number.	Method.	Dose.	Duration of Life.	Result.
1495	Intrav.	1·0 mg.	D. 21 days	G. T.
1496	Intrav.	0·1 mg.	D. 48 „	G. T.
1497	Intrap.	10·0 mg.	D. 35 „	G. T.
1498	Subcut.	20·0 mg.	D. 34 „	Local T.; slight T. of lungs and one tubercle in spleen.

GUINEA-PIGS.

Number.	Method.	Dose.	Duration of Life.	Result.
2595	Intrap.	1·0 mg.	D. 14 days	G. T.
2596	Subcut.	1·0 mg.	D. 86 „	G. T.

III.—December 13, 1907.

The strain was derived from the original material through G.P. 2365, and had been in cultivation a total period of 189 days.

The culture used was the 14th generation, 21 days old.

CALF 1331.

Subcutaneous.

Dose: 96·0 mg.

Killed: March 12, 1908.

90 days.

P.M.—There was a small-fibrous walled cyst with caseo-purulent contents at the seat of inoculation. The left prescapular gland, very slightly enlarged, contained two calcareous patches. There was no tuberculosis elsewhere.

Guinea-pig 2992.

Intraperitoneal.

Emulsion of spleen.

Killed: 117 days. Slight G.T.

RABBITS.

Number.	Method.	Dose.	Duration of Life.	Result.
1591	Intrav.	1·0 mg.	D. 31 days	General miliary T.
1592	Intrav.	0·1 mg.	D. 38 „	General miliary T.
1593	Subcut.	10·0 mg.	D. 49 „	Slight and non-progressive G. T. Death due to secondary infection of the local lesion.
1594	Subcut.	10·0 mg.	D. 96 „	Local T. and slight T. of lungs. Death probably due to same cause.

GUINEA-PIGS.

Number.	Method.	Dose.	Duration of Life.	Result.
2847	Intrap.	0·1 mg.	D. 40 days	G. T.
2848	Subcut.	0·1 mg.	D. 123 „	G. T.

MONKEY 123.

Subcutaneous.

Dose: 1·0 mg.

Died: April 23, 1908.

132 days.

P.M.—Flat caseous patch in the subcutaneous tissues at the seat of inoculation. Many axillary, cervical and vertebral glands were enlarged caseous and softened; others contained caseous tubercles. The lungs (crepitant) showed a moderate number of small grey nodules, some with caseous centres. The spleen was much enlarged and closely beset with softened caseous nodules up to a pea in size. The liver contained a few small caseous softened nodules; there were two in the right kidney. The bronchial and several abdominal glands contained one or two caseous tubercles each.

MONKEY 121.

Subcutaneous.

Dose: 0·1 mg.

Killed: March 19, 1908.

97 days.

P.M.—Cyst containing caseous substance and watery fluid at the seat of inoculation. One right axillary gland was much enlarged, and consisted of a thin-walled cyst with caseo-purulent contents. One vertebral gland was enlarged and caseous. Each lung contained about 40 small translucent tubercles, and a few larger ones with caseous centres. A few caseo-purulent tubercles were seen in the portal and pancreatic glands, and a few foci (containing very numerous T.B.) in one or two mesenteric glands. The Malpighian bodies of the spleen were conspicuous, and a few T.B. were seen in a smear from one.

Guinea-pig 3011.

Intraperitoneal.

Emulsion of spleen.

Died: 34 days. No obvious tuberculosis, but T.B. seen in pyloric and sternal glands.

MONKEY 119.

Subcutaneous.

Dose: 0·01 mg.

Died: September 9, 1908.

271 days.

P.M.—Caseous and softened tumours at seat of inoculation. The right axillary, cervical, and inguinal glands were greatly enlarged caseous and softened. The adjacent vertebral glands formed a large caseous mass. The bronchial and several abdominal glands showed varying degrees of caseation, some being severely affected. There were four caseous and softened nodules in the lungs and 20 in the spleen (up to 1·5 cm.). There was a moderate number of grey tubercles in the liver. In the intestine there was one caseous tubercle.

IV.—January 11, 1908.

The strain was derived from the original material through G.P. 2365, and had heen in artificial cultivation a total period of 218 days.

The culture used was the 16th generation, 24 days old.

MONKEY 125.

Fed.

Dose : 1·0 mg.

Died : May 6, 1908.

116 days.

P.M. — One suhmaxillary and one pharyngeal gland were enlarged caseous aud softened. Ahout a dozen caseous nodules and tuhercles were seen in the small intestine, some of which were ulcerated, and there was one in the large intestine. All the mesenteric, nine colic, and one rectal glands were enlarged and caseous. The spleen contained one softened caseous nodule, the liver nine or ten (the largest the size of a pea). The lungs contained nine dense caseous nodules up to 1 cm. in diameter. Three thoracic glands were caseous.

MONKEY 127.

Fed.

Dose : 0·1 mg.

Killed when dying : May 5, 1908.

115 days.

P.M.—One submaxillary gland was caseous and softened. The glands in the anterior part of the mesentery formed a large caseous and softened mass ; two only in the posterior part were affected. One ileo-colic, many colic, and three rectal glands were caseous or contained caseous nodules. There were several firm caseous nodules along the mesenteric veins. There was no tuherculous ulceration of the intestine. The spleen contained six caseous and softened nodules ; there were three or four miliary caseous tuhercles in the lung.

FOWLS.

Number.	Method.	Dose.	Duration of Life.	Result.
77	Intrav.	10·0 mg.	K. 146 days	No T.
75	Intrav.	1·0 mg.	K. 146 „	No T.

Guinea-pig 3104.

Intraperitoneal.

Emulsion of spleen of Fowl 77.

Died : 49 days. G. T.

RABBITS.

Number.	Method.	Dose.	Duration of Life.	Result.
1651	Intrav.	1·0 mg.	D. 16 days	G. T.
1652	Subcut.	16·0 mg.	K. 72 „	Local T. and scattered miliary tuhercles in lungs and kidneys.

GUINEA-PIGS.

Number.	Method.	Dose.	Duration of Life.	Result.
2879	Intrap.	1·0 mg.	D. 17 days	G. T.
2880	Subcut.	1·0 mg.	D. 56 „	G. T.

V.—January 28, 1908.

The strain was derived from the original material through G.P. 2363, and had heen in artificial cultivation a total period of 244 days.

The culture used was the 9th generation, 12 days old.

HORSE 5.

Subcutaneous.

Dose : 50·0 mg.

Killed : May 19, 1908.

112 days.

P.M. — There was a patch of fihrous tissue at the seat of inoculation. In the left prescapular region there were two large glands filled with caseo-pus, aud many smaller caseous glands ; one left cervical gland was large and caseous ; another contained a caseous nodule. Sparsely scattered small grey tuhercles were seen in the lungs, spleen and liver.

PIG 115.

Suhcutaneous.

Dose : 50·0 mg.

Killed : Nov. 30, 1908.

307 days.

P.M. — Slight general tnherculosis apparently retrogressive.

PIG 117.

Suhcutaneous.

Dose : 10·0 mg.

Killed : Oct. 22, 1908 (when in good condition).

268 days.

P.M. — Severe general tuberculosis of a chronic type.

GOAT 63.

Subcutaneous.

Dose : 10·0 mg.

Killed : March 5, 1909 (when very ill).

402 days.

P.M. — Severe chronic general tuherculosis.

RABBIT 1705.

Suhcutaneous.

Dose : 40·0 mg.

Died : 157 days.

P.M. — Chronic G. T. not severe.

VI.—March 6, 1908.

The strain was derived from the original material through G.P. 2365, and had heen in cultivation a total period of 273 days.

The culture used was the 22nd generation, 19 days old.

HORSE 11.

Intravenous.

Dose : 10·0 mg.

Died : April 26, 1908.

51 days.

P.M.—Acute general tuherculosis. T.B. swarming everywhere.

CALF 1373.

Intravenous.

Dose : 10·0 mg.

Killed when dying : April 3, 1908.

28 days.

P.M.—The lungs were almost entirely red firm and airless, and speckled with indefinite and irregular greyish foci (giving a moss-like pattern). In the crepitant lohules no tuhercles were seen. The thoracic glands were enlarged and firmer than normal. T.B. were numerous in the organs and in the glands examined.

CHIMPANZEE 9.

Cutaneous.

Dose : 0·01 mg.

Died : August 23, 1908.

170 days.

P.M.—There was no lesion at the seat of inoculation hetween the shoulders. In the right axilla there was an ulcer with caseo-purulent floor (which had developed out of a hroken-down caseous gland). Other axillary glands were normal, and there was no tuberculosis elsewhere.

GUINEA-PIGS.

—	Number.	Method.	Duration of Life.	Result.
E. of spleen.	3222	Intrap.	K. 74 days	Slight T.
	3223	Intrap.	K. 74 „	No T.
E. of nodule from floor of ulcer.	3224	Intrap.	K. 74 „	Slight G. T.
	3225	Intrap.	K. 74 „	G. T.

CHIMPANZEE 11.

Fed.

Dose : 1·0 mg.

Killed : December 2, 1908.

271 days.

P.M.—There was a focus of yellow pus in one tonsil. Ahout two dozen small ulcers were seen in the lower half of the small intestine, the majority shallow without caseation. There was a large mass composed of enlarged caseous and softened glands in the anterior end of the mesentery ; elsewhere the glands were separate, and ahout 16 in all were caseous and softened. One pancreatic gland was similar. In the spleen there was a mass (1 cm.) composed of aggregated caseous nodules. One axillary gland was caseous. There was a tubercle in the liver, and two on the serous surface of the small intestine.

GUINEA-PIGS

Inoculated with an emulsion of mesenteric gland.

Number.	Method.	Dose.	Duration of Life.	Resnlt.
3389	Intrap.	Very small	D. 140 days.	G.T.
3390	Intrap.	Rather larger.	D. 158 „	Severe G.T.

VIRUS H. 85. "H.B." [Lupus]—*continued.*

CULTURE INOCULATIONS—*continued.*

VII.—April 11, 1908.

The strain was derived from the original material through G.P. 2365 and had been in cultivation a total period of 309 days.

The culture used was the 24th generation, 22 days old.

RABBITS.

Number.	Method.	Dose.	Duration of Life.	Result.
1822	Intrav.	1·0 mg.	D. 10 days	Early T. of lungs and spleen.
1823	Intrav.	0·1 mg.	D. 110 „	General miliary T.
1824	Intrav.	0·01 mg.	D. 117 „	G. T.

MONKEY 153.

Subcutaneous.

Dose : 10·0 mg.

Killed when ill : June 9, 1908.

59 days.

P.M.—Large foul ulcer at seat of inoculation. The adjacent glands contained caseous patches and nodules. The lungs contained sparsely scattered grey tubercles, and there were two minute tubercles in the right kidney. T.B. were numerous in a smear from the spleen.

MONKEY PASSAGE EXPERIMENT.

CULTURE

Derived from original material through G.P. 2365.

December 13, 1907.

RHESUS MONKEY 119.

Subcutaneous.

Dose : 0·01 mg.

Died : September 9, 1908.

271 days.

P.M.—General tuberculosis

CULTURE

Derived from spleen of Monkey 119 ; the 4th generation, 11 days old was used for inoculation on October 30, 1908 : total duration of cultivation, 51 days.

RABBITS.

Number.	Method.	Dose.	Duration of Life.	Result.
1591	Intrav.	1·0 mg.	D. 31 days	General miliary T.
1592	Intrav.	0·1 mg.	D. 38 „	General miliary T.
1593	Subcut.	10·0 mg.	D. 49 „	Slight non-progressive T. Death due to secondary infection of local lesion.
1594	Subcut.	10·0 mg.	D. 96 „	Local T. and slight T. of lungs. Death probably due to secondary infection.

RHESUS MONKEY 235.

Subcutaneous.

Dose : 1·0 mg.

Died : December 17, 1908.

48 days.

P.M. — General tuberculosis not severe and insufficient to account for death which was probably hastened by cold.

RHESUS MONKEY 237.

Subcutaneous.

Dose : 1·0 mg.

Died : December 20, 1908.

51 days.

P.M.—Spontaneous tuberculosis.

RABBITS.

Number.	Method.	Dose.	Duration of Life.	Result.
2054	Intrav.	1·0 mg.	D. 39 days	General miliary T.
2055	Intrav.	0·1 mg.	D. 38 „	General miliary T.
2056	Intrav.	0·01 mg.	D. 136 „	G. T. (not severe).

VIRUS H. 85. "H.B." [Lupus]—*continued.*

CALF PASSAGE EXPERIMENT.

CULTURE.

Strain derived from original material through G.P. 2363. Duration of artificial cultivation, 83 days.

AUGUST 20, 1907.

CALF 1289.

Subcutaneous.

Dose : 50·0 mg.

Killed : November 22, 1907. (94 days.)

P.M.—The local tumour was a cyst with caseo-purulent contents. The prescapular gland was partly dense and caseous, partly calcareous. The thoracic, ileo-colic, and portal glands contained calcareous patches, nearly all the other glands in the body contained a varying number of caseous or calcareous tubercles. There was one tubercle in the lung, moderately numerous miliary tubercles in the spleen, one in a suprarenal, and a few small tubercles in the Peyer's patches.

RABBITS.

Number.	Method.	Dose.	Duration of Life.	Result.
1474	Intrav.	1·0 mg.	D. 11 days	Death from psorospermosis. Slight T. of lungs.
1473	Intrav.	0·1 mg.	D. 39 ,,	General miliary T.
1475	Intrap.	1·0 mg.	D. 41 ,,	General miliary T.
1476	Subcut.	10·0 mg.	K. 153 ,,	Slight chronic G.T., apparently progressive in the lungs.

Emulsion of left prescapular gland. (T.B. moderately numerous.)

CALF 1319.

Subcutaneous. Dose : 20·0 cc. of emulsion.

Killed : March 11, 1908. 110 days.

P.M.—There was a small patch of fibrous tissue containing opaque foci at the seat of inoculation. The left prescapular and one left prepectoral gland were not enlarged but contained small calcareous patches. There was no tuberculosis elsewhere.

RABBITS.

Number.	Method.	Dose.	Duration of Life.	Result.
1565	Subcut.	2·0 cc.	K. 189 days	Local T. and slight T. of lungs.
1566	Subcut.	2·0 cc.	D. 83 ,,	Local T. and slight T. of lungs. Death from cellulitis of back.

GUINEA-PIGS 2989, 2990.

Intraperitoneal. E. of prescapular gland.

K. 28 days. Early G. T.

APRIL 8, 1908. E. of tissues from G.P's. 2989–90 (T.B. not very numerous).

CALF 1397.

Subcutaneous.

Dose : 20·0 cc. of emulsion.

Killed : July 30, 1908. 113 days.

P.M.—Fibrous-walled cyst with caseo-purulent contents. The left prescapular gland was largely occupied by two caseous softened masses. There were three little tubercles in the lungs and seven caseous tubercles in the spleen ; the thoracic and renal glands contained scattered caseous tubercles : there was one in a pudic gland and one or two in the portal glands.

RABBIT 1816.

Subcutaneous.

Dose : 3·0 cc.

Died : 228 days.

P.M.—Chronic general tuberculosis.

CULTURE.

Derived from the mediastinal gland of Calf 1397.

The 4th generation of culture, 12 days old, was used for inoculation on October 3, 1908.

CALF 1445.

Subcutaneous.

Dose : 50·0 mg. (rather less than).

Killed : January 6, 1909. 95 days.

P.M.—Fibrous-walled cyst with caseo-purulent contents ; adjacent glands caseous and gritty. In the lungs, heart, and each kidney there were from two to five tubercles. The thoracic glands were extensively calcareous. The suprarenals contained numerous caseo-calcareous nodules ; the small intestine numerous nodules with caseous centres, some ulcerated, the large intestine numerous small ulcers. Many abdominal and peripheral glands contained caseous or calcareous tubercles more or less numerous.

RABBITS.

Number.	Method.	Dose.	Duration of Life.	Result.
2020	Subcut.	10·0 mg.	D. 137 days	G. T. not sufficient to account for death.
2021	Subcut.	10·0 mg.	K. 209 ,,	Local T., and slight T. of lungs and kidneys.

(*For continuation of the Passage Experiment see opposite page.*)

VIRUS H. 85. "H.B." [Lupus]—*continued.*

CALF PASSAGE EXPERIMENT—*continued.*

(*Continued from previous page.*)

CULTURE.

Derived from the mediastinal gland of Calf 1445. The 4th generation, 11 days old, was used for inoculation on February 17, 1909.

CALF 1531.

Subcutaneous. Dose : 50·0 mg.
Killed: May 12, 1909. 84 days.
P.M.—General progressive tuberculosis, moderately severe in the liver.

RABBITS.

Number.	Method.	Dose.	Duration of Life.	Result.
2174	Subcut.	10·0 mg.	D. 134 days	Chronic G. T. (not severe).
2175	Subcut.	10·0 mg.	D. 120 „	Chronic G. T. (not severe).

CULTURE.

Derived from the liver of Calf 1531. The 4th generation, 11 days old, was used for inoculation on June 28, 1909.

CALF 1565.

Subcutaneous. Dose : 50·0 mg.
Killed : October 5, 1909. 99 days.
P.M.—Very slight generalised retrogressive tuberculosis.

RABBITS.

Number.	Method.	Dose.	Duration of Life.	Result.
2378	Subcut.	10·0 mg.	K. 147 days	Slight G. T.
2379	Subcut.	10·0 mg.	D. 144 „	Chronic G. T. (not severe).

RABBITS AND GUINEA-PIGS INOCULATED TO TEST THE VIRULENCE OF THE BACILLI AFTER PASSAGE THROUGH THE 1st AND 2nd CALVES OF THE EXPERIMENT.

Culture derived from the prescapular gland of Calf 1289. The 4th generation, 24 days old, was used on January 22, 1908, for inoculating:

RABBITS.

Number.	Method.	Dose.	Duration of Life.	Result.
1692	Intrav.	1·0 mg.	D. 29 days	G. T.
1693	Subcut.	24·0 mg.	D. 133 „	Local T. and slight chronic T. of lungs and kidneys
1694	Subcut.	10·0 mg.	K. 464 „	Local T. and slight T. of lungs.

GUINEA-PIGS.

Number.	Method.	Dose.	Duration of Life.	Result.
2906	Subcut.	1·0 mg.	D. 39 days	Early G.T.
2907	Subcut.	1·0 mg.	D. 37 „	G.T.

Culture derived from Calf 1319 (left bronchial gland) through Guinea-pig 2991. The 4th generation, 22 days old, was used on July 3, 1908, for inoculating :

RABBITS.

Number.	Method.	Dose.	Duration of Life.	Result.
1921	Subcut.	20·0 mg.	D. 194 days	Slight G.T. ? cause of death.
1922	Subcut.	10·0 mg.	D. 211 „	G. T. (not severe).

VIRUS H. 85. "H.B." [Lupus]—*continued.*

RHESUS MONKEYS INOCULATED TO TEST THE VIRULENCE OF THE BACILLI AFTER PASSAGE THROUGH FIVE CALVES IN SERIES.

Culture derived from the liver of Calf 1531. The 4th generation, 11 days old, was used for inoculation on June 28, 1909.

MONKEY 333.

Subcutaneous. 1·0 mg.

Died: August 18, 1909. 51 days.

P.M.—Slight generalised tuberculosis; cause of death not apparent.

MONKEY 335.

Subcutaneous. 1·0 mg.

Died: August 6, 1909. 39 days.

P.M.—Very slight generalised tuberculosis; cause of death not apparent.

CALF 1331. Virus H. 85. "H.B."

Subcutaneous inoculation of culture derived from the original material through Guinea-pig 2365.

Dose—96·0 milligrammes.

Date of Inoculation—December 13, 1907. [Age about 14 weeks.]

Killed when well—March 12, 1908. [90 days after inoculation.]

Clinical Notes.

The calf remained well during the experiment.

Temperature.

Normal.

Tuberculin Tests.

February 21, 1908. [70 days after inoculation.] 1·0 cc. tuberculin (human). No reaction. Rise of temperature, 0·3° C.

March 4, 1908. [82 days after inoculation.] 4·0 cc. tuberculin (avian). No reaction. Rise of temperature, 0·1° C.

Weights.

	cwt.	qrs.	lbs.
December 13, 1907	1	1	2
March 12, 1908	1	2	20

Total gain of weight.—1 qr. 18 lbs.

Average rate of gain per week.—3·5 lbs.

POST-MORTEM EXAMINATION.

The carcass was in good condition.

Local Lesion.—In the subcutaneous tissues on the left side of the neck there was a circumscribed fluctuating tumour measuring 7 by 4·5 by 3·5 cm. On section it was a cyst with fibrous walls and thick creamy caseo-purulent contents.

Left Prescapular Gland.—The left prescapular gland measured 5·5 by 3 by 1·5 cm. and showed two irregular calcareous patches the largest 2 cm. in greatest diameter; the rest of the gland was normal. The patches were composed of calcareous grains set in a brownish translucent matrix.

The Right Prescapular Gland measured 4·3 by 2 by 1 cm. and was normal on section.

Axillary and Cervical Glands.—Normal.

Thorax.

Pleura, Lungs, Thoracic Glands, Heart.—Normal.

Abdomen.

Omentum and Peritoneum, Liver, Spleen, Kidneys, Suprarenals.—Normal.

Renal, Lumbar, Iliac, Coeliac, and Portal Glands.—Normal.

Alimentary Tract.

Tongue, Pharynx, Palate, Tonsils.—Normal.

Submaxillary, Retro-pharyngeal, Parotideal Glands.—Normal.

Intestines and Mesenteric Glands.—Normal.

Various Peripheral Lymphatic Glands.

Precrural, Popliteal, Gluteal, Ischiatic, Pudic.—Normal.

Animal Inoculated.

Guinea-pig 2992 was inoculated intraperitoneally with an emulsion made from the spleen. It was killed 117 days later, and showed slight general tuberculosis.

CALF 1289. Virus H. 85. "H.B."

Subcutaneous inoculation of culture derived from the original material through Guinea-pig 2363.

Dose—50·0 milligrammes.

Date of Inoculation—August 20, 1907. [Age about 13 weeks.]

Killed when in good health—November 22, 1907. [94 days after inoculation.]

Clinical Notes.

A rather prominent tumour developed at the seat of inoculation which subsequently became pendulous and fluctuant; it opened and discharged on November 21. The prescapular and other glands adjacent to the tumour became moderately enlarged.

The calf showed no sign of ill-health during the period of the experiment.

Temperature.

On the 10th day after inoculation the temperature rose to 39·8° C., and it reached a maximum of 40·1° C. on the 16th day; it then slowly declined to the normal. From the 38th day onwards the temperature was quite normal.

Tuberculin Test.

October 24, 1907. [65 days after inoculation.] Reacted. Rise of temperature, 1·5° C.

Weights.

	cwt.	qrs.	lbs.
August 20, 1907	1	0	25
November 22, 1907	1	3	10

Total gain of weight.—2 qrs. 13 lbs.

Average rate of gain per week.—5·14 lbs.

POST-MORTEM EXAMINATION.

The carcass was in good condition.

Local Lesion.—At the seat of inoculation on the left side of the neck there was a prominent fluctuating tumour measuring 10 by 7 by 6 cm., the skin over the centre of which showed a ragged ulcerous opening discharging caseo-pus; on section it was a cyst with thick fibrous walls and caseo-purulent contents with some firm caseous masses; the cavity was lined with pale granulation tissue and crossed by thick fibrous trabeculæ.

Left Prescapular Gland.—The left prescapular gland measured 7 by 4 by 2·5 cm.; on section about half the gland was composed of dense caseous slightly gritty substance; the rest of the gland was normal (the cortex at one extremity was free from tuberculosis) or contained calcareous patches.

Between the skin and the lower extremity of the prescapular gland there was a gland about the size of half a walnut which on section showed dense caseous patches and calcareous foci.

Right Prescapular Gland.—The right prescapular gland was slightly enlarged, measuring 6 by 2·5 by 1·2 cm.; it showed in the cortex about sixteen soft caseous gritty nodules ranging in size from a pin's head to that of a hemp seed.

Prepectoral Glands.—On the left side one the size of a pea was dense and caseo-calcareous throughout; the rest were normal. Those on the right side were normal.

Cervical Glands.—On the left side four glands were affected, containing from one to four small calcareous tubercles; in the upper cervical gland there was a soft caseous tubercle about 2 mm. in diameter.

On the right side the glands in the middle of the neck each contained a few minute calcareous tubercles; the superior cervical glands were normal.

Axillary Glands.—There was one miliary caseo-calcareous tubercle in the cortex of the left; the right was normal.

Thorax.

Pleura, Heart, and Pericardium.—Normal.

Lungs.—The lungs were perfectly normal in general appearance; under the pleura of the right cephalic lobe one pinhead-sized grey tubercle was found; no tubercles were seen elsewhere either on the surface or on section.

Thoracic Glands.—The bronchial and dorsal mediastinal glands were perhaps slightly enlarged; on section they showed throughout their substance calcareous patches of various sizes composed of loosely aggregated calcareous tubercles; these glands were rather more severely affected than the portal.

Abdomen.

Omentum and Peritoneum.—Normal.

Spleen.—The spleen was not enlarged; on section grey miliary tubercles with calcareous centres were evenly distributed throughout.

Liver.—The liver was normal in appearance; the substance showed very sparsely scattered grey or greyish-yellow foci of a doubtful nature; there were no definite tubercles.

Portal Glands.—The portal glands were slightly enlarged; on section they were rather closely beset with irregular calcareous tubercles arranged mainly in nodular groups, the gland tissue surrounding them being a little firmer than normal.

Coeliac Glands.—The coeliac glands contained a number of small discrete calcareous tubercles.

Kidneys.—Normal.

Suprarenal Bodies.—There were two millet-seed sized caseo-calcareous tubercles in the right suprarenal body; the left was normal.

Renal Gland.—The renal gland contained a minute calcareous tubercle.

Lumbar Glands.—There were two or three small calcareous tubercles in one of the lumbar glands and in another a minute calcareous grain.

Iliac Glands.—Normal.

Sacro-iliac Glands.—One contained a few calcareous tubercles.

Alimentary Tract.

Tongue, Pharynx, Palate, Tonsils.—Normal.

Retro-pharyngeal Glands.—Each contained a number of small discrete calcareous tubercles.

Submaxillary Glands.—The left contained a number of millet-seed sized calcareo-caseous tubercles. The right was smaller than the left and contained similar but less numerous tubercles.

Parotideal Glands.—These glands each contained several yellow softened caseous gritty nodules up to a hemp seed in size.

Intestines.—In every Peyer's patch there were a few yellow pinhead-sized caseo-calcareous tubercles the mucous membrane over which was intact.

The large intestine was normal.

Mesenteric Glands.—Each gland showed in the cortex a few irregular calcareous nodules, the largest varying up to about 5 mm. in diameter.

Ileo-Colic Glands.—The ileo-colic glands resembled the portal, but were not quite so severely affected.

Genito-Urinary System.

Testicles.—Normal.

Various Lymphatic Glands.

The *Popliteal, Precrural, and Pudic Glands* each contained several yellow softened caseous gritty nodules varying in size from a hemp seed to that of a pin's head.

Gluteal Glands.—The left contained a millet-seed sized calcareo-caseous tubercle, the right was normal.

Ischiatic Glands.—Normal.

Microscopical Examination.

Emulsion of Prescapular Gland.—Tubercle bacilli in moderate numbers.

Tubercle from the Right Suprarenal.—Tubercle bacilli in moderate numbers.

Tubercle from the Small Intestine.—Tubercle bacilli scanty.

Animals Inoculated.

An emulsion was made from the left prescapular gland and inoculated subcutaneously into Calf 1319, dose 20·0 cc., and into Rabbits 1565 and 1566, dose 2·0 cc. each. Both the rabbits showed only slight disseminated tuberculosis when killed 189 and 83 days after inoculation respectively.

CALF 1373. Virus H. 85. "H.B."

Intravenous inoculation of culture derived from the original material through Guinea-pig 2365.

Dose—10·0 milligrammes.

Date of Inoculation—March 6, 1908. [Age about 11 weeks.]

Killed when dying—April 3, 1908. [28 days after inoculation.]

Clinical Notes.

The calf was first noticed to be ill about a week after inoculation; the respiration was quickened and the animal had lost its appetite. The respiratory difficulty became more marked, the animal became progressively weaker and more emaciated, and was killed in a dying condition 28 days after inoculation.

Temperature.

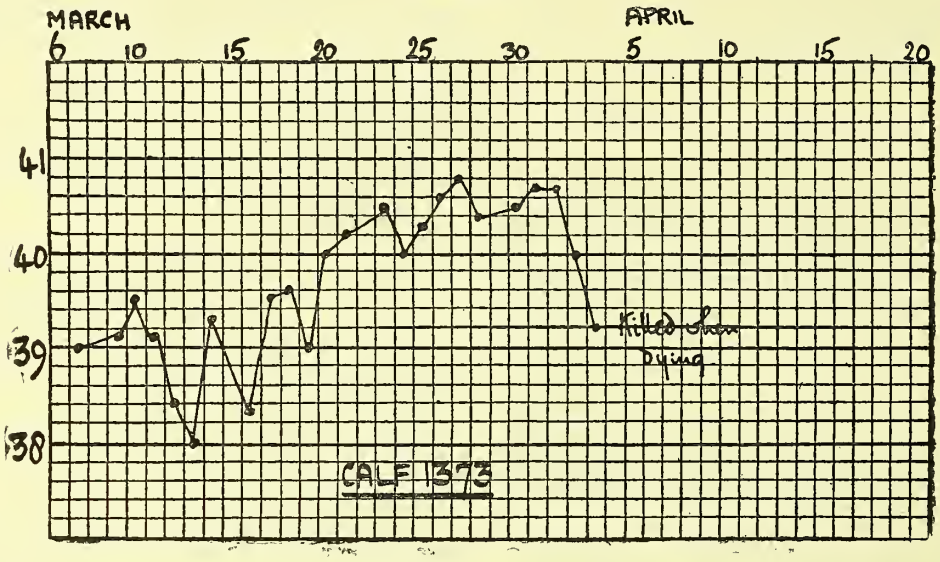

Tuberculin Test.

The calf was not tested subsequent to inoculation.

Weights.

	qrs.	lbs.
March 6, 1908	3	22
April 3, 1908	3	0

Total loss of weight.—22 lbs.

Average rate of loss per week.—5·5 lbs.

POST-MORTEM EXAMINATION.

The carcass was very emaciated.

Thorax.

Lungs.—The lungs did not collapse on opening the chest; they weighed 5 lbs. The anterior lobes and the greater portions of the caudal lobes were red firm and quite airless; in the dorsal parts of both caudal lobes and in the thin margin of the right there were a few normally crepitant lobules. The red solid parts from the surface were speckled with greyish yellow foci up to about 1 mm. in diameter, and on section they showed numerous irregular grey foci indefinite and dendritic in outline (giving a moss-like pattern) in the caudal lobes, more definite and like miliary tubercles in the cephalic.

The trachea, bronchi and small bronchioles were filled with mucus.

In the crepitant lobules no definite tubercles were seen.

Thoracic Glands.—The dorsal mediastinal and the bronchial glands were enlarged, they weighed together $4\frac{1}{4}$ ozs.; the caudal gland measured 13 cm. in length. The cortices were firmer and greyer than normal, and the glands generally were slightly congested; there was no sign of caseation.

Heart.—Normal.

Pleura.—Normal.

Abdomen.

Omentum and Peritoneum.—Normal.

Spleen.—The spleen was not enlarged; the pulp was firm, the Malpighian bodies appeared enlarged, and the cut surface was rather more granular looking than usual.

Liver.—The liver was pale; no definite foci were seen in it.

Portal Glands.—The portal glands were oedematous: no tubercles were visible in them.

Kidneys.—Normal.

Suprarenal Bodies.—Normal.

Renal, Lumbar, and Iliac Glands.—Normal.

Alimentary Tract.

Tongue, Pharynx, Tonsils.—Normal.

Submaxillary, Retro-pharyngeal, and Parotideal Glands.—Normal.

Intestines and Mesenteric Glands.—Normal.

Testes.—Normal.

Various Lymphatic Glands.

Precrural, Popliteal, Prescapular, Cervical, Axillary, Gluteal, Ischiatic, Pudic.—Normal.

Microscopical Examination.

(Smears from)

Lung.—Tubercle bacilli numerous, chiefly in clumps.

Liver.—Tubercle bacilli moderately numerous, chiefly in clumps.

Spleen.—Tubercle bacilli numerous.

Kidney.—Tubercle bacilli numerous.

Axillary Gland.—Tubercle bacilli very numerous.

Gluteal Gland.—Tubercle bacilli numerous.

In each specimen the bacilli occurred chiefly in clumps; there were many long beaded and curved forms.

CALF 1319. Virus H. 85. "H.B."

Subcutaneous inoculation of an emulsion of the left prescapular gland of Calf 1289.

Dose—20·0 cc. of emulsion, which contained tubercle bacilli in moderate numbers.

Date of Inoculation—November 22, 1907. [Age about 18 weeks.]

Killed when in good health—March 11, 1908. [110 days after inoculation.]

Clinical Notes.

A small thickened patch was felt at the seat of inoculation a fortnight after inoculation, and the adjacent prescapular gland was slightly enlarged. The thickening and enlargement subsequently almost entirely disappeared.

The calf remained well during the experiment.

Temperature.

Normal.

Tuberculin Tests.

February 21, 1908. [91 days after inoculation.] 1·0 cc. of tuberculin (human). Reacted. Rise of temperature, 1·4° C.

March 3, 1908. [102 days after inoculation.] 4·0 cc. of tuberculin (avian). No reaction. No rise of temperature.

Weights.

	cwt.	qrs.	lbs.
November 22, 1907	1	2	16
March 11, 1908	2	1	17

Total gain of weight.—3 qrs. 1 lb.

Average rate of gain per week.—5·4 lbs.

POST-MORTEM EXAMINATION.

The carcass was in good condition.

Local Lesion.—In the subcutaneous tissues on the left side of the neck there was a small thin patch of fibrous tissue containing a few small opaque whitish foci, not perceptibly gritty.

Left Prescapular Gland.—The left prescapular gland was about the same size as the right; it showed in the cortex towards one extremity a few small patches composed of calcareous grains.

Right Prescapular Gland.—The right prescapular gland measured 5·5 by 2 5 by 1 cm., and was normal on section.

Prepectoral Glands.—The spherical gland on the left side, not enlarged, showed in the cortex some small calcareous patches; other prepectoral glands were normal.

Cervical and Axillary Glands.—Normal.

Thorax.

Pleura, Lungs, Thoracic Glands, Heart.—Normal.

Abdomen.

Omentum and Peritoneum, Spleen, Liver, Kidneys, and Suprarenal Bodies.—Normal.

Portal, Coeliac, Renal, Lumbar, and Iliac Glands.—Normal.

Alimentary Tract.

Tongue, Pharynx, Palate, Tonsils.—Normal.

Submaxillary, Retropharyngeal and Parotideal Glands.—Normal.

Intestines and Mesenteric Glands.—Normal.

Various Peripheral Glands.

Precrural, Popliteal, Gluteal, Ischiatic, Pudic.—Normal.

Microscopical Examination.

Emulsion of Left Prescapular Gland.—No tubercle bacilli seen.

Emulsion of Left Bronchial Gland.—No tubercle bacilli seen.

Animals Inoculated.

Guinea-pigs 2989 and 2990 were inoculated intraperitoneally with an emulsion of the prescapular gland, and 2991 intraperitoneally with an emulsion made from the left bronchial gland.

The latter died in 54 days, and showed slight general tuberculosis; the former were killed after 28 days, and showed early general tuberculosis.

CALF 1397. Virus H. 85. "H.B."

Subcutaneous inoculation of an emulsion made from the tuberculous tissues of two guinea-pigs, 2989 and 2990, inoculated with an emulsion of prescapular gland from Calf 1319.

Dose—20·0 cc. of the emulsion. Tubercle bacilli were easily found in it, but were not very numerous.

Date of Inoculation—April 8, 1908.

Killed when in good health—July 30, 1908. [113 days after inoculation.]

Clinical Notes.

The calf remained well during the experiment.

Temperature.

There was a period of high temperature commencing on the seventeenth day and lasting seventeen days (maximum 40·5° C.). Subsequently the temperature was normal.

Weights.

	cwt.	qrs.	lbs.
April 8, 1908	0	3	16
July 30, 1908	1	1	17

Total gain of weight.—2 qrs. 1 lb

Average rate of gain per week.—3·5 lbs.

POST-MORTEM EXAMINATION.

The carcass was in good condition.

Local Lesion.—At the seat of inoculation on the left side of the neck there was a prominent fluctuating tumour measuring 11 by 8·5 by 6 cm.; on section it was a cyst with thick fibrous walls and yellow caseo-purulent contents.

Left Prescapular Gland.—The left prescapular gland measured 7 by 4 by 3·5 cm.; on section about three-quarters of the gland substance was replaced by two large caseous masses almost completely softened.

Right Prescapular Gland.—The right prescapular gland measured 4·5 by 2 by 1 cm. and was normal on section.

Prepectoral, Cervical, and Axillary Glands.—Normal.

Thorax.

Pleura.—Normal.

Lungs.—The lungs were crepitant and collapsed normally ; under the pleura one miliary tubercle with a calcareous centre was seen ; there were also two minute transparent tubercles ; no tubercles were seen on section.

Thoracic Glands.—The bronchial and mediastinal glands were normal in size ; they contained discrete yellowish caseous tubercles ranging in diameter from 1 to 2 mm. ; the tubercles were slightly gritty from calcification and were not very numerous.

Heart.—Normal.

Abdomen.

Omentum and Peritoneum.—Normal.

Spleen.—Seven caseous slightly gritty tubercles the size of millet seeds were seen in the spleen pulp.

Liver, Kidneys, and Suprarenal Bodies.—Normal.

Portal Glands.—There were two minute gritty tubercles in the cortices of these glands.

Renal Glands.—The renal glands (two) contained a few small caseous gritty tubercles, the largest the size of a pin's head.

Lumbar and Iliac Glands.—Normal.

Testicles.—Normal.

Alimentary Tract.

Tongue, Pharynx, Tonsils.—Normal.

Submaxillary, Retro-pharyngeal, and Parotideal Glands.—Normal.

Intestines and Mesenteric Glands.—Normal.

Various Lymphatic Glands.

Precrural, Popliteal, Gluteal, Ischiatic.—Normal.

Pudic.—The left pudic gland contained a caseous tubercle 1·5 mm. in diameter. The right was normal.

Microscopical Examination.

Emulsion of Prescapular Gland.—Tubercle bacilli in moderate numbers.

Emulsion of Thoracic Gland.—No tubercle bacilli seen.

CALF 1445. Virus H. 85. "H.B."

Subcutaneous inoculation of culture derived from the thoracic gland of Calf 1397.

Dose—Rather less than 50·0 milligrammes, a little escaping during the inoculation.

Date of Inoculation—October 3, 1908. [Age about 7 months.]

Killed when in good health—January 6, 1909. [95 days after inoculation.]

Clinical Notes.

A firm raised swelling developed at the seat of inoculation on the left side of the neck which on October 19 measured 10 by 8 cm. The tumour afterwards became soft and fluctuating but did not ulcerate through the skin.

The left prescapular gland became enlarged hard and nodular ; an enlarged left prepectoral gland could also be felt.

The calf remained well during the experiment.

Temperature.

There was a period of slight and irregular pyrexia for five weeks following the inoculation ; the highest temperature recorded during this period was 40·5° C., the lowest 38·5° C.

The temperature then remained normal for seven weeks.

During the last eleven days of the animal's life the temperature was again slightly raised and irregular (maximum 40·0° C., minimum 38·1° C.).

Weights.

			cwt.	qr.	lbs.
October 3, 1908	...	...	2	0	8
January 6, 1909	...	...	2	1	25

Total gain of weight.—1 qr. 17 lbs.

Average rate of gain per week.—3·3 lbs.

POST-MORTEM EXAMINATION.

The carcass was in good condition.

Local Lesion.—At the seat of inoculation on the left side of the neck there was a fluctuating swelling measuring 7·5 by 6 by 4 cm. composed of softened and breaking-down caseous substance surrounded by a wall of fibrous tissue.

Left Prescapular Gland.—The left prescapular gland was irregularly enlarged and nodular in outline ; it measured 6 by 4 by 3 cm. and showed on section three caseous and softened masses gritty around the margins, the largest 2·5 cm. in diameter ; they replaced nearly threequarters of the gland substance ; each had a thin fibrous wall ; the glandular tissue that remained showed discrete caseous nodules varying up to a small pea in size.

Right Prescapular Gland.—The right prescapular gland measured 4·2 by 2 by 1 cm. and was normal on section.

Prepectoral Glands.—On the left side one, the size of a walnut, was composed of dense yellow caseous substance gritty around the margins and surrounded by a very thick fibrous capsule. Others were normal.

Cervical Glands.—On the left side one, at the root of the neck, showed in the cortex a calcareous patch about 1 cm. in greatest diameter ; the rest were normal.

Thorax.

Lungs.—The lungs were crepitant throughout, with the exception of one lobule which was red and consolidated and contained a soft greyish yellow focus. Just under the pleura three minute grey (?) tubercles were seen and one hempseed-sized softened caseous nodule with a fibrous wall. No tubercles were seen on section.

Thoracic Glands.—The bronchial and dorsal mediastinal glands were slightly enlarged and firmer than normal ; on section the substance of the glands was extensively replaced by granular calcareous areas ; in some cases a half, in others nearly three-quarters of the gland consisted of calcareous deposit.

Heart.—Under the endocardium of the right auricle were two translucent grey tubercles ; there were two similar tubercles under the endocardium of the right

ventricle with minute grey granules on the membrane around them.

Pleura.—Normal.

Abdomen.

Omentum and Peritoneum.—Normal.

Spleen and Liver.—Normal.

Portal Glands.—The portal glands were normal in size and showed in the cortex scattered calcareous foci up to 2 mm.

Kidneys.—No tubercles were seen on the surface; on section four nodules, the largest 3 mm. in diameter, were seen in the medulla of the right and five in that of the left; the nodules were grey and translucent and had caseous or minute calcareous centres.

Suprarenal Bodies.—The cortex of each suprarenal contained numerous nodules, thirty being counted in that of the left and more than forty in that of the right; the right suprarenal was distinctly enlarged and had a nodular outline, the nodules in the cortex projecting from the surface; the left suprarenal was not obviously enlarged but the nodules in the cortex were plainly seen from the surface, some causing slight projections; the nodules varied from 2 to 4 mm. in diameter and had caseous or caseo-calcareous centres and broad grey margins.

Coeliac Glands.—One coeliac gland contained a pin-head sized calcareous tubercle.

Renal, Lumbar, and Iliac Glands.—Normal.

Alimentary Tract.

Tongue, Pharynx, Tonsils.—Normal.

Submaxillary Glands.—The right submaxillary gland contained a hempseed-sized caseous and softened nodule with a fibrous wall; the left was normal.

Retro-pharyngeal Glands.—The left contained a caseous nodule rather smaller than a hempseed. The right was normal.

Parotideal Glands.—Normal.

Small Intestines.—The first few feet of the small intestine were normal; then small slightly raised nodules with soft caseous centres were seen under the mucous membrane as well as in Peyer's patches; proceeding onwards lesions rapidly became more numerous and throughout the rest of the intestine the mucous surface was studded with numerous raised nodules, the largest 5 mm. in diameter with central congested depressions or ulcerations. On section they were found to be caused by local thickenings of the submucous tissues, some of which had softened caseous centres. Usually about twenty-four nodules were counted in each foot of intestines, occasionally there were as many as forty.

Large Intestines.—The mucous membrane of the caecum and colon showed numerous small ulcers with broad slightly raised margins; there was no sign of caseation in the centre and very little thickening of the submucous tissue.

Mesenteric Glands.—The first few glands, in the anterior part of the mesentery, were normal; the others contained scattered calcareous tubercles, becoming more numerous in the glands towards the posterior end of the mesentery.

Ileo-colic Glands.—These glands contained calcareous patches and moderately numerous discrete calcareous tubercles.

Colic Glands.—The colic glands examined contained each one or two calcareous tubercles.

Testicles.—Normal.

Various Lymphatic Glands.

Precrural and Popliteal Glands.—Normal.

Axillary Glands.—Normal.

Gluteal Glands.—There were two millet-seed sized caseous tubercles in the left gluteal, and a minute caseous tubercle in the right.

Ischiatic Glands.—The left contained a millet-seed sized caseous tubercle; the right was normal.

Microscopical Examination.

(Smears from)

Caseous nodule from Lung.—No tubercle bacilli seen.

Nodule from Kidney.—No tubercle bacilli seen.

Emulsion of Right Suprarenal Body.—A few tubercle bacilli seen.

Emulsion of Long Mediastinal Gland.—A moderate number of tubercle bacilli seen.

Centre of ulcer from Small Intestine.—A few tubercle bacilli seen.

CALF 1531. Virus H. 85. "H.B."

Subcutaneous inoculation of culture derived from the mediastinal gland of Calf 1445.

Dose—50·0 milligrammes.

Date of Inoculation—February 17, 1909. [Age 6 months.]

Killed when in good health—May 12, 1909. [84 days after inoculation.]

Clinical Notes.

The calf remained in good health during the experiment and grew normally.

Temperature.

On the ninth day the temperature rose to 39·5° C. and 41·0° C. was reached on the 15th day. The temperature then slowly declined to the normal; the pyrexia lasted 19 days in all. The temperature subsequently remained normal.

Weights.

	cwt.	qrs.	lbs.
February 17, 1909	1	3	4
May 12, 1909	2	1	14

Total gain of weight.—2 qrs. 10 lbs.

Average rate of gain per week.—5·5 lbs.

POST-MORTEM EXAMINATION.

The carcass was in good condition.

Local Lesion.—At the seat of inoculation on the left side of the neck there was a firm tumour measuring 12 by 8 by 4 cm. (including skin); on section it was composed of greatly thickened skin (1·2 cm. in thickness) and pinkish fibrous tissue containing discrete encapsuled caseous and softened nodules up to a pea in size, and a small cavity communicating externally filled with caseo-pus.

Left Prescapular Gland.—In front of the left shoulder there was a mass measuring 13 cm. in length by 5 cm. in thickness, the lower end of which was soft and fluctuating, the upper elastic; on section the upper part of the mass was composed of firm caseous gritty substance partially detached from its capsule, representing the prescapular gland proper, the lower was a caseo-purulent abscess surrounded by a thinned expansion of the capsule; the capsule was lined internally by granulation tissue.

The Right Prescapular Gland measured 4·6 by 2·3 by 1 cm. and was normal on section.

Prepectoral Glands.—On the left side one 2 cm. in diameter was caseous and softened throughout and had a thick fibrous capsule. The others were normal.

Cervical Glands.—On the left side in the lower part of the neck there were two glands forming a mass measuring 8 by 3 by 3 cm.; on section both were caseous throughout and partly softened, and had very thick fibrous capsules (up to 5 mm. thick).

Another gland near the above the size of a broad-bean was caseous throughout. One in the middle of the neck contained about half-a-dozen caseous tubercles.

On the right side one contained a caseous gritty tubercle 2 mm. in diameter. The rest were normal.

Thorax.

Lungs.—The lungs were crepitant throughout and contained a moderate number of nodules ranging from 2 to 7 or 8 mm. in diameter; they had fibrous walls and soft caseous gritty centres; they were most numerous on the lower lateral surfaces of the caudal lobes (31 were counted in an area 5 cm. square); nearer the dorsal border a similar area showed only 12.

On section nodules were scattered throughout the parenchyma; they appeared to be less numerous than on the surface.

There were also a few tubercles scattered about which were less than 2 mm. in diameter.

Thoracic Glands.—The bronchial and dorsal mediastinal glands were not enlarged, they contained discrete caseous gritty tubercles and a few larger caseo-calcareous nodules; the tubercles were moderately numerous in some of the glands, less numerous in the others.

Pleura and Heart.—Normal.

Abdomen.

Omentum and Peritoneum.—Normal.

Spleen.—The spleen was normal in size and showed in the pulp seven caseous slightly gritty tubercles with fibrous margins the largest the size of a millet-seed.

Liver.—The liver showed on the surface numerous fairly evenly distributed nodules ranging in size from 2 to 7 or 8 mm. in diameter, the majority varied from 3 to 6 mm.; twenty-four nodules were counted in an area 5 cm. square; some of the nodules projected slightly, a few having slightly "mushroomed" margins, the others had a layer of liver tissue between them and the capsule; the nodules had thick fibrous margins and softened caseous gritty centres.

Similar nodules were distributed throughout; twelve were counted in an area of the cut surface 5 cm. square.

Portal Glands.—The portal glands were not enlarged; there were four caseous gritty tubercles in one gland and two in another; a third was normal.

Pancreatic Glands.—One contained a caseous tubercle and a minute calcareous tubercle.

Kidneys.—In the cortex of the left under the capsule there were two millet-seed sized tubercles, one grey, the other greyish-white; there were also many small pale areas which on section extended into the kidney cortex in a wedge-shaped manner.

In the depth of the cortex of the right kidney there was one grey tubercle; there were also pale streaks as in the left.

Suprarenal Bodies.—Normal.

Renal Glands.—In one on the left side there was a pin head-sized caseous tubercle.

Lumbar and Iliac Glands.—Normal.

Alimentary Tract.

Tongue, Pharynx, Tonsils; Submaxillary, Retro-pharyngeal, and Parotideal Glands.—Normal.

Intestines.—Three Peyer's patches in the small intestine contained scattered yellow foci; in the jejunum there was one submucous caseous tubercle.

The large intestine was normal.

Mesenteric Glands.—The mesenteric glands contained about a score of nodules and tubercles varying in size from a wheat-grain to a small pin's head; the smallest ones were calcareous, the larger caseous and gritty; eight of the nodules were in one gland, the terminal one in the posterior part of the mesentery.

Ileo-colic Glands.—There were a few caseous tubercles in these glands.

Testes.—Normal.

All the peripheral lymphatic glands were examined and found normal.

Microscopical Examination.

Emulsion of Tubercles from Lung.—No tubercle bacilli seen.

Emulsion of Tubercles from Mediastinal Gland.—A few tubercle bacilli.

Emulsion of Nodule from Liver.—One tubercle? bacillus seen.

CALF 1565. Virus H. 85. "H.B."

Subcutaneous inoculation of culture derived from the liver of Calf 1531.

Dose—50·0 milligrammes.

Date of Inoculation—June 28, 1909. [Age about 14 weeks.]

Killed when in good health—October 5, 1909. [99 days after inoculation.]

Clinical Notes.

The calf remained well during the experiment and grew normally.

Temperature.

The temperature rose to 39·7° C. on the 15th day and reached a maximum (40·5° C.) on the 19th day; it then gradually declined to the normal; the pyrexia lasted 13 days in all. The temperature subsequently remained normal.

Tuberculin Test.

August 16, 1909. [49 days after inoculation.] Dose, 2·0 cc. Reacted. Rise of temperature, 1·4° C.

Weights.

	cwt.	qr.	lbs.
June 28, 1909	1	1	3
October 5, 1909	2	0	15

Total gain of weight.—3 qrs. 12 lbs.

Average rate of gain per week.—7 lbs.

POST-MORTEM EXAMINATION.

The carcass was in good condition.

Local Lesion.—In the subcutaneous tissues on the left side of the neck there was a flat patch measuring 9 by 5·5 by 0·7 cm. of fibroid tissue containing scattered calcareous or caseous foci; the skin over it was slightly thickened.

Left Prescapular Gland.—The left prescapular gland measured 6·5 by 3·5 by 2 cm. and showed about two-thirds of its substance composed of dense caseous gritty substance.

Right Prescapular Gland.—The right prescapular gland measured 5·7 by 2 by 1·4 cm. and was normal on section.

Prepectoral Glands.—Normal.

Thorax.

Lungs.—The lungs were crepitant and showed under the pleura very sparsely scattered tubercles ranging from a mere point up to about 1 mm. in diameter; the smallest ones were grey and homogeneous but the others were calcareous in the centre. A few similar tubercles were seen on section.

Thoracic Glands. — The bronchial and dorsal mediastinal glands were not enlarged; they showed on section a moderate number of irregular calcareous foci and patches of various sizes mostly small composed of aggregated calcareous foci.

Abdomen.

Spleen.—Eight miliary calcareous tubercles were found in the pulp.

Portal Glands.—These were normal in size and contained scattered yellow submiliary calcareo-caseous foci.

Intestines.—The mucous membrane of the small intestine showed a dozen small ulcers with thick raised rounded margins; the Peyer's patches were normal.

The mucous membrane of the large intestine showed seven ulcers similar to those in the small intestine.

Mesenteric and Ileo-colic Glands.—The mesenteric glands contained sparsely scattered irregular calcareous tubercles, one to three or four in each gland.

The ileo-colic glands contained similar tubercles.

Iliac Glands.—One contained a small calcareous tubercle, the others were normal.

There was one calcareous tubercle in each of the following glands: the *left submaxillary*, and the *right and left retro-pharyngeal.*

Mammary Lymphatic Glands.—In one there were two calcareous tubercles and one caseous tubercle.

There was no sign of tuberculosis in any other organ or gland.

GOAT 63 [Kid]. Virus H. 85. "H.B."

Subcutaneous inoculation of culture derived from the original material through Guinea-pig 2363.

Dose—10·0 milligrammes.

Date of Inoculation—January 28, 1908. [5 months old.]

Killed when very ill.—March 5, 1909. [402 days after inoculation.]

Clinical Notes.

The goat was very ill when killed 13 months after inoculation. He was breathing with a short rapid and forced inspiration, and was very thin and emaciated; he had been in this condition for a long time.

Temperature.

The temperature was raised during the whole period of the experiment; it was usually between 39·0° and 40·0° C. and showed but little variation from day to day. The temperature was highest from the 3rd to the 12th day after inoculation, and during September and October 1908; temperatures varying from 40·0 to 40·6° C. were frequently recorded during these periods.

The temperature was lowest during January and February 1909 and showed a gradual fall; during the last week of February and the first week in March it was usually below 39·0° C.

Tuberculin Tests.

March 4, 1908. [36 days after inoculation.] Dose, 1·0 cc. Reacted. Rise of temperature, 1·8° C.

May 20, 1908. [114 days after inoculation.] Dose, 2·0 cc. Rise of temperature, 1·9° C.

January 7, 1909. [345 days after inoculation.] Dose, 1·0 cc. Rise of temperature, 1·3° C.

Weights.

	qr.	lbs.
January 28, 1908	1	25
March 5, 1909	1	23

Loss of Weight.—2 lbs.

POST-MORTEM EXAMINATION.

The carcass was very thin.

Local Lesion.—On the left side of the neck extending from the middle of the neck to the shoulder there was a large very nodular mass irregular in outline and thickness measuring 16 by 11 by 5·5 cm.; the skin over the thickest portion was replaced by projecting masses of dried caseous substance representing nodules which had ulcerated through; on section the mass was found to be composed of separate but closely packed caseous gritty nodules with thin fibrous capsules bound together by white fibrous connective tissue; the nodules varied in size the largest being about 1·5 cm. in diameter; the under surface of the mass had a very striking appearance and resembled a cobble pavement.

Left Prescapular Gland.—The left prescapular gland measured 5·5 by 5·3 by 3 cm. and was composed throughout of slightly gritty caseous substance partly softened and partly dense.

Right Prescapular Gland.—The right prescapular gland measured 3·7 by 2 by 0·9 cm. and contained three caseo-calcareous nodules, one large the others small, replacing about one-third of the substance.

Prepectoral Glands.—One on the left side showed a minute calcareous tubercle: the rest were normal.

Cervical Glands.—On the left side the lower cervical gland 1·3 cm. in diameter, and a small one in the middle of the neck, were caseo-calcareous throughout; two others on the left side contained one and three calcareous tubercles.

The upper cervical on the right side contained four calcareo-caseous tubercles the largest 2 mm. in diameter, and a mid-cervical gland showed a calcareous grain.

Thorax.

Lungs.—The lungs filled the chest. They showed under the pleura very numerous yellow nodules varying in size; in the thin margins and along the dorsal borders the nodules were large, measuring up to 1·5 cm. in greatest diameter, and formed a continuous border, in the rest of the lung they were smaller ranging up to 5 mm. in diameter; on section the lung parenchyma was closely packed with cheesy gritty nodules largest and most softened towards the posterior end of the caudal lobes; the caseous substance readily shelled out from a thin fibrous capsule; in the left caudal

lobe near the tip there was a ramifying cavity 2 cm. in diameter partly filled with caseo-pus which communicated with a bronchus; the bronchus contained caseo-pus.

Thoracic Glands.—The bronchial and dorsal mediastinal glands were much enlarged. The bronchial and small mediastinal glands were composed practically throughout of calcareo-caseous substance which was cut with great difficulty on account of the large irregular calcareous masses.

The long mediastinal gland contained large calcareo-caseous patches and discrete nodules, embedded in slightly congested gland tissue.

Heart.—Normal.

Pleura.—Normal.

Diaphragm.—In the tendon of the diaphragm on the right side there were two flattened nodules which projected on both sides of the diaphragm; one measured 1·5, the other 2·5 cm. in greatest diameter and both were composed of caseo-calcareous substance surrounded by a thin fibrous capsule.

Abdomen.

Omentum.—The omentum contained three dense caseous gritty nodules, one the size of a French bean, another that of a pea, the third that of a millet seed.

Parietal Peritoneum.—Normal.

Spleen.—The spleen was greatly enlarged (weight 10 ozs.) and very firm. It showed on the peritoneal surfaces numerous slightly raised smooth yellowish-white nodules varying in shape; some were nearly circular in outline, but the majority were longer in one diameter than another, and several were distinctly kidney-shaped; they varied in longest diameter from about 1 to 3 cm.; under the capsule not covered by peritoneum very numerous yellow nodules were seen in the pulp and here there were only a few nodules on the surface similar to those described above.

On section they were dense, caseous, and slightly gritty, and had thin fibrous capsules; attached to the peritoneum were many long connective-tissue processes.

The spleen pulp was almost completely replaced by calcareo-caseous nodules with thin fibrous capsules varying from 2 to 5 mm. in diameter; they were so closely packed that many were facetted by pressure with their neighbours.

Liver.—The liver substance contained numerous nodules varying up to 1 cm. in diameter; they showed a tendency to occur in groups, and in several of these groups the nodules had coalesced; those under the capsule projected slightly and the capsule over them was thickened and showed in several instances connective tissue outgrowths. The nodules were composed of gritty caseous and softened substance surrounded by thin fibrous capsules.

Portal Glands.—In one portal gland there was a caseo-calcareous nodule rather larger than a pea and a few calcareous tubercles; in two others there were three irregular calcareous tubercles.

Coeliac Glands.—One contained a completely calcareous nodule, 3 mm. in diameter; in another there was a millet-seed sized calcareous tubercle.

Kidneys.—On stripping off the capsules seven nodules were seen in the cortex of the left kidney and eight in that of the right; they were calcareo-caseous with fibrous capsules and varied up to 4 mm. in diameter; one or two nodules were seen in the depth of the cortex. In the cortex of the left kidney besides the smaller nodules there was a large firm nodule the size of a broad bean; it projected from the surface and the capsule over it was firmly adherent; on section it was composed of calcareo-caseous substance and a fibrous capsule.

Projecting into the pelvis of the right kidney there was a large soft lobular grey mass resembling granulation tissue; it extended into and entirely replaced the papillary zone of this kidney and was adherent to one of the walls of the pelvis.

Suprarenal Bodies.—Normal.

Iliac Glands.—The iliac glands contained from two to four calcareo-caseous nodules up to 2·5 mm. in diameter.

Alimentary Tract.

Tongue, Pharynx, Tonsils.—Normal.

Retro-pharyngeal Glands.—The left was beset with caseo-calcareous nodules, the right contained one hemp-seed sized nodule.

Submaxillary Glands.—The left was more than half caseo-calcareous; the right contained four caseo-calcareous nodules up to 4 mm. in diameter.

Parotideal Glands.—There were five calcareo-caseous encapsuled nodules in the left and six in the right parotideal gland.

Parotid Salivary Glands.—One contained a hemp-seed sized calcareo-caseous nodule.

Intestines.—The mucous membrane of the small intestine showed three small ulcers with slightly thickened bases but no sign of caseation. The large intestine was normal.

Mesenteric Glands.—The mesenteric glands contained altogether twelve calcareous or calcareo-caseous nodules the largest the size of a pea.

Ileo-colic Glands.—In the ileo-colic glands there were a few calcareo-caseous nodules up to a hemp seed in size.

Testicles.—The substance of the right testicle contained numerous calcareous grains; there were similar but sparsely scattered grains in the left testicle.

Thyroid.—In the right half there was a caseo-calcareous nodule the size of a hemp seed; the left half was normal.

Eyes.—In the loose tissues at the back of the right eyeball close to the optic nerve there was a hemp-seed sized caseo-calcareous nodule.

Muscles.—In an intercostal muscle on the left side there was a caseo-calcareous nodule the size of a French bean.

Bones.—There was a caseo-calcareous nodule in the cancellous tissue of the shaft of each of three of the ribs. The head of the eighth rib was replaced by a caseo-calcareous mass which formed a flat mushroomed projection under the pleura; it measured 2·5 cm. in greatest diameter.

Various Lymphatic Glands.

Pudic Glands.—In the right there was a millet-seed sized calcareous tubercle; the left was normal.

Popliteal Glands.—These contained from two to four calcareo-caseous nodules varying up to 2·5 mm. in diameter.

One *Precrural Gland* contained two similar nodules.

Microscopical Examination.

Emulsion of softened nodule from the Lung.—A few tubercle bacilli.

HORSE 5 [Colt]. Virus H. 85. "H.B."

Subcutaneous inoculation of culture derived from the original material through Guinea-pig 2363.

Dose—50·0 milligrammes.

Date of Inoculation—January 28, 1908. [Age 8–10 months.]

Killed when in good health—May 19, 1908. [112 days after inoculation.]

Clinical Notes.

A moderately large tumour developed at the seat of inoculation, which burst on the 9th day; finally the whole of the body of the tumour sloughed out leaving a large ulcer with raised undermined margins from which there was a continuous discharge; this was treated with antiseptic lotions.

The floor of the ulcer developed granulations, and the ulcer gradually healed.

The prescapular gland became much enlarged, and the tissues between the lesion and the gland were infiltrated.

The general health of the horse remained good during the experiment.

Temperature.

During four days immediately following the inoculation, the temperature was above 39·0° C. (maximum 39·5° C.).

On the 17th day after inoculation the temperature was 39·4° C., on the 23rd day 39·5° C., on the 31st day 39·3° C., and on the 39th day 39·1° C.

With these exceptions the temperature did not rise above 39·0° C. during the experiment.

Tuberculin Test.

The animal was not tested subsequent to inoculation.

Weights.

	cwt.	qrs.	lbs.
January 28, 1908	2	2	10
May 19, 1908	2	2	16

Total gain of weight.—6 lbs.

POST-MORTEM EXAMINATION.

The carcass was in good condition.

Local Lesion.—The skin on the left side of the neck showed a small scar; this was situated over the middle of a mass of fibrous tissue 3 cm. in diameter and 1 cm. in greatest thickness, from which radiated into the surrounding tissues slender fibrous strands giving a puckered appearance; there was no sign of caseation.

The subcutaneous tissues between the lesion and the gland were slightly thickened, and showed here and there a caseous tubercle.

Left Prescapular Gland.—In front of the left shoulder there was a mass measuring 7 by 5 by 4 cm. which on section was composed of two glands, both of which were filled with thin yellowish-white caseopus; the margin of each gland was grey and translucent, and lined internally with a thin layer of firm yellow caseous substance.

At each extremity of the mass there was a group of slightly enlarged glands; the largest of the superior group was a little more than 1 cm. in diameter; two were composed of dense creamy caseated substance, two or three others were partly caseous, others though enlarged were not caseous.

In the inferior group there was one kidney shaped gland (? one of the prepectorals) 2 cm. in greatest diameter which was composed throughout of dense creamy caseous substance; two smaller glands were caseous practically throughout; a number of others appeared normal.

Cervical Glands.—One of the lower cervical glands on the left side was much enlarged measuring 4·5 by 4 by 2 cm.; on section it was composed of dense creamy yellow caseous tracts, each surrounded by a narrow margin of translucent grey tissue. Around this gland were several smaller glands which appeared enlarged but were not caseous.

In the middle of the neck on the left side a gland contained a dense caseated nodule the size of a kidney bean; the caseous substance in this and the other glands was just perceptibly gritty.

Other cervical glands were normal.

Thorax.

Pleura.—Normal.

Lungs.—The lungs were normally crepitant; they showed under the pleura sparsely scattered translucent grey tubercles, the largest the size of a millet seed; a few of the larger ones had in the centre a minute soft yellow focus, the smallest ones were glassy. No definite tubercles were seen on section.

Bronchial and Mediastinal Glands.—Normal.

Heart.—Normal.

Abdomen.

Omentum and Peritoneum.—Normal.

Spleen.—The spleen was normal on the surface, but showed in the pulp sparsely scattered grey fibrous tubercles 1 to 2 mm. in diameter with no sign of caseation or calcification; there was one pinhead-sized caseous tubercle.

Liver.—On the surface three millet-seed sized grey tubercles with minute opaque centres were seen; in the depth two similar but smaller grey tubercles were found. There was also a parasitic nodule 1 cm. in diameter.

Portal Glands.—Normal.

Kidneys and Suprarenal Bodies.—Normal.

Renal, Lumbar, and Iliac Glands.—Normal.

Alimentary Tract.

Tongue, Pharyngeal Mucous Membrane.—Normal.

Submaxillary and Retro-pharyngeal Glands.—Normal.

Intestines.—Normal.

Mesenteric Glands.—Normal.

Various Lymphatic Glands.

Axillary, Precrural, and Popliteal.—Normal.

Microscopical Examination.

Emulsion of lower Cervical Gland.—Tubercle bacilli moderately numerous.

Parasitic nodule from Liver.—No tubercle bacilli.

Tubercle from Liver.—No tubercle bacilli.

HORSE 11 [Colt]. Virus H. 85. "H.B."

Intravenous inoculation of culture derived from the original material through Guinea-pig 2365.

Dose—10·0 milligrammes.

Date of Inoculation—March 6, 1908. [Age 9–12 months.]

Died—April 26, 1908. [51 days after inoculation.]

Clinical Notes.

The respiration had been increased in frequency and somewhat laboured for about three weeks before death. No other symptoms were noticed until the last few days of life when the horse lost appetite and became obviously thin.

Temperature.

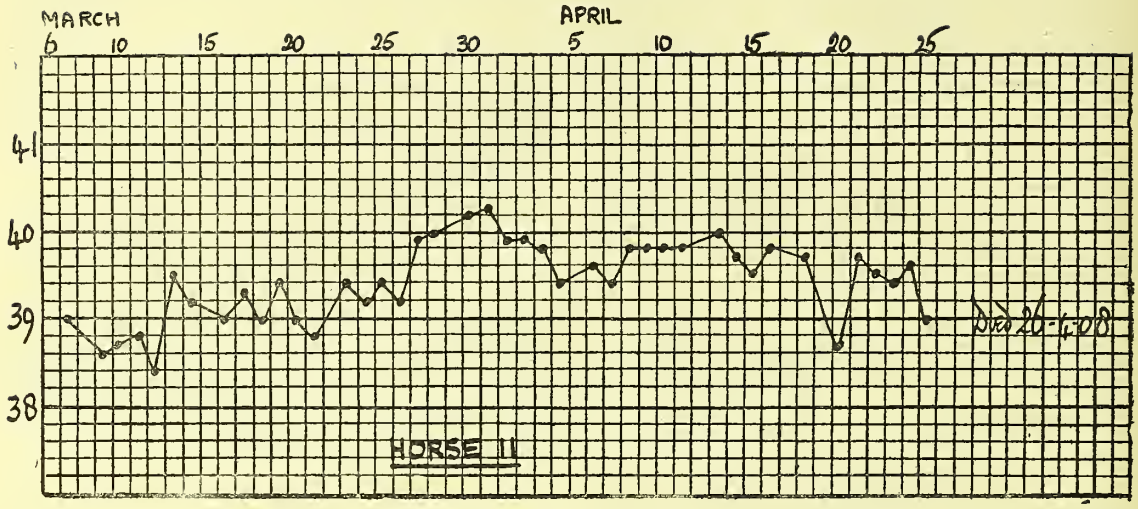

Weights.

			cwt.	qrs.	lbs.
March 6, 1908	...	...	1	3	14
April 26, 1908	...	...	1	1	26

Total loss of weight.—1 qr. 16 lbs.

Average rate of loss per week.—6 lbs.

POST-MORTEM EXAMINATION.

The carcass was thin.

Thorax.

The pleural cavities contained a slight excess of fluid.

Pleura.—Normal.

Lungs.—On opening the chest the lungs did not collapse. They showed when removed a large part of each lung at the level of the root dark red and consolidated; the consolidation was more extensive on the right side than the left; spreading backwards over the caudal lobes from these areas was a diffuse network of consolidated patches which only here and there reached the margin of the lung; on section this diffuse consolidation was found to affect the interior of the caudal lobes as well; the crepitant parts of the lung were firmer than normal.

The lung parenchyma was closely beset with tubercles which varied in size from a point just visible to the naked eye up to 2 mm.; the tubercles varying from 1 to 2 mm. in diameter were moderately numerous and evenly distributed; they were opaque greyish or in some cases greyish yellow and when scraped with a knife were found to be soft and to have a very thin fibrous wall; the very minute tubercles were grey and seemed in places to be very numerous, suggesting a recent dissemination; here and there were larger nodules, yellow and purulent with a fibrous wall.

Thoracic Glands.—The bronchial and mediastinal glands were much enlarged; they were firm and composed practically throughout of creamy white homogeneous caseated tissue showing in some of the glands signs of breaking down.

Heart and Pericardium.—There was a quantity of yellow serous fluid in the pericardial sac. The heart muscle was pale and firm; there were no tubercles on the pericardium or endocardium.

Abdomen.

Omentum and Peritoneum.—Normal.

Spleen.—The spleen was not apparently enlarged and showed on section one yellow pinhead-sized caseous tubercle; the pulp otherwise appeared normal.

Splenic Glands.—In the hilum of the spleen there were two enlarged glands which were composed practically throughout of firm creamy-white patches with narrow margins of greyish-white more translucent tissue.

Liver.—The substance was firmer than normal and the margins of the lobules were pale but no tubercles were seen.

Portal Glands.—The portal glands were enormously enlarged. On section the cortices were extensively replaced by firm yellowish patches which varied in size—some were very narrow, others penetrated some distance into the interior of the gland; the medullary portions were soft and dark red in colour.

Kidneys.—The kidneys were pale and flabby; no tubercles were seen on the surface or in the depth of the cortex; in the medulla of each there were fairly numerous greyish-white or creamy-white tubercles ranging in size from a mere point up to about 1 mm. in diameter.

Suprarenal Bodies.—Normal.

Coeliac Glands.—Around the coeliac axis there was a group of enlarged glands; two of these were composed almost throughout of firm homogeneous creamy-white substance, only a small quantity of normal pigmented gland tissue remaining; the other glands were similarly but not so severely affected, containing a larger amount of normal glandular tissue.

Gastric Glands.—Close to the above glands, but in contact with the stomach, there were two enlarged glands which were composed throughout of firm creamy caseated tissue.

Iliac Glands.—On the right side there were two slightly enlarged glands; one was partly composed of greyish-white areas showing creamy opaque patches in the centre; the other contained greyish semi-translucent nodules and early foci in the cortex. The glands on the left side showed early tubercles in the cortices.

Lumbar Glands.—The lumbar glands contained discrete greyish tubercles up to 2 mm. in diameter.

Ilio-sacral Glands.—The ilio-sacral glands showed from the surface numerous small grey patches in places confluent; these on section were apparently tuberculous.

Intestines.—Yellow spots up to 1·5 mm. in diameter were seen scattered about on the mucous surface of the small intestine.

There were a few similar foci in the large intestine.

Mesenteric and Colic Glands.—Normal.

Tongue.—The lymphoid follicles at the base of the tongue were enlarged and several had soft yellow centres.

Pharyngeal Glands.—On the right side there were three slightly enlarged glands which on section were composed almost entirely of pale greyish semi-opaque tissue; the glands on the opposite side were much smaller, congested, but not obviously tuberculous.

Submaxillary Glands.—These appeared normal.

Cervical Glands.—At the root of the neck there were several groups of glands; some of these contained definite grey tubercles; in one there was a softened nodule; in the others there was nothing definitely of a tuberculous nature, though the appearance of some was suspicious.

Prescapular Glands.—The prescapular glands appeared normal.

Axillary Glands.—The axillary glands were oedematous and congested.

Microscopical Examination.

Tubercle from Lung.—Tubercle bacilli exceedingly numerous.

Smear from Spleen.—Tubercle bacilli numerous.

Smear from Liver.—Tubercle bacilli numerous.

Yellow focus from Tongue.—Tubercle bacilli numerous.

Smear from Gastric Gland.—Tubercle bacilli exceedingly numerous.

Smear from Ilio-sacral Gland.—Tubercle bacilli very numerous.

Smear from Prescapular Gland.—Tubercle bacilli very numerous.

Smear from Cervical Gland.—Tubercle bacilli very numerous.

Yellow focus from Small Intestine. } Tubercle bacilli exceedingly numerous.
Scraping of Mucous Membrane of Small Intestine. }

In all the smears the bacilli were arranged chiefly in dense clumps, many circular in outline, but mostly irregular.

CHIMPANZEE 9. Virus H. 85. "H.B."

(A young animal.)

Cutaneous inoculation of culture derived from the original material through Guinea-pig 2365.

Dose—0·01 milligramme. [The skin was scarified with a scalpel with a serrated edge over an area 5·8 by 4·5 cm. and the emulsion of culture applied.]

Date of Inoculation—March 6, 1908.

Died—August 23, 1908. [170 days after inoculation.]

Clinical Notes.

The wounds at the seat of inoculation healed completely, and no signs of tuberculosis were seen in this situation at any period of the experiment.

On July 18, four and a half months after the inoculation, a hemispherical gland was first noticed in the right axilla; on examination it was found to be hard, freely movable, and 3 cm. in diameter. The skin afterwards became adherent to the gland, then reddened, and finally broke down (on August 12). The chimpanzee had been quite well and lively up to this time.

On August 20 he was noticed to be ill; on the following day he was collapsed, lying curled up in his straw, and his extremities were cold. Artificial heat was provided, and on August 22 he appeared to be better, but on the morning of August 23 he was found dead.

Weight.

At death—16 lbs.

POST-MORTEM EXAMINATION.

The carcass was in moderately good condition.

Seat of Inoculation.—There was no sign of tuberculosis in the skin at the seat of inoculation.

Axillary Glands.—In the right axilla four centimetres external to the nipple there was a circular ulcer 1·8 cm. in diameter, the skin around which was thinned bluish and undermined; rising from the centre of the floor of the ulcer to the level of the skin there was a rounded reddish eminence about 8 mm. in diameter; the exposed floor of the ulcer around this projection as well as that under the skin was covered with yellow caseo-purulent substance; on section the projecting part of the floor was composed of fibrous and glandular tissue, the latter containing a few small yellow softened areas; there was no thickening of the tissues around the ulcer, and other glands in the axilla were normal.

The left axillary glands were normal.

Thorax.

Lungs, Bronchial Glands, Pleura, Heart.—Normal.

Abdomen.

Peritoneum, Liver, Spleen, Kidneys, Suprarenal Bodies.—Normal.

Portal, Splenic, Renal, Lumbar, and Iliac Glands.—Normal.

Alimentary Tract.

Tongue, Pharynx, Tonsils, Submaxillary and Pharyngeal Glands.—Normal.

Intestines and Mesenteric Glands.—Normal.

Inguinal and Cervical Glands.—Normal.

Brain.—Normal.

Microscopical Examination.

Pus from floor of Ulcer.—Numerous organisms stained blue; no tubercle bacilli seen.

Pus from Projecting Gland.—A few organisms stained blue; no tubercle bacilli seen.

Animals Inoculated.

Guinea-pigs.—Two guinea-pigs, 3222 and 3223, were inoculated intraperitoneally with an emulsion of spleen. They were killed after 74 days: one showed slight tuberculosis, the other was healthy.

Two others, 3224 and 3225, were inoculated intraperitoneally with two separate emulsions of nodules from the floor of the ulcer. They were killed after 74 days and showed general tuberculosis.

CHIMPANZEE 11. Virus H. 85. "H.B."

(A young animal.)

Fed once with culture derived from the original material through Guinea-pig 2365.

Dose—1·0 milligramme, taken in milk.

Date of Feeding—March 6, 1908.

Killed when in good health—December 2, 1908. [271 days after feeding.]

Clinical Notes.

Except for occasional indisposition and loss of appetite the Chimpanzee remained well during the experiment.

The weight at death was 21 lbs.

POST-MORTEM EXAMINATION.

The carcass was in good condition.

Alimentary Tract.

Tongue and Pharynx.—Normal.

Tonsils.—The right tonsil contained a focus of yellow pus, the left was normal.

Submaxillary, Pharyngeal, and Cervical Glands.—Normal.

Small Intestine.—The duodenum and the greater part of the jejunum were normal except for two submucous caseous tubercles; the rest of the intestine showed numerous small ulcers, none larger than 5 mm. in diameter, all situated in Peyer's patches some containing two and even three; twenty four altogether were counted; the majority were shallow with slightly raised margins irregular edges and only very slightly thickened base without caseation; a few towards the lower end of the ileum had a patch of caseo-necrotic substance at their base. The Peyer's patch near the ileo caecal valve was not ulcerated.

Large Intestine.—Normal.

Gastric Glands.—Normal.

Mesenteric Glands.—Nearly all the mesenteric glands were enlarged forming tumours which could be distinctly felt through the abdominal wall after death. In the anterior part of the mesentery there was a fluctuating mass nodular around the margins measuring 4·5 by 4 by 3 cm. to which the small intestine was at one part adherent; it was composed of a number of caseous and softened areas separated by fibrous trabeculae.

Just in front of this mass behind the head of the pancreas and in close contact with the small intestine there was a caseous gland rather more than 1 cm. in diameter.

In the lower part of the mesentery the glands were separate and freely moveable; they varied in size up to 2·5 cm. in greatest diameter some projecting considerably beyond the surface of the mesentery; on section the larger ones were caseous and softened practically throughout; some of the smaller ones were partly caseous; there was also a number of small unenlarged glands which were normal on section; the single tuberculous glands numbered about sixteen and were distributed at regular intervals from the mass in the anterior part to the junction of the ileum and caecum.

Ileo-colic and Colic Glands.—Normal.

Thorax.

Lungs.—The lungs were slightly pigmented but contained no tubercles.

Bronchial Glands, Heart, Pleura.—Normal.

Larynx and Trachea.—Normal.

Abdomen.

Omentum and Parietal Peritoneum.—Normal.

On the serous surface of the first part of the small intestine two small greyish-white tubercles were seen.

Spleen.—The spleen was normal in size; it showed in the pulp a nodule nearly 1 cm. in greatest diameter composed of a group of small irregular nodules with softened caseous centres and grey margins separated by red splenic tissue; the rest of the spleen was normal.

Liver.—In the depth of the liver substance a minute translucent tubercle was seen; otherwise the liver was perfectly normal.

The portal gland was normal.

Kidneys.—In the cortex of each kidney there were many pale spots, greyish or greyish-yellow in colour, up to a millimetre in diameter, with not very well defined margins—not apparently tuberculous.

Suprarenal Bodies.—Normal.

Axillary Glands.—One on the left side was enlarged the size of a broad bean, and showed on section several irregular yellow caseous areas; the rest were normal.

Microscopical Examinations.

Emulsion of a caseous Mesenteric Gland, No. 1.—No tubercle bacilli; a few small blue bacilli.

Emulsion of a caseous Mesenteric Gland, No. 2.—No tubercle bacilli.

Smear from ulcer in Small Intestine.—No tubercle bacilli.

Smear from focus in Right Tonsil.—No tubercle bacilli; numerous other micro-organisms.

Emulsion of a Spleen Nodule.—No tubercle bacilli.

Smear from Malpighian Body of Spleen.—No tubercle bacilli.

Smear from the Portal Gland.—No tubercle bacilli.

Smear from the Liver.—No tubercle bacilli.

Smear from the caseous Axillary Gland.—No tubercle bacilli.

Animals Inoculated.

Guinea-pigs 3389 and 3390 were inoculated with an emulsion made from a caseous mesenteric gland. The former received a very small dose, the latter a rather larger one. They died of general tuberculosis in 140 and 158 days respectively.

RHESUS MONKEY 123. Virus H. 85. "H.B."

(A young animal.)

Subcutaneous inoculation of culture derived from the original material through Guinea-pig 2365.

Dose—1·0 milligramme.

Date of Inoculation—December 13, 1907.

Died—April 23, 1908. [132 days after inoculation.]

Clinical Notes.

A prominent fluctuating tumour developed at the seat of inoculation over the right scapula and a gland in the right axilla became enlarged. On January 8 the tumour opened, discharging purulent material.

The discharge continued intermittently for several weeks. On March 7 the tumour was semi-fluctuating, measuring 4·5 by 4·2 cm.; the skin over it showed several openings, which discharged profusely, and a number of small bluish-red patches of thin skin the site of previous ulcers. In the right axilla there was one freely movable gland 2 cm. in greatest diameter. The tumour subsequently diminished in size; the glandular mass in the right axilla became larger. The monkey appeared to be well until the middle of April; it was then noticed to be thin and weak, and it looked ill; there was no increase in respiration. Weakness and emaciation continued and the monkey died on April 23, 132 days after inoculation.

Temperature.

The temperature was normal during the experiment —to within three days of death, when it fell rapidly— the maximum range of variation being 1·1° C. (38·6 to 39·7° C.).

Weight.

At death—2670 grammes.

POST-MORTEM EXAMINATION.

The carcass was emaciated.

Local Lesion.—In the subcutaneous tissues over the lower angle of the right scapula there was a flat yellow caseous patch about 5 mm. in greatest thickness and 3·5 cm. in greatest diameter; the caseous substance was cheesy and rather dry, the more fluid parts of the lesion having all escaped through the openings in the skin.

The skin over the tumour showed four small openings, from only one of which it was possible to express a small quantity of caseo-pus.

Axillary Glands.—In the right axilla there was a mass measuring 3 by 2 by 1·5 cm. composed of several glands fused together, all of which were caseous and softened throughout; the skin was adherent and showed a small opening. Around this mass there were several isolated glands, two of which contained two or three softened caseous nodules.

Deeper in the axilla and lying on the great vessels of the arm there were three softened caseous glands, the largest the size of a kidney bean.

In the left axilla two glands each contained a millet-seed sized softened and caseous tubercle. The others were normal.

Cervical Glands.—One behind the right clavicle the size of a large pea was caseous and softened throughout. Other glands on this side were normal.

On the left side under the trapezius near the vertebral column were two caseous and softened glands, the largest 1 cm. in greatest diameter, and about the centre of the clavicle there was a gland with a small caseous nodule.

Vertebral Glands.—In the 8th interspace on the right side near the vertebral column there was an enlarged caseous and softened gland 1 cm. in greatest diameter; in the 9th and 10th respectively there was a slightly enlarged gland with a millet-seed sized caseous tubercle. In the 11th interspace on this side there was an enlarged congested gland without any sign of caseation.

The glands on the left side were normal.

Thorax.

Pleura.—Normal.

Lungs.—The lungs were pink and crepitant and collapsed normally, and there were no adhesions; they contained, however, a moderate number of hard nodules, ranging in size from a pin's head to that of a hemp seed. Some of the smallest nodules were grey and homogeneous throughout, the others had grey margins and caseous centres, in some softened.

Bronchial Glands.—The bronchial glands were not enlarged; only two were obviously tuberculous, each containing a millet-seed sized caseous tubercle.

Heart and Pericardium.—Normal.

Abdomen.

Omentum and Peritoneum.—The omentum and meso-colon showed a few minute translucent grey tubercles.

The parietal peritoneum was normal.

Omental Glands.—The glands in the great omentum along the curvature of the stomach were normal. A gland in the lesser omentum near the pylorus contained two miliary caseous tubercles.

Spleen.—The spleen was much enlarged, measuring 6·5 by 3·5 by 2 cm., and was adherent to the parietal peritoneum. The pulp was very closely beset with yellow softened caseous nodules varying in size from a millet seed to a fairly large pea. The nodules just under the capsule projected slightly from the surface.

Liver.—The liver was normal in colour and consistency; it contained sparsely scattered yellow caseous and softened nodules ranging in size from about 1 up to 3 mm. in diameter.

Kidneys.—In the cortex of the right kidney there were two yellow caseous and softened nodules; one 3 mm. in diameter projected slightly from the surface, the other 2 mm. in diameter was not visible from the surface.

The left kidney was normal.

Suprarenal Bodies.—Normal.

Portal Gland.—The portal gland contained a softened caseous nodule the size of a hemp seed.

Splenic Glands.—One splenic lymphatic gland contained a pinhead-sized caseous tubercle.

Retro-peritoneal Glands.—One of the retro-peritoneal lymphatic glands situated between the kidneys contained a hemp-seed sized softened and caseous nodule.

Pancreatic Glands.—In the cortex of a gland at the head of the pancreas there was a miliary caseous tubercle.

Intestines.—Normal.

Mesenteric Glands.—The mesenteric glands were about normal in size; one contained a softened caseous nodule the size of a hemp seed, another a millet-seed sized caseous tubercle, and two or three others early caseous foci.

Ileo-Colic Glands.—Normal.

Colic Glands.—The colic glands appeared slightly enlarged but were not otherwise abnormal.

Brain.—Normal.

Inguinal Glands.—Normal.

Tongue, Pharynx, and Tonsils.—Normal.

Larynx and Trachea.—Normal.

Pharyngeal, Submental, and Submaxillary Glands.—Normal.

Microscopical Examination.

Lung (tubercle from) } A few tubercle bacilli seen.
Spleen (caseous nodule) }

Mesenteric Gland (early caseous focus).—A few tubercle bacilli seen.

RHESUS MONKEY 121. Virus H. 85. "H.B."

(A young animal.)

Subcutaneous inoculation of culture derived from the original material through Guinea-pig 2365.

Dose—0·1 milligramme.

Date of Inoculation—December 13, 1907.

Killed when well—March 19, 1908. [97 days after inoculation.]

Clinical Notes.

A fluctuating tumour developed at the seat of inoculation near the lower angle of the right scapula, which opened and discharged its caseous contents on January 31.

On March 7 the tumour was raised and softened in the centre and measured 2·5 by 2 cm.; the skin over the centre was thin and bluish and near the margin there was one small aperture discharging thin pus. In the right axilla there was a glandular mass, freely movable, 2·5 cm. in greatest diameter.

The monkey remained well during the experiment.

Temperature.

From the 14th to the 38th day after inoculation the temperature was irregular and a little below the normal (maximum 39·6, minimum 38·5° C.). Subsequently the temperature rose, and there was slight irregular pyrexia which continued until the monkey was killed (maximum 40·2, minimum 39·0° C.).

Weight.

At death—2350 grammes.

POST-MORTEM EXAMINATION.

The carcass was in very good condition; the muscles were firm, and there was plenty of subcutaneous fat.

Local Lesion.—On the right side over the scapula there was a slightly raised swelling measuring 2 cm. in diameter and 1 cm. in thickness; the skin over it was bluish, and showed several openings discharging turbid fluid.

On section the tumour was a cyst with thick fibrous walls and very irregular internal surface lined with granulation tissue; it contained a small amount of curdy caseous substance suspended in watery fluid. The tumour was wholly subcutaneous and the muscles were not infiltrated.

Axillary Glands.—On the right side there was one large fluctuating gland measuring 2 by 2 by 1·5 cm. with a thin wall and thick caseo-purulent contents; another gland the size of a pea was caseous and softened throughout; the rest were normal. All the glands on the left side were normal.

Vertebral Glands.—One on the right side in the 7th intercostal space measured 8 mm. in diameter, and had a thick fibrous wall and softened caseous contents; the rest were normal.

Thorax.

Pleura.—Normal.

Lungs.—The lungs were pink, crepitant, and collapsed normally; they contained evenly distributed shotty tubercles varying in size from about 0·5 mm. or less up to 2·5 mm. A few were larger, one being 5 mm. in diameter; the tubercles were grey, translucent and homogeneous, except some of the larger ones, which had yellow caseous centres (the 5 mm. nodule was well advanced in caseation and beginning to soften). Forty were counted in the left lung, and there were rather more in the right.

Bronchial Glands.—The bronchial glands were perhaps slightly enlarged; there was, however, no sign of caseation.

Heart.—Normal.

Abdomen.

Omentum and Peritoneum.—Normal.

Spleen.—The spleen was normal in size; the Malpighian bodies were conspicuous, and two or three were distinctly enlarged, being about 1·5 mm. in diameter; there was, however, no sign of caseation.

Liver.—Normal.

Portal Gland.—The portal gland was not enlarged; it contained three caseo-purulent tubercles, one the size of a millet seed, the others less than a pin's head.

Kidneys.—Normal.

Suprarenal Bodies.—Normal.

Coeliac Glands.—Normal.

Lumbar, Iliac, and Renal Glands.—Normal.

Pancreatic Glands.—One gland in the pancreas contained two caseo-purulent tubercles, the largest the size of a millet seed. Other pancreatic glands were normal.

Alimentary Tract.

Tongue, Pharynx, and Tonsils.—Normal.

Submaxillary, Retro-pharyngeal, and Cervical Glands.—Normal.

Intestines.—Normal.

Mesenteric Glands.—The mesenteric glands were of about normal size; one or two in the anterior part showed under the capsule a few greyish-white indefinite foci up to 1 mm.; in the cortex of one of the glands in the posterior part of the mesentery a yellow caseous focus was seen.

Ileo-Colic and Colic Glands.—Normal.

Testicles.—Normal.

Larynx and Trachea.—Normal.

Microscopical Examination.

Lung
- (1) *Emulsion of a tubercle* [two smears examined]: ? two tubercle bacilli seen.
- (2) *Centre of a caseous tubercle:* a few tubercle bacilli seen.

Spleen.—Enlarged Malpighian body: a few tubercle bacilli seen.

Liver.—Scraping: no tubercle bacilli.

Portal Gland.—Purulent focus from: numerous tubercle bacilli.

Small Intestine.—Scraping from mucous surface of duodenum: no tubercle bacilli.

Mesenteric Gland, greyish white focus from: very numerous tubercle bacilli, mainly in clumps.

Mesenteric Gland, caseous focus from: very numerous tubercle bacilli, mainly in clumps.

Animal Inoculated.

Guinea-pig 3011 was inoculated intraperitoneally with an emulsion made from the spleen. It died in 34 days; there was no obvious tuberculosis, but T.B. were found in smears from the pyloric and sternal glands.

RHESUS MONKEY 119. Virus H. 85. "H.B."

(A young animal.)

Subcutaneous inoculation of culture derived from the original material through Guinea-pig 2365.

Dose—0·01 milligramme.

Date of Inoculation—December 13, 1907.

Died—September 9, 1908. [271 days after inoculation.]

Clinical Notes.

The monkey appeared to be in good health, and was lively and active, until the end of July, when it was first noticed to be unwell. From this time onwards its condition slowly deteriorated; it became weak, lost flesh, and sat all day huddled up in a corner of its cage. During the last week of life the monkey refused all food; up to this time its appetite had been good. Weight at death, 2070 grammes.

Temperature.

During December the temperature was a little raised (maximum 40·2° C.). From January to the middle of April it was quite normal; during the latter half of April and May the temperature was slowly rising, and a maximum of 40·4° C. was reached on May 30. The temperature remained high (averaging about 40·0° C.) until the end of August. During the first few days of September it fell rapidly to 35·0° C., and for five days before death no temperature could be recorded by the clinical thermometer.

POST-MORTEM EXAMINATION.

The carcass was in fair condition; the muscles were firm.

Local Lesion.—In the subcutaneous tissues near the posterior angle of the right scapula there was a soft caseous mass 1·5 cm. in greatest diameter, the skin over which showed three small ulcers covered over with dried caseo-pus. There was a second subcutaneous caseous mass on the side of the thorax 3 or 4 cm. below the above.

Axillary Glands.—On the right side there was a group of five very enlarged glands, the largest being the size of a pigeon's egg; in life they formed a very prominent pendulous mass; one of the glands was adherent to the skin which showed a circular ulcer 1·5 cm. in diameter, the floor of which was raised rounded and of a bright red colour; all the glands were fluctuant and filled with creamy caseo-purulent substance. On the left side one gland only was affected; this contained a large pea-sized and a hemp-seed-sized caseous nodule.

Cervical Glands.—In the right posterior triangle there was a large cystic gland, rather larger than a thrush's egg, filled with curdy caseo-pus; near the sterno-clavicular joint there was a caseous gland the size of a broad bean. The glands on the left side were normal.

Vertebral Glands.—On the right side on the 7th to the 9th ribs extending from the vertebral column 2·5 cm. outwards, and measuring from before backwards 3 cm., there was an irregular yellow mass which on section was composed of caseous softened substance.

A gland in the 6th interspace on each side contained a millet-seed-sized caseous tubercle.

Thorax.

Lungs.—The lungs were a little congested but pink and crepitant throughout; the right caudal lobe was adherent to the enlarged vertebral glands, but could be separated from them without tearing its tissue. The right cephalic lobe showed near the root one pea-sized thin-walled caseous softened nodule; there was a similar nodule in the right middle lobe. There was no nodule in the right caudal; the left cephalic was normal. The left caudal lobe contained in the posterior part two yellow caseous breaking-down nodules, one a centimetre the other 0·5 cm. in diameter.

Bronchial Glands.—On the right side there were two praetracheo-bronchial glands, one of which contained a hemp-seed sized caseous nodule, the other a millet-seed sized caseous nodule.

An intertracheo-bronchial gland on the right side contained a pea-sized softened and caseous nodule.

In the root of the left lung surrounding the bronchus there was a group of five enlarged glands, the largest 1·8 cm. in diameter; one of the smaller ones contained discrete caseous nodules, the rest were caseous and softened throughout.

Heart and Pericardium; Pleura.—Normal.

Abdomen.

Omentum.—The omentum contained two caseous nodules with fibrous margins each 2·5 mm. in diameter.

Peritoneum, Mesentery, and Mesocolon.—Normal.

Spleen.—The spleen was slightly enlarged, measuring 5 by 2·5 by 1·5 cm., and showed projecting from its surface half a dozen yellow nodules ranging from 0·8 up to 1·5 cm. in diameter, and under the capsule a few smaller ones up to a hemp seed in size. On section the pulp contained, besides those seen from the surface, scattered nodules ranging up to a centimetre in diameter. Altogether the spleen contained about twenty nodules of various sizes; they were all caseous and softened throughout.

Splenic Lymphatic Glands.—Normal.

Liver.—The liver was normal in colour, it showed under the capsule, as well as in the depth, a moderate number of submiliary grey tubercles. One rather larger tubercle under the capsule was caseous in the centre.

The gland on the head of the pancreas was much enlarged, measuring 1·8 cm. in diameter, and was caseous and softened throughout.

A gland near the pylorus contained two caseous nodules, the largest 2·7 mm. in diameter.

Kidneys.—The kidneys were pale; no tubercles were seen either on surface or on section.

Suprarenal Bodies.—Normal.

Iliac Glands.—Normal.

Lumbar Glands.—One lumbar gland was the size of a small pea, and caseous and softened throughout.

Ilio-sacral Glands.—One ilio-sacral gland contained two caseous nodules up to a hemp seed in size; two others contained each one caseous tubercle.

Alimentary Tract.

Tongue, Pharynx, and Tonsils.—Normal.

Submaxillary Glands.—On the left side one contained two pinhead-sized caseous tubercles, the others were normal.

Pharyngeal Glands.—The one on the right side showed a caseous and softened tubercle the size of a millet-seed. The one on the left side was normal.

Intestines.—In the small intestine there was a millet-seed sized submucous caseous tubercle.

The large intestine was normal.

Mesenteric Glands.—The mesenteric glands were not enlarged; they contained three caseous tubercles and a few caseous foci.

Ileo-Colic Glands.—Normal.

Colic Glands.—One colic gland contained a millet-seed sized caseous tubercle, the rest were normal.

Brain.—Normal.

Inguinal Glands.—On the right side there were three enlarged glands, ranging in size from a small pea to that of a cherry, which on section were caseous and softened practically throughout. On the left side one gland contained a soft caseous mass 1 cm. in greatest diameter.

Microscopical Examination.

Emulsion of Nodule from Spleen.—Tubercle bacilli moderately numerous.

RHESUS MONKEY 153. Virus H. 85. "H.B."

(A young animal.)

Subcutaneous inoculation of culture derived from the original material through Guinea-pig 2365.

Dose—10·0 milligrammes.

Date of Inoculation—April 11, 1908.

Killed when ill—June 9, 1908. [59 days after inoculation.]

Clinical Notes.

A very large fluctuating tumour developed at the seat of inoculation over the right scapula ; this opened and discharged its caseo-purulent contents, and became a large foul ulcer with undermined margins.

The monkey was killed when ill 59 days after inoculation on account of the infectivity of the ulcerated area.

Temperature.

From April 12 to May 27 the temperature remained normal with the exception of a slight rise (maximum 40·0° C.) during the first week in May.

On May 28 the temperature again rose, reaching a maximum of 40·2° C. on May 31 ; it remained high for a few days, and then quickly fell. On June 9, when the monkey was killed, the temperature was 37·2° C.

Weight.

At death—2700 grammes.

POST-MORTEM EXAMINATION.

The carcass was thin.

Local Lesion.—Over the right scapula there was a large foul ulcer, measuring 6·5 by 4 cm. in area, with irregular raised considerably undermined margins, the edges of the skin in places being necrosed ; the floor of the ulcer was irregular granular and congested and covered with caseo-pus. Under the skin at the margin of the ulcer there was a narrow zone of breaking-down caseous substance ; this zone was all that was left of a very large tumour.

Axillary Glands.—On the right side there were two enlarged congested glands, the largest 2 cm. in length, each of which showed around the cortex yellow caseous patches not softened but readily broken down with a scalpel ; a smaller gland contained a hemp-seed sized caseous nodule

The glands on the left side were normal.

Cervical Glands.—On the right side behind the clavicle there was an enlarged gland which showed about three quarters of its substance caseous and oftened ; another smaller gland near it was congested but not caseous.

On the left side one gland behind the clavicle the size of a large pea showed a softened caseous patch replacing half the substance.

The rest of the cervical glands were normal.

Vertebral Glands.—On the right side from the fifth to the tenth interspaces there was a chain of slightly enlarged glands ; three were congested but not caseous, two were caseous throughout.

On the left side at the level of the seventh interspace there were two caseous glands the size of split peas.

Inguinal Glands.—Normal.

Thorax.

Pleura, Heart, and Pericardium.—Normal.

Lungs.—The lungs were crepitant but a little congested and oedematous. They contained sparsely and evenly distributed grey tubercles, the largest the size of a millet seed.

Bronchial Glands.—The bronchial glands were normal in size and appearance.

Abdomen.

Omentum and Peritoneum.—Normal.

Spleen.—The spleen was normal in size. The Malpighian bodies appeared to be enlarged but were not opaque, and there were no definite tubercles.

Liver.—The liver appeared normal.

Kidneys.—In the cortex of the right kidney there were two minute grey tubercles ; the left was normal.

Suprarenal Bodies.—Normal.

Lumbar Glands.—Normal.

Alimentary Tract.

Tongue, Pharynx, Tonsils.—Normal.

Submaxillary and Pharyngeal Glands.—Normal.

Intestines and Mesenteric Glands.—Normal.

Microscopical Examination.

Smear from Spleen.—Fairly numerous tubercle bacilli occurring chiefly in groups.

Smear from Liver.—No tubercle bacilli.

Tubercle from Lung.—Tubercle bacilli in moderate numbers.

RHESUS MONKEY 125. Virus H. 85. "H.B."

(A young animal.)

Fed once with culture derived from the original material through Guinea-pig 2365.

Dose—1·0 milligramme.

Date of Feeding—January 11, 1908.

Died—May 6, 1908. [116 days after feeding.]

Clinical Notes.

The monkey was in poor condition when the experiment commenced, but gradually improved and became fat and well-looking. It remained well until the third week in April when it was noticed to be depressed and seedy. There were no definite symptoms : the monkey did not lose flesh and the respiration was normal, but it slowly became weaker and more depressed and ill-looking and died on May 6.

Temperature.

For two and a half months (up to April 1) the temperature remained approximately normal (maximum 39·4° C., minimum 38·4° C.). From April 2 to April 18 the temperature was raised (maximum 40·0° C., minimum 39·1° C.) ; after this a rapid fall took place, and for the last eleven days of life the temperature was below 35·0° C. and could not be recorded by the clinical thermometer.

Weight.

At death—2650 grammes.

POST-MORTEM EXAMINATION.

The carcass was in very good condition ; there was plenty of subcutaneous and abdominal fat, and the muscles were firm and well-developed.

Alimentary Tract.

Tongue, Pharynx, Tonsils.—Normal.

Submaxillary Lymphatic Glands.—A gland the size of a hemp seed near the right submaxillary salivary gland was caseous and softened throughout ; others on this side and those on the left were normal.

Pharyngeal Lymphatic Glands.—The pharyngeal gland on the left side was more than a centimetre in greatest diameter, and was caseous and softened throughout. The right pharyngeal gland was normal.

Cervical Glands.—Normal.

Small Intestine.—In the anterior part of the small intestine there were five nodules varying in size from a millet seed to a hemp seed ; the smallest and largest nodules were caseous, and the mucous membrane over them was intact ; the others showed small ulcers and had only a small quantity of caseo-pus in the interior ; the deep wall of the nodule was thickened but the peritoneal surface was normal.

The first Peyer's patch contained four yellow caseous tubercles, the mucous membrane over some of which was ulcerated ; on the wall of the intestine close to this patch, near the mesenteric border, there was a dense elongated caseous nodule formed by the fusion of three small ones. Two other Peyer's patches contained one and three caseous tubercles the mucous membrane over which showed small ulcers.

Large Intestine.—The mucous membrane of the rectum showed a small erosion and near it in the wall of the gut there was a shotty caseous nodule 2 mm. in diameter. The rest of the large intestine was normal.

Pyloric and Pancreatic Glands.—Normal.

Mesenteric Glands.—All the mesenteric glands were enlarged, the largest measuring a little more than 1·5 cm. in greatest diameter ; on section their substance was found to be almost entirely replaced by caseous areas, many softened.

Ileo-Colic Glands.—Normal.

Colic Glands.—Nine of the colic glands were enlarged, the largest measuring 1 cm. in diameter ; the larger ones were caseous throughout and had thick fibrous capsules, the others showed various amounts of caseation.

Rectal Glands.—One rectal gland was caseous.

Abdomen.

Omentum.—Normal.

Peritoneum.—There was one millet-seed sized caseous tubercle on the meso-colon, and on the upper part of the mesentery three dense caseous nodules with fibrous walls ranging from a millet to a hemp seed in size.

Spleen.—The spleen was normal in size, it contained one softened caseous nodule with a thin fibrous wall 2·5 mm. in diameter.

Splenic Lymphatic Glands.—Normal.

Liver.—The liver showed under the capsule embedded in the substance nine yellow spherical nodules ranging in size from a millet seed to that of a small pea, they had tenacious caseo-purulent contents and thin fibrous walls. There were also two pinhead-sized tubercles with grey margins. No nodules were seen on section.

Portal Gland.—Normal.

Kidneys.—Normal.

Suprarenal Bodies.—Normal.

Lumbar and Iliac Glands.—Normal.

Thorax.

Pleura.—Normal.

Lungs.—The lungs were crepitant and collapsed normally ; the left cephalic lobe contained two somewhat irregular dense caseous nodules with grey margins the largest 5 mm. in diameter. There were no nodules in the left caudal lobe. The right cephalic lobe contained three dense caseous nodules with narrow grey margins, the largest 7 mm. in diameter. The right middle lobe contained two caseous nodules, the largest 2 mm. In the right caudal lobe there were two dense caseous nodules, one 5 mm. in diameter, the other measuring 1 by 0·5 by 0·4 cm.

Thoracic Glands.—Praetracheo-bronchial glands : A gland on each side in front of the root of each lung was slightly enlarged and the substance extensively replaced by yellow breaking down caseous nodules.

On the right side of the trachea in front of the bronchial gland there was an enlarged gland similarly but not so severely affected.

The intertracheo-bronchial glands were normal.

Heart.—Normal.

Larynx and Trachea.—Normal.

Inguinal Glands.—Normal.

Axillary Glands.—One of the left axillary glands contained a caseous softened nodule the size of a hemp seed. The right axillary gland was normal.

Microscopical Examination.

Emulsion from Bronchial Gland.—No tubercle bacilli seen.

Smear from Liver Nodule.—One tubercle bacillus seen.

Smear from Caseous Tubercle in Small Intestine.—No tubercle bacilli seen.

RHESUS MONKEY 127. Virus H. 85. "H.B."

(A young animal.)

Fed once with culture derived from the original material through G.P. 2365.

Dose—0·1 milligramme.

Date of Feeding—January 11, 1908.

Killed when dying—May 5, 1908. [115 days after feeding.]

Clinical Notes.

The monkey remained well for more than two months after the feeding. During April it gradually became thin and lost its appetite, and looked ill ; there was no increase in respiration. Weakness and emaciation continued, and the animal was killed when dying on May 5.

Temperature.

The temperature remained approximately normal for three months from January 11 till April 10 ; from April 11 onwards it slowly fell ; it was 39·3° C. on the 11th ; 38·0° C. on the 24th, and 37·0° on May 2. On May 4 the temperature was below 35·6° C. ; the following day the monkey was killed.

Weight.

At death—1450 grammes.

POST-MORTEM EXAMINATION.

The carcass was emaciated.

Alimentary Tract.

Tongue, Pharynx, Tonsils.—Normal.

Submaxillary Glands. — The right submaxillary gland was the size of a large pea and was caseous and softened throughout, the left was normal.

Pharyngeal and Cervical Glands.—Normal.

Intestines.—One of the nodules in the mesentery (q.v.) was adherent to the wall of the small intestine, and the mucous membrane over it was on the point of breaking down. There was no sign of ulceration in the small intestine.

The mucous membrane of the large intestine showed numerous ulcers of various sizes, some large with serpiginous margins ; the floors of these ulcers were smooth and there was no thickening of the bases ; a smear made from some mucus from the floor of one of the ulcers showed no tubercle bacilli.

Mesenteric Glands.—In the anterior part of the mesentery on each side there was a mass measuring 2·5 by 1 by 1 cm. composed of several glands fused together ; on section they were all cheesy, caseous and softened practically throughout ; the glands in the posterior part of the mesentery were not enlarged ; one contained a hemp-seed sized caseous nodule, another a millet-seed sized caseous tubercle. The rest were normal.

Mesentery.—Along four of the mesenteric veins in the mesentery corresponding to the large caseous glands there were several firm caseous nodules varying in size from a millet seed to a small pea ; one of the larger ones was adherent to the wall of the intestine.

Ileo-Colic Glands.—One the size of a pea had a thick fibrous wall and cheesy caseous contents.

Colic Glands.—All the colic glands were enlarged, eight along the ascending and transverse colon were caseous, one or two 5 mm. in diameter were caseous throughout, the rest contained caseous nodules, varying from a millet seed upwards in size ; the other colic glands, though enlarged, were not caseous.

Rectal Glands.—Three rectal glands were affected ; one the size of a pea was caseous throughout and softened, the others were partly caseous.

Abdomen.

Omentum and Parietal Peritoneum.—Normal.

Spleen.—The spleen was not enlarged ; it contained six yellow caseous and softened nodules, the largest 3 mm. in diameter.

Liver.—Two grey foci of a doubtful nature were seen just under the capsule on the anterior surface ; otherwise the liver was normal.

Portal Gland.—Normal.

Kidneys.—Normal.

Suprarenal Bodies.—Normal.

Thorax.

Pleura.—Normal.

Heart.—Normal.

Lungs.—The lungs were crepitant and collapsed normally ; in the left lung there were two shotty miliary caseous tubercles ; in the right posterior lobe there were a caseous nodule with a grey margin the size of a hemp seed and a grey miliary tubercle.

Bronchial Glands.—Normal.

Larynx and Trachea.—Normal.

In the web between the third and fourth toes of the left foot there was a pea-sized abscess filled with ill formed blood-stained pus.

Microscopical Examination.

Emulsion of a Tubercle from the Lung.—Tubercle bacilli in moderate numbers.

Emulsion of a Tubercle from the Spleen.—A few tubercle bacilli.

Smear from Floor of Ulcer in Large Intestine.—No tubercle bacilli.

Pus from Abscess in Left Foot.—No tubercle bacilli ; cocci.

RHESUS MONKEY 235. Virus H. 85. "H.B."

(A young animal.)

Subcutaneous inoculation of culture derived from the spleen of Monkey 119.

Dose—1·0 milligramme.

Date of Inoculation—October 30, 1908.

Died—December 17, 1908. [48 days after inoculation.]

Clinical Notes.

The monkey appeared to be in good health until December 14, when it was seen to be huddled up in a corner of its cage looking depressed and ill. The animal grew worse, and died on December 17. There was no increase of respiration during the illness, and the appetite was fairly good until the day of death. The weight at death was 1750 grammes.

POST-MORTEM EXAMINATION.

The carcass was in poor condition.

Local Lesion.—The subcutaneous tissues in the middle of the back over the lower dorsal vertebrae showed a large collection of hæmorrhagic caseo-necrotic substance measuring 6 cm. in greatest diameter ; the subcutaneous tissues on the right side between the lesion and the groin were hæmorrhagic and oedematous.

Axillary Glands.—The glands on the right side were moderately enlarged and deeply congested ; one contained softened caseous nodules replacing about half the substance, two others showed thin caseous patches at the margin of the cortex ; the others were enlarged but not caseous.

On the left side the glands were not so large as those on the right ; one, the largest, showed the cortex partly caseous and softened, the others were slightly enlarged and deeply congested but not caseous.

Inguinal Glands.—The glands on both sides were enlarged ; one in each group showed early caseation of the cortex.

Cervical Glands.—On the right side behind the

clavicle one was enlarged and contained two hemp-seed sized caseous nodules. Other cervical glands appeared normal.

Vertebral Glands.—The glands in the eighth and ninth interspaces on each side were enlarged, the largest, 1 cm. in greatest diameter, caseous and softened throughout.

Thorax.

Lungs.—The lungs were crepitant throughout; the right caudal lobe was adherent to the enlarged vertebral glands; the lung parenchyma contained fairly numerous evenly-distributed grey tubercles ranging in size from a mere point up to 1 mm. or rather more in diameter; a few of the larger ones had yellow caseous centres, the rest were grey and translucent.

Bronchial Glands.—The bronchial glands were slightly enlarged, but showed no sign of caseation.

Heart and Pericardium; Pleura.—Normal.

Larynx and Trachea.—Normal.

Abdomen.

Omentum and Peritoneum.—Normal.

Spleen.—The spleen was not apparently enlarged; it showed in the pulp a moderate number of grey miliary tubercles, many with opaque centres.

Liver.—The liver was normal in size and colour; it showed on the anterior surface under the capsule two minute greyish-white tubercles.

Pancreatic Glands.—Of the glands along the anterior border of the pancreas one contained a caseous focus.

Kidneys.—Each kidney showed in the cortex a few grey miliary tubercles.

Suprarenal Bodies.—Normal.

Lumbar Glands.—The lumbar glands were enlarged; two contained each one caseous tubercle.

Iliac Glands.—Normal.

Alimentary Tract.

Tongue, Pharynx, Tonsils.—Normal.

Submaxillary and Pharyngeal Glands.—Normal.

Intestines.—Normal.

Mesenteric, Ileo-colic and Colic Glands.—Normal.

Microscopical Examination.

Smear from Local Lesion.—Numerous tubercle bacilli chiefly in clumps.

Tubercle from Liver.—A few tubercle bacilli seen.

RHESUS MONKEY 237. Virus 85. "H.B."

(A young animal.)

Subcutaneous inoculation of culture derived from the spleen of Monkey 119.

Dose—1·0 milligramme.

Date of Inoculation—October 30, 1908.

Died—December 20, 1908. [51 days after inoculation.]

POST-MORTEM EXAMINATION.

The carcass was thin.

Spontaneous Tuberculosis.

Thorax.

Lungs.—In the right cephalic lobe there was a caseous and softened mass with a thin fibrous wall measuring 2·5 cm. in greatest diameter; the mass formed on the inner and ventral surface of the lobe a small rounded prominence and the lung tissue around it was consolidated to some extent; the rest of the lungs was crepitant and contained fairly numerous evenly distributed tubercles varying in size from 0·5 to 2 mm. in diameter; some of the smaller ones were grey and homogeneous, the rest were yellow and caseous in the centre.

Bronchial Glands.—On the right side of the trachea there was a smooth fluctuating tumour the size of a pheasant's egg which on section was a thin-walled cyst filled with watery caseo-purulent substance; there was a slightly enlarged gland on the left side which contained discrete caseous tubercles; one of the intertracheo-bronchial glands contained a miliary caseous tubercle.

Abdomen.

Spleen.—The spleen was enlarged and closely beset with yellow softened caseous nodules varying from 1 to 5 mm. in diameter.

Liver.—The liver contained scattered caseous nodules ranging in diameter from 1 to 3 mm.

Two glands on the head of the pancreas and one in the small curvature of the stomach contained discrete caseous tubercles.

Kidneys.—In the cortex of each kidney there were scattered grey translucent tubercles.

Inguinal Glands.—An inguinal gland on the left side contained a caseous and softened nodule.

Local Lesion.—In the subcutaneous tissues of the back, at the seat of inoculation, there was a moderately large caseous lesion surrounded by pinkish fibroid tissue and beginning to break down in the centre.

Axillary, Cervical, and Vertebral Glands.—Normal.

Microscopical Examination.

Lung (smear from large caseous mass).—Tubercle bacilli numerous.

RHESUS MONKEY 335. Virus H. 85. "H.B."

(A young animal.)

Subcutaneous inoculation of culture derived from the liver of Calf 1531

Dose—1·0 milligramme.

Date of Inoculation—June 28, 1909.

Died—August 6, 1909. [39 days after inoculation.]

POST-MORTEM EXAMINATION.

The carcass was emaciated. Its weight was 1150 grammes.

Local Lesion.—The skin over the right scapula and lower ribs on the right side showed a large ulcer the floor of which was almost completely covered with a dry caseous scab.

Axillary Glands.—On the right side there were three the size of peas, caseo-necrotic throughout; another similar in size contained miliary caseous tubercles; one gland on the left side contained a caseous and softened tubercle.

Vertebral Glands.—Two on the right side were slightly enlarged and contained each a caseous and softened patch. Another on this side showed a few caseous tubercles.

Cervical Glands.—One or two in each posterior triangle were enlarged but not caseous.

Lungs.—The lungs were crepitant and contained scattered evenly distributed submiliary grey tubercles.

Liver.—The liver showed a moderate number of minute grey foci evenly distributed throughout the substance.

Kidneys.—Each kidney showed on the surface a moderate number of pale grey miliary tubercles.

Inguinal Glands.—The inguinal glands on the right side were enlarged but not caseous; those on the left side appeared normal.

The remaining organs and glands were examined and appeared normal.

Microscopical Examination.

Smear from Spleen.—No tubercle bacilli.

Smear from Liver (tubercle).—No tubercle bacilli; moderately numerous short bacilli, mainly in pairs, stained blue.

Smear from Lung (tubercles).—No tubercle bacilli.

Smear from Mesenteric Gland.—A few tubercle bacilli; also blue-stained organisms similar to those in the liver.

RHESUS MONKEY 333. Virus H. 85. "H.B."

(A young animal.)

Subcutaneous inoculation of culture derived from the liver of Calf 1531.

Dose—1·0 milligramme.

Date of Inoculation—June 28, 1909.

Died—August 18, 1909. [51 days after inoculation.]

POST-MORTEM EXAMINATION.

The carcass was thin; its weight was 1250 grammes.

The cause of death was not apparent.

Local Lesion.—In the muscles of the back over the posterior part of the right scapula there was a large caseous tumour measuring 5 by 5 by 2·5 cm. which showed in the centre a cavity filled with turbid serous fluid; the skin over it was not adherent.

Axillary Glands.—On the right side three glands, the largest the size of a large pea, were caseous throughout; on the left side one contained a few caseous foci.

Cervical Glands.—In the right posterior triangle there was a group of eight or nine glands varying from 3 up to 8 mm. in diameter, all of which were caseous throughout; on the left side there were four small caseous glands.

Vertebral Glands.—On the right side in the 6th to the 8th interspaces there were three caseous and softened glands the size of large peas; the glands in the 9th and 10th interspaces were slightly enlarged and partly caseous. Other vertebral glands were normal.

Lungs.—The lungs were crepitant; they showed on the surface under the pleura scattered grey tubercles, the largest not a millimetre in diameter.

There was a slight excess of fluid in the peritoneal cavity.

Spleen.—The spleen was normal in size and contained scattered caseous tubercles up to a millet seed in size.

The gland on the head of the pancreas contained one caseous tubercle.

Mesenteric Glands.—There were four caseous tubercles in these glands.

Kidneys.—There were three or four congested grey tubercles in each kidney.

The other organs and glands were examined and found normal.

PIG 115. Virus H. 85. "H.B."

Subcutaneous inoculation of culture derived from the original material through Guinea-pig 2363.

Dose—50·0 milligrammes.

Date of Inoculation—January 28, 1908. [Age 11 weeks.]

Killed when in good health—November 30, 1908. [307 days after inoculation.]

Clinical Notes.

The pig remained well during the whole period of the experiment and grew normally.

Weights.

	cwt.	qrs.	lbs.
January 28, 1908	0	1	13
November 30, 1908	1	1	18

Total gain of weight.—1 cwt. 0 qr. 5 lbs.

Average rate of gain per week.—2·7 lbs.

POST-MORTEM EXAMINATION.

The carcass was in good condition.

Local Lesion.—The skin on the right side of the abdomen showed a long linear scar; in the subcutaneous tissues beneath this there was a patch of puckered fibrous tissue showing discrete calcareo-caseous tubercles varying in size from a pin's head to that of a hemp-seed.

Inguinal Glands.—On the right side the one nearest the local lesion measured 3 by 2·5 by 1·5 cm. and was

composed throughout of dense pinkish caseated tissue gritty around the margins ; three others varying in size from a pea to a broad bean were calcareous throughout and stony hard ; the others were normal.

The glands on the left side were normal.

Iliac Glands.—The right iliac gland was enlarged and closely beset with calcareous nodules forming in places irregular patches. The left iliac gland was normal.

Precrural Glands.—Normal.

Ventral Mediastinal Glands.—The one on the right side the size of a small walnut was calcareous almost throughout ; the one on the left side was normal.

Thorax.

Lungs.—The lungs were crepitant throughout and contained fairly numerous irregular yellow calcareous nodules ranging from 1 to rather more than 2 mm. in diameter ; they were most numerous in the posterior parts of the caudal lobes and gradually became less numerous anteriorly, the cephalic lobes containing only sparsely scattered nodules.

Bronchial Glands.—The bronchial glands were very slightly enlarged and contained discrete calcareous nodules up to a hemp seed in size.

Heart and Pleura.—Normal.

Abdomen.

Omentum and Peritoneum.—Normal.

Spleen.—In the pulp there were two miliary caseo-calcareous tubercles.

Liver.—The liver was normal on surface and on section.

Portal Glands.—The portal glands were little if at all enlarged ; they contained discrete highly calcareous nodules up to a hemp-seed in size ; one contained also a calcareous patch 1 cm. in diameter.

Kidneys.—Normal.

Suprarenal Bodies.—Normal.

Coeliac Glands.—These glands were slightly enlarged and contained discrete calcareo-caseous nodules up to a hemp-seed in size.

Lumbar Glands.—Three small lumbar glands were calcareo-caseous practically throughout.

Alimentary Tract.

Tongue, Tonsils, Pharynx.—Normal.

Retro-Pharyngeal Glands.—The one on the right side contained a hempseed - sized caseo - calcareous nodule. The one on the left side was normal.

Submaxillary Glands. — Each submaxillary gland contained a few calcareo-caseous nodules.

Intestines.—Normal.

Mesenteric Glands.—With the exception of three or four at the anterior end all the mesenteric glands were much enlarged and on section caseo-calcareous throughout ; the few glands at the anterior end were of about normal size but contained calcareous nodules.

Ileo-colic Glands.—Some of the ileo-colic glands were nodular and completely calcified, others were partly calcareo-caseous or contained calcareous nodules.

Various Lymphatic Glands.

A gland just in front of the right shoulder contained a millet-seed-sized caseous tubercle.

Axillary, Pudic, and Popliteal Glands.—Normal.

PIG 117. Virus H. 85. "H.B."

Subcutaneous inoculation of culture derived from the original material through Guinea-pig 2363.

Dose—10·0 milligrammes.

Date of Inoculation—January 28, 1908. [Age 11 weeks.]

Killed when in good health—October 22, 1908. [268 days after inoculation.]

Clinical Notes.

The pig grew well and was in good condition when killed.

Weights.

		cwt.	qr.	lbs.
January 28, 1908	... ...	0	1	10
October 22, 1908	... ...	1	0	15

Total gain of weight.—3 qrs. 5 lbs.

Average rate of gain per week.—2·3 lbs.

POST-MORTEM EXAMINATION.

The carcass was in good condition.

Local Lesion.—In the subcutaneous tissues of the abdominal wall on the right side there was a nodular tumour measuring 7·5 by 7·5 by 2·5 cm. composed of separate nodules varying in diameter up to 1 cm. ; the nodules were caseous and encapsuled and surrounded and loosely bound together by white connective tissue ; the skin over the mass showed several rounded prominences (projecting nodules) some ulcerated, some yellow and on the point of breaking through, others covered by normal skin.

Between the lesion and the nearest glands there was a series of caseous nodules like those in the lesion ; there were similar nodules in the tissues around the glands.

Inguinal Glands.—The inguinal glands, three in number, were much enlarged ; two were caseous throughout and slightly gritty, the other was studded with caseous nodules.

Ventral Mediastinal Glands.—One on the right side, 2 cm. in greatest diameter, was caseo-calcareous throughout and beginning to soften ; the one on the opposite side contained discrete caseous nodules.

Thorax.

Lungs.—There was one slender adhesion to the chest wall. The lung parenchyma was closely beset with caseous encapsuled nodules, varying up to 5 mm. in diameter ; many contained calcareous grains ; there were also numerous small tubercles, some caseous the majority grey and translucent. The lung tissue between the nodules was crepitant, and there were no areas of collapse.

The fringes around the margins of the lungs was slightly hypertrophied.

Bronchial Glands.—The bronchial glands were much enlarged, firm, and beset with caseous and softened nodules varying in diameter up to 5 mm.

Pleura.—On the parietal pleura there was a fleshy fibrous outgrowth, in the centre of which was a caseous nodule 5 mm. in diameter. The pleura elsewhere was slightly roughened.

Diaphragm.—On the pleural surface of the diaphragm there was one lenticular caseous nodule and several small connective tissue tags.

Heart.—Normal.

Abdomen.

Omentum.—There was one millet-seed sized yellow tubercle on the omentum.

Peritoneum.—Normal.

Spleen.—The spleen showed projecting from the surface a number of yellow nodules, which varied in size from 0·5 to rather more than 1 cm. in diameter; on section they were yellow, caseous, and softened, and had fibrous capsules; similar nodules were seen in the depth; the majority of the nodules, however, came near the surface, and formed the projections seen from the surface; altogether there were thirty-six of these nodules; there were also a few caseous tubercles the size of millet-seeds.

Liver.—The liver was enlarged (weight 4 lbs. 3 oz.); the substance was pale and very tough and very closely beset with encapsuled caseous and softened nodules ranging in diameter from 2 to 7 or 8 mm.: the great majority of the nodules varied from 5 mm. upwards; those under the capsule projected slightly, the capsule around many showing slight puckering.

Portal Glands.—The portal glands were slightly enlarged and beset with caseous and softened nodules gritty from calcification.

Kidneys.—In the cortex of one kidney four small greyish-white tubercles were seen; in that of the other there was a millet-seed sized yellow caseous tubercle and two or three translucent grey ones.

Suprarenal Bodies.—Normal.

Coeliac Glands.—All the glands in this group were rather closely beset with caseous and softened nodules ranging from 1 to 3 mm. in diameter.

Lumbar Glands.—One lumbar gland contained one, another two, caseous nodules up to a hemp-seed in size.

Iliac Glands.—The right iliac gland was closely beset with caseous and softened nodules up to 5 mm. in diameter. The left iliac gland contained four caseous tubercles.

A small gland between the suprarenal bodies was partly caseous.

Alimentary Tract.

Tongue, Pharynx, Tonsils.—Normal.

Submaxillary Glands.—There were three or four caseous nodules in each submaxillary gland.

Parotideal Glands.—There was one hempseed-sized caseous nodule in each parotideal gland.

Retro-pharyngeal Glands.—There was one caseous nodule in each.

Intestines.—Normal.

Mesenteric Glands.—The glands in the lower third of the mesentery were slightly enlarged and practically all caseous throughout; the other mesenteric glands contained discrete caseous nodules ranging in size from a millet seed to a large pea; the caseous substance contained calcareous grains.

Ileo-colic and Colic Glands.—These glands contained scattered miliary caseous tubercles, some gritty.

Testicles.—In the substance of the left testicle there was a softened caseous and encapsuled nodule 1 cm. in diameter; the tunica vaginalis over the epididymis of this testicle contained a smaller caseous nodule.

The right testicle was normal.

Thymus.—There was a hempseed-sized caseous nodule in the thymus.

Various Lymphatic Glands.

Prescapular and Prepectoral Glands.—On the left side in front of the scapula there were two slightly enlarged glands; one was closely beset with softened caseous nodules, the largest 8 mm. in diameter, the other contained three smaller caseous nodules; on the right side there were also two glands: one was normal, the other contained about half-a-dozen small caseous nodules.

Cervical Glands.—There were a few caseous nodules in each cervical gland; one on the right side near the thorax contained one large one a centimetre in diameter and a number of small ones.

Precrural Glands.—The left precrural gland contained three yellow caseous and softened nodules, the largest 6 mm. in diameter. In the right there were two similar nodules.

Vertebral Gland.—One of the vertebral glands on the right side was caseous.

Microscopical Examinations.

Nodule from Liver.—No tubercle bacilli seen.

Nodule from Spleen.—No tubercle bacilli seen.

VIRUS H. 85. "H.B."

ABSTRACTS OF THE POST-MORTEM NOTES OF RABBITS INOCULATED WITH CULTURES OR TISSUE EMULSIONS OBTAINED FROM ANIMALS USED IN THE PASSAGE EXPERIMENTS WITH THE VIRUS.

1. Subcutaneous Inoculations with Cultures.

Source of Culture Inoculated.	Dose in Milligrammes.	Number of Rabbit.	Weight in Grammes.		Duration of Life.	Result.
			Initial.	Final.		
Calf Passage.						
Calf 1289 (1st calf) Left prescapular gland.	24·0 mg.	**1693**	1,250	1,100	Died 133 days	Very slight generalised tuberculosis. The cause of death was not apparent. There was a nodular caseous local tumour, and the adjacent glands were caseous and softened throughout. The lungs contained a few small glassy tubercles and a few miliary tubercles with caseous centres. On the surface of the kidneys small pits, and grey foci some with caseous centres, were seen; section showed a few caseating streaks. There was no tuberculosis elsewhere.
	10·0 mg.	**1694**	1,000	2,950	Killed 464 days	Local tuberculosis and slight tuberculosis of lungs. The local tumour was moderately large and composed of caseous nodules bound together by fibrous tissue. The adjacent gland was beset with calcareous particles. The lungs contained scattered caseous and gritty or calcareous nodules up to a pea in size. There was no tuberculosis elsewhere.
Calf 1319 (2nd calf) Left bronchial gland, through G.P. 2991.	20·0 mg.	**1921**	1,650	2,000	Died 194 days	Very slight generalised tuberculosis. The cause of death was not apparent. The local lesion was a thin-walled cyst filled with caseo-pus; the nearest glands contained softened caseous nodules. In each caudal lobe of the lung there was a caseous nodule or two and half way round one caudal lobe a caseating fringe, in the rest of the lungs two or three small tubercles were seen. One kidney contained three caseous tubercles and there was a caseous tubercle in the spleen. There was no tuberculosis elsewhere.
	10·0 mg.	**1922**	1,400	1,400	Died 211 days	General tuberculosis, not severe. The local lesion was large caseous and softened and the adjacent gland was partly caseous. In the thin margins of the lungs there were a few caseating patches and collapsed patches with caseous foci, in the rest of the lung scattered tubercles were seen. There was a caseous tubercle in the spleen, and the liver showed fairly numerous minute grey points (smear, one T.B. seen). There was a moderate number of caseous tubercles and caseous streaks in each kidney. The end of the ileum showed scattered caseous foci (smear, one T.B. seen); there were caseous nodules on the mesentery, in the subperitoneal tissues, and in the areolar tissues of the groin; numerous small tubercles were seen in the omentum, and there was early tuberculosis of the synovial membrane of the knee-joints.
Calf 1397 (3rd Calf) Mediastinal gland.	10·0 mg.	**2020**	2,100	1,570	Died 137 days	General tuberculosis, not sufficient to account for death. There was a caseous and softened local lesion, and the nearest glands were caseous and softened. The lungs contained scattered caseous tubercles with grey margins and in the thin margins a few caseating patches. There were fairly numerous miliary tubercles on the dorsal mediastinal pleura. In the cortex of each kidney was a moderate number of caseous tubercles and a few larger wedge-shaped nodules, grey with caseous foci; a few caseous tubercles were seen in the medulla. The coeliac glands were beset with caseous tubercles.

VIRUS H. 85. "H.B."—*continued.*

ABSTRACTS OF THE POST-MORTEM NOTES OF RABBITS INOCULATED WITH CULTURES OR TISSUE EMULSIONS OBTAINED FROM ANIMALS USED IN THE PASSAGE EXPERIMENTS WITH THE VIRUS—*continued.*

1. SUBCUTANEOUS INOCULATIONS WITH CULTURES—*continued.*

Source of Culture Inoculated.	Dose in Milligrammes.	Number of Rabbit.	Weight in Grammes.		Duration of Life.	Result.
			Initial.	Final.		
Calf 1397 (3rd Calf) Mediastinal gland—*cont.*	10·0 mg.	**2021**	2,100	2,750	Killed 209 days	Slight generalised tuberculosis. There was a large thin-walled cyst filled with caseo-pus at the seat of inoculation, and an adjacent gland was partly caseous. The lungs contained discrete fibro-calcareous tubercles. One kidney showed on the surface three projecting nodules, the largest the size of a pea, and a depressed patch of fibrous tissue with caseo-calcareous foci; some caseous streaks were seen on section. There was no tuberculosis elsewhere.
Calf 1445 (4th calf) ... Mediastinal gland.	10·0 mg.	**2174**	1,800	1,100	Died 134 days	Chronic general tuberculosis, not severe. The local tumour was composed of thick caseous material in a thin capsule; the adjacent gland contained a caseous tubercle. The lungs showed on the surface firm caseous nodules (up to 5 mm.) and scattered grey tubercles; in the thin margins there was a narrow fringe of caseating tissue. Grey foci were seen on the surface of the liver, and a small number of tubercles in the spleen. The kidneys showed on the surface small pits, depressed scars in which were grey nodules with caseous foci, and a miliary tubercle or two; on section caseous streaks were seen. There were caseous nodules on the omentum (numerous), mesentery, and meso-colon, in the subperitoneal tissues of the back, around the bladder, and on the meso-testis, and a few in the areolar tissues of groin and pubis. The epididymes were caseous, and there were a few caseous nodules in the testes. Both eyes were tuberculous, and the lachrymal glands contained caseous nodules.
	10·0 mg.	**2175**	1,550	900	Died 120 days	Chronic general tuberculosis, not severe. There was a thin-walled caseous local lesion, and the nearest glands were caseous and softened. The lungs showed caseous nodules in the thin margins, and small scattered tubercles elsewhere. The kidneys showed on the surface numerous small pits and a few tubercles and grey nodules; caseous streaks were seen in the depth. There were scattered caseous tubercles in the areolar tissues of the groin, axilla, and lumbar regions. The testicles were enlarged and extensively caseous. There was early tuberculosis of the eyes.
Calf 1531 (5th calf) ... Liver.	10·0 mg.	**2378**	1,550	2,100	Killed 147 days	Slight general tuberculosis. The local tumour was nodular and caseous, and the nearest glands were caseous and softened. The lungs contained scattered submiliary grey tubercles, some with caseous centres. Each kidney showed a moderate number of miliary tubercles with minute opaque central foci, and one contained also three grey nodules with caseous foci, the largest the size of a pea. There was a caseous nodule on one epididymis, another in one lachrymal gland, and another over one malar bone which was ulcerated.
	10·0 mg.	**2379**	1,200	1,120	Died 144 days	Chronic general tuberculosis, not severe. The local lesion consisted of a mass of caseous nodules, and the nearest glands were caseous and softened. The lungs contained a moderate number of caseous tubercles mainly submiliary. In the cortex of each kidney there were moderately numerous caseous tubercles and nodules (up to 3 mm.); the latter did not project. Most of the lymphatic glands contained caseous tubercles. One lachrymal gland contained a caseous nodule, and the opposite eye showed a few grey tubercles in the iris.

2. Intravenous Inoculations with Cultures.

				Calf Passage.		
Calf 1289 (1st calf) Left prescapular gland.	1·0 mg.	**1692**	2,000	1,300	Died 29 days	General miliary tuberculosis.
				Rhesus Monkey Passage.		
Rhesus Monkey 119 (1st monkey) Spleen.	1·0 mg.	**2054**	2,250	1,550	Died 39 days	General miliary tuberculosis.
	0·1 mg.	**2055**	2,000	1,220	Died 38 days	General miliary tuberculosis.
	0·01 mg.	**2056**	1,500	1,450	Died 136 days	General tuberculosis, not severe. The lungs were crepitant and contained discrete grey tubercles with caseous centres, and around the margins were small caseous patches. The tracheal glands were partly caseous. The spleen contained numerous calcareo-caseous tubercles, and there were a few minute grey foci in the liver. Each kidney showed fairly numerous caseous foci and several caseous streaks. Many of the abdominal glands contained caseous tubercles.

3. Subcutaneous Inoculations with Tissue Emulsions.

Source of Tissue Emulsion Inoculated.	Dose of Emulsion.	Number of Rabbit.	Weight in Grammes. Initial.	Weight in Grammes. Final.	Duration of Life.	Result.
						Calf Passage.
Calf 1289 (1st calf) Left prescapular gland.	T.B. moderately numerous. 2·0 cc.	**1565**	1,620	2,680	Killed 189 days	Local tuberculosis and very slight tuberculosis of the lungs. The local lesion was a flat cyst with caseo-purulent contents, and around it were some discrete caseous nodules; the adjacent gland contained a caseo-purulent nodule. The lungs contained a caseous gritty nodule, a grey tubercle, and in the thin margin of one lobe a narrow caseous band 1½ inches long. There was no tuberculosis elsewhere.
	2·0 cc.	**1566**	1,320	1,950	Died 83 days	Local tuberculosis and very slight tuberculosis of lungs. Death from cellulitis of back. At the site of inoculation there was a haemorrhagic patch studded with small yellow tubercles; the adjacent glands contained caseous tubercles. The lungs contained half-a-dozen tubercles some with caseous centres, and one tracheal gland showed a caseous focus. There was no tuberculosis elsewhere.
G.P.'s 2989-90 from **Calf 1319** (2nd calf) left prescapular gland.	3·0 cc. T.B. not very numerous.	**1816**	3,450	1,920	Died 228 days	Chronic general tuberculosis. The local lesion was a thin-walled cyst filled with thick caseo-pus; the nearest glands were caseous and softened The lungs contained fairly numerous firm caseous nodules up to a split-pea in size and a few larger caseous masses. There were numerous flattened caseous growths of various sizes on the pleura. The spleen contained scattered caseous tubercles. The kidneys showed a moderate number of projecting caseous nodules up to a hemp seed in size. There were a few caseous tubercles on the mesentery, and there was early tuberculosis of one elbow-joint.

VIRUS H. 91. "H.S."

LUPUS.

VIRUS H. 91. "H.S."

LUPUS.

CULTURE INOCULATIONS.

I.—January 20, 1908.

The strain was derived from the original material through G.P. 2590, and had been in cultivation a total period of 82 days.

The culture used was the 6th generation, 22 days old.

FOWLS.

Number.	Method.	Dose.	Duration of Life.	Result.
79	Intrav.	10·0 mg.	K. 239 days	No T.*
81	Intrav.	10·0 mg.	K. 239 „	Early T. of intestines, liver, and spleen (spontaneous).

* A guinea-pig (3268) was inoculated intraperitoneally with an emulsion of lung of Fowl 79. It was killed after 74 days and showed slight tuberculosis.

CULTURE

Derived from the spleen of Fowl 81. The 4th generation of culture, 25 days old, was used for inoculation on November 13, 1908.

PIGEON 75.

Intramuscular.

Dose : 1½ glycerin serum tubes.

Killed after 224 days.

P.M.—Local lesion only.

PIGEON 77.

Intramuscular.

Dose : 1½ glycerin serum tubes.

Killed after 224 days.

P.M.—Local lesion only.

RABBITS.

Number.	Method.	Dose.	Duration of Life.	Result.
1688	Intrav. and Subcut.	1·0 mg.	K. 235 days	Caseous nodule in tissues of ear. One or two tubercles? in lungs.
1687	Intrav.	0·1 mg.	K. 235 „	Two tubercles in lungs.
1686	Subcut.	50·0 mg.	K. 235 „	Local lesion and pus in one kidney.
1689	Subcut.	10·0 mg.	K. 235 „	Local lesion and two tubercles in the lungs.

GUINEA-PIGS.

Number.	Method.	Dose.	Duration of Life.	Result.
2900	Intrap.	1·0 mg.	D. 21 days	Early G. T.
2898	Intrap.	0·1 mg.	D. 19 „	Early G. T.
2901	Subcut.	1·0 mg.	D. 40 „	Early G. T.
2899	Subcut.	0·1 mg.	D. 73 „	G. T.

CALF 1353.

Subcutaneous.

Dose : 50·0 mg.

Killed : May 18, 1908.

119 days.

P.M. — Small thin-walled cyst containing caseopus at seat of inoculation, and half a dozen small caseo-calcareous nodules in left prescapular gland. No tuberculosis elsewhere.

CULTURE INOCULATIONS—*continued.*

II.—March 5, 1908.

The strain was derived from the original material through G.P. 2590, and had been in cultivation a total period of 127 days.

The culture used was the 9th generation, 22 days old.

MONKEY 133.

Subcutaneous.

Dose : 0·1 mg.

Killed : September 24, 1908.

203 days.

P.M.—General tuberculosis similar to but more severe than that of Monkey 139. The eyes were normal.

CULTURE

Derived from the spleen of Monkey 133.

The 4th generation, 17 days old, was used for inoculation on November 5, 1907.

MONKEY 239.

Subcutaneous. Dose : 1·0 mg.

Died : December 4, 1908. 29 days.

P.M.—Small caseous local lesion ; one cervical and one vertebral gland each showed a caseous focus. There was no tuberculosis elsewhere. The cause of death was not apparent.

MONKEY 241.

Subcutaneous. Dose : 1·0 mg.

Died : November 22, 1908. 17 days.

P.M.—Spontaneous tuberculosis.

GUINEA-PIGS.

Number.	Method.	Dose.	Duration of Life.	Result.
3345	Subcut.	1·0 mg.	D. 118 days	G. T.
3346	Subcut.	1·0 mg.	D. 41 „	Slight early T.

MONKEY 139.

Subcutaneous.

Dose : 1·0 mg.

Killed : September 18, 1908.

197 days.

P.M.—There were several caseous nodules at the seat of inoculation : the neighbouring glands were much enlarged, caseous and softened. There were three small tubercles in the lung, eight softened caseous nodules in the spleen and three muco-purulent cysts in the liver. Many of the lymphatic glands contained caseous nodules. Behind the right eyeball there was a large caseo-purulent swelling and the eye was disorganised and filled with caseo-pus ; another caseous nodule was situated just below the orbital ridge. There were four caseous nodules on the frontal bones of the skull, the bone below each being necrosed. Five yellow caseous nodules and one soft grey nodule were seen on the pons.

GUINEA-PIGS.

Number.	Method.	Dose.	Duration of Life.	Result.
2987	Subcut.	1·0 mg.	D. 24 days	Early G. T.
2988	Subcut.	1·0 mg.	D. 55 „	G. T.

CALF 1353. Virus H. 91. "H.S."

Subcutaneous inoculation of culture derived from the original material through Guinea-pig 2590.

Dose—50·0 milligrammes.

Date of Inoculation—January 20, 1908. [Age 24 days.]

Killed when in good health—May 18, 1908. [119 days after inoculation.]

Clinical Notes.

The calf remained well during the experiment.

Temperature.

There was a short period of pyrexia commencing on the 10th day after inoculation, lasting eleven days; the maximum temperature recorded was 40·6° C. Subsequently the temperature was normal.

Tuberculin Test.

February 21, 1908. [32 days after inoculation.] Reacted. Rise of temperature, 1·0° C.

Weights.

	cwt.	qrs.	lbs.
January 20, 1908	0	3	16
May 18, 1908	1	1	24

Total gain of weight.—2 qrs. 8 lbs.

Average rate of gain per week.—3·7 lbs.

POST-MORTEM EXAMINATION.

The carcass was in good condition.

Local Lesion.—At the seat of inoculation on the left side of the neck there was a small prominent circumscribed fluctuating swelling measuring 6·5 by 4·5 by 3·5 cm.; on section it was a thin-walled cyst filled with tenacious caseo-pus containing a few solid caseous masses; calcareous grains were detected on the internal surface of the cyst wall.

Left Prescapular Gland.—The left prescapular gland measured 5 by 2 by 1·2 cm.; it contained in the cortex half a dozen yellow caseo-calcareous nodules ranging in size from 2· to 5· mm. in diameter; three were close together in a group, the others were isolated.

Right Prescapular Gland.—The right prescapular gland measured 4·5 by 1·5 by 0·9 cm., and was normal on section.

Thoracic Glands.—There was a greyish-white, pinhead-sized fibrous body in a mediastinal gland. Other thoracic glands were normal.

Liver.—In the depth of the liver there was a hemp-seed sized grey nodule, with a minute yellowish centre; otherwise the liver was normal.

The remaining organs and glands were examined and found normal.

Various Lymphatic Glands.

Precrural, Popliteal, Gluteal, Ischiatic, Pudic.—Normal.

Microscopical Examination.

Fibrous Body from Thoracic Gland.—No tubercle bacilli.

Nodule from Liver.—No tubercle bacilli.

RHESUS MONKEY 239. Virus H. 91. "H.S."

(A young animal.)

Subcutaneous inoculation of culture derived from the spleen of Monkey 133.

Dose—1·0 milligramme.

Date of Inoculation—November 5, 1908.

Died—December 4, 1908. [29 days after inoculation.]

POST-MORTEM EXAMINATION.

The body was in fair condition; there was plenty of subcutaneous fat.

Local Lesion—In the subcutaneous tissues over the right scapula there was a breaking-down caseous lesion measuring 2·5 by 2·5 by 1 cm. the skin over which was intact.

Axillary Glands.—Normal.

Cervical Glands.—One behind the right clavicle was slightly enlarged and contained a caseous focus.

Vertebral Glands.—One in the 7th interspace was slightly enlarged and showed a caseous focus in the centre.

There was no sign of tuberculosis elsewhere; the lungs, liver, spleen and kidneys were perfectly normal to the naked eye and there was nothing to account for the death of the animal.

Microscopical Examination.

Smear from Spleen—A few tubercle bacilli.

RHESUS MONKEY 133. Virus H. 91. "H.S."

(A young animal.)

Subcutaneous inoculation of culture derived from the original material through Guinea-pig 2590.

Dose—0·1 milligramme.

Date of Inoculation—March 5, 1908.

Killed when in good health—September 24, 1908. [203 days after inoculation.]

Clinical Notes.

The monkey remained well during the experiment. The weight at death was 2250 grammes.

POST-MORTEM EXAMINATION.

The carcass was in good condition.

Local Lesion.—In the subcutaneous tissues over the right scapula, there were about a dozen caseous nodules, varying from a hemp seed to a pea in size, the skin over one of which was puckered and scarred.

Axillary Glands.—On the right side there were two soft fluctuating glands, one the size of a pigeon's egg, the other a little smaller, both of which had thin fibrous walls and caseo-purulent contents. Those on the left side were normal.

Cervical Glands.—On the right side behind the

clavicle there were a pea-sized and two hemp-seed sized glands which were caseous throughout, and one which contained a soft caseous nodule 5 mm. in diameter. Other cervical glands were normal.

Vertebral Glands.—On the right side one in the 7th interspace, the size of a split pea, was caseous throughout; another smaller one in the 11th interspace was also caseous; on the left side one in the 11th space 1 cm. in diameter was caseous throughout.

Thorax.

Pleura and Heart.—Normal.

Lungs.—The lungs were expanded and crepitant throughout except for one small patch of collapse in the left caudal lobe; they contained a moderate number of hard nodules varying in diameter up to nearly 5 mm.; they were evenly distributed, each lung containing about three dozen, and on section were yellowish-white with narrow grey margins; the majority were firm, but some were softened or beginning to soften.

Bronchial Glands. — The intertracheo-bronchial glands were much enlarged and caseous practically throughout; the other bronchial glands (four in number) were also enlarged, but not to the same extent; one showed no caseation; the others contained five caseous and softened nodules, the largest the size of a large pea.

Ventral Mediastinal Glands.—One on the left side at the entrance to the thorax, the size of a large pea, was caseous and softened throughout.

Abdomen.

Omentum and Peritoneum.—Normal.

Spleen.—The spleen was normal in size, and showed in the pulp twenty yellow caseous nodules with fibrous margins, ranging in diameter from about 1 to 2 mm.; one of the nodules projected in the hilum more than half its diameter.

Splenic Lymphatic Glands.—Normal.

Liver.—The liver showed in the substance three fibrous-walled cysts, 3 to 5 mm. in diameter, with greenish muco-purulent contents, and three or four greyish-white miliary tubercles. In the longitudinal fissure there were two pea-sized cheesy caseous nodules with fibrous margins.

Pancreatic Glands.—On the anterior border of the pancreas there were three moderately enlarged glands, all of which were yellow caseous and softened in from three-quarters to nearly the whole of their extent.

Kidneys.—The left kidney showed in the cortex half-a-dozen yellow caseous nodules with grey margins, ranging from 1 to 2 mm. in diameter. There were four similar nodules in the right kidney, the largest 3 mm. in diameter.

Suprarenal Bodies.—Normal.

Lumbar Glands.—Between the kidneys there was a group of enlarged glands, the largest about 1 cm. in diameter; four were caseous and softened practically throughout; two were oedematous and congested, but not caseous.

Iliac Glands.—The one on the left side was much enlarged, the size of a filbert, and caseous and softened throughout; the one on the right side and the ileo-sacral glands were normal.

Alimentary Tract.

Tongue, Pharynx, Tonsils.—Normal.

Submaxillary Glands.—On the right side one nearly 1 cm. in diameter was caseous and softened throughout; the one on the left side contained a millet-seed sized caseous tubercle.

Retro-pharyngeal Glands.—The left pharyngeal gland, the size of a pea, was partly caseous; the right was normal.

Intestines.—In the small intestines there were 12 transverse ulcers up to 8 mm. in length with slightly thickened margins and fibrous base; on the peritoneal surface of two there was in each case one caseous tubercle.

In the cæcum and early part of the large intestine there were a good many irregular ulcers; these, like those in the small intestine, showed no sign of caseation.

Mesenteric Glands.—Seven mesenteric glands contained from one to six caseous nodules, the largest the size of a hemp seed.

Ileo-Colic Glands.—There were similar nodules in the ileo-colic glands.

Colic Glands.—Practically all the glands of the first part of the colon were enlarged, showing varying degrees of caseation, and many were adherent to the wall; of the remainder, four contained each one millet-seed sized caseous tubercle.

Brain.—In the grey matter of the gyrus fornicatus on the right side just above the anterior part of the rostrum of the corpus callosum there was a yellow caseous nodule 8 mm. in diameter; the nodule was softened in the centre, firm elsewhere, and had a narrow grey margin; it projected slightly from the inner surface of the cerebrum, and was adherent to the opposite hemisphere; the grey matter of the latter at the point of contact showed a small patch of caseation.

Skull.—In the frontal bone there were two foci of caseo-necrosis each about 3 mm. in diameter, and in the parietal bone three; on removing the calvarium the whole thickness of the skull at these points was necrosed, and there was caseo-pus between the dura mater and the internal table.

Under the dura mater in the middle fossa of the skull there was a collection of caseo-pus 5 mm. in diameter; the bone under this was necrosed.

Eyes.—Normal.

Microscopical Examination.

Emulsion of Tubercles from Spleen.—A few tubercle bacilli seen.

Smear from Nodule in Cerebrum.—No tubercle bacilli seen.

Smear from Nodule in Skull-cap.—A few tubercle bacilli seen.

RHESUS MONKEY 139. Virus H. 91. "H.S."

(A young animal.)

Subcutaneous inoculation of culture derived from the original material through Guinea-pig 2590.

Dose—1·0 milligramme.

Date of Inoculation—March 5, 1908.

Killed when in moderately good health—September 18, 1908. [197 days after inoculation.]

Clinical Notes.

The disease of the right eye (*see* post-mortem notes) commenced seven weeks before the monkey was killed with slight redness of the conjunctivæ, lachrymation, and slight swelling of the conjunctiva at the external canthus. The swelling increased in size and soon became a prominent red tumour. The palpebral fissure became widely dilated, and the eyeball was pushed forwards and inwards. For several weeks it was impossible for the eyelids to cover the ball and the cornea as a result gradually became opaque.

The general condition was moderately good when the monkey was killed. It was active and appeared fairly well, but since the disease of the eye commenced it had not grown, and had lost flesh.

POST-MORTEM EXAMINATION.

The carcass was in fairly good condition.

Local Lesion.—In the subcutaneous tissues over the anterior part of the right scapula there was a soft caseous nodule with a thin fibrous wall the size and shape of a broad bean. Two or three centimetres

posterior to this the skin showed several small white scars, in one of which there was a minute opening; this communicated with the caseous nodule under it. Near the latter there was a flattened caseous nodule 1 cm. in diameter. There were three similar but smaller caseous nodules under the aponeurosis of the superficial muscles over the scapula.

Axillary Glands.—In the right axilla there was a chain of enlarged glands extending from the level of the nipple to the clavicle; the largest of the glands was the size of a thrush's egg, and all were practically caseous and softened throughout. The most posterior one of the chain was adherent to the skin which was ulcerated.

In the left axilla one gland contained a softened caseous nodule with a fibrous wall 1 cm. in diameter. Another contained a hemp-seed sized caseous nodule, while a third contained a caseous tubercle.

Cervical Glands.—The cervical glands on the right side behind the clavicle were much enlarged, and were fused together to form a large thin walled loculated cyst filled with greenish yellow curdy caseo-pus.

The cervical glands on the left side were normal.

Vertebral Glands.—Normal.

Thorax.

Lungs.—The lungs were crepitant throughout and collapsed normally. In the left lung there were two fibrous tubercles, one the size of a pin's head, the other that of a millet seed; in the right lung there was one pinhead-sized fibrous tubercle.

Bronchial Glands.—The bronchial glands were normal in size and appearance.

Heart and Pleura.—Normal.

Abdomen.

Omentum and Peritoneum.—Normal.

Spleen.—The spleen was normal in size: it showed in the pulp half a dozen softened caseous nodules ranging from 1 to about 2·5 mm. in diameter; the capsule of the spleen at the anterior end was thickened and contained two projecting softened caseous nodules, the largest the size of a hemp seed.

Splenic Lymphatic Glands.—Normal.

Liver.—In the liver substance there were two cysts each about 1 cm. in diameter with thin fibrous walls and muco-purulent contents. There was a much larger but otherwise similar cyst in one of the small lobes of the liver.

The gland on the head of the pancreas contained three softened caseous nodules, the largest the size of a smal pea.

Kidneys and Suprarenal Bodies.—Normal.

Lumbar Glands.—One lumbar gland contained a small softened caseous nodule.

Iliac Glands.—A right iliac gland was enlarged and contained a pea-sized caseous and softened nodule.

Alimentary Tract.

Tongue, Pharynx, Tonsils.—Normal.

Submaxillary Glands.—The left submaxillary gland contained a pea-sized softened and caseous nodule. The right was normal.

Retro-pharyngeal Glands.—Each pharyngeal gland contained a pea-sized caseous and softened nodule.

Intestines.—Normal.

Mesenteric, Ileo-Colic, and Colic Glands.—Normal.

Inguinal Glands.—In the right inguinal gland there was a millet-seed sized softened and caseous nodule.

In the left inguinal gland there was a hemp-seed sized caseous nodule.

Eyes, Cranium, and Brain.—Projecting from the external surface of the right eyeball between the eyelids there was a prominent reddish fleshy lobed swelling over which the eyelids were stretched; the palpebral fissure was widely dilated and the eyeball pushed forwards and inwards; the cornea was slightly opaque and the lens also.

The swelling when cut into was found to be merely thickened and oedematous conjunctiva. On removing the eyeball a large swelling was seen projecting from the back; this was soft and composed of yellow caseo-pus; when cut into, the eye was found to be filled with caseo-pus and there was a communication between the interior of the eye and the swelling outside.

Just below the orbital ridge above the internal canthus of the right eye there was a softened caseous nodule the size of a large pea, the skin over which showed two small recent openings.

Just above the right orbital ridge there was a thin-walled somewhat flattened softened caseous nodule, 2 cm. in greatest diameter; the bone beneath this showed early necrosis.

In the subcutaneous tissues of the scalp behind this nodule there were two similar nodules each 1 cm. in diameter, one situated about the centre of the parietal bone, the other on the parieto-occipital fissure.

There was a similar nodule just above the orbital ridge on the left side.

The frontal bone showed altogether four small patches of caseo-necrosis, the external and internal tables in each case being eaten away.

On the left side of the pons just in front of the cerebellum partly replacing the small anterior lobe there was a group of five yellow caseous and softened nodules, the largest 5 mm. in diameter. On the under surface of the pons on this side there was a flattened soft greyish lenticular nodule, 5 mm. in diameter.

The brain was otherwise normal.

The left eye was normal.

Microscopical Examinations.

Caseo-pus from Swelling on the Right Eyeball.—Tubercle bacilli numerous.

Caseous Nodule in front of the Cerebellum.—Tubercle bacilli very numerous.

Pus from one of the Nodules in the Liver.—Several clumps of tubercle bacilli.

RHESUS MONKEY 241. Virus H. 91. "H.S."

(A young animal.)

Subcutaneous inoculation of culture derived from the spleen of Monkey 133.

Dose—1·0 milligramme.

Date of Inoculation—November 5, 1908.

Died—November 22, 1908. [17 days after inoculation.]

POST-MORTEM EXAMINATION.

Spontaneous tuberculosis.

Lungs.—The right anterior lobe was solid and caseous throughout and firmly adherent to the chest wall. The rest of the lung was crepitant and contained scattered caseous tubercles up to a millet seed in size.

Bronchial Glands.—The bronchial glands were enlarged and caseous.

Spleen.—The spleen was enlarged and contained many caseous nodules of various sizes.

Liver.—The liver contained a moderate number of caseous nodules.

Portal Gland.—The portal gland was enlarged caseous and softened throughout.

Kidneys.—The kidneys contained altogether three caseous nodules ranging in size from a millet-seed to a small pea.

Inguinal Glands.—The right inguinal glands were enlarged and caseous.

VIRUS H. 92. "D.N."

LUPUS.

VIRUS H. 92. "D.N."

CULTURE INOCULATIONS.

I.—January 2, 1908.

The strain was derived from the original material through G.P. 2592, and had been in artificial cultivation a total period of 64 days.

The culture used was the 4th generation, 21 days old.

RABBITS.

Number.	Method.	Dose.	Duration of Life.	Result.
1630	Intrav.	1·0 mg.	D. 183 days	Slight chronic G.T.
1631	Intrav.	0·1 mg.	D. 188 „	Slight T. of lungs, bronchial glands, and kidneys.
1632	Subcut.	10·0 mg.	K. 258 „	Local tuberculosis.

GUINEA-PIGS.

Number.	Method.	Dose.	Duration of Life.	Result.
2860	Intrap.	1·0 mg.	D. 20 days	G. T.
2861	Subcut.	1·0 mg.	D. 1 day	No T. No apparent cause of death.

PIG 107.

Subcutaneous.

Dose : 50·0 mg.

Killed : May 14, 1908.

133 days.

P.M.—Scar at seat of inoculation, and scattered caseous tubercles in the subcutaneous tissues. A right inguinal and a ventral mediastinal gland were enlarged, caseous, and softened. In the lungs were numerous indefinite greyish foci in places forming small patches. Two small caseous nodules were seen in left suprarenal. The bronchial glands and two or three neck glands contained scattered soft whitish foci. There was an opening in the cornea of each eye and the whole eye was disorganized; there was no definite T., but T.B. were found in the anterior chamber.

PIG 109.

Subcutaneous.

Dose : 50·0 mg.

Killed : June 9, 1908.

159 days.

P.M.—There were scattered caseous nodules in the subcutaneous tissues at the seat of inoculation, three of which had ulcerated. The adjacent inguinal and ventral mediastinal glands were enlarged and caseous; one precrural gland contained caseous nodules. In the lung two caseous tubercles were seen. One submaxillary gland contained caseous tubercles. There was an opening in the cornea of the right eye and the whole eye was disorganized. T.B. were found in the anterior and posterior chambers.

CALF 1317.

Subcutaneous.

Dose : 50·0 mg.

Died : January 28, 1908.

26 days.

P.M.—Renal disease. Flat caseo-necrotic local lesion. Left prescapular and one cervical gland largely composed of caseous networks in a translucent matrix. Some minute foci were seen in lungs and liver (smears showed few T.B.) One yellow focus was seen in a portal gland.

January 2, 1908.

The strain was derived from the original material through G.P. 2593, and had been in artificial cultivation a total period of 64 days.

The culture used was the 4th generation, 21 days old.

RABBITS.

Number.	Method.	Dose.	Duration of Life.	Result.
1633	Subcut.	22·0 mg.	D. 208 days	Local T., and slight T. of lungs and kidneys.
1634	Subcut.	50·0 mg.	K. 258 „	Local lesion only.

VIRUS H. 92. "D.N."—*continued.*

CULTURE INOCULATIONS—*continued.*

II.—February 21, 1908.

The strain was derived from the original material through G.P. 2592, and had been in artificial cultivation a total period of 114 days.

The 8th generation of culture, 18 days old, was used.

CALF 1377.

Intravenous.

Dose : 10·0 mg.

Died : March 24, 1908.

32 days.

P.M.—Pneumonic consolidation of lungs; minute grey foci were seen everywhere throughout the organ. Early tuberculosis of thoracic glands. Numerous minute grey granules (early tubercles) were seen on the endocardium. A few grey foci were seen on the surface of the liver, and scattered grey foci in the kidneys. T.B. were moderately numerous in the organs, and in all the glands examined.

HORSE 7.

Intravenous.

Dose : 10·0 mg.

Killed : July 7, 1908.

137 days.

P.M.—The lungs were crepitant; they showed small translucent grey tubercles, numerous in the posterior third of the caudal lobes, scanty in the anterior lobes. In the bronchial glands were a few calcareous foci. The liver contained a grey translucent tubercle.

Guinea-pig 3144.

Intraperitoneal.

Emulsion of spleen.

Killed : 80 days.

Chronic general tuberculosis.

HORSE 9.

Subcutaneous.

Dose : 100·0 mg.

Killed : July 6, 1908.

136 days.

P.M.—Linear scar at seat of inoculation; two left prescapular glands contained each a small fibro-calcareous patch. In the lung one small grey gritty nodule was seen, and one bronchial gland showed a calcareous tubercle. One ileo-colic gland contained a few foci.

Guinea-pig 3143.

Intraperitoneal.

Emulsion of spleen.

Killed : 81 days.

Healthy.

RABBITS.

Number.	Method.	Dose.	Duration of Life.	Result.
1739	Intrav.	1·0 mg.	D. 55 days	Slight T. of lungs. Death from cellulitis.
1740	Intrav.	1·0 mg.	K. 208 „	G.T. (spontaneous).

GUINEA-PIGS.

Number.	Method.	Dose.	Duration of Life.	Result.
2969	Subcut.	1·0 mg.	D. 46 days	G. T.
2970	Subcut.	1·0 mg.	D. 58 „	G. T.
2971	Fed daily for five days; the daily dose was 3·0 mg. between the three guinea-pigs.		D. 36 days	G. T. (Culture insufflated).
2972			D. 148 „	Chronic G. T.
2973			D. 126 „	Chronic G. T.

VIRUS H. 92. "D.N."—*continued.*

CULTURE INOCULATIONS—*continued.*

II.—February 21, 1908—*continued.*

The strain was derived from the original material through G.P. 2592.

The 8th generation of culture, 18 days old, was used.

MICE.

Number.	Method.	Dose.	Duration of Life.	Result.
29	Intrap.	10·0 mg.	D. 1 day	No apparent cause for death.
30	Intrap. and Intra-muscular	10·0 mg.	D. 1 „	
31	Subcut.	50·0 mg.	D. 10 days	Local tuberculosis with slight dissemination of T. B.
32	Subcut.	50·0 mg.	D. 26 „	Local ulcer. T.B. in liver and spleen.

III.—February 24, 1908.

The strain was derived from the original material through G.P. 2593, and had been in artificial cultivation a total period of 117 days.

The culture used was the 9th generation, 21 days old.

FOWLS.

Number.	Method.	Dose.	Duration of Life.	Result.
87	Intrav.	33·0 mg.	K. 206 days	No T.
89	Intrav.	50·0 mg.	K. 206 „	One small greyish tubercle in liver only.

IV.—May 27, 1908.

The strain was derived from the original material through G.P. 2593, and had been in artificial cultivation a total period of 210 days.

The culture used was the 14th generation, 20 days old.

MONKEY 177.

Subcutaneous.

Dose : 1·0 mg.

Died : July 5, 1908.

39 days.

P.M.—General tuberculosis.

CALF 1317. Virus H. 92. "D.N."

Subcutaneous inoculation of culture derived from the original material through Guinea-pig 2592.
Dose—50·0 milligrammes.
Date of Inoculation—January 2, 1908. [Age 8 weeks.]
Died—January 28, 1908. [26 days after inoculation.]

Clinical Notes.

The calf was first noticed to be ill on January 27, when it refused all solid food. On the following day it was found lying down breathing rather rapidly and in a semi-comatose condition. The coma deepened, and the calf died in the afternoon.

Temperature.

The temperature slowly rose, reaching 40·1° C. on the 14th day after inoculation. Three days later it fell suddenly to 38·2° C.; it then rapidly rose again to 40·1° C., and remained above normal until the calf died, on the 26th day after inoculation.

Tuberculin Test.

The calf was not tested subsequent to inoculation.

Weights.

	qrs.	lbs.
January 2, 1908	3	18
January 28, 1908	3	9

Total loss of weight.—9 lbs.

POST-MORTEM EXAMINATION.

The carcass was in fair condition.

Local Lesion.—In the subcutaneous tissues on the left side of the neck there was a flat patch of yellow caseo-necrotic tissue, adherent to and infiltrating the skin, measuring 12 by 7 cm. in superficial area and 1·5 cm. in greatest thickness; the central parts of the thickest portion were beginning to break down.

Left Prescapular Gland.—The left prescapular gland measured 6·5 by 4 by 3 cm. More than three-quarters of its cortex was firm and composed of a close yellow caseous network in a grey translucent matrix.

Right Prescapular Gland.—The right prescapular gland measured 4 by 1·5 by 0·9 cm. and was normal on section.

Prepectoral Glands.—Normal.

Cervical Glands.—One in the middle of the neck on the left side was enlarged, and showed half its substance replaced by a mass of grey translucent tissue containing a fine caseous network.

Thorax.

Lungs. — The lungs were crepitant throughout except for a few collapsed lobules; they showed on the surface evenly distributed though not very numerous grey and reddish grey foci up to 0·5 mm. in diameter (? early tubercles). Similar foci were seen on section.

Thoracic Glands.—The bronchial and mediastinal glands were slightly congested and oedematous; nothing tuberculous was seen on section.

Larynx and Trachea.—Normal.

Pleura, Heart.—Normal.

Abdomen.

Omentum and Peritoneum.—Normal.

Spleen.—Appeared normal.

Liver.—The liver was pale, the substance yellowish and friable. It showed under the capsule sparsely scattered minute grey foci. None was seen on section.

Portal Glands.—A minute yellow point was seen in one of the glands.

Coeliac Glands.—These glands showed no naked-eye evidence of tuberculosis.

Kidneys.—The kidneys were much enlarged, the right weighing 13 ozs., the left 12 ozs. The capsules stripped readily. The surfaces were irregular, and each lobule was marked by depressed greyish fibrous-looking patches, irregular in outline, which penetrated the cortex as greyish streaks or patches; the kidney tissue between these areas was pale, and the substance generally was rather tough; the cortex was increased in thickness; there was considerable oedema in the medulla; no gravel or stones were found, and the ureters and bladder appeared normal.

The tissues around the kidneys, ureters, lumbar and iliac glands, and the rectum were very oedematous.

Lumbar Glands.—The lumbar glands were much enlarged; their substance was soft and of a reddish-brown colour (hyperplasia and congestion); no tubercles were seen.

The Iliac and Rectal Glands were similar.

Suprarenal Bodies.—Pale, no tubercles seen.

Alimentary Tract.

Tongue, Pharynx, Tonsils.—Normal.

Pharyngeal, Submaxillary, and Parotideal Glands.—Normal.

Intestines and Mesenteric Glands.—Appeared normal.

Various Peripheral Glands.

Precrural, Popliteal, Gluteal, Ischiatic, Axillary, Pudic.—These glands showed no naked-eye evidence of tuberculosis.

Microscopical Examination.

(Smears from)

Lung.—A few long tubercle bacilli seen.

Liver.—A few short (?) tubercle bacilli seen.

Spleen.—No tubercle bacilli.

Kidney.—No tubercle bacilli.

Thoracic Gland.—A few long tubercle bacilli seen.

Portal Gland.—Three tubercle bacilli seen (moderately short).

CALF 1377. Virus H. 92. "D.N."

Intravenous inoculation of culture derived from the original material through Guinea-pig 2592.
Dose—10·0 milligrammes.
Date of Inoculation—February 21, 1908. [Age about 10 weeks.]
Died—March 24, 1908. [32 days after inoculation.]

Clinical Notes.

The calf was noticed to be ill, with quickened respiration and loss of appetite, within a fortnight after inoculation. The respirations continued to be frequent, and the animal became very weak and emaciated; it died on the 32nd day after injection.

Temperature.

The temperature rose to 40·1° C. on the 8th day, and reached a maximum of 41·8° C. on the 12th day. It continued to be very high (between 40·0 and 41·0° C.) until the 27th day; the temperature then slowly fell, and the calf died five days later.

Tuberculin Test.

The calf was not tested subsequent to inoculation.

Weights.

	cwt.	qrs.	lbs.
February 21, 1908	1	0	1
March 24, 1908	0	3	3

Total loss of weight.—26 lbs.

Average rate of loss per week.—5·7 lbs.

POST-MORTEM EXAMINATION.

The carcass was emaciated.

Local Lesion.—There was a small patch of tuberculous thickening in the wall of the left jugular vein at the point of inoculation.

Cervical Glands.—A cervical gland near the lesion was enlarged but not caseous; other cervical glands were normal.

Thorax.

Heart.—On the pleural surface of the pericardium near the base of the heart there were about half a dozen reddish bodies rather larger than a millet seed and resembling haemo-lymph glands; two however had grey centres.

On the endocardium of the right auricle and right ventricle there were very numerous minute grey granules; there were fairly numerous similar granules in places on the endocardium of the left ventricle and one or two on that of the left auricle.

Lungs.—The lungs weighed 3 lbs. 15 ozs.; the anterior lobes, the right middle, and the antero-ventral portions of the caudal lobes were dark red solid and quite airless; the rest of the caudal lobes was congested and still air-containing; the airless portions were engorged with blood and the bronchi filled with mucus. No tubercles were seen from the surface, but on section numerous minute grey foci could be detected evenly distributed throughout the lung substance.

Thoracic Glands.—The bronchial and dorsal mediastinal glands were enlarged; on section they were fairly firm, deeply congested, and the cortices were beset with grey tubercles, irregular in outline and in places forming a coarse network.

Pleura.—Normal.

Abdomen.

Omentum and Peritoneum.—Normal.

Liver.—On the anterior surface there were a few flat filmy grey foci; no tubercles were seen in the depth.

Portal Glands.—The portal glands were a little enlarged and oedematous; there were no tubercles.

Spleen.—The spleen weighed 5 ozs. The capsule was wrinkled, and the fibrous trabeculæ more conspicuous than usual (from atrophy of the pulp?); no tubercles were seen.

Kidneys.—Each kidney showed in the cortex just under the capsule scattered minute grey foci; they were also seen in the depth of the cortex, and more distinctly than on the surface; a few were seen in the medulla of one kidney.

Suprarenal Bodies.—Normal.

Renal, Lumbar, Iliac, Coeliac, and Mesenteric Glands.—Normal.

Intestines.—Normal.

Tongue, Tonsils, Pharynx, Larynx, Trachea.—Normal.

All the peripheral lymphatic glands were examined and found to be normal.

Microscopical Examinations.

(Scrapings from)

Lung.—Tubercle bacilli numerous.

Liver.—Tubercle bacilli numerous.

Spleen.—A moderate number of tubercle bacilli seen.

Kidney.—Tubercle bacilli moderately numerous.

Suprarenal Body.—Tubercle bacilli, a few seen.

Axillary Gland.—A moderate number of tubercle bacilli seen.

Precrural Gland.—A moderate number of tubercle bacilli seen.

Popliteal Gland.—A moderate number of tubercle bacilli seen.

Haemo-lymph Gland from Pericardium.—A moderate number of tubercle bacilli, chiefly in clumps

---

PIG 107. Virus H. 92. "D.N."

Subcutaneous inoculation of culture derived from the original material through Guinea-pig 2592.

Dose—50·0 milligrammes.

Date of Inoculation—January 2, 1908. [Age 7½ weeks.]

Killed when well—May 14, 1908. [133 days after inoculation.]

Clinical Notes.

The pig was noticed to be blind some few weeks before it was killed. Its general health had been good during the experiment, but it had not grown well; this was probably due to the difficulty of finding its food consequent on the animal's blindness.

Tuberculin Test.

The pig was not tested subsequent to inoculation.

Weights.

	qrs.	lbs.
January 2, 1908	1	9
May 14, 1908...	2	4

Total gain of weight.—23 lbs.

POST-MORTEM EXAMINATION.

The carcass was in good condition.

Local Lesion.—The skin on the right side of the abdomen at the site of inoculation showed a small

scar; in the subcutaneous tissues under and for some distance around the scar were scattered caseous gritty tubercles, the largest about 2 mm. in diameter; there were also two softened caseous nodules the size of split peas.

Inguinal Glands.—On the right side the gland nearest the local lesion was 2 cm. in greatest diameter and was caseous and softened throughout; another contained discrete irregular caseo-calcareous nodules up to 3 mm. in diameter; the rest were normal.

The glands on the left side were normal.

Thorax.

Pleura.—Normal.

Lungs.—The lungs were fuller and somewhat firmer than normal. The surfaces were mottled with irregular greyish foci indefinite in outline and of a doubtful nature; they were in places confluent and formed small irregular greyish-red patches; similar foci were seen on section; in one of the caudal lobes there was a millet-seed greyish white tubercle.

Bronchial Glands.—The bronchial glands were not enlarged; they showed on section a few soft whitish foci.

Ventral Mediastinal Glands.—The gland on the right side was enlarged and showed more than three-quarters of its substance caseous and softened and slightly gritty from calcification.

The gland on the left side was normal.

Heart.—On the endocardium of the right auricle there were numerous small slightly raised grey granules; no foci were seen elsewhere in the heart.

Abdomen.

Omentum and Peritoneum, Spleen, Liver, and Portal Glands.—Normal.

Kidneys.—Both kidneys showed on the surface numerous irregular grey foci, the largest nearly 1 mm. in diameter; similar foci were seen on section.

Suprarenal Bodies.—The left suprarenal showed in the cortex two caseous and softened nodules, one 2· the other 3· mm. in diameter; the right was normal.

Lumbar and Iliac Glands.—Normal.

Alimentary Tract.

Tongue, Pharynx, Palate.—Normal.

Submaxillary Glands.—Normal.

Parotideal Glands.—The left showed on section scattered soft whitish foci. The right was normal.

Cervical Glands.—A cervical gland on the right side near the angle of the jaw contained a nodule of whitish pultaceous substance. Other cervical glands were normal.

Intestines and Mesenteric Glands.—Normal.

Prescapular Glands.—The left showed on section scattered soft whitish foci.

Popliteal Glands.—Normal.

Testicles.—Normal

Eyes.—The cornea of each eye was opaque and vascularized and showed near the margin an opening 2 mm. in diameter which communicated with the anterior chamber and through which some of the degenerated iris projected; on section the eye internally was hæmorrhagic and completely disorganized, but not suppurating. The posterior chamber of the eye was filled with blood-clot and detached retina. A smear made from material which projected through one of the openings and one from some juice from an anterior chamber showed a moderate number of tubercle bacilli and numerous cocci.

Microscopical Examination.

Scraping from Lung.—Tubercle bacilli sparsely scattered.

Scraping from Spleen.—No tubercle bacilli seen.

Grey Granules from Heart.—No tubercle bacilli numerous.

Grey Foci from Kidney.—No tubercle bacilli seen.

Tubercle from Suprarenal.—Tubercle bacilli numerous.

Focus from Right Parotideal Gland.—Tubercle bacilli in moderate numbers.

Fluid from Anterior Chamber of Eye.—Tubercle bacilli in moderate numbers.

Fluid from Tissue projecting through one of the Openings into the Anterior Chamber.—Tubercle bacilli in moderate numbers.

Smear from Material in Posterior Chamber of Eye.—No tubercle bacilli seen.

PIG 109. Virus H. 92. "D.N."

Subcutaneous inoculation of culture derived from the original material through Guinea-pig 2592.

Dose—50·0 milligrammes.

Date of Inoculation—January 2, 1908. [Age 7½ weeks.]

Killed when in good health—June 9, 1908. [159 days after inoculation.]

Clinical Notes.

The pig remained well during the experiment.

Weights.

	qrs.	lbs.
January 2, 1908	1	3
June 9, 1908	3	21

Total gain of weight.—2 qrs. 18 lbs.

POST-MORTEM EXAMINATION.

The carcass was fat.

Local Lesion.—The skin on the right side of the abdomen showed three small dry scabs, which when removed exposed small cavities containing caseo-pus; there were also three or four rounded prominences with normal skin over them, which on section were found to be caused by softened caseous nodules in the subcutaneous tissues.

In the fatty tissues under and for some distance around the skin lesions, there was a number of caseous nodules varying much in size, the largest about 1 cm. in diameter; some of the large ones were caseo-purulent, the others were cheesy and gritty.

Superficial Inguinal Glands.—On the right side the two nearest the local lesion were enlarged, the largest 3 cm. in greatest diameter, and were caseous and softened throughout. Another smaller gland was beset with caseous nodules up to a hemp seed;

the rest were normal. Those on the left side were normal.

Precrural Glands.—The right precrural gland contained a pea-sized cheesy caseous nodule and a hemp-seed sized nodule which readily shelled out.

The left precrural gland was normal.

Ventral Mediastinal Glands.—The one on the right side was much enlarged measuring 2·5 cm. in greatest diameter, and was composed throughout of cheesy caseous substance which readily shelled out from its capsule.

The one on the left side was normal.

Thorax.

Pleura.—Normal.

Lungs.—The lungs were crepitant; in the right caudal lobe just under the pleura there were two caseous tubercles the size of millet seeds.

Bronchial Glands.—Normal.

Heart.—Normal.

Abdomen.

Omentum and Peritoneum.—Normal.

Spleen, Liver and Portal Glands, Kidneys and Suprarenal Bodies.—Normal.

Lumbar and Iliac Glands.—Normal.

Alimentary Tract.

Tongue, Pharynx, Tonsils.—Normal.

Submaxillary Glands.—The left contained three pinhead-sized caseous tubercles. The right was normal.

Retro-pharyngeal Glands.—Normal.

Intestines and Mesenteric Glands.—Normal.

Various Lymphatic Glands.

Precrural and Popliteal, Gluteal and Ischiatic, Pudic, Axillary, Prescapular, and Cervical.—Normal.

Eyes.—The right eye was completely disorganized. The cornea was prominent and opaque but not vascularized; it showed near the margin a clean-cut opening through which protruded degenerated iris. On section through the eyeball the iris was found to be closely applied to the cornea and separated from it by a thin layer of pus; the posterior chamber of the eye was filled with yellow tenacious pus which practically completely replaced the vitreous humour; the lens was apparently destroyed.

The left eye was normal.

Microscopical Examination.

Anterior Chamber of Eye.—A few tubercle bacilli.

Posterior Chamber of Eye.—A few tubercle bacilli.

HORSE 9 [Yearling]. Virus H. 92. "D.N."

Subcutaneous inoculation of culture derived from the original material through Guinea-pig 2592.

Dose—100·0 milligrammes.

Date of Inoculation—February 21, 1908.

Killed when in good health—July 6, 1908. [136 days after inoculation.]

Clinical Notes.

A small soft fluctuating tumour quickly formed at the seat of inoculation; on the 4th day it opened and discharged its caseo-purulent contents. The lesion subsequently healed leaving a scar.

The animal remained well during the experiment.

Temperature.

On the 11th day after inoculation the temperature was 39·5° C. With this exception the temperature was normal during the experiment.

Tuberculin Test.

May 20, 1908. [89 days after inoculation.] Reacted. Rise of temperature, 2·4° C.

Weights.

	cwt.	qrs.	lbs.
February 21, 1908	1	3	25
July 6, 1908	2	1	2

Total gain of weight.—1 qr. 5 lbs.

POST-MORTEM EXAMINATION.

The carcass was in good condition.

Local Lesion.—At the seat of inoculation on the left side of the neck there was a linear scar; on section there was no sign of caseation in the scar or in the subcutaneous tissue around.

Left Prescapular Glands.—The left prescapular glands were not enlarged; two contained each one small brownish fibroid patch with a few calcareous grains.

Right Prescapular, Prepectoral, and Axillary Glands.—Normal.

Thorax.

Lungs.—Under the pleura of the left caudal lobe there was a grey nodule about 2 mm. in diameter with an opaque gritty focus in the centre; otherwise the lungs were normal.

Bronchial Glands.—One contained a calcareous tubercle rather less than a pin's head in size; the other was normal.

Pleura and Heart.—Normal.

Abdomen.

Omentum and Peritoneum.—Normal.

Spleen, Liver, Kidneys, and Suprarenal Bodies.—Normal.

Portal, Splenic, Renal, Lumbar, and Iliac Glands.—Normal.

Alimentary Tract.

Tongue, Pharynx, Palate, Tonsils.—Normal.

Submaxillary and Pharyngeal Glands.—Normal.

Intestines.—Normal.

Mesenteric Glands.—Normal.

Ileo-Colic Glands.—One ileo-colic gland contained a millet-seed sized dry yellow focus and a few whitish foci.

Various Lymphatic Glands.

Precrural, Popliteal, Gluteal, Ischiatic, Pudic.—Normal.

Testes.—Normal.

Microscopical Examination.

Smear from Splenic Gland.—No tubercle bacilli.

Calcareous Tubercle from Bronchial Gland.—No tubercle bacilli.

Focus from Ileo-Colic Gland.—No tubercle bacilli.

Nodule from Lung.—No tubercle bacilli.

Animal Inoculated.

Guinea-pig 3143 was inoculated intraperitoneally with an emulsion made from the spleen. It was killed 81 days later and found to be healthy.

HORSE 7 [Yearling]. Virus H. 92. "D.N."

Intravenous inoculation of culture derived from the original material through Guinea-pig 2592.

Dose—10·0 milligrammes.

Date of Inoculation—February 21, 1908.

Killed when in good health—July 7, 1908. [137 days after inoculation.]

Clinical Notes.

The animal remained well during the experiment.

Temperature.

On the 7th day after inoculation the temperature rose to 39·1° C. and remained slightly raised for five weeks; the maximum during this period was 39·9° C. Subsequently the temperature remained approximately normal.

Tuberculin Test.

May 20, 1908. [89 days after inoculation.] Reacted. Rise of temperature, 2·1° C.

Weights.

	cwt.	qrs.	lbs.
February 21, 1908	2	1	4
July 7, 1908	2	2	20

Total gain of weight.—1 qr. 16 lbs.

POST-MORTEM EXAMINATION.

The carcass was in good condition.

Local Lesion.—The skin on the left side over the jugular vein showed a small scar; in the subcutaneous tissues beneath this there was a hemp-seed sized nodule with fibrous wall and caseo-purulent contents.

Left Jugular Vein.—At the point of entry of the injection needle on the outside of the vessel wall there was a hemp-seed sized fibrous nodule.

Prescapular and Cervical Glands.—Normal.

Thorax.

Lungs.—The lungs were pink crepitant and collapsed normally. The posterior third of each caudal lobe was rather closely beset with translucent grey tubercles, the largest 1 mm. in diameter, which stood up from the cut surface and could be distinctly felt; further forwards they quickly became less numerous, and in the anterior portions were very sparsely scattered.

Bronchial Glands.—The bronchial glands were not enlarged; each contained one or two small calcareous tubercles or foci.

Heart.—Normal.

Pleura.—Normal.

Abdomen.

Omentum and Peritoneum.—Normal.

Liver.—Under the capsule there was a grey translucent tubercle about 1 mm. in diameter; otherwise the liver was normal.

Spleen, Kidneys, and Suprarenal Bodies.—Normal.

Portal, Renal, Lumbar, and Iliac Glands.—Normal.

Alimentary Tract.

Tongue, Pharynx, Tonsils.—Normal.

Submaxillary and Pharyngeal Glands.—Normal.

Intestines and Mesenteric Glands.—Normal.

Testes.—Normal.

Various Lymphatic Glands.

Precrural, Popliteal, Axillary, Gluteal, Ischiatic.—Normal.

Animal Inoculated.

Guinea-pig 3144 was inoculated intraperitoneally with an emulsion made from the spleen. It was killed after 80 days and showed chronic general tuberculosis.

RHESUS MONKEY 177. Virus H. 92. "D.N."

(A young animal.)

Subcutaneous inoculation of culture derived from the original material through Guinea-pig 2593.

Dose—1·0 milligramme.

Date of Inoculation—May 27, 1908.

Died—July 5, 1908. [39 days after inoculation.]

Clinical Notes.

The monkey was noticed to be ill about a week before death; it rapidly became worse, losing appetite and weight, and was found dead on the morning of July 5.

Weight.

At death—1500 grammes.

POST-MORTEM EXAMINATION.

The carcass was emaciated.

Local Lesion.—On the left side, just behind the posterior angle of the scapula, there was an ulcerated area measuring 4 by 3 cm. with a dry hæmorrhagic floor and inverted undermined margins; beneath the undermined skin around the ulcer there was some caseo-pus, and the muscles for a short distance beyond were beset with caseous tubercles.

Axillary Glands.—On the left side there was a large caseous and softened gland 2 cm. in diameter; there were also three firm caseous glands, the largest 1 cm. in diameter, and a smaller gland beset with discrete caseous tubercles. On the right side one 1 cm. in diameter was caseous and softened practically throughout; two other small glands contained each a few miliary caseous tubercles.

Cervical Glands.—One behind the right clavicle contained a millet-seed sized caseous tubercle; behind the left clavicle there were four tuberculous glands, one the size of a pea was caseous and softened throughout, the others contained discrete caseous tubercles. Other cervical glands were normal.

Inguinal Glands.—The inguinal glands on each side were enlarged and beset with firm yellowish-white caseous nodules up to 2 mm. in diameter.

Vertebral Glands.—On the left side in the 8th to 11th interspaces there was a chain of four enlarged

caseous and softened glands, the largest 8 mm. in diameter.

Thorax.

Pleura.—Normal.

Lungs.—The lungs were crepitant and collapsed normally; the left caudal lobe was adherent to the enlarged vertebral glands; the parenchyma of the lungs contained moderately numerous evenly distributed shotty caseous nodules with narrow grey margins, varying in size from a pin's head to a hemp seed.

Bronchial Glands.—The bronchial glands were congested and slightly enlarged, and contained yellow softened caseous nodules.

Heart.—There was one caseous tubercle in the muscle of the right ventricle the size of a millet seed; otherwise the heart was normal.

Abdomen.

Omentum and Peritoneum.—The omentum showed numerous tubercles, the majority minute and grey; the rest, situated near the curvature of the stomach and the spleen, larger and caseous in the centre.

On the peritoneal surface of the diaphragm on the right side there was a number of flattened miliary caseous tubercles.

The parietal peritoneum was normal.

Spleen.—The spleen was enlarged measuring 5·5 by 3 by 1·5 cm. and showed on the surface under the capsule numerous yellowish-white tubercles ranging from 1 to rather more than 2 mm. in diameter. On section the pulp was extensively replaced by yellow caseous nodules, the majority beginning to break down in the centre, ranging up to 3 mm. in diameter.

The splenic lymphatic glands contained small caseous tubercles.

Liver.—The liver was closely beset with tubercles mainly of two sizes, one minute greyish-white, the other yellow caseous and ranging up to 2·5 mm. in diameter.

The glands on the pancreas near the hilum of the liver were enlarged and their cortices closely beset with caseous softening nodules up to 2·5 mm. in diameter.

Kidneys.—Each kidney showed in the cortex on the surface as well as on section numerous minute greyish-white tubercles, the largest about 0·5 mm. in diameter, and a few larger yellow caseous tubercles ranging up to a millet seed in size.

Suprarenal Bodies.—The left suprarenal body contained a miliary caseous tubercle and a few minute greyish-white tubercles.

The right contained a few minute greyish-white foci.

Lumbar and Iliac Glands.—The lumbar and iliac glands were enlarged and contained each a number of yellow caseous nodules up to 3 mm. in diameter.

Alimentary Tract.

Under the mucous membrane at the base of the tongue there were two yellow caseous tubercles.

Tonsils, Larynx, and Trachea.—Normal.

Submaxillary and Submental Glands.—These glands were slightly enlarged and contained yellow caseous nodules.

Pharyngeal Glands.—Each pharyngeal gland contained a nodule or two.

Intestines.—There were three or four caseous tubercles on the serous surface of the small intestine, and one in the submucous tissues.

The large intestine was normal.

Mesenteric Glands.—The mesenteric glands were congested, and some were slightly enlarged; the larger ones showed their cortices beset with caseous and in places confluent tubercles; the other glands contained small discrete caseous tubercles.

Ileo-Colic and Colic Glands.—The ileo-colic and the majority of the colic glands, though not enlarged, contained each one or two caseous tubercles.

The skin of the abdomen and thighs showed several hæmorrhagic spots, the centres of which were necrosed.

In the subcutaneous tissues near the pubis there was a millet-seed sized caseous tubercle; under the scalp there was a similar tubercle.

In the centre of the suture between the parietal bones there was a small focus of caseo-necrosis.

Microscopical Examination.

Hæmorrhagic Spot with Necrosed Centre.—T.B. numerous.

VIRUS H. 99. "L.K."

LUPUS.

VIRUS H. 99. "L.K."

CULTURE INOCULATIONS.

April 3, 1908.

The strain was derived from the original material through Guinea-pig 2927, and had been in artificial cultivation a total period of 28 days.

The culture used was the 5th generation, 7 days old.

CALF 1401.

Subcutaneous.

Dose : 50·0 mg.

Killed : August 1, 1908.

120 days.

P.M. — Small fibro-calcareous local tumour ; in the left prescapular gland there was a patch of fibroid tissue containing caseous gritty areas. The mesenteric and colic glands contained scattered calcareous foci.

MONKEY 147.

Subcutaneous.

Dose : 1·0 mg.

Died : May 7, 1908.

34 days.

P.M. —Acute general tuberculosis.

MONKEY 149.

Subcutaneous.

Dose : 0·1 mg.

Died : May 23, 1908.

50 days.

P.M.—General tuberculosis.

MONKEY 151.

Subcutaneous.

Dose : 0·01 mg.

Died : May 9, 1908.

36 days.

P.M.—Acute general tuberculosis.

RABBITS.

Number.	Method.	Dose.	Duration of Life.	Result.
1811	Intrav.	1·0 mg.	D. 21 days	G. T.
1812	Intrav.	0·1 mg.	D. 143 „	G. T., not obviously progressive.
1813	Intrav.	0·01 mg.	D. 1 day	Psorospermosis.
1814	Subcut.	50·0 mg.	D. 89 days	G. T.
1815	Subcut.	35·0 mg.	K. 144 „	Local lesion and slight T. of lungs.

GUINEA-PIGS.

Number.	Method.	Dose.	Duration of Life.	Result.
3023	Intrap.	1·0 mg.	D. 16 days	G. T.
3024	Subcut.	1·0 mg.	D. 27 „	Early G. T.

A parrot was cutaneously inoculated on October 16, 1908, with culture derived from the original material through Guinea-pig 2928. The culture used was the 7th generation, 20 days old.

PARROT 13.

Scarified at root of beak with knife dipped in turbid suspension of culture.

Died : June 23, 1909. 250 days

P.M.—General miliary tuberculosis. (There was no local lesion.)

CALF 1401. Virus H. 99. "L.K."

Subcutaneous inoculation of culture derived from the original material through Guinea-pig 2927.

Dose—50·0 milligrammes.

Date of Inoculation—April 3, 1908. [Age about 9 weeks.]

Killed when in good health—August 1, 1908. [120 days after inoculation.]

Clinical Notes.

The calf remained well during the experiment.

Temperature.

For a period of seventeen days following the inoculation the temperature was irregular (maximum 39·6° C., minimum 37·5° C.). After this it remained perfectly normal.

Weights.

	cwt.	qrs.	lbs.
April 3, 1908	0	3	23
August 1, 1908	1	2	15

Total gain of weight.—2 qrs. 20 lbs.

Average rate of gain per week.—4·4 lbs.

POST-MORTEM EXAMINATION.

The carcass was in good condition.

Local Lesion.—At the seat of inoculation on the left side of the neck there was a slightly raised patch of thickening measuring 8 by 5 cm. showing on the surface a depressed scar; on section the tumour was composed of thickened skin and a layer of translucent fibroid tissue 1 cm. in greatest thickness containing calcareous foci.

Left Prescapular Gland.—The left prescapular gland measured 5 by 2·5 by 1·5 cm. and showed in the cortex a tuberculous patch 2 cm. in length and about 0·7 cm. in greatest thickness composed of brownish fibroid tissue containing small softened caseous gritty areas.

Prepectoral Glands.—One on the left side was a little more than 1 cm. in diameter, and was fibro-caseo-calcareous throughout; the capsule was much thickened.

Right Prescapular Gland.—The right prescapular gland measured 4·5 by 2 by 1 cm. and was normal on section.

Cervical and Axillary Glands.—Normal.

Thorax.

Pleura, Lungs, Thoracic Glands, Heart.—Normal.

Abdomen.

Omentum and Peritoneum, Spleen, Liver, and Portal Glands, Kidneys, and Suprarenal Bodies.—Normal.

Renal, Lumbar, and Iliac Glands.—Normal.

Alimentary Tract.

Tongue, Pharynx, Tonsils.—Normal.

Submaxillary, Retro-pharyngeal and Parotideal Glands.—Normal.

Intestines.—Normal.

Mesenteric Glands.—Many of the mesenteric glands contained sparsely scattered yellow calcareous foci; the rest were normal.

Ileo-Colic Glands.—One gland showed in the cortex rather numerous irregular calcareous tubercles; some of the others contained a few calcareous grains; the rest were normal.

Various Lymphatic Glands.

Precrural, Popliteal, Gluteal, Ischiatic, Pudic.—Normal.

RHESUS MONKEY 147. Virus H. 99. "L.K."

(A young animal.)

Subcutaneous inoculation of culture derived from the original material through Guinea-pig 2927.

Dose—1·0 milligramme.

Date of Inoculation—April 3, 1908.

Died—May 7, 1908. [34 days after inoculation.]

Clinical Notes.

About three weeks after inoculation the monkey was noticed to be quiet and depressed, and it had no appetite. Loss of appetite continued, the animal became weak and emaciated and the respiration accelerated, and death supervened at the close of the fifth week after inoculation.

Weight.

At death—2350 grammes.

POST-MORTEM EXAMINATION.

The carcass was emaciated.

Local Lesion.—In the subcutaneous tissues of the back there was a flat swelling measuring 8 by 6·5 cm. by about 1 cm. in greatest thickness. The skin over it showed an opening 5 mm. in diameter with thin undermined congested margins discharging caseo-pus.

On section the tumour showed a cavity or flat space in the centre containing blood-stained pultaceous caseo-pus and caseous shreds; this space was surrounded by a layer of firmer caseous substance 4 mm. in greatest thickness, which was adherent to the skin on the one hand and the muscles on the other.

The muscles were infiltrated and beset with small caseous nodules.

Axillary Glands.—In the right axilla there was one gland the size of a broad bean which was caseous and softened throughout, another smaller one contained a pea-sized caseous nodule and a miliary caseous tubercle. In a third gland there were three or four caseous tubercles.

On the left side one gland the size of a pea was caseous and softened practically throughout. Two others each contained a miliary caseous tubercle.

Cervical Glands.—The cervical glands on each side were slightly enlarged, deeply congested, but showed no sign of caseation.

Vertebral Glands.—On the right side in the ninth and 10th interspaces there were two large prominent fluctuating glands filled with creamy pus. In the 7th and 8th there were two small caseous glands.

On the left side opposite the 7th interspace there were two prominent caseous and softened glands each a centimetre in diameter, one situated on the bodies of the vertebræ, the other over the heads of the ribs. Three of the glands posterior to this, not so large, were caseous throughout.

Thorax.

Pleura.—Normal.

Lungs.—The lungs were crepitant and collapsed normally; they contained fairly numerous shotty caseous tubercles with grey margins ranging in diameter from 1 to 2 mm.

Bronchial Glands.—The bronchial glands, prae- and intertracheal, were slightly enlarged congested and beset with discrete caseous nodules up to 2 mm.

Heart and Pericardium.—There was an excess of fluid in the pericardial sac. The surface of the heart was mottled with hæmorrhages. The heart muscles and valves were normal.

Larynx and Trachea.—Normal.

Abdomen.

The peritoneal cavity contained from 30 to 40 cc. of clear yellow serous fluid.

Omentum and Peritoneum.—The omentum contained three miliary caseous tubercles and several minute greyish-white tubercles.

The parietal peritoneum was normal.

Spleen.—The spleen was enlarged, and measured 5·5 by 2·8 by 1·3 cm. The pulp was moderately closely beset with caseous tubercles ranging from 0·5 to 3 mm. in diameter, the larger ones being yellow and softened.

Splenic Lymphatic Glands.—The splenic glands contained a few miliary caseous tubercles.

Liver.—The liver was enlarged and very closely beset with opaque whitish caseous tubercles, ranging in size from a mere point to about 1·5 mm. in diameter.

Portal and Pancreatic Glands.—The portal gland and the glands around the head of the pancreas were enlarged and closely beset with yellow caseous and softened nodules.

Kidneys.—In the cortex of the left kidney just under the capsule there was a minute greyish-white tubercle and in the depth two miliary caseous tubercles.

On the surface of the right kidney there were four yellowish-white caseous tubercles rather less than a millimetre in diameter; none was seen in the depth.

Suprarenal Bodies.—Normal.

Lumbar Glands.—Each of the lumbar glands contained a caseous tubercle.

Iliac Glands.—Normal.

Alimentary Tract.

Tongue, Tonsils, Pharynx.—Normal.

Pharyngeal Glands.—The pharyngeal gland on the right side contained two softened caseous tubercles. That on the left side was normal.

Submaxillary Glands.—The right submaxillary gland contained a miliary caseous tubercle, the left three or four caseous tubercles.

Intestines.—There were three submucous caseous tubercles in the small intestine and about half a dozen hemp-seed sized caseous nodules in the large intestine, the majority firm and not ulcerated a few softened and ulcerated (the smear was made from one of the latter).

Mesenteric Glands.—There were two caseous tubercles in the mesenteric glands, the largest the size of a millet seed.

Ileo-Colic Glands.—Normal.

Colic Glands.—Four colic glands on the descending colon each contained a caseous tubercle.

Various Lymphatic Glands.

Popliteal.—Each popliteal gland contained a miliary caseous tubercle.

Inguinal.—There was a caseous tubercle in one of the glands on the right side and there were three in those of the left.

Microscopical Examination.

Tubercle from the Liver.—Tubercle bacilli numerous.

Nodule from the Colon.—Exceedingly numerous tubercle bacilli—resembled a pure culture.

RHESUS MONKEY 149. Virus H. 99. "L.K."

(A young animal.)

Subcutaneous inoculation of culture derived from the original material through Guinea-pig 2927.

Dose—0·1 milligramme.

Date of Inoculation—April 3, 1908.

Died—May 23, 1908. [50 days after inoculation.]

POST-MORTEM EXAMINATION.

The carcass was emaciated.

Local Lesion.—The skin of the back just behind the right scapula showed a large ulcer 4·5 by 2·5 cm. in area, with irregular inverted undermined margins and pale granular floor showing some hæmorrhagic discharge.

Under the skin surrounding the ulcer for a distance of in places 1 cm. there was a zone of breaking-down caseous substance.

Axillary Glands.—In the right axilla there was a large mass 2 cm. in diameter composed throughout of softened caseous substance, and four smaller glands, which were wholly or almost completely caseous.

The glands in the left axilla were normal.

Cervical Glands.—Behind the right clavicle there was a pea-sized gland caseous and softened throughout; there was a similar gland in a similar situation on the left side. A left upper cervical gland the size of a small pea was caseous and softened throughout. Other cervical glands were normal. Other glands in the neck were normal.

Submental Gland.—A submental gland the size of a small pea was caseous and softened throughout.

Vertebral Glands.—The vertebral glands on the right side in the 7th to the 10th interspaces were greatly enlarged, fused together, and converted into thin-walled cysts filled with creamy yellow caseo-pus.

Other vertebral glands were normal.

Inguinal Glands.—Normal.

Thorax.

Heart, Pericardium and Pleura.—Normal.

Lungs.—The lungs collapsed normally. The right caudal lobe was adherent to the enlarged vertebral glands. In the parenchyma there was a moderate number of evenly distributed shotty caseous tubercles with narrow grey margins ranging from 1 to 2 mm. in diameter.

Thoracic Glands.—The praetracheo-bronchial glands were normal. Two of the intertracheo-bronchial glands contained each a caseo-purulent nodule, the largest 5 mm. in diameter.

Abdomen.

Omentum.—The omentum contained scattered caseous tubercles ranging up to 2 mm. in diameter.

Peritoneum.—Normal.

Spleen.—The spleen measured 4·5 by 2·5 by 1·3 cm., and was beset though not closely with softened caseous nodules, varying in size up to 5 mm. in diameter.

Splenic Lymphatic Glands.—Normal.

Pancreatic Glands.—Two glands on the anterior border of the pancreas were enlarged and beset closely with caseo-purulent nodules, the largest the size of a pea.

Liver.—The liver was normal in size and colour. It showed under the capsule embedded in the substance eighteen softened caseous nodules varying in size from 1 to 5 mm. Five small caseous nodules were seen on section.

A small gland on the neck of the gall-bladder was normal.

Kidneys.—The kidneys were pale, the capsules adherent; the cortex of the right contained one pinhead-sized caseous tubercle. In that of the left there were half-a-dozen caseous tubercles ranging from 0·5 to 1 mm. in diameter.

Suprarenal Bodies.—Normal.

Lumbar and Iliac Glands.—Normal.

Alimentary Tract.

Tongue, Pharynx, Tonsils.—Normal.

Retro-pharyngeal Glands.—Normal.

Intestines.—Normal.

Mesenteric, Ileo-Colic and Colic Glands.—Normal.

Larynx and Trachea.—Normal.

RHESUS MONKEY 151. Virus H. 99. "L.K."

(A young animal.)

Subcutaneous inoculation of culture derived from the original material through Guinea-pig 2927.

Dose—0·01 milligramme.

Date of Inoculation—April 3, 1908.

Died—May 9, 1908. [36 days after inoculation.]

Clinical Notes.

The course of the disease in this monkey was similar to that of its fellow, No. 147.

Weight.

At death—1920 grammes.

POST-MORTEM EXAMINATION.

The carcass was emaciated.

Local Lesion.—The skin of the back just posterior to the angle of the right scapula showed a circular ulcer 2·5 mm. in diameter with considerably undermined margins. The exposed floor was congested slightly granular and showed here and there thin caseous patches.

Under the undermined skin surrounding the ulcer there was a zone of yellow caseous substance 5 mm. in greatest thickness and 1·5 mm. in greatest breadth, adherent to and infiltrating the muscles.

Axillary Glands.—On the right side one the size of a kidney bean, and two the size of small peas were adherent to each other and caseous practically throughout, the larger one beginning to break down. Another gland contained a caseous nodule 2 mm. in diameter.

Two small glands on the left side showed small caseous patches around the cortex. Another contained a millet-seed sized caseous tubercle.

Cervical Glands.—Behind the right clavicle there were two glands, one the size of a large pea was caseous practically throughout, the other that of a hemp seed was partly caseous. One gland in the corresponding position on the left side contained a caseous tubercle 1·5 mm. in diameter.

Vertebral Glands.—On the right side extending from the 7th to the 11th interspace there was a chain of four enlarged glands varying in size up to nearly a centimetre, all of which were caseous throughout and softened.

Thorax.

There was a slight excess of fluid in the pleural cavities.

Pleura.—Normal.

Diaphragm.—In the muscle of the diaphragm on the left side there was a millet-seed sized caseous tubercle.

Lungs.—The lungs were crepitant and slightly adherent to the enlarged vertebral glands on the right side. They contained scattered evenly distributed shotty caseous tubercles varying from 1 to a little more than 2 mm. in diameter.

Bronchial Glands.—The bronchial glands were moderately enlarged and their substance closely beset with yellow caseous nodules up to 2 mm. in diameter.

Heart and Pericardium.—The pericardial sac was filled with clear serous fluid.

The heart muscle and valves were normal.

Larynx and Trachea.—Normal.

Abdomen.

The peritoneal cavity contained 70 cc. of clear yellow fluid.

Omentum and Peritoneum.—The omentum showed a moderate number of small tubercles, some caseous. There were two miliary caseous tubercles on the mesocolon.

The parietal peritoneum was normal.

Spleen.—The spleen was enlarged, measuring 6 by 2·8 by 1·4 cm., and was very closely beset with yellow

caseous nodules ranging from 1 up to 3 mm. in diameter, the larger ones beginning to break down in the centre.

Splenic Lymphatic Glands.—The splenic glands were slightly enlarged and contained each a few discrete caseous tubercles.

Liver.—The liver was enlarged and closely and evenly beset with caseous tubercles mainly of two sizes, the larger ones ranging from 1 to 2 mm. in diameter, creamy white and homogeneous throughout, the smaller ones more numerous than the former, very minute some being just visible and greyish white.

Portal Glands.—Two large glands near the hilum of the liver, between it and the head of the pancreas, were yellow and caseous practically throughout.

Kidneys.—In the depth of the cortex of the left kidney there were two pinhead-sized yellow caseous tubercles. On the surface of the right there were two yellow caseous tubercles, the largest 1·5 mm. in diameter, and a somewhat elongated tubercle was seen in the depth of the cortex.

Suprarenal Bodies.—Normal.

Omental Gland.—A gland in the small omentum near the pylorus, the size of a split pea, showed the cortex almost entirely replaced by caseous patches.

Lumbar Glands.—Three of the lumbar glands each contained a yellow caseous nodule the size of a hemp seed.

Iliac Glands.—One of the left iliac glands was enlarged and partly caseous. One of the glands on the right side contained a millet-seed sized caseous tubercle.

Alimentary Tract.

Tongue, Pharynx.—Normal.

Tonsils.—Each tonsil showed a soft whitish focus.

Pharyngeal Glands.—Each pharyngeal gland contained a caseous tubercle.

Submaxillary Glands.—The left submaxillary gland contained a caseous tubercle. The right was normal.

Intestines.—The mucous membrane of the small intestine was speckled with petechial hæmorrhages; there were no tubercles.

The large intestine was normal.

Mesenteric Glands.—The mesenteric glands were not enlarged, they showed a few miliary caseous tubercles and early caseous patches in the cortex.

Ileo-Colic and Colic Glands.—Normal.

Inguinal Glands.—There was a small caseous tubercle in each of two of the glands on the right side. The left were normal.

Microscopical Examination.

Whitish Focus from Right Tonsil.—Tubercle bacilli numerous.

Whitish Focus from Left Tonsil.—Tubercle bacilli numerous.

VIRUS H. 100. "R.S."

LUPUS.

VIRUS H. 100. "R.S."

LUPUS.

CULTURE INOCULATIONS, AND PASSAGE EXPERIMENTS. I.

The strain was derived from the original material through G.P. 2929, and was inoculated on May 19, 1908, when it had been in artificial cultivation a total period of 69 days.

The culture used was the 8th generation, 14 days old.

CALF 1419.
Subcutaneous.
Dose : 50·0 mg.
Killed : September 18, 1908.
122 days.
P.M.—Chronic progressive general tuberculosis.

MONKEY 163.
Subcutaneous.
Dose : 1·0 mg.
Died : August 13, 1908.
86 days.
P.M. — General tuberculosis, not severe.

CULTURE.

The strain was derived from the lung of Calf 1419 and was inoculated on December 3, 1908, after 76 days artificial cultivation. The 7th generation of culture was used when 9 days old.

CALF 1511.
Subcutaneous.
Dose : 50·0 mg.
Died : Jan. 26, 1909.
39 days.
P.M. — General tuberculosis.

CALF 1517.
Subcutaneous.
Dose : 50·0 mg.
Died : Dec. 25, 1908.
22 days.
P.M.—Acute tuberculosis.

RABBITS.

Number.	Method.	Dose.	Duration of Life.	Result.
2072	Intrav.	1·0 mg.	D. 14 days	Acute T.
2073	Intrav.	0·1 mg.	D. 18 „	Acute miliary T.
2074	Intrav.	0·01 mg.	D. 26 „	G. T.
2075	Subcut.	10·0 mg.	D. 58 „	G. T.
2076	Subcut.	2·7 mg.	D. 52 „	G. T.

GUINEA-PIGS.

Number.	Method.	Dose.	Duration of Life.	Result.
3388	Intrap.	0·1 mg.	D. 16 days	Acute T.
3386	Subcut.	1·0 mg.	D. 39 „	G. T.
3387	Subcut.	0·1 mg.	D. 39 „	G. T.

† A culture was raised from the kidney of Rabbit 1869. On June 18, 1909, the third generation, 15 days old, was inoculated into :—

RABBITS.

Number.	Method.	Dose.	Duration of Life.	Result.
2373	Subcut.	10·0 mg.	D. 36 days	G. T.
2372	Subcut.	5·0 mg.	D. 84 „	G. T.

RABBITS.

Number.	Method.	Dose.	Duration of Life.	Result.
1866	Intrav.	1·0 mg.	D. 22 days	G. T.
1867	Intrav.	0·1 mg	D. 17 „	Acute T.
1868	Intrav.	0·01 mg.	D 174 „	G. T.
1869†	Subcut.	10·0 mg.	D. 337 „	G. T.
1870	Subcut.	10·0 mg.	D. 163 „	G. T.

GUINEA-PIGS.

Number.	Method.	Dose.	Duration of Life.	Result.
3048	Intrap.	1 0 mg.	D. 30 days	General miliary T.
3050	Intrap.	0·1 mg.	D. 43 „	G. T.
3049	Subcut.	1·0 mg.	D. 284 „	G. T.
3051	Subcut.	0·1 mg.	D 192 „	G. T.

CULTURE.

The strain was derived from the liver of Calf 1419 and was inoculated on December 18, 1908, after 91 days artificial cultivation. The 8th generation of culture was used when 15 days old.

RABBITS.

Number.	Method.	Dose.	Duration of Life.	Result.
2092	Intrav.	1·0 mg.	D. 13 days	Acute T.
2093	Intrav.	0·1 mg.	D. 19 „	General miliary T.
2094	Intrav.	0·01 mg.	D. 32 „	G. T.
2095	Subcut.	10·0 mg.	D. 45 „	G. T.
2096	Subcut.	10·0 mg.	D. 43 „	G. T.

GUINEA-PIGS.

Number.	Method.	Dose.	Duration of Life.	Result.
3397	Intrap.	0·1 mg.	D. 14 days	Acute T.
3398	Subcut.	0·1 mg.	D. 39 „	Severe G. T.

The strain was inoculated into two monkeys and a rabbit on March 26, 1909. The 13th generation of culture, 11 days old, was used. Duration of artificial cultivation: 189 days.

RHESUS MONKEY 281.

Subcutaneous.

Dose: 1·0 mg.

Died: April 17, 1909.

22 days.

P.M.—Early general tuberculosis. The cause of death was not apparent.

RHESUS MONKEY 283.

Subcutaneous.

Dose: 1·0 mg.

Died: April 29, 1909.

34 days.

P.M.—General tuberculosis, severe.

RABBIT 2225.

Subcutaneous.

Dose: 10·0 mg.

Died in 59 days.

P.M.—General tuberculosis.

VIRUS H. 100. "R.S."—*continued.*

CULTURE INOCULATIONS, AND PASSAGE EXPERIMENTS. II.

The strain was derived from the original material through G.P. 2931, and was inoculated on August 24, 1908, when it had been in artificial cultivation a total period of 148 days.

The culture used was the 8th generation, 11 days old.

CALF 1409.
Subcutaneous.
Dose : 100·0 mg.
Killed : December 21, 1908.
119 days.

P.M. — Collapsed cyst at seat of inoculation. Left prescapular gland contained caseo-calcareous tracts and discrete nodules and tubercles. In the lungs there were moderately numerous irregular homogeneous and translucent nodules (up to 4 mm.). Two thoracic glands contained each a few calcareous foci and small caseo-calcareous nodules. There was a single caseous or caseo-calcareous tubercle in each of three abdominal glands.

CULTURE

Derived from the mediastinal gland of Calf 1409. The 5th generation, 11 days old, was used for inoculation on February 17, 1909.

CALF 1543.
Subcutaneous.
Dose : 50·0 mg.
Killed when dying : March 23, 1909.
34 days.
P.M.—General miliary tuberculosis.

RABBITS.

Number.	Method.	Dose.	Duration of Life.	Result.
2176	Subcut.	10·0 mg.	D. 51 days	G. T.
2177	Subcut.	10·0 mg.	D. 73 „	G. T.

RHESUS MONKEY 207.
Subcutaneous.
Dose : 1·0 mg.
Died : September 19, 1908.
26 days.

P.M.—Caseo-purulent local tumour. One axillary, one cervical, and three vertebral glands were caseous and softened. The spleen and one bronchial gland contained each a caseous tubercle. Death was due to cold.

RABBITS.

Number.	Method.	Dose.	Duration of Life.	Result.
1974	Intrav.	1·0 mg.	D. 21 days	General miliary T.
1975	Intrav.	0·1 mg.	D. 40 „	G. T.
1976	Intrav.	0·01 mg.	D. 78 „	G. T.
1977	Subcut.	10·0 mg.	D. 91 „	G. T.

FOWLS.

Number.	Method.	Dose.	Duration of Life.	Result.
121	Intrav.	10·0 mg.	K. 2 days (accident).	Healthy.
119	Intrav.	1·0 mg.	K. 171 days	Scattered tubercles in the lung, one in the liver.

VIRUS H. 100. "R.S."—*continued.*

CULTURE INOCULATIONS—*continued.*

III.—December 21, 1908.

The strain was derived from the original material through Guinea-pig 2931, and had been 267 days in artificial cultivation.

The culture used was the 17th generation, 10 days old.

RHESUS MONKEY 255.
Subcutaneous.
Dose : 1·0 mg.
Died : February 7, 1909.
48 days.
P.M. — Slight disseminated tuberculosis ; the cause of death was not apparent.

RHESUS MONKEY 257.
Subcutaneous.
Dose : 1·0 mg.
Killed : January 15, 1909.
(On account of gangrenous condition of upper lip and gum).
25 days.
P.M.—Local lesion only.

RHESUS MONKEY 261.
Fed.
Dose : 10·0 mg.
Died : March 10, 1909.
79 days.
P.M.—Severe tuberculosis of mesenteric glands, slight tuberculosis of the other glands in the alimentary tract and of the intestines, the lungs, spleen, and liver. Death was hastened by non-tuberculous ulceration of the large intestine.

IV.—January 25, 1909.

The strain was derived from the original material through Guinea-pig 2929, and had been 320 days in artificial cultivation.

The culture used was the 18th generation, 18 days old.

CALF 1547.
Subcutaneous.
Dose : 100·0 mg.
Killed : April 30, 1909.
95 days.
P.M. — Generalised tuberculosis, not severe and not obviously progressive.

CALF 1523.
Subcutaneous.
Dose : 50·0 mg.
Killed when dying : April 8, 1909.
73 days.
P.M.—General tuberculosis.

CULTURE.
Derived from the left bronchial gland of Calf 1523.
The 4th generation of culture, 15 days old, was used for inoculation on June 18, 1909.

RABBITS.

Number.	Method.	Dose.	Duration of Life.	Result.
2370	Subcut.	10·0 mg.	D. 60 days	G.T.
2371	Subcut.	10·0 mg.	D. 83 „	G.T.

RABBITS.

Number.	Method.	Dose.	Duration of Life.	Result.
2127	Subcut.	10·0 mg.	D. 133 days	G.T.
2128	Subcut.	10·0 mg.	D. 145 „	G.T.

VIRUS H. 100. "R.S."—*continued.*

CULTURE INOCULATIONS—*continued.*

FEEDING EXPERIMENT.

SEPTEMBER 19–OCTOBER 1, 1908.

The strain was derived from the original material through Guinea-pig 2931, and had been in artificial cultivation a total period of 174–186 days.

The cultures used were of the 10th and 11th generations, 4 to 9 days old.

PIG 133.

Fed every other day for a fortnight, 7 times in all.

Dose: The growth from one serum culture on each occasion.

Killed: January 11, 1909.

114 days.

P.M.—Slight disseminated tuberculosis. The submaxillary, mesenteric, and ileo-colic glands were all occupied to a greater or less extent by caseo-calcareous tissue. The liver contained scattered grey tubercles with minute calcareous centres, the lungs seven. The portal, coeliac, and one colic glands contained one or more caseo-calcareous tubercles. The intestines and other organs were normal.

PIG 135.

Fed every other day for a fortnight, 7 times in all.

Dose: The growth from one serum culture on each occasion.

Killed: February 12, 1909.

146 days.

P.M.—The submaxillary and most of the mesenteric glands contained caseous gritty nodules which shelled out of normal-looking gland tissue; a few small tubercles were seen in three ileo-colic and colic glands; there was a minute calcareous focus in the liver; other organs and glands were normal.

CALF 1419. Virus H. 100. "R.S."

Subcutaneous inoculation of culture derived from the original material through Guinea-pig 2929.

Dose—50·0 milligrammes.

Date of Inoculation—May 19, 1908. [Age about 9 weeks.]

Killed when in moderately good health—September 18, 1908. [122 days after inoculation.]

Clinical Notes.

The calf remained well during the experiment, but did not grow normally, and was rather thin when killed.

Temperature.

The temperature was slightly raised for nine days during the second and third weeks after inoculation, and again for seven days during the fifth and sixth weeks; the maximum temperature recorded on the first occasion was 39·7° C., and on the second 39·8° C. Otherwise the temperature was approximately normal during the experiment.

Tuberculin Test.

August 18, 1908. [91 days after inoculation.] Dose, 2·0 cc. Reacted. Rise of temperature, 1·6° C.

Weights.

	cwt.	qrs.	lbs.
May 19, 1908	0	3	17
September 18, 1908	1	0	24

Total gain of weight.—1 qr. 7 lbs.

Average rate of gain per week.—2 lbs.

POST-MORTEM EXAMINATION.

The carcass was in fair condition.

Local Lesion.—At the seat of inoculation there was a prominent tumour measuring 8·5 by 7 by 4 cm., the skin over the centre of which showed a shallow depressed area, at the bottom of which there was a small opening through which exuded caseo-pus.

On section the tumour was found to consist of two parts; one, the superficial one, was composed of thickened skin and a mass of white fibrous tissue beset with calcareous and caseo-purulent nodules of various sizes, and containing in its centre a lenticular cavity 5 cm. in greatest diameter, with caseo-purulent contents; the other was the muscle beneath, which showed an increase in interstitial connective tissue, and was beset with dense well-defined fibro-caseo-calcareous nodules, varying in size from 7 or 8 mm. up to 1·5 cm.

Left Prescapular Gland.—The left prescapular gland measured 5·5 by 3 by 2·5 cm. and was composed of irregular caseo-calcareous patches and nodules set in a scanty matrix of fibroid glandular tissue; the capsule was much thickened.

Prepectoral Glands.—On the left side the rounded gland was 1 cm. in diameter and resembled the prescapular; the kidney-shaped gland was much enlarged, measuring 3·5 cm. in greatest diameter, and showed irregular caseo-calcareous patches and discrete caseo-calcareous tubercles.

On the right side one contained a hemp-seed sized caseous nodule with a thick fibrous capsule; another contained two calcareous foci.

Right Prescapular Gland.—The right prescapular gland measured 4·5 by 2 by 1 cm. and showed in the cortex a few very minute calcareous foci.

Cervical Glands.—On the left side the upper cervical gland contained a caseo-calcareous nodule 1·5 cm. in diameter separated into smaller nodules by fibrous trabeculae, and a small caseo calcareous tubercle.

A mid-cervical gland on this side and the right superior cervical gland contained each two miliary caseo-calcareous tubercles

Thorax.

Pleura.—The costal pleura showed on the right side three loosely attached haemorrhagic nodules the size of hemp seeds, and some hypertrophy of the fringes

The pleural surface of the diaphragm showed numerous small connective tissue processes but no tubercles.

Lungs.—There were two long slender adhesions to the chest wall. The lungs were crepitant and collapsed normally; they contained a moderate number of evenly distributed hard nodules varying in size from a millet seed to that of a large pea; the larger ones were caseo-calcareous or calcareo-caseous and some were softened and had thick fibrous capsules; the medium sized ones and the majority of the small ones had calcareous or caseo-calcareous centres; a few of the smaller ones were fibrous and homogeneous throughout.

There were besides about half a dozen larger nodules, the largest rather more than 1·5 cm. in diameter; these were composed of yellow softened caseo-calcareous substance surrounded by a fibrous capsule and separated into smaller areas by fibrous trabeculae.

The fringes around the margins of the lungs were hypertrophied and showed one flattened yellow nodule of dry caseous substance.

Thoracic Glands.—The long mediastinal gland was enlarged; it contained a large very firm mass measuring 2·5 by 2 by 1 cm. composed of dense caseo-calcareous substance, and discrete calcareous foci as in the other glands. The rest of the mediastinal and the bronchial glands were little if at all enlarged and contained small irregular calcareous patches (up to 5 mm. in diameter) and foci and occasionally a softened caseous nodule.

Heart.—Normal.

Abdomen.

Omentum.—The ventral surface of the omentum was roughened with numerous small connective tissue tags; there were also half a dozen fibrous tubercles, one with a calcareous centre.

Peritoneum.—There were numerous small fibrous tags on the left side of the rumen and the left side of the diaphragm; on the right side there were a dozen raised fibrous tubercles, the largest the size of a millet seed.

Spleen.—The spleen was normal in size and contained one hemp-seed sized caseous gritty nodule with a fibrous capsule.

Liver.—The liver showed on the convex surface numerous slightly raised grey fibrous tubercles, 1 mm. in diameter. Near the thin margin on this surface there was a group of five calcareo-caseous nodules; one the size of a split pea lay in a shallow depression in the liver substance; the others, much smaller, were more superficial.

In the thin part of the left lobe there was a large hard nodular mass, 3 cm. in diameter, which projected prominently from the under surface of the liver and was adherent to the omentum. On section it was composed of very dense fibro-caseous substance, gritty from calcification, surrounded by a fibrous capsule. The capsule of the liver around the mass was studded with fibrous tubercles up to a small pea in size with caseo-calcareous centres; there were several isolated nodules in the substance of the liver around the mass.

The rest of the liver contained three nodules, the largest 1·4 cm. in diameter, similar on section to the large mass above described.

Portal Glands.—One was large, 4 cm. in diameter, and resembled the prescapular gland on section; another was beset with nodules up to 1 cm. in diameter, like those in the liver; a third showed small calcareous patches. A smaller gland contained two calcareous tubercles; the rest were normal.

Kidneys.—Normal.

Suprarenal Bodies.—The right was normal. The left contained in the cortex a caseo-calcareous nodule about the size of a hemp seed.

Renal Gland.—The renal gland contained three whitish irregular caseous tubercles, the largest 1 mm. in diameter; one was perceptibly gritty.

Lumbar Glands.—Three lumbar glands contained each one or two small irregular yellow foci (up to 1 mm.); some were distinctly gritty, others not.

Coeliac Glands.—One the size of a broad bean showed three-quarters of its substance dense caseous and gritty, the rest was studded with yellow gritty tubercles. Other coeliac glands contained scattered calcareous tubercles.

Alimentary Tract.

Tongue, Pharynx, Tonsils.—Normal.

Submaxillary Glands.—Each contained a few calcareous tubercles, and one a caseous tubercle.

Retro-pharyngeal Glands.—There were a few small calcareous tubercles in the left retro-pharyngeal gland and a few rather larger ones in the right.

Parotideal Glands.—The left contained four softened caseous very slightly gritty nodules, the largest the size of a hemp seed; in the right there was one softened caseous nodule.

Intestines.—Two Peyer's patches contained scattered yellow gritty foci. The large intestine was normal.

Mesenteric Glands.—The glands at the termination of the mesentery were rather severely affected, the cortices being extensively replaced by calcareous areas some of which contained soft caseous patches; the rest of the mesenteric glands showed in the cortex scattered calcareous foci up to 2 or 3 mm. in diameter.

Ileo-Colic Glands.—The ileo-colic resembled the mesenteric glands, some being severely, others slightly affected.

Various Lymphatic Glands.

Precrural Glands.—In the cortex of the left there was a millet-seed sized caseous and softened gritty tubercle and a smaller calcareous tubercle. The right contained three or four minute calcareous foci.

Popliteal Glands.—Each contained a few minute calcareous foci.

Pudic Glands.—These contained several softened caseous nodules the size of wheat grains and a few gritty foci.

Ischiatic and Gluteal Glands.—Both ischiatic and the left gluteal glands showed each one or two minute calcareous foci. The right gluteal was normal.

Eyes.—Normal.

Mammary Gland.—Normal.

Microscopical Examinations.

Emulsion made from a Lung Nodule.—A moderate number of tubercle bacilli.

Emulsion made from a Liver Nodule.—One tubercle? bacillus seen.

Emulsion made from the Left Prescapular Gland.—Tubercle bacilli numerous.

Emulsion made from the Long Mediastinal Gland.—A few tubercle bacilli seen.

CALF 1409. Virus H. 100. "R.S."

Subcutaneous inoculation of culture derived from the original material through Guinea-pig 2931.

Dose—100·0 milligrammes.

Date of Inoculation—August 24, 1908. [Age about six months.]

Killed when in good health—December 21, 1908. [119 days after inoculation.]

Clinical Notes.

A prominent tumour of moderate size developed at the seat of inoculation which became soft and fluctuating, and eventually opened and discharged caseo-purulent matter. The adjacent prescapular gland became moderately enlarged and hard. The calf remained well during the experiment.

Temperature.

There was a very slight rise of temperature commencing on the 12th day after inoculation, and lasting 14 days (maximum 40·1° C.). With this exception the temperature was normal throughout the experiment.

Tuberculin Test.

November 4, 1908. [72 days after inoculation.] Dose, 2·0 cc. Slight reaction? Rise of temperature, 0·7° C.

Weights.

	cwt.	qrs.	lbs.
August 24, 1908...	1	3	21
December 21, 1908	2	2	22

Total gain of weight.—3 qrs. 1 lb.

Average rate of gain per week.—5 lbs.

POST-MORTEM EXAMINATION.

The carcass was in good condition.

Local Lesion.—At the seat of inoculation on the left side of the neck there was a firm tumour, the lower part of which was covered with masses of dried discharge; on removal of these a funnel-shaped depression in the skin was seen, at the apex of which was a sinus discharging pus. On section the tumour was composed of greatly thickened skin (1·8 cm. in greatest thickness) and a collapsed subcutaneous cyst with purulent contents, and a thick fibrous wall containing caseous gritty streaks. The sinus mentioned above led into the cavity.

Left Prescapular Gland.—The left prescapular gland measured 6 by 3 by 2·5 cm.; the capsule was thickened, the substance was tough; in the cortex chiefly in the superficial part were moderately numerous discrete tubercles and nodules; the former were calcareous, the latter caseo-calcareous; at one extremity the cortex was more severely affected showing irregular caseo-calcareous tracts.

Right Prescapular Gland.—The right prescapular gland measured 5 by 2·3 by 1·3 cm., and was normal on section.

Prepectoral Glands.—On the left side two were slightly enlarged but were not otherwise abnormal. Those on the right side were normal.

Cervical and Axillary Glands.—Normal.

Thorax.

Lungs.—The lungs were pink and crepitant throughout; they showed under the pleura as well as on section moderately numerous irregular translucent grey nodules ranging from 1 to 3 or 4 mm. in diameter; the nodules were homogeneous throughout (resembling gland tissue), and showed no sign of caseation or calcification.

Thoracic Glands.—The bronchial and dorsal mediastinal glands were little if at all enlarged; the bronchial and the long mediastinal glands contained sparsely scattered calcareous foci and a few caseo-calcareous nodules up to a hemp seed in size; the other mediastinal glands showed one or two calcareous grains only.

Pleura and Heart.—Normal.

Abdomen.

Omentum and Peritoneum.—Normal.

Spleen, Liver, Kidneys and Suprarenal Bodies.—Normal.

Portal Glands.—In one portal gland there was a millet-seed sized caseous gritty tubercle, and in another a minute calcareous grain

Renal, Lumbar, and Iliac Glands.—Normal.

Alimentary Tract.

Tongue, Pharynx, Tonsils.—Normal.

Retro-pharyngeal, Submaxillary and Parotideal Glands.—Normal.

Intestines.—Normal.

Mesenteric Glands.—One contained a millet-seed sized caseous tubercle, another an irregular caseo-calcareous nodule about 3 mm. in greatest diameter.

Ileo-Colic Glands.—Normal.

Testicles.—Normal.

Various Lymphatic Glands.

Precrural and Popliteal, Gluteal and Ischiatic, Pudic.—Normal.

Microscopical Examination.

Emulsion of the Left Prescapular Gland.—A moderate number of tubercle bacilli.

Emulsion of the Long Mediastinal Gland.—A few tubercle bacilli.

Emulsion of the Nodules from the Lung.—Scattered tubercle bacilli.

CALF 1523. Virus H. 100. "R.S."

Subcutaneous inoculation of culture derived from the original material through Guinea-pig 2929.

Dose—50·0 milligrammes.

Date of Inoculation—January 25, 1909. [Age about 16 weeks.]

Killed when dying—April 8, 1909. [73 days after inoculation.]

Clinical Notes.

The course of the disease was similar to that usually seen in cases of generalised progressive tuberculosis in the calf.

Temperature

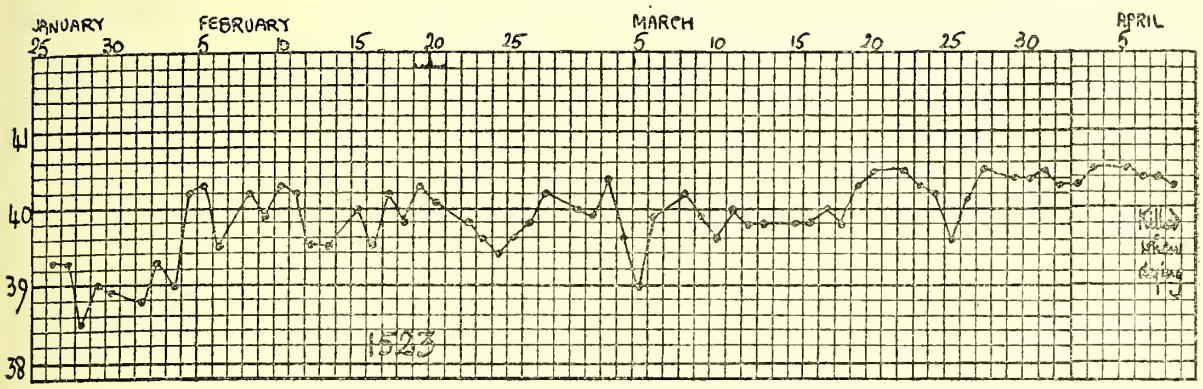

Weights.

	cwt.	qr.	lbs.
January 25, 1909	1	0	8
April 8, 1909	1	0	6

Loss of weight.—2 lbs.

POST-MORTEM EXAMINATION.

The carcass was thin.

Local Lesion.—At the seat of inoculation on the left side of the neck there was a very large firm tumour extending downwards into the loose tissues of the neck and backwards to the scapula, completely covering the adjacent lymphatic glands. On removal it was found to be intimately adherent to the scapular and prepectoral glands and to be composed of a large mass measuring 19 by 11 by 6 cm., and of infiltrated muscles which connected the large mass to the nearest glands. On section this mass was composed of yellow caseous substance with a cavity in the centre containing serous fluid; the skin over it was infiltrated and the muscles beneath were closely beset with dense yellow caseous nodules of various sizes; the muscles between the main mass and the glands were similarly affected; the tumour weighed with skin and infiltrated muscles 2 lbs. 10 ozs.

Left Prescapular Gland.—The left prescapular gland measured 12 by 6·5 by 6·5 cm. and weighed 14 ozs. It was composed throughout of dense pinkish-yellow cascated tissue slightly gritty from calcification; the capsule was much thickened and on the side adjacent to the tumour infiltrated with caseous nodules.

Right Prescapular Gland.—The right prescapular gland measured 3·5 by 1·5 by 0·7 cm. and was normal on section.

Prepectoral Glands.—On the left side one spherical gland 2·5 cm. in diameter was dense and caseous throughout; another about the same size was not so advanced, a third much larger than the first two was composed of pinkish-grey tissue closely beset with caseous tubercles; a fourth gland the size of a sparrow's egg was similar to the latter.

The glands on the right side were normal.

Cervical Glands.—In the lower part of the neck on the left side there was a large firm gland the size of a duck's egg; on section it was composed of firm greyish tissue closely beset with caseous tubercles and showing also a large irregular homogeneous yellow caseous patch. A small gland near it contained a hemp-seed sized caseous nodule.

A midcervical gland on the left side the size of a kidney bean was firm, grey, and beset with caseous tubercles; the other cervical glands were normal.

Axillary Glands.—Normal.

Thorax.

Pleura.—On the costal and diaphragmatic pleura there were scattered lenticular loosely attached nodules, ranging from a millet seed to a split pea in size. Many had haemorrhagic margins.

Lungs.—The lungs were voluminous and collapsed only partially; they weighed 5 lbs. 11 ozs.; the surfaces of the anterior lobes and the antero-ventral parts of the caudal were studded with raised pinkish nodules the largest about 10 mm. or more in diameter; here and there the nodules had coalesced and many were flattened out and mushroomed forming early "Perlsucht" growths. On the surfaces of the posterior and dorsal parts of the caudal lobes the nodules did not project and were not so numerous as in the anterior lobes. On section the lung parenchyma showed moderately numerous firm caseous nodules with greyish translucent margins varying from 2 to 8 mm. in diameter; here and there there was a larger nodule due to the coalescence of two or three smaller ones. Around many groups of nodules in the anterior lobes as well as around some single ones were reddish angular patches of consolidation; there were similar patches in the caudal lobes but smaller and not so numerous as in the anterior lobes.

Thoracic Glands.—The bronchial and dorsal mediastinal glands were enlarged and weighed 11 ozs.; they were firm and composed throughout of pinkish-grey tissue containing yellow caseous slightly gritty areas varying greatly in size, the largest measuring about 1 cm. in diameter; the inter-bronchial glands were similarly affected.

Heart.—Normal.

Abdomen.

Omentum and Peritoneum.—Normal.

Spleen.—The spleen showed in the pulp a moderate number of evenly distributed yellow caseous nodules the majority 4 to 5 mm. in diameter; there were a few smaller ones and a few larger ones; some caused projections on the surface and nearly all were softened in the centre.

Liver.—The liver was enlarged and pale; it showed on the convex surface two reddish-grey flattened "mushroomed" growths covering caseous nodules embedded in the substance of the liver. On the concave surface there were three prominent caseating nodules the largest more than 1 cm. in diameter; under the capsule and not causing projections were scattered nodules with caseous centres and grey margins ranging from a millet to a hemp seed in size; four dozen were counted on both surfaces; similar nodules were scattered evenly throughout the substance.

Portal Glands.—The portal glands were enlarged and composed almost entirely of large nodules with broad reddish-grey margins and firm yellow caseous centres slightly gritty from calcification.

Coeliac Glands.—The coeliac glands were enlarged and showed on section dense yellow caseous patches surrounded by firm greyish-red tissue.

Kidneys.—On the surface of the left kidney there were seven and on that of the right ten nodules ranging from a millet seed to a large pea in size; the majority of the nodules were large, they had broad grey margins and firm yellow caseous centres which were slightly gritty from calcification; some projected from the surface and were adherent to the capsule, the others were completely embedded in the cortex; there were a few similar nodules in the depth of the cortex of each kidney.

Renal Gland.—This gland was enlarged and almost entirely composed of two coalescing caseating nodules

Lumbar Glands.—All the lumbar glands were enlarged; one was firm and caseating throughout

another contained several discrete caseating nodules up to a pea, a third contained a few small grey nodules the largest caseous in the centre.

Iliac Glands.—In the left there were two and in the right five firm yellow caseous nodules with greyish-red margins, the largest measuring 1 cm. in diameter.

Alimentary Tract.

Pharynx.—In the corrugated mucous membrane there were several caseous nodules, one ulcerated.

Tonsils, Tongue.—Normal.

Submaxillary Glands.—The right was enlarged and three-quarters of its substance was beset with caseating nodules ; the left was normal.

Retro-pharyngeal Glands.—The right was enlarged and composed throughout of caseating nodules ; the left contained one pea-sized caseating nodule.

Parotideal Glands.—The left contained three caseous nodules the largest the size of a pea ; the right contained one grey tubercle.

Intestines.—Eight Peyer's patches in the small intestine contained softened caseous nodules, many ulcerated.

In the large intestine there were three submucous caseous tubercles, one ulcerated.

Mesenteric Glands.—Several mesenteric glands contained large firm caseating nodules, the largest 2 cm. in greatest diameter. The nodules were composed of yellow caseous areas embedded in reddish-grey tissue. Other glands contained one or two discrete nodules up to a hemp seed in size.

Ileo-colic Glands.—All were enlarged and on section showed nodules resembling those in the mesenteric glands.

Eyes.—Normal.

Testicles.—Normal.

Various Lymphatic Glands.

Precrural Glands.—The left contained an oval caseating nodule, 1·5 cm. in greatest diameter ; in the right there was a millet-seed sized caseous tubercle.

Popliteal Glands.—The left was normal. In the right there was a firm yellow caseous nodule with greyish-red margins about 8 mm. in diameter.

Gluteal Glands.—One contained a pea-sized caseating nodule, the other was normal.

Pudic and Ischiatic Glands.—Normal.

Haemo-lymph Gland.—One haemo-lymph gland among the lumbar glands contained a pea-sized caseating nodule.

Microscopical Examination.

Emulsion made from the Left Bronchial Gland.—Numerous tubercle bacilli.

CALF 1547. Virus H. 100. "R.S."

Subcutaneous inoculation of culture derived from the original material through Guinea-pig 2929.

Dose—100·0 milligrammes.

Date of Inoculation—January 25, 1909. [Age about 16 weeks.]

Killed when in good health—April 30, 1909. [95 days after inoculation.]

Clinical Notes.

The calf remained well during the experiment and grew normally.

Temperature.

For nine days following the inoculation the temperature was slightly raised and irregular, fluctuating between 38·9 and 39·8° C. ; it then rose sharply to 41·1° C., and reached a maximum of 41·2° C. on the following day. The temperature then slowly declined to the normal, and remained normal subsequently ; the pyrexia was of 25 days total duration.

Weights.

	cwt.	qrs.	lbs.
January 25, 1909	1	0	4
April 30, 1909	1	3	3

Total gain of weight.—2 qrs. 27 lbs.

Average rate of gain per week—6·1 lbs.

POST-MORTEM EXAMINATION.

The carcass was in good condition.

Local Lesion.—At the seat of inoculation on the left side of the neck there was a semi-fluctuating tumour measuring 13·5 by 7·5 by 4·5 cm. ; on section it was composed of a mass of dense caseous substance surrounded and completely separated from a fibrous capsule by caseo-pus ; the skin was greatly thickened and showed an ulcer 3·5 cm. in diameter the floor of which was formed by the dense caseous sequestrum ; between the latter and the edges of the skin which were inverted caseo-pus exuded.

Left Prescapular Gland.—The left prescapular gland measured 7·5 by 5 by 3·5 cm. and showed about three-quarters of its substance dense and caseous ; at one extremity of the gland this caseous substance was broken up into nodules each of which was surrounded by a thick fibrous capsule ; the caseous masses were gritty around the margins ; the rest of the gland showed caseous tubercles and nodules composed of aggregated tubercles.

The Right Prescapular Gland measured 4 by 2 by 1 cm. and was normal on section.

Prepectoral Glands.—On the left side one contained a calcareo-caseous nodule the size of a large pea. In one of the glands on the right side there was a caseous nodule 2 mm. in diameter.

Cervical Glands.—On the left side one contained a caseous gritty nodule 2·5 mm. in diameter ; on the right side the gland near the angle of the jaw contained a small calcareous tubercle.

Thorax.

Lungs.—The lungs were crepitant throughout ; they showed just under the pleura scattered nodules ranging from a millet seed to a pea in size ; the larger ones were caseous, softened, and gritty, and had fibrous capsules, many of the smaller ones had calcareous or calcareo-caseous centres ; 120 were counted on the surfaces of the right lobes, and there was a smaller number on the surfaces of the left. Nodules similar to those on the surface were scattered throughout the substance of the lungs.

Thoracic Glands.—The dorsal mediastinal and bronchial glands were not enlarged ; they contained scattered yellow tubercles ranging from a point just visible to the naked eye up to 2 mm. in diameter ; the larger ones were caseous and slightly gritty, the minute ones were calcareous.

Heart, Pleura and Pericardium.—Normal.

Abdomen.

Omentum and Peritoneum, Spleen, Kidneys and Suprarenal Bodies.—Normal.

Liver.—The liver was normal on the surface and on section.

Portal Glands.—The portal glands were normal in size ; they contained altogether eight tubercles the largest the size of a millet seed ; some were caseous others calcareo-caseous.

Coeliac Glands.—The coeliac glands were normal in size; one contained a millet-seed sized caseous tubercle.

Renal Glands.—One contained two, another four, caseous gritty tubercles.

Alimentary Tract.

Tongue, Pharynx, Tonsils.—Normal.

Submaxillary Glands.—In the left there was one calcareous tubercle, in the right a calcareous focus.

Parotideal Glands.—The left was normal, the right contained a pea-sized encapsuled caseous nodule.

Retro-pharyngeal Glands.—In the left there was one caseous nodule, in the right a calcareous tubercle.

Intestines.—The majority of the Peyer's patches contained yellow caseous tubercles (from one to eight) the largest the size of a millet seed.

The large intestine was normal.

Mesenteric Glands.—There was a moderate number of calcareo-caseous nodules in the mesenteric glands ranging from a millet seed to a large pea in size.

Ileo-colic Glands.—These contained similar nodules.

Testes.—Normal.

Various Lymphatic Glands.

Precrural Glands.—In the cortex of the right there was one hemp-seed sized caseous nodule ; in the left there were two similar but rather smaller nodules.

Popliteal Glands.—The right was normal, the left contained a hemp-seed sized yellow caseous nodule with a fibrous margin.

Pudic, Gluteal, Ischiatic and Axillary Glands.—Normal.

CALF 1511. Virus H. 100. "R.S."

Subcutaneous inoculation of culture derived from the liver of Calf 1419.

Dose—50·0 milligrammes.

Date of Inoculation—December 18, 1908. [Age about 14 weeks.]

Died—January 26, 1909. [39 days after inoculation.]

Clinical Notes.

The course of the disease was similar to that usually seen in calves suffering from acute tuberculosis.

Temperature.

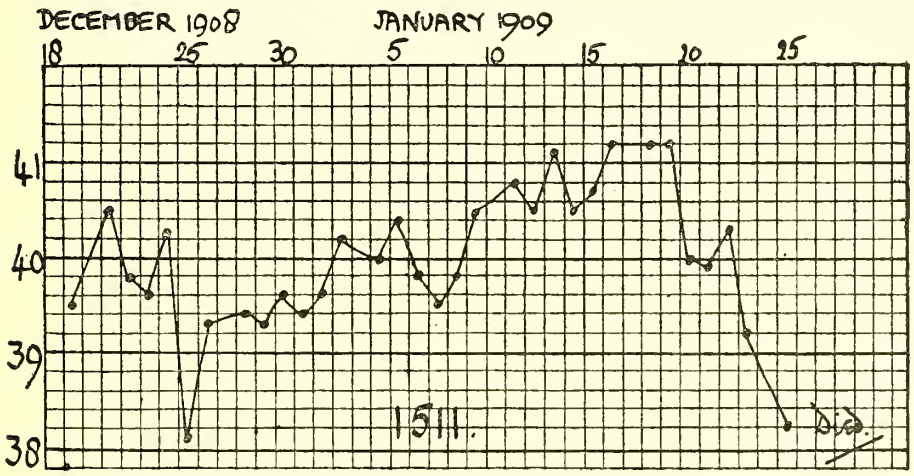

Weights.

	cwt.	qr.	lbs.
December 18, 1908	1	1	2
January 26, 1909	1	0	12

Total loss of weight.—18 lbs.

Average rate of loss per week.—3·2 lbs.

POST-MORTEM EXAMINATION.

The carcass was emaciated.

Local Lesion.—At the seat of inoculation on the left side of the neck there was a firm tumour measuring 12 by 6·5 by 2 cm. ; it was composed of dense caseous substance infiltrating skin and muscles.

Left Prescapular Gland.—The left prescapular gland measured 9 by 5 by 4 cm. ; the cortex was dense yellow and caseous throughout ; the medulla was congested.

Right Prescapular Gland.—The right prescapular gland measured 5 by 2 by 1 cm. and showed in the cortex numerous irregular yellow caseous tubercles up to 2 mm. in diameter.

Prepectoral Glands.—On the left side there were four glands ; one was egg-shaped and 4·5 cm. in length and was composed throughout of dense pinkish yellow caseated tissue ; another 1 cm. in diameter was caseating throughout, a third showed early caseation of the cortex, and the fourth contained discrete caseous tubercles.

All the prepectoral glands on the right side contained discrete caseous tubercles.

Cervical Glands.—All the cervical glands were slightly enlarged, congested and oedematous, and contained numerous caseous tubercles up to 2 mm. in diameter, becoming confluent in two of the glands on the left side.

Thorax.

Pleura.—On the costal pleura near the vertebral column there were about half-a-dozen small flattened caseating nodules. There were four smaller ones on the diaphragmatic pleura.

Lungs.—The lungs were enlarged and weighed 6 lbs. 8 ozs. The anterior lobes on the right side were extensively consolidated, very little crepitant lung tissue remaining; the right caudal lobe showed about a third of its substance dark red and solid, the rest being crepitant and diffusely congested and consolidated.

The left cephalic lobe showed a large patch of consolidation and the antero-ventral portion of the caudal lobe was firm, dark red, and airless; the rest of these lobes was congested and crepitant.

The lung parenchyma was very closely beset with caseating tubercles, rather irregular in outline and varying up to 1·5 mm. in diameter.

Thoracic Glands.—The bronchial and dorsal mediastinal glands were enlarged (weight together 6 ozs.) and deeply congested externally; on section their cortices were closely beset with caseous tubercles aggregated together here and there to form caseating patches.

Heart.—Dilated and hypertrophied. On the endocardium of the right auricle there were four small tubercles and on that of the right ventricle one.

Abdomen.

Omentum.—On the ventral surface of the omentum there were moderately numerous firm reddish flattened nodules caseating in the centre, the largest 3 mm. in diameter.

Parietal Peritoneum.—Normal.

Spleen.—The pulp was closely beset with caseous tubercles, the largest the size of a millet-seed.

Liver.—The liver showed on the surface moderately numerous tubercles; some immediately beneath the capsule were flattened, greyish, with caseous centres, and about 1·5 mm. in diameter; others deeper down were much smaller and of a yellowish colour. On section the substance showed moderately numerous evenly distributed caseous tubercles ranging from a mere point to rather less than 1 mm. in diameter.

Portal Glands.—The portal glands were enlarged and very oedematous; the cortices were closely beset with coalescing caseous tubercles.

Gall-bladder.—Under the mucous membrane of the gall-bladder there were four caseous tubercles.

Kidneys.—In the cortex of each kidney there were sparsely scattered miliary caseous tubercles.

Suprarenal Bodies.—In the cortex of the right there were three, and in that of the left two pinhead-sized caseous tubercles.

Coeliac and Renal Glands.—These glands were enlarged and very closely beset with caseous tubercles.

Lumbar Glands.—The lumbar glands were closely beset with caseous tubercles.

Alimentary Tract.

Pharynx and Palate.—There were numerous caseous tubercles in the corrugated mucous membrane of the vault of the pharynx and fairly numerous submucous tubercles on both sides of the soft palate.

Tongue.—There were a few caseous submucous tubercles at the root of the tongue.

Tonsils.—There were a few caseous tubercles in each tonsil.

Submaxillary, Retro-pharyngeal, and Parotideal Glands.—All showed their cortices closely beset with irregular caseous tubercles.

Intestines.—All the Peyer's patches contained miliary caseous tubercles; in some they were very numerous, especially in the ileum; there were also scattered submucous tubercles in the small intestine. No tubercles were seen in the large intestine.

Mesenteric and Ileo-colic Glands.—These glands were enlarged and showed their cortices closely beset with caseous tubercles confluent around the peripheral parts of the cortices.

Peripheral Lymphatic Glands.—All the peripheral lymphatic glands were enlarged and their cortices closely beset with caseous tubercles, irregular in outline, and varying up to 2 or 2·5 mm. in diameter.

Haemo-lymph Glands.—Most of the haemo-lymph glands were enlarged and contained caseous tubercles similar to those in the peripheral lymphatic glands.

Larynx and Trachea.—The mucous membrane of the larynx below the vocal chords and of the trachea was deeply congested and showed numerous caseous ulcers up to 3 mm. in greatest diameter; the margins of each were more deeply congested than the surrounding membrane.

Thymus.—The thymus contained scattered caseous tubercles similar to those in the peripheral glands.

Testicles.—Normal.

CALF 1517. Virus H. 100. "R.S."

Subcutaneous inoculation of culture derived from the lung of Calf 1419.

Dose—50·0 milligrammes.

Date of Inoculation—December 3, 1908.

Died—December 25, 1908. [22 days after inoculation.]

Clinical Notes.

The course of the disease was similar to that usually seen in cases of acute tuberculosis of the lungs following the subcutaneous inoculation of virulent tubercle bacilli.

Temperature.

Irregular pyrexia set in on the day following the inoculation, and continued until the twenty-first day. On the twenty-second day the temperature fell to 38·3° C., and the calf died in the afternoon of that day. The highest temperature recorded was 40·7° C. on the fourteenth day.

Weights.

	cwt.	qrs.	lbs.
December 3, 1908	1	0	12
December 25, 1908	0	3	25

Total loss of weight.—15 lbs.

Average rate of loss per week.—Nearly 5 lbs.

POST-MORTEM EXAMINATION.

The carcass was emaciated.

Local Lesion.—At the seat of inoculation on the left side of the neck there was a well defined flat tumour measuring 10 by 7 by 2·5 cm.; it was com-

posed of pinkish-yellow caseo-necrotic substance which infiltrated the skin and the muscles.

Left Prescapular Gland.—The left prescapular gland measured 8 by 4·5 by 3·5 cm., and was composed throughout of dense pinkish-yellow caseo-necrotic substance.

Right Prescapular Gland.—The right prescapular gland measured 4·5 by 0·7 by 0·6 cm., and was normal on section.

Prepectoral Glands.—The round prepectoral gland on the left side measured 1·4 cm. in diameter, and was composed throughout of dense caseo-necrotic substance; two other glands contained each one greyish-white tubercle 1 mm. in diameter.

The prepectoral glands on the right side were normal.

Cervical Glands.—On the left side the upper cervical gland contained a nodule, measuring 2 by 1·2 cm., and representing one-third of the gland, composed of greyish-yellow caseo-necrotic substance containing opaque yellow foci. In the cortex of the mid-cervical gland there was a small grey tubercle. The lower cervical gland showed in its cortex small yellowish-white tubercles becoming confluent; the rest were normal.

On the right side the mid-cervical gland contained in the cortex three small yellowish-white caseous tubercles, and one other two minute grey tubercles; the rest were normal.

Thorax.

Lungs.—The lungs were heavy (weight 4 lbs. 4 ozs.) and of a dark red colour; the cephalic lobes of both lungs, the right caudal lobe and two-thirds of the left caudal lobe, were firm, hepatized, and airless, except for a few small air-containing lobules in the marginal portions; the lower portion of the left caudal lobe was pink and crepitant. The surfaces of both lungs were moderately closely beset with discrete greyish-white tubercles, the larger ones measuring 1 mm. in diameter; on section the tubercles seemed more numerous than on the surface and were in places confluent; the majority were rather less than 1 mm. in diameter.

Thoracic Glands.—The thoracic glands were congested and slightly enlarged. The left bronchial gland showed in the cortex a moderate number of irregular greyish-white caseous tubercles, in places becoming confluent.

The long mediastinal gland was similarly affected.

The other smaller thoracic glands contained scattered caseous tubercles.

Pleura.—Normal.

Heart.—Normal.

Abdomen.

Omentum and Peritoneum.—On the omentum two millet-seed sized tubercles with yellowish-white centres were seen. The parietal peritoneum was normal.

Spleen.—The spleen was soft and dark red; no tubercles were seen.

Liver.—The liver showed on its surface fourteen minute grey tubercles; on section similar tubercles were sparsely scattered throughout the substance, which was pale and of a yellowish colour.

Portal Glands.—The portal glands were not enlarged and showed in the cortices a few discrete greyish-white tubercles.

Coeliac Glands.—The coeliac glands were three in number; one showed in the cortex two greyish-white tubercles, the largest measuring 1 mm. in diameter; a single tubercle was seen in another, and the third showed a small patch of early caseation in the cortex.

Kidneys.—On the surface of the left kidney three minute grey tubercles were seen and one a little more than 1 mm. in diameter. On section three small grey tubercles were seen in the cortex.

In the cortex of the right kidney there were nine small grey tubercles on the surface and two in the depth.

Suprarenal Bodies.—One minute grey tubercle was seen in the cortex of the right; the left appeared normal.

Renal Glands.—One renal gland showed a moderate number of discrete greyish-white tubercles, the other showed four similar tubercles in the cortex.

Lumbar Glands.—One lumbar gland showed in the cortex two miliary caseous tubercles.

Iliac Glands.—Two caseous tubercles were seen in the left and one in the right.

Alimentary Tract.

Tongue, Tonsils.—Normal.

Pharynx, Larynx, Trachea.—The mucous membranes of the larynx and trachea were congested; no tubercles were seen. The mucous membrane of the pharynx was deeply congested.

Retro-pharyngeal Glands.—The pharyngeal glands were deeply congested, almost black; the right contained about half-a-dozen small greyish-white tubercles; in the left was seen a moderate number of indefinite grey points.

Submaxillary Glands.—Each of the submaxillary glands contained one small greyish-white tubercle and a few discrete grey points.

Parotideal Glands.—The left parotideal gland showed four greyish-white tubercles; the right two.

Intestines.—Normal.

Mesenteric Glands.—Two mesenteric glands showed in their cortices a few greyish-white miliary tubercles.

Ileo-colic Glands.—One ileo-colic gland contained three similar tubercles.

Various Lymphatic Glands.

Axillary Glands.—The left contained a small grey tubercle; the right was normal.

Ventral Mediastinal Glands.—One contained in the cortex two miliary caseous tubercles.

Popliteal Glands.—On the surface of the right three slightly-raised caseous tubercles with slightly congested translucent margins were seen, the largest measuring a little more than 1 mm. in diameter.

Precrural Glands.—The left showed two miliary greyish-white tubercles in the cortex; no tubercles were seen in the right.

Supramammary Gland.—The supramammary gland contained ten small greyish-white caseous tubercles, the majority of which were congested around the margins.

Gluteal Glands.—The right contained three small yellowish-white tubercles; the left was normal.

Microscopical Examinations.

Smear from Cut Surface of Lung.—A moderate number of tubercle bacilli.

Emulsion of the Left Prepectoral Gland.—Moderately numerous tubercle bacilli.

Emulsion of the Left Bronchial Gland.—A few tubercle bacilli seen.

Smear from Cut Surface of Spleen.—Two tubercle bacilli seen.

Smear from a Tubercle in the Liver.—Two tubercle bacilli seen.

CALF 1543. Virus H. 100. "R.S."

Subcutaneous inoculation of culture derived from the mediastinal gland of Calf 1409.

Dose—50·0 milligrammes.

Date of Inoculation—February 17, 1909. [Age about 5 months.]

Killed when dying—March 23, 1909. [34 days after inoculation.]

Clinical Notes.

The course of the disease was similar to that usually seen in calves suffering from acute tuberculosis.

Temperature.

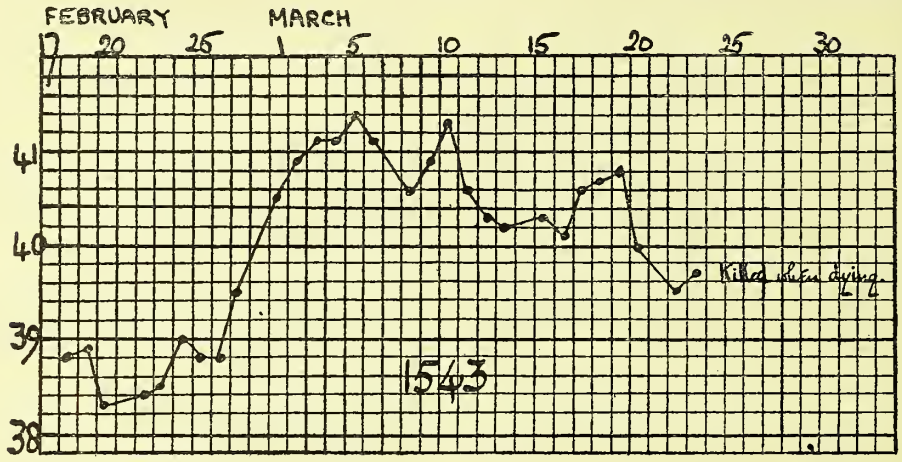

Weights.

	cwt.	qr.	lb.
February 17, 1909	1	1	1
March 23, 1909	1	0	0

Total loss of weight.—1 qr. 1 lb.

Average rate of loss per week.—5·8 lbs.

POST-MORTEM EXAMINATION.

The carcass was emaciated.

Local Lesion.—At the seat of inoculation on the left side of the neck, there was a large firm tumour weighing 1 lb. 2 ozs. and measuring 14 by 10 by 5·5 cm. On section it was composed of caseo-necrotic substance infiltrating the skin and the muscles, the latter deeply; it contained a large oval cavity 7·5 cm. in length with ragged caseo-necrotic walls and clear yellowish serous contents.

Left Prescapular Gland.—The left prescapular gland measured 9 by 5 by 4 cm. and was composed partly of dense pinkish-yellow caseous substance and partly of grey tissue closely infiltrated with a yellow caseous network.

Right Prescapular Gland.—The right prescapular gland measured 4 by 1·8 by 0·8 cm. and showed in the cortex scattered caseous nodules up to 2·5 mm. in diameter.

Prepectoral Glands.—On the left side one 1·5 cm. in diameter was firm and in an early stage of caseation; the others on this side and on the right contained discrete caseous nodules as in the peripheral lymphatic glands (*see* below).

Cervical Glands.—On the left side the lower cervical gland was the size of a walnut and was composed of firm translucent grey tissue closely infiltrated with irregular yellow caseous foci. The other glands were not appreciably enlarged but contained a varying number of caseating nodules.

Thorax.

Parietal Pleura.—The connective tissue fringes along some of the ribs were slightly hypertrophied and contained grey tubercles and a few lenticular nodules like those on the omentum.

Lungs.—The lungs were enlarged and collapsed only slightly; they weighed 6 lbs. 2 ozs. The anterior lobes and the antero-ventral portions of the caudal were pale reddish in colour and quite airless; the rest of the caudal lobes was air containing but abnormally firm and many of the bronchi were plugged with muco-pus; the tissue was congested.

The surfaces of the anterior lobes and parts of the caudal were closely studded with raised grey nodules here and there aggregated together; they varied from 1 up to 3 mm. in diameter, the majority being about 2 mm. On section the lung parenchyma was everywhere very closely beset with miliary grey tubercles with caseous centres; the tubercles were for the most part discrete, but here and there were aggregated together.

Thoracic Glands.—The dorsal mediastinal and bronchial glands were much enlarged, weighing altogether 10 ozs.; their cortices were composed throughout of firm grey tissue containing irregular ill-defined yellow foci and streaks (early caseation) and in places a well-defined yellow caseous network.

The interbronchial glands were enlarged and similarly affected.

Heart.—The pericardium over the great vessels showed three clusters of grey caseating tubercles in loose connective tissue. The heart muscle and the valves were normal.

Abdomen.

Omentum.—On the ventral surface of the omentum there were from three to four dozen lenticular nodules varying up to 4 mm. in diameter; they were grey, some reddish, and had caseous centres.

Parietal Peritoneum.—Normal.

Spleen.—The spleen was slightly enlarged and closely beset with caseating tubercles varying from 1 to about 2·5 mm. in diameter.

Liver.—The liver showed on the surface very numerous caseous tubercles, some just beneath the capsule, others projecting slightly; many of the latter were flattened out and had thin overhanging grey margins and measured up to 3 mm. in diameter. On section the liver substance was closely and evenly beset with caseous tubercles varying in size up to that of a millet seed.

Portal Glands.—The portal glands were enlarged and oedematous and showed their cortices composed of confluent grey tubercles with caseous centres.

Kidneys.—One kidney was congenitally absent and was represented by a small mass of fibrous tissues

containing a few tubercles. The other kidney (the right) was nearly twice the normal in size and showed in the cortex a moderate number of grey tubercles up to 2 mm. in diameter with minute caseous centres.

Suprarenal Bodies.—The left contained a grey miliary tubercle ; the right was normal.

Renal Gland.—The renal gland was enlarged, the cortex was grey (aggregated tubercles) and infiltrated with small caseous foci.

Alimentary Tract.

Pharynx.—Under the mucous membrane at the base of the tongue there were two grey miliary tubercles.

Tonsils.—Normal.

Intestines.—Six Peyer's patches in the small intestine contained scattered foci of yellow pus.
The large intestines appeared normal.

Mesenteric Glands.—These contained scattered grey tubercles with minute caseous centres.

Ileo-colic Glands.—The ileo-colic glands showed similar tubercles but more numerous and in places confluent.

Various Lymphatic Glands.

The lumbar, iliac, and all the peripheral lymphatic glands contained moderately numerous caseous nodules varying from 1 up to about 3 mm. in diameter.

Larynx and Trachea.—The mucous membrane showed a few miliary grey tubercles.

Eyes.—Normal.

Testicles.—Normal.

Microscopical Examination.

Purulent focus from the Small Intestine.—Numerous tubercle bacilli.

RHESUS MONKEY 163. Virus H. 100. "R.S."

(A young animal.)

Subcutaneous inoculation of culture derived from the original material through Guinea-pig 2929.

Dose—1·0 milligramme.

Date of Inoculation—May 19, 1908.

Died—August 13, 1908. [86 days after inoculation.]

Clinical Notes.

The monkey lost appetite and became weak and emaciated ; the respiration was normal and there were no other symptoms. The weight at death was 1650 grammes.

POST-MORTEM EXAMINATION.

The carcass was emaciated.

Local Lesion.—In the subcutaneous tissues over the posterior angle of the left scapula there was a small flattened cavity 2·5 cm. in greatest diameter containing a small quantity of curdy caseo-pus. The cavity was surrounded by a wall of fibrous tissue, 1 mm. thick, lined internally with granulation tissue. The skin over it showed two small openings which led into the interior of the cavity.

Axillary Glands.—One on the right side contained two pinhead-sized caseous tubercles, another a minute caseous focus.
On the left side, one the size of a pea showed three-quarters of its substance caseous and softened ; another contained a millet-seed sized caseous tubercle. The rest were free from caseation.

Cervical Glands.—None of the cervical glands showed any sign of caseation. Those behind the clavicle were deeply congested.

Vertebral Glands.—In the 9th interspace on the left side there was a caseous and softened gland the size of a split pea. The 7th, 8th, and 10th interspaces each contained a small caseous gland. The rest were normal.

Thorax.

Lungs.—The lungs were voluminous, somewhat oedematous, and mottled with patches of congestion. The thin ventral margins of the anterior lobes were red and airless. The lung tissue showed distributed evenly throughout fairly numerous grey tubercles, varying slightly in size from about 0·5 up to a little more than 1 mm. in diameter ; the larger ones had opaque white centres, the smaller ones were homogeneous.

Bronchial Glands.—The bronchial glands were slightly enlarged, deeply congested, and contained scattered discrete caseous tubercles.

Heart.—There were small petechial haemorrhages on the surface of the heart, otherwise the heart was normal.

Pleura.—Normal. The pleural cavities contained each about 10·0 cc. of clear yellow fluid.

Abdomen.

Omentum. — The omentum showed half a dozen shotty caseous tubercles, the largest the size of a millet seed.

Peritoneum.—Normal.

Spleen.—The spleen was not enlarged, and showed in the pulp a moderate number of evenly distributed softened yellow caseous nodules, ranging in size from 1 to 2·5 mm. in diameter.

Splenic Lymphatic Glands.—Normal.

Liver. — On the surface of the liver just under the capsule two yellow caseous tubercles with grey margins the largest a millimetre in diameter were seen ; there were also scattered greyish-white points of a doubtful nature. On section one caseous tubercle was seen in the depth.

Portal Gland.—The portal gland on the head of the pancreas was slightly enlarged and contained discrete miliary caseous tubercles.

Kidneys.—The right kidney showed on the surface a dozen or more tubercles varying in size up to 1 mm. A few similar tubercles were seen in the depth. The left kidney showed in the cortex about the same number of similar tubercles.

Suprarenal Bodies.—Normal.

Alimentary Tract.

Tongue, Pharynx.—Normal.

Pharyngeal and Submaxillary Glands.—Normal.

Intestines.—Normal.

Gastric Glands.—One gastric gland contained a minute caseous focus.

Mesenteric Ileo-Colic, and Colic Glands.—Normal.

Inguinal Glands.—Normal.

RHESUS MONKEY 207. Virus H. 100. "R.S.'

(A young animal.)

Subcutaneous inoculation of culture derived from the original material through Guinea-pig 2931.

Dose—1·0 milligramme.

Date of Inoculation—August 24, 1908.

Died—September 19, 1908. [26 days after inoculation.]

Clinical Notes.

On the morning of September 11, after a cold night, the monkey was found to be in a state of collapse. It rallied a little when the room was warmed, but sank and died on September 19. The weight at death was 1120 grammes.

POST-MORTEM EXAMINATION.

The carcass was thin.

Local Lesion.—In the subcutaneous tissues of the back over the posterior ribs there was a collection of caseo-pus measuring 3 by 1·5 by 1 cm ; the skin over it showed a small opening through which the caseo-pus exuded.

Axillary Glands.—On the right side one a centimetre in greatest diameter was caseous and softened throughout. Others on this side and those on the left were normal.

Cervical Glands.—One behind the left clavicle the size of a small pea was caseous and softened throughout. Other cervical glands were normal.

Vertebral Glands.—On the right side the glands in the 9th to the 11th interspaces were slightly enlarged, caseous, and softened throughout. Other vertebral glands were normal.

Thorax.

Lungs.—The lungs showed around the roots some airless red collapsed patches : otherwise the organ was normal.

Bronchial Glands.—A bronchial gland on the left side contained a pinhead-sized yellow caseous tubercle ; the rest were normal.

Heart and Pleura.—Normal.

Abdomen.

Omentum and Peritoneum.—Normal.

Spleen.—The spleen was normal in size and contained one pinhead-sized caseous tubercle.

Liver, Kidneys, and Suprarenal Bodies.—Normal.

Splenic, Pancreatic, Lumbar, and Renal Glands.—Normal.

Alimentary Tract.

Tongue, Pharynx, Tonsils.—Normal.

Submaxillary and Retropharyngeal Glands.—Normal.

Intestines, Mesenteric, and Ileo-Colic Glands.—Normal.

Inguinal Glands.—Normal.

Microscopical Examination.

Tubercle from the Spleen.—Tubercle bacilli numerous.

RHESUS MONKEY 255. Virus H. 100. "R.S."

(A young animal.)

Subcutaneous inoculation of culture derived from the original material through Guinea-pig 2931.

Dose—1·0 milligramme.

Date of Inoculation—December 21, 1908.

Died—February 7, 1909. [48 days after inoculation.]

POST-MORTEM EXAMINATION.

The cause of death was not apparent.

Local Lesion.—Over the ribs on the left side just behind the angle of the scapula there was a prominent fluctuating swelling measuring 3·5 by 2·5 by 1·5 cm. On section the tumour was composed of caseous substance, the superficial and central parts of which were softened, the deep and marginal parts dense and infiltrating the muscles. The skin over the tumour was intact.

Axillary Glands.—On the left side one the size of a pea showed the cortex partly caseous, another contained a caseous focus.

On the right side one contained a caseous tubercle.

Cervical Glands.—On the left side one the size of a hemp-seed was beset with pinhead-sized caseous tubercles.

Other cervical glands were normal.

Vertebral Glands.—One in the 9th interspace on the left side was slightly enlarged and partly caseous.

One in the 8th and one in the 18th interspaces on this side contained caseous foci. The rest were normal.

Thorax.

Lungs.—The lungs were crepitant and collapsed normally ; they showed under the pleura scattered translucent (some almost transparent) grey tubercles ranging from a mere point up to 1 mm. in diameter. Altogether three dozen were counted on the surface of the lungs. On section one caseous tubercle the size of a millet-seed and a few minute grey tubercles were seen.

Abdomen.

Spleen.—The spleen was normal in size and showed in the pulp two yellowish-white caseous tubercles the size of a millet-seed and a few scattered minute greyish foci, ? early tubercles.

Liver.—The liver showed in the substance just under the capsule half a dozen opaque greyish-yellow tubercles, the largest the size of a millet-seed. On section three caseous tubercles the largest 2 mm. in diameter were seen in the depth.

Ileo-colic Glands.—One contained a miliary caseous tubercle.

All the remaining organs and glands were examined and found normal.

Microscopical Examination.

Spleen (one of the grey foci).—Moderately numerous tubercle bacilli.

RHESUS MONKEY 257. Virus H. 100. "R.S."

(A young animal)

Subcutaneous inoculation of culture derived from the original material through Guinea-pig 2931.

Dose—1·0 milligramme.

Date of Inoculation—December 21, 1908.

Killed—January 15, 1909. [25 days after inoculation.]

Clinical Notes.

The animal was killed on account of the development of a gangrenous condition of the upper lip and gum

POST-MORTEM EXAMINATION.

The carcass was in fair condition.

Local Lesion.—In the subcutaneous tissues of the back on the right side over the lower ribs there was a hemispherical caseous and softened tumour measuring 2 by 1 cm.

Axillary Glands.—One on the right side was enlarged and congested, but was not caseous; the rest were normal.

Vertebral Glands.—On the right side the glands in the last few interspaces were enlarged and congested but showed no sign of caseation.

The upper lips and gum above the incisor teeth were gangrenous and sloughing and very foul; the two central incisors had fallen out, and the lateral ones were loose; the face was very oedematous.

The submental and submaxillary glands were enlarged.

There was no sign of disease elsewhere.

Microscopical Examination.

Smear from substance of Spleen.—One tubercle bacillus seen.

Smear from substance of Liver.—No tubercle bacilli seen.

RHESUS MONKEY 261. Virus H. 100. "R.S."

Fed once with culture derived from the original material through Guinea-pig 2931.

Dose—10·0 milligrammes.

Date of Feeding—December 21, 1908.

Died—March 10, 1909. [79 days after feeding.]

Clinical Notes.

The monkey died after a fortnight's illness, marked by loss of appetite, extreme weakness and emaciation.

The weight at death was 1750 grammes.

POST-MORTEM EXAMINATION.

The carcass was emaciated.

Alimentary Tract.

Tongue and Pharynx.—Normal.

Tonsils.—In the right tonsil there was a firm greyish-white focus. The left appeared normal.

Submaxillary Glands.—One on the right side was slightly enlarged and partly caseous; the rest were normal.

Retro-pharyngeal Glands.—Each pharyngeal gland was slightly enlarged and showed caseous patches in the cortex.

Submental Glands.—Three submental glands, the largest the size of a hemp seed, were caseous almost throughout.

Intestines.—The mucous membrane of the small intestine showed fourteen tuberculous ulcers varying from 2 to about 10 mm. in greatest diameter; they had thickened bases and were caseous around the margins.

The mucous membrane of the caecum showed large areas of ulceration (not tuberculous); the floor of the ulcerated areas was hæmorrhagic and partially covered with a greyish adherent membrane.

Mesenteric Glands.—The mesenteric glands were enlarged and fused together to form a mass 4 by 2 by 2 cm. and were caseous and softened throughout.

Ileo-colic Glands.—One ileo-colic gland contained a minute caseous tubercle, and one of the glands in the upper part of the meso-colon showed a patch of early caseation in the cortex.

On the anterior part of the mesentery there were scattered miliary caseous tubercles.

Thorax.

Lungs.—The lungs were crepitant throughout and contained altogether six firm yellow caseous nodules 2 to 6 mm. in diameter.

Bronchial Glands.—The praetracheo-bronchial gland on the left side was enlarged and showed about half its substance caseous and softened.

The gland on the right side contained two caseous tubercles. Two of the intertracheo-bronchial glands each contained two caseous tubercles.

Heart and Pleura.—Normal.

Abdomen.

Omentum and Parietal Peritoneum.—Normal.

Spleen.—The spleen was normal in size and showed in the pulp three miliary caseous tubercles.

Liver.—The liver showed under the capsule rather more than a dozen opaque greyish-white or greyish-yellow tubercles, varying from a mere point up to 1 mm. in diameter. Similar tubercles were seen scattered about in the depth of the liver.

Kidneys and Suprarenal Bodies; Portal, Pancreatic, and Splenic Glands.—Normal.

Lumbar Glands.—The lumbar glands were enlarged and in a state of early caseation.

Cervical, Inguinal, and Axillary Glands.—Normal.

Microscopical Examination.

Smear from a Tubercle in the Tonsil.—Tubercle bacilli very numerous—resembled a pure culture.

RHESUS MONKEY 281. Virus H. 100. "R.S."

(A young animal.)

Subcutaneous inoculation of culture derived from the liver of Calf 1419.

Dose—1·0 milligramme.

Date of Inoculation—March 26, 1909.

Died—April 17, 1909. [22 days after inoculation.]

POST-MORTEM EXAMINATION.

The carcass was thin. Its weight was 1400 grammes. The monkey died prematurely. The cause of death was not apparent.

Local Lesion.—Over the left scapula at the seat of inoculation there was a large ulcerated area with clean-cut slightly undermined margins and smooth dry floor formed by muscles which showed here and there a thin adherent yellow patch.

Axillary Glands.—The glands on the right side were enlarged; some were caseous and softened throughout, others were partly caseous. Those on the left side were normal.

Cervical Glands.—On the left side in the posterior triangle there were two caseous and softened glands one the size of a large pea, the other much smaller. Behind the acromial end of the clavicle there were two small glands which contained each a cascous tubercle or two. Other cervical glands were normal.

Thorax.

Lungs.—The lungs were crepitant and showed on the surface sparsely scattered translucent miliary grey tubercles; altogether nine were counted on the surfaces of both lungs.

Bronchial Glands.—Normal.

Abdomen.

Spleen.—The spleen was slightly enlarged and contained numerous greyish-yellow tubercles, some softened, the largest 1 mm. in diameter.

Liver.—The liver was moderately closely beset with opaque greyish or greyish-yellow tubercles varying from a mere point up to 1 mm. in diameter.

Portal Gland.—The portal gland was not enlarged, but contained a few caseous tubercles.

Kidneys and Suprarenal Bodies.—Normal.

Lumbar Glands.—One contained a caseous tubercle.

There was no sign of tuberculosis elsewhere in the body.

RHESUS MONKEY 283. Virus H. 100. "R.S."

(A young animal.)

Subcutaneous inoculation of culture derived from the liver of Calf 1419.

Dose—1·0 milligramme.

Date of Inoculation—March 26, 1909.

Died—April 29, 1909. [34 days after inoculation.]

Clinical Notes.

The course of the disease was similar to that usually seen in monkeys suffering from acute tuberculosis.

The weight at death was 1520 grammes.

POST-MORTEM EXAMINATION.

The carcass was emaciated.

Local Lesion.—At the seat of inoculation over the right scapula there was a large ulcer, 6 cm. in greatest diameter, with thinned undermined margins and congested floor formed by the muscles, covered with a thin yellow layer and showing here and there small necrotic masses; the ulcer was partially covered with a thin brownish easily detached scab.

Axillary Glands.—On the right side there was a group of six enlarged glands, the largest 1·3 cm. in diameter, all caseous and softened throughout.

On the left side two glands contained each one or two small caseous tubercles.

Cervical Glands.—Two behind the clavicle on the right side were enlarged (1 cm. in diameter) and caseous and softened throughout. In the left posterior triangle behind the clavicle were four slightly enlarged glands; two showed patches of caseation, the other two discrete caseous tubercles.

Vertebral Glands.—On the right side two, the largest the size of a split pea, in the 8th and 9th interspaces, were caseous throughout; another in the 11th space contained a caseous tubercle. Those on the left side were normal.

Thorax.

Lungs.—The lungs were voluminous and showed no areas of collapse; they contained a moderate number of evenly-distributed tubercles ranging up to about 2 mm. in diameter; the majority had caseous centres and grey margins; a few of the smaller ones were translucent throughout, while most of the largest ones were completely caseous.

Bronchial Glands.—On the right side of the trachea extending from the 1st rib to the bronchus there were two enlarged glands which were caseous throughout. Other bronchial glands showed a moderate degree of enlargement and their cortices were closely beset with caseous nodules.

Heart.—The pericardial sac was distended with clear fluid. The heart muscles and valves were normal.

Ribs.—There were a few tubercles in the rib marrow.

Pleura.—Normal.

Abdomen.

There was a slight excess of fluid in the peritoneal cavity.

Omentum.—The omentum showed about half-a-dozen miliary caseous tubercles.

Peritoneum.—Normal.

Spleen.—The spleen was enlarged, measuring 5 by 2·5 by 1·5 cm., and closely beset with caseous nodules varying up to 3 mm. in diameter.

The Splenic Lymphatic Glands were slightly enlarged and showed small caseous tubercles in the cortices.

Liver.—The liver was enlarged, pale, and very closely beset with caseous tubercles varying in size from a point just visible to the naked eye up to 1·5 mm. in diameter.

Portal Gland.—The gland in the small omentum was enlarged and its cortex filled with caseous coalescing nodules.

Kidneys.—The cortex of the left kidney contained several caseous tubercles, six near the surface and one in the depth ; the largest was the size of a millet seed. On the surface of the right there were four similar tubercles ; none was seen in the depth.

Suprarenal Bodies.—In the cortex of the left there were two caseous tubercles, in that of the right one.

Iliac Glands.—One contained a caseous tubercle.

Lumbar Glands.—The lumbar glands were enlarged and beset with caseous tubercles ranging up to 2 mm. in diameter.

Inguinal Glands.—The left inguinal gland contained one caseous nodule 3 mm. in diameter.

Alimentary Tract.

Tongue, Pharynx.—Normal.

Tonsils.—In each tonsil a minute whitish focus or two was seen.

Submaxillary Glands.—On the left side one contained a caseous tubercle.

Retro-pharyngeal Glands.—Normal.

Intestines.—Not examined.

Mesenteric Glands.—These glands were not enlarged but contained several discrete caseous tubercles.

Ileo-colic and Colic Glands.—Normal.

Microscopical Examination.

Tubercle from the Tonsil.—Tubercle bacilli numerous.

PIG 133. Virus H. 100. "R.S."

Fed on alternate days for a fortnight—seven times in all—with culture derived from the original material through Guinea-pig 2931.

Dose—The pig received the growth from one serum tube on each occasion.

Date of Feeding—September 19—October 1, 1908. [Age 16 weeks.]

Killed when in good health—January 11, 1909. [114 days after feeding.]

Clinical Notes.

The pig remained well during the experiment, and grew normally.

Weights.

	cwt.	qrs.	lbs.
September 19, 1908	0	1	21
January 11, 1909	1	0	3

Total gain of weight.—2 qrs. 10 lbs.

Average rate of gain per week.—4·1 lbs.

POST-MORTEM EXAMINATION.

The carcass was in good condition.

Alimentary Tract.

Tongue, Pharynx, Palate, Tonsils.—Normal.

Submaxillary Glands.—The glands on each side contained discrete irregular caseo-calcareous tubercles and a few irregular caseo-calcareous nodules, the largest 5 mm. in diameter, composed of aggregated tubercles.

Retro-pharyngeal and Cervical Glands.—Normal.

Intestines.—Normal.

Mesenteric Glands.—The mesenteric glands were enlarged to about twice the normal size ; the glands in the posterior quarter of the mesentery were almost entirely replaced by caseo-calcareous masses which readily shelled out, leaving a thin loculated fibrous wall and a small amount of normal-looking gland tissue ; they were more severely affected than those in the anterior part, most of which had only about half their substance replaced by caseo-calcareous masses ; a few glands at the anterior end of the mesentery were of about normal size and contained discrete tubercles only.

Ileo-colic Glands. — The ileo-colic glands were slightly enlarged and beset with caseo-calcareous tubercles up to a hemp seed in size.

Colic Glands.—One colic gland contained a calcareous tubercle.

Thorax.

Lungs.—The lungs were crepitant and collapsed normally ; they showed under the pleura altogether seven tubercles ; three of these had calcareous centres, the rest were grey and translucent. No tubercles were seen on section.

Bronchial Glands.—Normal.

Heart and Pleura —Normal.

Abdomen.

Omentum and Peritoneum.—Normal.

Diaphragm.—On the peritoneal surface on the right side there was a patch of small granulations which could just be felt under the finger.

Liver.—The liver showed on the surface just under the capsule scattered grey tubercles, the largest rather more than 1 mm. in diameter, with minute calcareous centres ; altogether 25 were counted on both surfaces ; scattered tubercles were seen on section.

Portal Glands.—The portal glands were not enlarged and showed in the cortices scattered caseo-calcareous tubercles and a few small nodules up to 3 mm. in diameter composed of aggregated tubercles.

Spleen, Kidneys, and Suprarenal Bodies.—Normal.

Coeliac Glands.—The coeliac glands were not enlarged ; one contained a whitish caseous tubercle and a few minute whitish gritty foci, another a caseo-calcareous tubercle rather larger than a millet seed.

Renal, Lumbar, and Iliac Glands.—Normal.

Testicles.—Normal.

Inguinal Glands.—Normal.

PIG 135. Virus H. 100. "R.S."

Fed on alternate days for a fortnight—seven times in all—with culture derived from the original material through guinea-pig 2931.

Dose—The pig received the growth from one serum culture on each occasion.

Date of Feeding—September 19—October 1, 1908.

Killed when in good health—February 12, 1909. [146 days after feeding.]

Clinical Notes.

The pig remained well during the experiment and gained considerably in weight and size.

Weights.

	cwt.	qrs.	lbs.
September 19, 1908	0	1	25
February 12, 1909	1	2	24

Total gain of weight.—1 cwt. 0 qrs. 27 lbs.

Average rate of gain per week.—6·6 lbs.

POST-MORTEM EXAMINATION.

The carcass was fat.

Alimentary Tract.

Tongue, Pharynx and Tonsils.—Normal.

Submaxillary Glands.—One on each side was slightly enlarged and contained a moderate number of discrete caseous nodules varying from 1 to 5 mm. in diameter; they were slightly gritty from calcification and readily shelled out from normal-looking gland tissue leaving a smooth-walled cavity.

Another small gland on one side contained a millet-seed-sized tubercle.

Retro-pharyngeal and Cervical Glands.—Normal.

Intestines.—Normal.

Mesenteric Glands.—Several at the anterior end of the mesentery were normal; the glands in the posterior third were normal in size and contained a moderate number of discrete caseous gritty nodules the largest 2 or 3 mm. in diameter; the other mesenteric glands also contained caseous nodules but these varied more in size, some attaining a diameter of 7 or 8 mm. Like those in the submaxillary glands they readily shelled out from normal-looking gland tissue.

Ileo-colic Glands.—The majority were normal; two contained a few discrete tubercles.

Colic Glands.—Two tubercles were found in the colic glands.

Liver.—One minute calcareous focus was seen just under the capsule, otherwise the liver was normal.

The remaining organs and glands of the body were examined and found normal.

TABULAR SUMMARY OF THE RESULTS IN RABBITS INOCULATED WITH CULTURES DERIVED FROM ANIMALS THROUGH WHICH THE VIRUS HAD BEEN PASSED.

(1) Subcutaneous Inoculations.

Source of Culture.	Dose in Milli-grammes.	Number of Rabbit.	Weight in grammes. Initial.	Weight in grammes. Final.	Duration of Life.	Result.
			Series α.			
Calf 1419 (1st calf) Lung.	10·0 mg.	2075	1,600	1,220	Died 58 days	General tuberculosis.
	2·7 mg.	2076	1,700	1,770	Died 52 days	General tuberculosis.
Liver.	10·0 mg.	2095	1,750	1,600	Died 45 days	General tuberculosis.
	10·0 mg.	2096	1,700	1,350	Died 43 days	General tuberculosis.
	10·0 mg.	2225	1,950	1,220	Died 59 days	General tuberculosis.
			Series β.			
Calf 1409 (1st calf) Mediastinal gland.	10·0 mg.	2176	1,990	1,800	Died 51 days	General tuberculosis.
	10·0 mg.	2177	2,190	1,720	Died 73 days	General tuberculosis.
			Series γ.			
Calf 1523 (1st calf) Left bronchial gland.	10·0 mg.	2370	1,500	1,050	Died 60 days	General tuberculosis.
	10·0 mg.	2371	1,300	1,200	Died 83 days	General tuberculosis.
			Series δ.			
Rabbit 1869 (1st rabbit) Kidney.	10·0 mg.	2373	1,250	1,100	Died 36 days	General tuberculosis.
	5·0 mg.	2372	1,170	1,200	Died 84 days	General tuberculosis.

(2) Intravenous Inoculations.

			Series α.			
Calf 1419 (1st calf) Lung.	1·0 mg.	2072	2,150	1,500	Died 14 days	Acute miliary tuberculosis.
	0·1 mg.	2073	2,000	1,670	Died 18 days	Acute miliary tuberculosis.
	0·01 mg.	2074	1,950	1,470	Died 26 days	General miliary tuberculosis.
Liver.	1·0 mg.	2092	2,650	1,950	Died 13 days	Acute generalised tuberculosis.
	0·1 mg.	2093	2,550	1,800	Died 19 days	General miliary tuberculosis.
	0·01 mg.	2094	2,650	1,900	Died 32 days	General tuberculosis.

VIRUS H. 101. "E.G."

LUPUS.

VIRUS H. 101. "E.G."

CULTURE INOCULATIONS.

I.—May 22, 1908.

The strain was derived from the original material through guinea-pig 2932, and had been 56 days in artificial cultivation.

The culture used was the 4th generation, 17 days old.

CALF 1447.

Subcutaneous

Dose : 50·0 mg.

Killed : September 22, 1908.

123 days.

P.M. — Small local tumour, composed mainly of thickened skin. The left prescapular contained three pea-sized caseous nodules, the left pre-pectoral one. There was no tuberculosis elsewhere.

MONKEY 173.

Subcutaneous.

Dose : 1·0 mg.

Died : August 7, 1908.

77 days.

P.M. — Small local ulcer. Slight enlargement and caseation of two vertebral and one cervical glands. One small axillary gland was adherent to ulcerated skin and was partly caseous, another contained a caseous nodule. Half a dozen miliary caseous tubercles were seen in the lungs. The cause of death was not apparent.

GUINEA-PIGS.

Number.	Method.	Dose.	Duration of Life.	Result.
3075	Intrap.	0·1 mg.	D. 35 days	G.T.
3077	Subcut.	1·0 mg.	D. 119 „	G.T.
3076	Subcut.	0·1 mg.	D. 454 ,	Chronic G.T.

RABBITS.

Number.	Method.	Dose.	Duration of Life.	Result.
1885	Intrav.	1·0 mg.	D. 24 days	Early G.T.
1886	Intrav.	0·1 mg.	K. 144 „	Very slight T. of lungs and kidneys.
1887	Intrav.	0·1 mg.	K. 144 „	Slight T. of kidneys, and (?) T. of lungs.
1888	Subcut.	20·0 mg.	K. 144 „	Local T. One nodule in lung.
1889	Subcut.	10·0 mg.	D. 27 „	Local lesion only.

VIRUS H. 101. "E.G."

CULTURE INOCULATIONS—*continued.*

II.—August 24, 1908.

The strain was derived from the original material through guinea-pig 2932, and had been 150 days in artificial cultivation.

The culture used was the 7th generation, 11 days old.

RHESUS MONKEY 209.
Subcutaneous.
Dose : 1·0 mg.
Died : September 17, 1908.
24 days.
P.M. — Pneumonia. Local tuberculosis ; one early tubercle in liver and one in spleen.

RHESUS MONKEY 211.
Subcutaneous.
Dose : 1·0 mg.
Died : October 14, 1908.
51 days.
P.M.—Severe general tuberculosis.

RABBIT 1978.
Subcutaneous.
Dose : 57·0 mg.
Killed : 160 days.
P.M.—Small local lesion only.

CALF 1447. Virus H. 101. "E.G."

Subcutaneous inoculation of culture derived from the original material through Guinea-pig 2932.

Dose—50·0 milligrammes.

Date of Inoculation—May 22, 1908. [Age about 10 weeks.]

Killed when in good health—September 22, 1908. [123 days after inoculation.]

Clinical Notes.

The calf remained well during the experiment.

Temperature.

There was a slight rise of temperature commencing on the 9th day and lasting 14 days (maximum 40·4° C.). Subsequently the temperature was approximately normal.

Tuberculin Test.

August 18, 1908. [88 days after inoculation.] Dose, 2·0 cc. Reacted. Rise of temperature, 2·7° C.

Weights.

	cwt.	qrs.	lbs.
May 22, 1908	1	0	1
September 22, 1908	1	2	17

Total gain of weight.—2 qrs. 16 lbs.

Average rate of gain per week.—4·1 lbs.

POST-MORTEM EXAMINATION.

The carcass was in good condition.

Local Lesion.—At the seat of inoculation there was a firm tumour measuring 6 by 6 by 2 cm. ; on section it was found to consist of greatly thickened skin and subcutaneous patch of fibrous tissue ; thickened skin formed the main mass of the tumour.

Left Prescapular Gland.—The left prescapular gland measured 4·5 by 2 by 1·5 cm. and showed in the cortex three pea-sized caseous and softened nodules with fibrous walls.

Right Prescapular Gland.—The right prescapular gland measured 4·5 by 2 by 1 cm. and was normal on section.

Prepectoral Glands.—One on the left side contained a pea-sized caseous and softened nodule, the rest were normal.

Cervical and Axillary Glands.—Normal.

Thorax.

Pleura, Lungs, Heart, Thoracic Glands.—Normal.

Abdomen.

Omentum and Peritoneum.—Normal.

Spleen, Liver, Kidneys, and Suprarenal Bodies.—Normal.

Renal, Lumbar, and Iliac Glands, Portal and Coeliac Glands.—Normal.

Alimentary Tract.

Tongue, Pharynx, Tonsils.—Normal.

Submaxillary, Retro-pharyngeal, and Parotideal Glands.—Normal.

Intestines and Mesenteric Glands.—Normal.

Testicles.—Normal.

Various Lymphatic Glands.

Precrural, Popliteal, Gluteal, Ischiatic, Pudic.—Normal.

RHESUS MONKEY 173. Virus H. 101. "E.G."

(A young animal.)

Subcutaneous inoculation of culture derived from the original material through Guinea-pig 2932.

Dose—1·0 milligramme.

Date of Inoculation—May 22, 1908.

Died—August 7, 1908. [77 days after inoculation.]

Clinical Notes.

The monkey remained well and was in good condition until within a day or two of its death. The weight at death was 2050 grammes.

POST-MORTEM EXAMINATION.

The carcass was in good condition.

Local Lesion.—The skin over the posterior angle of the left scapula showed a superficial ulcer measuring 1·3 by 0·6 cm. covered with a raised mass of dried discharge. The floor of the ulcer was covered with granulation tissue and the base was formed by a thin layer of fibrous tissue. There was no sign of caseation in the base of or in the tissues around the ulcer.

Axillary Glands.—The glands on the right side were normal. The skin in the left axilla showed a small ulcer with a pale granular floor; on section a small gland was found to be adherent to the skin at this point; this gland was normal except for a thin layer of caseous material just under the granulation tissue; another gland the size of a large pea contained a softened caseous nodule 5 mm. in diameter. Other glands in the left axilla were normal.

Cervical Glands.—On the left side one behind the clavicle 1 cm. in diameter was caseous and softened throughout; the rest were normal.

Vertebral Glands.—One in the sixth and one in the eighth interspace on the left side, each the size of a split pea, were caseous and softened throughout. The rest were normal.

Thorax.

Pleura.—Normal.

Lungs.—The lungs were pinkish and crepitant. They showed in the substance just under the pleura half-a-dozen miliary caseous tubercles with grey margins. No tubercles were seen on section.

Bronchial Glands and Heart.—Normal.

Abdomen.

Omentum and Peritoneum.—Normal.

Spleen and Liver, Splenic, Portal, and Pancreatic Glands.—Normal.

Kidneys.—There was a minute greyish-white point in the cortex of one kidney. The other was normal.

Suprarenal Bodies, Lumbar and Iliac Glands.—Normal.

Alimentary Tract.

Tongue, Pharynx and Larynx, Tonsils.—Normal.

Submaxillary and Pharyngeal Glands.—Normal.

Intestines and Mesenteric Glands.—Normal.

Inguinal Glands.—Normal.

Brain.—Normal.

Microscopical Examination

Lung (tubercle).—A few tubercle bacilli seen.

Kidney (grey focus).—No tubercle bacilli.

RHESUS MONKEY 209. Virus H 101. "E.G."

(A young animal.)

Subcutaneous inoculation of culture derived from the original material through Guinea-pig 2932.

Dose—1·0 milligramme.

Date of Inoculation—August 24, 1908.

Died—September 17, 1908. [24 days after inoculation.]

Clinical Notes.

The monkey remained well until September 10. On the morning of September 11, after a cold night, it was found to be in a state of collapse. It rallied a little when the room was warmed, but sank and died on September 17 (of pneumonia). The weight at death was 1220 grammes.

POST-MORTEM EXAMINATION.

The carcass was thin.

Local Lesion.—In the subcutaneous tissues of the back over the right scapula there was a soft fluctuating swelling measuring 3 by 3 by about 1·5 cm. On section it was a thin-walled cyst filled with viscid light brownish caseo-pus.

Axillary Glands.—Two glands in the right axilla were enlarged congested and showed each an early caseous focus in the cortex.

The glands on the left side were normal.

Cervical Glands.—Normal.

Vertebral Glands.—Normal.

Thorax.

Lungs.—A right middle lobe and almost the whole of the right caudal lobe were enlarged dark red solid and airless. The ventral portions of the cephalic and the left caudal lobes were in a similar condition. The rest of the lungs was pink and crepitant. No tubercles were seen.

Bronchial Glands, Heart, Pericardium, and Pleura—Normal.

Abdomen.

Omentum and Peritoneum.—Normal.

Spleen.—The spleen was normal in size and no tubercles were seen on section. One Malpighian body seemed a little enlarged; a smear from this showed tubercle bacilli.

Liver.—One minute grey focus was seen in the substance under the capsule.

Splenic, Pancreatic, Ileo-Colic, Mesenteric, Colic, Lumbar, and Iliac Glands.—Normal.

Intestines.—Normal.

Tongue, Pharynx, Tonsils.—Normal.

Submaxillary and Retro-pharyngeal Glands.—Normal.

Inguinal Glands.—Normal.

Microscopical Examinations.

Focus from Liver.—Tubercle bacilli in moderate numbers.

Enlarged Malpighian Body from Spleen.—Tubercle bacilli in moderate numbers.

RHÉSUS MONKEY 211. Virus H. 101. "E.G."

(A young animal.)

Subcutaneous inoculation of culture derived from the original material through Guinea-pig 2932.

Dose—1·0 milligramme.

Date of Inoculation—August 24, 1908

Died—October 14, 1908. [51 days after inoculation.]

Clinical Notes.

The monkey's illness commenced about the 42nd day after the inoculation; up to this time the animal had been active and lively. The illness was of the character usually seen in monkeys suffering from acute tuberculosis; death ensued on the ninth day after the onset.

The weight at death was 1370 grammes.

POST-MORTEM EXAMINATION.

The carcass was emaciated.

Local Lesion.—The skin over the right scapula showed an ulcer 2·5 cm. in greatest diameter, the margins of which were considerably undermined especially in one direction; the floor of the ulcer was covered with brownish ill-formed pus; the base was slightly thickened and contained caseous foci.

Axillary Glands.—On the right side one the size of a sparrow's egg was caseous and softened throughout. Two smaller ones showed nearly the whole of their substance similarly caseous. The glands on the left side appeared normal.

Cervical Glands.—Two behind the right clavicle the size of small peas were caseous almost throughout; on the left side one contained a minute caseous tubercle.

Vertebral Glands.—In the second interspace on the left side there was a caseous and softened gland the size of a split pea.

There was a similar gland on the right side of the vertebral column opposite the 9th interspace.

Other vertebral glands were normal.

Thorax.

Pleura.—There was one pinhead-sized caseous tubercle on the pleura.

Lungs.—The lungs were slightly adherent to the chest wall; they were congested and showed several areas of consolidation (red hepatisation) and collapsed only partially. The parenchyma was closely beset with caseous tubercles with grey margins ranging from 1 to 2 or rather more millimetres in diameter.

Bronchial Glands.—The bronchial glands were slightly enlarged and congested and contained a small number of miliary caseous tubercles.

Ventral Mediastinal Glands.—The ventral mediastinal glands contained each several miliary caseous tubercles.

Heart and Pericardium.—Normal.

Abdomen.

Omentum and Peritoneum.—The omentum contained a moderate number of minute grey tubercles and three or four caseous tubercles the size of millet seeds.

There was one caseous tubercle and a few minute grey tubercles on the meso-colon.

Spleen.—The spleen was enlarged, measuring 6 by 3·5 by 1·5 cm., and was very closely beset with softened caseous nodules varying in diameter from 1 to 2·5 mm.

Splenic Lymphatic Glands.—Two contained each one miliary caseous tubercle, another contained about half a dozen.

Liver.—The liver was enlarged and paler than normal, and contained numerous evenly distributed caseous tubercles with grey margins ranging from about 0·5 to 1·5 mm. in diameter.

Two Glands near the head of the Pancreas were slightly enlarged, and showed their cortices beset with yellow caseous nodules.

Pyloric Gland.—The pyloric gland was enlarged, and closely beset with yellow caseous nodules.

Kidneys.—Each kidney showed in the cortex a moderate number of tubercles varying in size up to that of a millet seed; the larger ones were caseous with narrow grey margins; the smaller ones were either grey and homogeneous, or had minute opaque centres.

Lumbar Glands.—The lumbar glands were slightly enlarged, and contained altogether half a dozen miliary caseous tubercles.

Alimentary Tract.

Tongue, Pharynx, Tonsils.—Under the mucous membrane at the base of the tongue there was a small caseous tubercle. The pharynx and tonsils were normal.

Submaxillary Glands.—One on the right side contained one pinhead-sized caseous tubercle; those on the left side were normal.

Retro-pharyngeal Glands.—There was a caseous tubercle in each retro-pharyngeal gland.

Intestines.—Normal.

Mesenteric Glands.—One contained half a dozen caseous tubercles; two others contained one each.

Ileo-Colic and Colic Glands.—Normal.

Brain.—Normal.

Skull.—Scattered whitish tubercles were seen in the cancellous tissue of the parietal and frontal bones.

Microscopical Examination.

Tubercle from Tongue.—A moderate number of tubercle bacilli with extraneous organisms.

VIRUS H. 102. "N.H."

LUPUS.

VIRUS H. 102. "N.H."

LUPUS.

CULTURE INOCULATIONS.

MAY 20, 1908.

The strain was derived from the original material through Guinea-pig 2934, and had been in cultivation a total period of 62 days.

The culture used was the 3rd generation, 15 days old.

CALF 1423.

Subcutaneous.

Dose : 43·0 mg.

Killed : September 4, 1908.

107 days.

P.M.—Small cyst containing caseo-purulent clots and watery fluid at seat of inoculation. Small calcareous patch in left prescapular gland, and no tuberculosis elsewhere.

MONKEY 169.

Subcutaneous.

Dose : 1·0 mg.

Died : July 14, 1908.

55 days.

P.M.—The local tumour was composed of caseous substance in a thin fibrous wall. One axillary and one vertebral gland contained caseous tubercles, and there was one tubercle in the lung, one in the liver, and one in the spleen. There were no lesions elsewhere, and the cause of death was not ascertained.

GUINEA-PIGS.

Number.	Method.	Dose.	Duration of Life.	Result.
3057	Intrap.	0·1 mg.	D. 47 days	Slight and apparently non-progressive T. confined to the abdomen.
3056	Subcut.	1·0 mg.	D. 504 „	Chronic G. T.
3058	Subcut.	0·1 mg.	D. 462 „	Chronic G. T.

RABBITS.

Number.	Method.	Dose.	Duration of Life.	Result.
1876	Intrav.	1·0 mg.	K. 139 days	Slight T. of kidneys.
1877	Intrav.	0·1 mg.	K. 139 „	One tubercle in a kidney.
1878	Intrav.	0·01 mg.	K. 139 „	No T.
1879	Subcut.	1·0 mg.	K. 139 „	Local lesion only.
1880	Subcut.	1·0 mg.	D. 15 „	Small local lesion and no sign of tuberculosis elsewhere; slight psorospermosis of liver

VIRUS H. 102. "N.H."—*continued.*

CULTURE INOCULATIONS, AND MONKEY PASSAGE EXPERIMENT.

August 26, 1908.

The strain was derived from the original material through Guinea-pig 2934, and had been in artificial cultivation a total period of 160 days.

The culture used was the 8th generation, 13 days old.

RHESUS MONKEY 213.

Subcutaneous.

Dose : 1·0 mg.

Died : Jan. 29, 1909.

156 days.

P.M.—Chronic general tuberculosis. Death from pneumonia.

CULTURE

Derived from the lung of Monkey 213. The 4th generation of culture, 6 days old, was used for inoculation on May 6, 1909. Duration of artificial cultivation, 97 days.

MONKEY 321.

Subcutaneous

Dose : 1·0 mg.

Died : Oct. 7, 1909.

154 days.

P.M.—General tuberculosis.

MONKEY 323.

Subcutaneous.

Dose : 1·0 mg.

Died : Sept. 10, 1909.

127 days.

P.M.—General tuberculosis, very severe in spleen.

GUINEA-PIGS.

Number.	Method.	Dose.	Duration of Life.	Result.
3761	Subcut.	1·0 mg.	K. 193 days	Local T.
3762	Subcut.	1·0 mg.	K. 193 „	Slight retrogressive G. T.

RHESUS MONKEY 215.

Subcutaneous.

Dose : 1·0 mg.

Died : Feb. 25, 1909.

183 days.

P.M.—Chronic general tuberculosis, very severe on diaphragm and pleura and in spleen.

RABBITS.

Number.	Method.	Dose.	Duration of Life.	Result.
1979	Subcut.	50·0 mg.	K. 160 days	Local lesion and one tubercle in the lung.
1980	Subcut.	23·0 mg.	D. 10 „	An acute infection.

GUINEA-PIGS.

Number.	Method.	Dose.	Duration of Life.	Result.
3231	Intrap.	10·0 mg.	D. 45 days	G. T.
3230	Subcut.	10·0 mg.	D. 145 „	Chronic G. T.

A parrot was cutaneously inoculated (on October 16, 1908), with culture derived from the original material through Guinea-pig 2934. The culture used was the 14th generation, 17 days old.

PARROT 15.

Scarified behind right ear with knife dipped in turbid suspension of culture.

Killed : March 22, 1910. 522 days.

General tuberculosis ; there was no local lesion.

VIRUS H. 102. "N.H."—*continued.*

FEEDING EXPERIMENTS.

SEPTEMBER 19—OCTOBER 1, 1908.

The strain was derived from the original material through Guinea-pig 2934, and had been 184–196 days in artificial cultivation.

The cultures used were the 10th and 11th generations, from 4 to 9 days old.

PIG 137.

Fed on alternate days for a fortnight, seven times in all.

Dose: The growth from one serum culture on each occasion.

Killed: January 9, 1909. 112 days.

P.M.—There was a small grey tubercle, and an encapsuled nodule containing mortary substance, in the liver (smears, no T.B.); no sign of tuberculosis elsewhere.

PIG 139.

Fed on alternate days for a fortnight, seven times in all.

Dose: The growth from one serum culture on each occasion.

Killed: February 10, 1909. 144 days.

P.M.—One submaxillary gland contained two caseo-calcareous tubercles. There was no tuberculosis elsewhere.

DECEMBER 21, 1908.

The strain was derived from the original material through Guinea-pig 2934, and had been 277 days in artificial cultivation.

The culture used was the 14th generation, 10 days old.

RHESUS MONKEY 259.

Fed. Dose: 10·0 mg.

Died: March 4, 1909. 73 days.

P.M.—In the small intestine there were five small ulcers showing no sign of caseation, and the mesenteric glands contained scattered miliary caseous tubercles. There was no tuberculosis elsewhere. Death from ulcerative colitis.

CALF 1423. Virus H. 102. "N.H."

Subcutaneous inoculation of culture derived from the original material through Guinea-pig 2934.

Dose—43·0 milligrammes.

Date of Inoculation—May 20, 1908. [Age about 11 weeks.]

Killed when in good health—September 4, 1908. [107 days after inoculation.]

Clinical Notes.

The calf remained well during the experiment.

Temperature.

For a fortnight after the inoculation the temperature was slightly raised (maximum 40·0° C. on the 7th day); it was afterwards normal.

Tuberculin Test.

August 18, 1908. [90 days after inoculation.] Dose, 2·0 cc. Reacted. Rise of temperature, 1·9° C.

Weights.

	cwt.	qrs.	lbs.
May 20, 1908	1	0	3
September 4, 1908	1	2	5

Total gain of weight.—2 qrs. 2 lbs.

Average rate of gain per week.—3·9 lbs.

POST-MORTEM EXAMINATION.

The carcass was in good condition.

Local Lesion.—At the seat of inoculation on the left side of the neck there was a cyst measuring 5·5 by 4 by 2 cm.; it had a moderately thick fibrous wall lined internally with granulation tissue, and contained watery fluid and yellow caseo-purulent clots.

Left Prescapular Gland.—The left prescapular gland measured 5 by 2 by 1 cm., and showed in the cortex a calcareous patch the size of a split pea.

Right Prescapular Gland.—The right prescapular gland measured 5 by 2 by 1 cm., and was normal on section.

Prepectoral, Cervical, and Axillary Glands.—Normal.

Thorax.

Pleura, Lungs, Heart, Thoracic Glands.—Normal.

Abdomen.

Omentum and Peritoneum, Spleen, Liver, Kidneys, Suprarenal Bodies.—Normal.

Portal, Renal, Lumbar, and Iliac Glands.—Normal.

Alimentary Tract.

Tongue, Pharynx, Tonsils.—Normal.

Submaxillary and Retro-pharyngeal Glands.—Normal.

Intestines and Mesenteric Glands.—Normal.

Testicles.—Normal.

Various Lymphatic Glands.

Precrural, Popliteal, Gluteal, Ischiatic, Pudic.—Normal.

RHESUS MONKEY 169. Virus H. 102. "N.H."

(A young animal.)

Subcutaneous inoculation of culture derived from the original material through Guinea-pig 2934.

Dose—1·0 milligramme.

Date of Inoculation—May 20, 1908.

Died—July 14, 1908. [55 days after inoculation.]

Clinical Notes.

The monkey had been in good health, active and lively, until three days before death. There were no definite symptoms; the monkey was quiet, refused food, and remained crouching in a corner of its cage; it rapidly sank, and died on the 55th day after inoculation.

Weight.

At death—1620 grammes.

POST-MORTEM EXAMINATION.

The carcass was in fair condition.

Local Lesion.—Over the last few ribs on the left side there was a raised circumscribed tumour measuring 3·5 by 2·5 by 1 cm., the skin over the anterior end of which was thin and sbowed several small ulcers exposing softened caseous substance. On section the tumour was composed of yellow breaking down caseous substance surrounded by a thin wall of fibrous tissue.

Axillary Glands.—On the left side one contained half a dozen caseous tubercles, the largest a millimetre in diameter; others on this side and those on the right were normal.

Vertebral Glands.—A vertebral gland in the tenth interspace on the left side was slightly enlarged and contained a softened caseous nodule about 2 mm. in diameter; the rest were normal.

Thorax.

Lungs.—Both lungs showed in the thin ventral portions of all the lobes irregular dark red patches of collapse. There was a large patch of collapse on the diaphragmatic surface of the left caudal lobe.

There was one minute grey tubercle under the pleura of one of the caudal lobes.

Bronchial Glands, Heart and Pericardium, Pleura.—Normal.

Abdomen.

Omentum and Peritoneum.—Normal.

Liver.—The liver showed just under the capsule one yellow caseous tubercle a millimetre in diameter; none was seen in the depth.

Spleen.—The spleen was normal in size; in the pulp there was one greyish-white millet-seed sized tubercle.

Portal, Splenic, Lumbar, and Iliac Glands.—Normal.

Kidneys and Suprarenal Bodies.—Normal.

Alimentary Tract.

Tongue, Pharynx, Tonsils.—Normal.

Submaxillary and Pharyngeal Glands.—Normal.

Intestines.—Normal.

Mesenteric and Ileo-Colic Glands.—The mesenteric and ileo-colic glands were slightly congested and appeared a little enlarged but were not otherwise abnormal.

Brain.—Normal.

Inguinal and Cervical Glands.—Normal.

Microscopical Examination.

Tubercle from Lung.—Tubercle bacilli numerous.

Tubercle from Spleen.—Tubercle bacilli numerous.

Tubercle from Liver.—Tubercle bacilli numerous.

RHESUS MONKEY 213. Virus H. 102. "N.H."
(A young animal.)

Subcutaneous inoculation of culture derived from the original material through Guinea-pig 2934.

Dose—1·0 milligramme.

Date of Inoculation—August 26, 1908.

Died—January 29, 1909. [156 days after inoculation.]

Clinical Notes.

The monkey was ill for a fortnight before death; it lost its appetite and became thin and very weak; the respirations were laboured and difficult.

The weight at death was 1500 grammes.

Pneumonia was the immediate cause of death.

POST-MORTEM EXAMINATION.

The carcass was emaciated.

Local Lesion.—The local lesion consisted of a number of softened and caseous nodules in the muscles over the right scapula; they covered an area measuring 2·5 by 2·5 cm. The skin over them was adherent puckered and showed two or three small openings though which caseo-pus could be expressed.

Axillary Glands.—On the right side there were five caseous and softened glands the largest the size of a thrush's egg.

The glands on the left side were normal.

Cervical Glands.—In the right posterior triangle there were two completely caseous and softened glands, the largest rather more than 1 cm. in diameter. Other cervical glands were normal.

Vertebral Glands.—On the right side extending from the lower margin of the 6th to the upper margin of the 8th rib near the vertebral column there was a caseous and softened mass 1·5 cm. in greatest diameter.

Thorax.

Each pleural cavity contained about 15·0 cc. of clear fluid.

Lungs.—Much of the left caudal lobe, more than half of the left cephalic lobe, and the right middle lobe were reddish oedematous and airless. The right caudal and right cephalic lobes were also extensively consolidated but contained more crepitant lung tissue than the left.

The lung parenchyma contained scattered caseous and softened nodules, with thin fibrous walls, the largest 5 mm. in diameter; fifteen nodules were counted in all the lobes.

In the right middle lobe there was a mass 1 cm. in diameter composed of aggregated nodules.

Bronchial Glands. — On the right side one praetracheo-bronchial gland contained a caseous and softened nodule 5 mm. in diameter. On the left side an oval gland 1 cm. in length was caseous throughout, another contained two caseous tubercles.

One of the intertracheo-bronchial glands was much enlarged measuring 1·3 cm. in greatest length and was caseous and softened throughout, the rest were normal.

Heart and Pleura.—Normal.

Abdomen.

Omentum. — The omentum showed a moderate number of grey translucent pearly tubercles, the largest less than a millimetre in diameter.

Parietal Peritoneum.—Normal.

Spleen.—The spleen measured 4 by 1·5 by 1 cm., and was very little enlarged. It contained altogether about twenty yellow softened caseous nodules, ranging up to 6 or 7 mm. in diameter; several projected prominently from the surface, and at one extremity there was a group which had become confluent.

Splenic Lymphatic Glands.—Normal.

Liver.—The liver was pale and contained scattered caseous and softened encapsuled nodules, varying from 1·5 to 5 mm. in diameter. Fifteen were counted on the surface under the capsule, and there were a few in the depth; there were besides a few minute caseous tubercles less than 1 mm. in diameter.

Kidneys.—The cortex of the left kidney contained one caseous tubercle with grey margins, 2 mm. in diameter.

In the cortex of the right kidney there were two caseous and softened nodules, one 4 mm., the other 2·5 mm., in diameter.

Suprarenal Bodies.—Normal.

Pancreatic, Lumbar, and Iliac Glands.—Normal.

Intestines.—Normal.

Mesenteric, Ileo-Colic, and Colic Glands.—Normal.

Brain.—On the outer surface of the left hemisphere of the cerebrum, about its middle, there was a softened caseous area, 2·5 cm. in length and 0·8 cm. in breadth; it projected from the surface and its capsule was adherent to the dura mater; on section it was found to involve only the grey matter which in this area was replaced by caseo-pus in nearly its whole thickness.

There was a caseating nodule in the grey matter of the left temporo-sphenoidal lobe.

Tongue, Pharynx, Tonsils.—Normal.

Submaxillary and Retropharyngeal Glands.—Normal.

Inguinal Glands.—Normal.

Microscopical Examination.

Emulsion of nodules from Lung.—A few tubercle bacilli seen.

Caseo-pus from the Brain. — (1) No tubercle bacilli seen. (2) Three tubercle bacilli seen after a prolonged search.

RHESUS MONKEY 215. Virus H. 102. "N.H."
(A young animal.)

Subcutaneous inoculation of culture derived from the original material through Guinea-pig 2934

Dose—1·0 milligramme.

Date of Inoculation—August 26, 1908.

Died—February 25, 1909. [183 days after inoculation.]

Clinical Notes.

The monkey died after a month's illness, characterised by loss of appetite, progressive weakness and emaciation. The weight at death was 1550 grammes.

POST-MORTEM EXAMINATION.

The carcass was emaciated.

Local Lesion.—The skin over the right scapula showed a small healing ulcer covered with a dry scab through the floor of which projected soft caseous substance, in the subcutaneous tissues beneath there was a flat caseous patch measuring 3·5 by 2 by 0·5 cm.; in the muscles of the right scapula there were eight caseous and softened nodules the largest the size of a large pea.

Axillary Glands.—In the right axilla there was a group of four or five enlarged fused glands, all of which were caseous throughout.

In the left axilla there were three slightly enlarged glands, each of which contained a caseous nodule.

Cervical Glands.—In the right posterior triangle there were three softened and caseous glands ranging from 8 to 10 mm. in diameter; in the left posterior triangle there were three caseous glands, the largest the size of a pea.

Sternal Glands.—The sternal glands were enlarged and caseous throughout.

Vertebral Glands.—One on the right side was enlarged and caseous throughout; the rest were normal.

Thorax.

Pleura and Diaphragm.—The left lung was intimately adherent to the diaphragm, and was removed from it only with difficulty; it was adherent also though less intimately to almost the whole of the costal pleura. The left half of the diaphragm was much thickened in one place, measuring 5 mm. in diameter, and was composed throughout its whole thickness of caseous tuberculous tissue; the peritoneum covering it was free except at one spot where the caseous substance had penetrated and was adherent to the liver.

The costal pleura on the left side except for a small patch near the vertebral column and the anterior end of the thorax, was covered with caseating tubercuous plaques.

The costal pleura on the right side showed between the costal cartilages four caseous nodules, the largest the size of a hemp seed.

Lungs.—The left lung was crepitant and covering it was a thick fibrinous membrane which could be pulled off; on section it contained scattered firm caseous nodules the largest 5 mm. in diameter.

The right lung was also crepitant throughout and contained rather more numerous nodules than the left. In the posterior part of the caudal lobe there was besides the small nodules a firm caseous nodule 12 mm. in diameter.

Bronchial Glands.—The bronchial glands were enlarged, the intertracheo-bronchial being caseous practically throughout; the praetracheo-bronchial contained each two or three softened caseous nodules.

Heart.—Normal.

Abdomen.

Omentum.—The omentum contained a moderate number of translucent grey tubercles, the largest 1 mm. in diameter and one caseous nodule 3 mm. in diameter.

Parietal Peritoneum.—Normal.

Spleen.—The spleen was enormously enlarged and firmly adherent to the ribs and the peritoneum covering the left kidney; it measured 9 by 5 by 3·5 cm. and felt soft and fluctuant throughout; the capsule was thickened, and there were several yellow nodules projecting through it. On section it was found to be composed throughout of large softened yellow caseous nodules, the largest more than 1 cm. in diameter; in many places they had coalesced, and in others they were separated only by their capsules or a thin layer of reddish tissue, which was apparently all that remained of the spleen pulp.

Liver.—The liver contained a moderate number of yellow caseous and softened nodules varying in diameter from 2 to 8 mm.; there were besides scattered tubercles the largest the size of a millet seed caseous in the centre.

A gland on the head of the pancreas contained four caseous nodules the largest the size of a hemp seed, two others each contained one small caseous nodule.

Kidneys.—The right kidney showed in the cortex three yellow caseous nodules 5 to 7 mm. in diameter; in the cortex of the left kidney there were four yellow caseous nodules the largest 6 mm. in diameter and one grey tubercle.

Suprarenal Bodies.—Normal.

Lumbar and Iliac Glands.—The lumbar glands were enlarged, fused together and caseous throughout. One iliac gland the size of a pea was caseous throughout.

Alimentary Tract.

Tongue, Pharynx, Tonsils, and Pharyngeal Glands.—Normal.

Submaxillary Glands.—On the left side two contained each one millet-seed sized caseous tubercle.

Intestines.—Normal.

Gastric Glands.—One at the cardiac end of the stomach contained a hemp-seed sized caseous nodule, one at the pyloric end contained a millet-seed sized caseous tubercle.

Mesenteric and Ileo-colic Glands.—Normal.

Colic Glands.—Three at the beginning of the ascending colon were enlarged and caseous. Two of these were adherent to the wall of the colon.

Brain.—Normal.

Muscles.—In the left thigh muscles there was a caseous and softened nodule the size of a kidney bean.

There was a pea-sized caseous nodule in the left pectoral muscle.

RRESUS MONKEY 259. Virus H. 102. "N.H."

(A young animal.)

Fed once with culture derived from the original material through Guinea-pig 2934.

Dose—10·0 milligrammes.

Date of Feeding—December 21, 1908.

Died—March 4, 1909. [73 days after feeding.]

Clinical Notes.

The dose was administered with a catheter; the monkey vomited immediately afterwards.

The monkey remained well until the end of February, 1909, when it lost appetite, looked ill and depressed, and sank and died within a week.

The weight at death was 1250 grammes.

POST-MORTEM EXAMINATION.

Death from ulcerative colitis.

Intestines.—The mucous membrane of the small intestine showed five small ulcers with slightly pigmented thickened bases showing no sign of caseation.

The mucous membrane of the caecum was extensively ulcerated, the floors of the ulcerated areas being congested and covered with yellow necrotic shreds; the upper part of the colon was also ulcerated and its walls thickened and contracted; there were small ulcers all the way down the large intestine.

Mesenteric Glands.—The mesenteric glands were not enlarged; they showed in the cortex scattered caseous tubercles varying up to a millet seed in size.

The Ileo-colic and Colic Glands were normal.

There was no tuberculosis elsewhere.

RHESUS MONKEY 321. Virus H. 102. "N.H."

(A young animal.)

Subcutaneous inoculation of culture derived from the lung of Monkey 213.

Dose—1·0 milligramme.

Date of Inoculation—May 6, 1909.

Died—October 7, 1909. [154 days after inoculation.]

POST-MORTEM EXAMINATION.

The carcass was thin. Its weight was 2300 grammes.

Local Lesion.—The skin in the right axillary line near the margin of the thorax showed a small ulcer covered with a dry scab; in the subcutaneous tissues beneath this there was a small collection of caseo-pus; between this and the spinous processes of the vertebrae there was a moderately large scar in the skin at the site of inoculation of the culture. Between the muscles under this scar were two caseous nodules.

Axillary Glands.—The glands on the right side were slightly enlarged and deeply congested but two only contained each one millet-seed sized caseous tubercle. The glands on the left side were deeply congested but free from tubercles.

The Cervical and other glands in the neck appeared normal.

Vertebral Glands.—On the right side the glands in the 9th and 10th interspaces were much enlarged caseous and softened throughout; one on the left side in the 10th interspace the size of a split pea was partly caseous.

Thorax.

Lungs.—The lungs were voluminous and contained altogether a dozen irregular solid masses the largest 3 cm. in greatest diameter; there were four in the right caudal lobe two in the right middle and six in the lobes on the left side; on section they were composed practically throughout of breaking-down caseous substance surrounded by reddish consolidated lung tissue; scattered about in the rest of the lung tissue which was crepitant were caseous nodules ranging from a millet to a hemp seed in size.

The right caudal lobe of the lung was adherent to the enlarged vertebral glands.

Bronchial Glands.—The bronchial glands were greatly enlarged caseous and softened throughout.

Abdomen.

Omentum.—The omentum contained scattered translucent grey tubercles and three or four caseous nodules up to a hemp seed in size.

Peritoneum.—There were a few caseous and softened nodules on the mesentery and a few scattered about in the subperitoneal tissues of the abdominal wall.

Spleen.—The spleen was only slightly enlarged measuring 5·5 by 3 by 1·5 cm.; the pulp contained a moderate number of caseo-purulent nodules ranging up to a pea in size; the majority were large.

Liver.—The liver was normal in general appearance and contained sparsely scattered caseous nodules and tubercles; half a dozen nodules ranging from a hemp seed to a pea in size were seen under the capsule and one or two similar ones were seen on section. Under the capsule as well as in the depth there were scattered caseous tubercles, the largest 1 mm. in diameter.

The glands on the head of the pancreas were normal in size, one contained a caseous and softened nodule 2 mm. in diameter.

Kidneys.—The left kidney showed in the cortex two caseous tubercles 1 and 2 mm. in diameter and two minute grey tubercles. In the cortex of the right there were half a dozen caseous nodules ranging in size from a millet seed to a large pea.

Brain.—The cortex of the cerebrum on the right side showed on the surface three caseous and softened nodules the largest 5 mm. in diameter.

On the left side there was one hemp-seed sized caseous nodule on the surface and one in the depth of the cortex. In the island of Reil on the left side there was a large caseous nodule, 1 cm. in diameter, softened and haemorrhagic in the centre; it was situated partly in the cortex and partly in the white matter of the lobe.

The remaining organs and glands were free from tuberculous lesions.

RHESUS MONKEY 323. Virus H. 102. "N.H."

(A young animal.)

Subcutaneous inoculation of culture derived from the lung of Monkey 213.

Dose—1·0 milligramme.

Date of Inoculation—May 6, 1909.

Died—September 10, 1909. [127 days after inoculation.]

POST-MORTEM EXAMINATION.

The carcass was emaciated. Its weight was 1700 grammes.

Local Lesion.—The skin on the right side over the posterior ribs showed a healing ulcer with granular floor; on reflecting the skin, two or three caseous nodules were seen in the intercostal muscles.

Axillary Glands.—On the right side there were two caseous and softened masses each about the size of a thrush's egg, and one pea-sized caseous gland. On the left side there was one pea-sized caseous gland.

Cervical Glands.—Three in the right posterior triangle each contained one hemp-seed sized caseous nodule; on the left side there were two millet-seed sized caseous tubercles.

Vertebral Glands.—On the right side, extending from the 7th to the 10th interspaces there was a prominent fluctuating tumour the size of a pigeon's egg filled with softened caseous substance.

Under the costal pleura near this tumour there were ten caseous and softened nodules arranged along the last three ribs. They appeared to have arisen under the periosteum, for the surface of the ribs from which they projected was rough.

One vertebral gland on the left side in the 10th interspace, the size of a split pea, was caseous throughout.

Thorax.

Lungs.—The right lung was very adherent to the enlarged vertebral glands, and the pleura in several places was thickened. The lung parenchyma, except for the posterior part of the right caudal lobe which was collapsed, was crepitant and contained moderately numerous evenly distributed yellow caseous nodules ranging up to 4 mm. in diameter.

Bronchial Glands.—The bronchial glands were moderately enlarged and showed their substance almost completely replaced by caseous and softened nodules.

Pleura and Heart.—Normal.

Abdomen.

Omentum and Peritoneum.—There were two caseous and softened nodules twice the size of a hemp seed in the omentum and one on the mesentery. The parietal peritoneum was normal.

Spleen.—The spleen was greatly enlarged measuring 8 by 5 by 3 cm. and was packed almost as closely as possible with softened yellow caseous nodules, the largest 5 mm. in diameter.

The splenic lymphatic glands contained about half-a-dozen caseous tubercles.

Liver.—The liver was normal in colour and showed fairly numerous evenly distributed submiliary caseous tubercles with grey margins; here and there was a caseous tubercle the size of a millet seed.

The gland on the head of the pancreas was enlarged and oedematous and showed irregular caseous nodules arranged around the cortices.

Kidneys.—The left kidney showed in the cortex about a dozen yellow caseous and softened nodules ranging from 1 to 3·5 mm. in diameter.

Sixteen similar nodules were counted in the right kidney.

Suprarenal Bodies.—Normal.

Lumbar Glands.—These contained two pea-sized caseous and softened nodules and one tubercle.

Alimentary Tract.

Tongue, Pharynx, Tonsils.—Normal.

Submaxillary Lymphatic Glands.—One contained a caseous nodule 2·5 mm. in diameter; there was a similar nodule in one of the submaxillary salivary glands.

Other glands in the neck were normal.

Intestines.—Three caseous and softened nodules each about twice the size of a hemp seed were seen in the wall of the large intestine.

The small intestine was normal.

Mesenteric and Ileo-colic Glands.—One mesenteric gland contained a millet-seed sized caseous tubercle.

One ileo-colic gland contained a hemp-seed sized caseous nodule.

Inguinal Glands.—The right contained two millet-seed sized caseous tubercles. The left contained two hemp-seed sized caseous nodules.

Skull.—Under the dura mater of the vault of the skull there were half-a-dozen caseous tubercles the bone beneath which was eroded.

Brain.—In the white matter of the right occipital lobe there was a pea-sized yellow caseous nodule.

Under the periosteum of the jaw-bone on the right side there was a hemp-seed sized caseous nodule.

Microscopical Examination.

Smear from Brain nodule.—Moderately numerous tubercle bacilli.

PIG 137. Virus H. 102. "N.H."

Fed on alternate days for a fortnight—seven times in all—with culture derived from the original material through Guinea-pig 2934.

Dose—The pig received the growth from one serum tube on each occasion.

Date of Feeding—September 19—October 1, 1908. [Age 16 weeks.]

Killed when in good health—January 9, 1909. [112 days after feeding.]

Clinical Notes.

The pig remained well during the experiment and grew normally.

Weights.

	cwt.	qr.	lbs.
September 19, 1908	0	1	12
January 9, 1909	1	0	0

Total gain of weight.—2 qrs. 16 lbs.

Average rate of gain per week.—4·5 lbs.

POST-MORTEM EXAMINATION.

The carcass was in good condition.

Alimentary Tract.

Tongue, Pharynx, Tonsils; Submaxillary, Retro-pharyngeal and Parotideal Glands; Intestines; Mesenteric, Ileo-Colic and Colic Glands.—Normal.

Thorax.

Pleura, Lungs, Heart, Thoracic Glands.—Normal.

Abdomen.

Omentum and Peritoneum; Spleen, Kidneys and Suprarenal Bodies; Portal, Renal, Lumbar and Iliac Glands.—Normal.

Liver.—Under the capsule there was a small soft grey tubercle and a hemp-seed sized encapsuled nodule containing dry mortary substance; the liver was otherwise normal.

Microscopical Examination.

Tubercle from Liver.—No tubercle bacilli seen.

Nodule from Liver.—No tubercle bacilli seen.

PIG 139. Virus H. 102. "N.H."

Fed on alternate days for a fortnight—seven times in all—with culture derived from the original material through Guinea-pig 2934.

Dose—The pig received the growth from one serum tube on each occasion.

Date of Feeding—September 19—October 1, 1908. [Age 16 weeks.]

Killed when in good health—February 10, 1909. [144 days after feeding.]

Clinical Notes.

The pig remained well during the experiment and grew normally.

Weight.

	cwt.	qr.	lbs.
September 19, 1908	0	1	25
February 10, 1909	1	2	17

Total gain of weight.—1 cwt. 0 qr. 20 lbs.

POST-MORTEM EXAMINATION.

The carcass was in good condition.

Alimentary Tract.

Submaxillary Glands.—One on the left side contained two pinhead-sized caseo-calcareous tubercles. Those on the right side were normal.

Retro-pharyngeal Glands; Tongue, Pharynx, Tonsils; Intestines and Mesenteric Glands.—Normal.

Abdomen.

Peritoneum, Spleen, Kidneys and Suprarenal Bodies.—Normal.

Liver.—Under the capsule of the liver two pinhead-sized grey fibrous homogeneous tubercles were seen; they were not apparently of a tuberculous nature.

The remaining organs and glands were examined and found normal.

VIRUS H. 103. "N.S."

LUPUS.

VIRUS H. 103. "N.S."

CULTURE INOCULATIONS.

I.—April 28, 1908.

The strain was derived from the original material through Guinea-pig 2940 (coeliac gland), and had been in cultivation a total period of 36 days.

The culture used was the third generation, 14 days old.

RABBITS.

Number.	Method.	Dose.	Duration of Life.	Result.
1840	Intrav.	1·0 mg.	K. 160 days	Miliary T. of lungs and kidneys (retrogressive).
1841	Intrav.	1·0 mg.	D. 13 „	Early T. of lungs. Death from injuries.

GUINEA-PIGS

Number.	Method.	Dose.	Duration of Life.	Result.
3035	Intrap.	1·0 mg.	D. 46 days	G. T.
3036	Subcut.	1·0 mg.	D. 129 „	G. T.

II.—May 20, 1908.

The strain was derived from the original material, through G.P. 2938, and had been in artificial cultivation a total period of 70 days.

The culture used was the 7th generation, 13 days old.

MONKEY 171.

Subcutaneous.

Dose : 1·0 mg.

Died : September 8, 1908.

111 days.

P.M.—General tuberculosis severe in lungs.

GUINEA-PIGS.

Number.	Method.	Dose.	Duration of Life.	Result.
3059	Intrap.	1·0 mg.	D. 142 days	Very slight G.T. insufficient to account for death.
3060	Subcut.	1·0 mg.	D. 134 „	G. T.

RABBITS.

Number.	Method.	Dose.	Duration of Life.	Result.
1881	Intrav.	1·0 mg.	D. 22 days	G. T.
1882	Intrav.	0·1 mg.	K. 138 „	Slight T. of lungs, kidneys, and mammary gland.
1883	Subcut.	31·0 mg.	K. 138 „	Local lesion only.
1884	Subcut.	10·0 mg.	K. 138 „	Local lesion only.

VIRUS H. 103. "N.S."—*continued.*

CULTURE INOCULATIONS—*continued.*

II.—May 20, 1908.

The strain was derived from the original material, through G.P. 2940, and had been in artificial cultivation a total period of 58 days.
The culture used was the 5th generation, 13 days old.

CALF 1457.

Subcutaneous.

Dose : 88·0 mg

Killed : September 4, 1908.

107 days.

P.M.—There was a small local tumour composed of thickened skin, fibroid tissue, and a very small cavity communicating with the exterior by a sinus and containing caseo-pus ; no tuberculosis elsewhere.

III.—September 2, 1908.

The strain was derived from the original material, through G.P. 2938, and had been 175 days in artificial cultivation.

The culture used was the 13th generation, 20 days old.

GUINEA-PIGS.

Number.	Method.	Dose.	Duration of Life.	Result.
3263	Subcut.	10·0 mg.	D. 106 days	G. T.
3262	Subcut.	1·0 mg.	D. 193 ,,	G. T.

RHESUS MONKEY 217.

Subcutaneous.

Dose : 1·0 mg.

Died : December 13, 1908.

102 days.

P.M.—There was an ulcer with caseo-necrotic floor at the seat of inoculation, and the adjacent glands were moderately enlarged caseous and softened ; four glands in the thorax and a pancreatic gland were similarly affected. The spleen contained scattered grey miliary tubercles, and about half-a-dozen caseous tubercles were seen in each kidney. The mesenteric glands contained scattered caseous tubercles. T.B. were seen in a smear from the mucous membrane of the small intestine. Death was probably due to cold.

CALF 1457. Virus H. 103. "N.S."

Subcutaneous inoculation of culture derived from the original material through Guinea-pig 2940.

Dose—88·0 milligrammes.

Date of Inoculation—May 20, 1908. [Age about 10 weeks.]

Killed when in good health—September 4, 1908. [107 days after inoculation.]

Clinical Notes.

The calf remained well during the experiment.

Temperature.

Approximately normal throughout.

Tuberculin Test.

August 18, 1908. [90 days after inoculation.]
Dose 2·0 cc. Reacted. Rise of temperature 1·8° C.

Weights.

	cwt.	qrs.	lbs.
May 20, 1908	1	0	6
September 4, 1908	1	3	5

Total gain of weight.—2 qrs. 27 lbs.

Average rate of gain per week.—5·5 lbs.

POST-MORTEM EXAMINATION.

The carcass was in good condition.

Local Lesion.—On the left side of the neck there was a small firm tumour measuring 5 by 3·5 by 2 cm.; it consisted of thickened skin and a subcutaneous mass of brownish translucent fibroid tissue showing in the centre a very small cavity containing caseo-pus; the fibroid tissue around the cavity showed indefinite yellow streaks. There was a funnel-shaped depression in the skin, filled with caseo-pus, which communicated with the cavity in the tumour.

Left Prescapular Gland.—The left prescapular gland measured 4·9 by 2·5 by 1·3 cm. and appeared normal on section.

Right Prescapular Gland.—The right prescapular gland measured 4·5 by 1·9 by 1 cm. and was normal on section.

Prepectoral, Cervical and Axillary Glands.—Normal.

The remaining glands and all the organs were normal.

RHESUS MONKEY 171. Virus H. 103. "N.S."

(A young animal.)

Subcutaneous inoculation of culture derived from the original material through Guinea-pig 2938.

Dose—1·0 milligramme.

Date of Inoculation—May 20, 1908.

Died—September 8, 1908. [111 days after inoculation.]

Clinical Notes.

The monkey appeared in good health until the last week of August, when he began to look ill and to sit huddled up in a corner of his cage. He then lost his appetite and grew thin and weak, and on the morning of September 8 he died.

The weight at death was 1350 grammes.

POST-MORTEM EXAMINATION.

The carcass was thin.

Local Lesion.—The skin over the left scapula showed a shallow ulcer concealed by a scab composed of hair matted together with discharge; in the muscles just under the ulcer, as well as immediately around it, there were several caseo-purulent nodules.

Axillary Glands.—On the left side one of the glands was adherent to the skin, which was ulcerated; this gland was a little more than 1 cm. in diameter, was fibrous, and showed an irregular cavity in its interior containing a small quantity of caseo-pus. Another gland near the above contained four softened caseous tubercles; two others at the apex of the axilla contained a few softened caseous nodules.

The glands on the right side contained three softened caseous nodules ranging in size from a millet to a hemp seed.

Cervical Glands.—The left posterior triangle was filled with a collection of enlarged soft and fluctuating glands, one larger than a pigeon's egg; they all had thin walls and creamy caseo-purulent contents. Other cervical glands were normal.

Submaxillary Glands.—The submaxillary glands on both sides were enlarged and contained soft and caseous nodules.

Vertebral Glands.—On the left side of the thorax extending from the middle of the vertebræ on to the ribs there was a large thin walled lobulated mass measuring 4 by 2·5 by 2 cm.; this on section was found to be filled with caseo-pus.

Thorax.

Lungs.—The right lung was crepitant and collapsed normally, and had no adhesions. It contained sparsely scattered shotty tubercles, the largest the size of a millet seed. Some of the smallest tubercles were grey and homogeneous, but the rest had caseous centres.

The left lung was firmly adherent along its dorsal border to the enlarged vertebral glands.

All the lobes of the left lung were enlarged firm very dark red and almost completely airless. The caudal lobe was the most firmly adherent to the vertebral glands, and could not be separated without tearing the lung tissue. On section this lobe was composed of firm grey slightly pigmented solid tissue, showing close to its adhesion to the vertebral glands softened caseous patches and elsewhere slightly opaque yellowish areas of early caseation. The anterior lobes showed on section greyish areas, some of which were caseous in the centre, embedded in red collapsed tissue.

Bronchial Glands.—The bronchial glands on the right side were only very slightly enlarged, and contained two miliary caseous tubercles. Those on the left side were distinctly enlarged, particularly the intertracheo-bronchial; they however contained only a few caseous tubercles.

Heart.—Normal.

Abdomen.

Omentum and Peritoneum.—Normal.

Spleen.—The spleen was perhaps slightly enlarged, measuring 5 by 2·5 by 1 cm. and showed in the pulp a moderate number of yellow caseous and softened nodules ranging in size from 2 up to 4 mm.

Splenic Glands.—Three of the splenic lymphatic glands each contained one or two small caseous tubercles.

Liver.—The liver was normal in general appearance; it showed just under the capsule three grey miliary tubercles with opaque centres; no tubercles were seen on section of the liver.

Portal Gland.—There was a small gland in the hilum of the liver which contained a millet-seed sized caseous tubercle.

Pancreatic Gland.—The gland on the head of the pancreas contained three caseous softened nodules, the largest measuring 3 mm. in diameter.

The gland near the pylorus contained a millet-seed sized and a pinhead-sized caseous tubercle.

Kidneys.—The kidneys were pale; each showed on the surface as well as in the depth a moderate number of miliary tubercles with yellow caseous centres and grey margins, in one there was also a yellow caseous nodule a little more than 3 mm. in diameter.

Suprarenal Bodies.—Normal.

Lumbar and Iliac Glands.—Two lumbar glands contained each two miliary caseous tubercles.

The iliac glands were normal.

Alimentary Tract.

Tongue, Pharynx, Tonsils.—Normal.

Retro-pharyngeal Glands.—Normal.

Intestines.—Normal.

Mesenteric Glands.—The mesenteric glands were

slightly enlarged and showed in the cortices discrete caseous tubercles and soft caseous patches.

Ileo-Colic Glands.—The ileo-colic glands together contained three caseous tubercles up to a hemp seed in size.

Colic Glands.—Several of the colic glands were enlarged, the largest being the size of a pea ; some were caseous almost throughout, others contained discrete caseous tubercles of various sizes.

Brain.—Normal.

Inguinal Glands.—The inguinal glands contained softened caseous nodules.

RHESUS MONKEY 217. Virus H. 103. "N.S."

(A young animal.)

Subcutaneous inoculation of culture derived from the original material through Guinea-pig 2938.

Dose—1·0 milligramme.

Date of Inoculation—September 2, 1908.

Died—December 13, 1908. [102 days after inoculation.]

Clinical Notes.

The monkey remained well and lively until the beginning of December, when it lost its appetite and became quiet and depressed. Weakness and emaciation followed and during the last few days of life the respirations were increased in frequency. The animal died on December 13. It was kept in a house which was not artificially heated, and death was probably hastened by cold.

Weight at death—1600 grammes.

POST-MORTEM EXAMINATION.

The carcass was emaciated.

Local Lesion.—The skin over the right scapula showed an ulcer measuring 2·5 cm. in diameter with raised undermined margins and floor covered with masses of caseo-necrotic substance. The ulcer was completely covered by a large raised dry caseous scab. The base of the ulcer was caseous and was adherent to the aponeurosis of the muscles but did not infiltrate them.

Axillary Glands.—On the right side two glands one 1·5 cm. in diameter, the other rather smaller, were caseous and softened practically throughout. Two others were slightly enlarged but were not caseous.

The glands on the left side appeared normal.

Cervical Glands.—Behind the right clavicle there was a gland the size of a pea which was caseous throughout.

Two smaller glands under the trapezius were partly caseous.

On the left side there was one pea-sized caseous gland behind the clavicle.

Other glands in the neck were normal.

Vertebral Glands.—On the right side one in the 6th and one in the 7th interspaces were enlarged, the largest being the size of a pea, and were caseous throughout.

Other vertebral glands were normal.

Thorax.

Lungs.—The lungs were pink and crepitant and collapsed normally. No definite tubercles were seen either on the surface or on section, but on the surface under the pleura there was a few minute grey points.

Bronchial Glands.—The right praetracheo-bronchial gland was normal ; the left contained a miliary caseous tubercle.

The intertracheo-bronchial gland on the left side was moderately enlarged and caseous practically throughout.

Heart, Pericardium and Pleura.—Normal.

Ventral Mediastinal Glands.—Two glands on the left side just above the manubrium the size of large peas were caseous practically throughout.

Trachea.—Normal.

Abdomen.

Omentum, Peritoneum, Mesentery.—Normal.

Spleen.—The spleen was normal in size dark red in colour and showed in the pulp scattered greyish miliary tubercles.

The splenic lymphatic glands were slightly enlarged but showed no sign of caseation.

Liver.—The margins of the lobules were outlined by yellow fatty foci. Three or four doubtful grey foci were seen but there was nothing of a definitely tuberculous nature.

The gland on the head of the pancreas was moderately enlarged and showed the cortex extensively replaced by caseous nodules the largest the size of a hempseed.

Kidneys.—The left kidney showed in the cortex on the surface one pinhead-sized softened caseous tubercle. On section four small caseous tubercles were seen in the depth of the cortex.

The right kidney showed two caseous tubercles on the surface and eight in the depth of the cortex.

Alimentary Tract.

Tongue, Pharynx, Tonsils.—Normal.

Intestines.—Normal.

Mesenteric Glands.—The mesenteric glands were normal in size and contained scattered caseous tubercles.

Brain and Bones of the Skull.—Normal.

Microscopical Examinations.

Emulsion of Axillary Gland.—Exceedingly numerous tubercle bacilli.

Smear from an Emulsion of Spleen Pulp.—Tubercle bacilli occurring in scattered clumps, some of the clumps containing a large number of individuals.

Smear from a Spleen Tubercle.—Numerous tubercle bacilli.

Smear from the Splenic Gland.—No tubercle bacilli.

Smear from the Liver Substance.—A few tubercle bacilli.

Scraping from Mucous Membrane of Small Intestine.—Scattered small clumps of tubercle bacilli.

Caseous focus from Mesenteric Gland.—Very numerous tubercle bacilli.

VIRUS H. 105. "G.S."

LUPUS.

VIRUS H. 105. "G.S."

CULTURE INOCULATIONS, AND PASSAGE EXPERIMENT I.

The strain was derived from the original material through Guinea-pig 2950, and was inoculated on May 22, 1908, when it had been 60 days in artificial cultivation. The culture used was the 5th generation, 17 days old.

CALF 1449.
Subcutaneous.
Dose : 48·0 mg.
Killed : September 29, 1908.
130 days.
P.M. — Generalised tuberculosis not severe.
Fibrous - walled cyst ; left prescapular gland caseous and softened. A very few tubercles mostly small and calcareous in lungs and spleen, one in liver. All the lymphatic glands contained calcareous or caseous nodules, confluent in several mesenteric glands. There were numerous soft yellow foci in the intestines.

RABBITS.

Number.	Method.	Dose.	Duration of Life.	Result.
1890	Intrav.	1·0 mg.	D. 40 days	G. T.
1891	Intrav.	0·1 mg.	D. 31 ,,	G. T.
1892	Intrav.	0·01 mg.	D. 41 ,,	G. T.
1893	Subcut.	10·0 mg.	K. 152 ,,	Chronic progressive G. T.
1894	Subcut.	1·0 mg.	K. 152 ,,	Progressive G. T.

CULTURE.
Strain derived from popliteal gland of Calf 1449. Inoculated on December 16, 1908, after 78 days artificial cultivation. The culture used was the 6th generation, 16 days old.

CALF 1521.
Subcutaneous.
Dose : 50·0 mg.
Killed when very ill : March 4, 1909.
78 days.
P.M. — Severe general tuberculosis.

RABBITS.

Number.	Method.	Dose.	Duration of Life.	Result.
2083	Subcut.	1·0 mg.	D. 96 days	G. T.
2084	Subcut.	5·0 mg.	D. 116 ,,	G. T.

CULTURE
Strain derived from lung of Calf 1449. Inoculated on December 16, 1908, after 78 days artificial cultivation. The culture used was the 6th generation, 16 days old.

CALF 1525.
Subcutaneous.
Dose : 50·0 mg.
Killed : March 19, 1909.
93 days.
P.M. — Very slight generalised retrogressive tuberculosis.

RABBITS.

Number.	Method.	Dose.	Duration of Life.	Result.
2085	Subcut.	10·0 mg.	D. 144 days	G. T. severe in lungs and kidneys.
2086	Subcut.	10·0 mg.	D. 145 ,,	Local T., and slight T. of lungs, kidneys, and pleura.

CULTURE.

Derived from the portal gland of Calf 1521. Inoculated on April 8, 1909, after 35 days artificial cultivation. The culture used was the 4th generation, 9 days old.

CALF 1465.

Subcutaneous.

Dose : 20·0 mg.

Killed : June 9, 1909.

62 days.

P.M. — Slight generalised retrogressive tuberculosis.

RABBITS.

Number.	Method.	Dose.	Duration of Life.	Result.
2292	Intrav.	1·0 mg.	D. 18 days	General miliary T.
2291	Intrav.	0·1 mg.	D. 15 „	T. of lungs only. Death from injuries.
2290	Intrav.	0·01 mg.	D. 32 „	G. T.
2293	Subcut.	1·0 mg.	D. 46 „	G. T.
2294	Subcut.	1·0 mg.	D. 109 „	Local T. and slight T. of lungs and a kidney.

CULTURE.

Derived from the bronchial gland of Calf 1465. Inoculated on July 6, 1909, after 27 days artificial cultivation. The culture used was the 3rd generation, 8 days old.

CALF 1573.

Subcutaneous.

Dose : 47·0 mg.

Killed (when well) : October 28, 1909.

114 days.

P.M.—Chronic general tuberculosis, severe in spleen.

RABBITS.

Number.	Method.	Dose.	Duration of Life.	Result.
2384	Subcut.	1·0 mg.	D. 122 days	Chronic G. T., not severe.
2385	Subcut.	1·0 mg.	K. 139 „	Very slight G. T.

CULTURE.

Derived from the lung of Calf 1573. Inoculated on December 10, 1909, after 43 days artificial cultivation. The culture used was the 4th generation, 10 days old.

RABBITS.

Number.	Method.	Dose.	Duration of Life.	Result.
2483	Subcut.	10·0 mg.	D. 71 days	G. T.
2484	Subcut.	10·0 mg.	D. 74 „	G. T.
2485	Subcut.	10·0 mg.	D. 66 „	G. T.
2486	Subcut.	10·0 mg.	D. 113 „	G. T.
2487	Subcut.	10·0 mg.	D. 75 „	G. T.
2488	Subcut.	10·0 mg.	D. 55 „	G. T.

GUINEA-PIGS.

Number.	Method.	Dose.	Duration of Life.	Result.
3944	Subcut.	1·0 mg.	D. 67 days	G. T., not severe.
3945	Subcut.	1·0 mg.	D. 76 „	G. T.
3946	Subcut.	1·0 mg.	D. 89 „	G. T.
3947	Subcut.	1·0 mg.	D. 78 „	G. T.
3948	Subcut.	1·0 mg.	D. 60 „	G. T.
3949	Subcut.	1·0 mg.	D. 63 „	G. T.
3950	Subcut.	1·0 mg.	D. 21 „	Early G. T.
3951	Subcut.	1·0 mg.	D. 73 „	G. T.
3952	Subcut.	1·0 mg.	D. 63 „	G. T.
3953	Subcut.	1·0 mg.	D. 36 „	G. T.

VIRUS H. 105. "G.S."—*continued.*

CULTURE INOCULATIONS, AND PASSAGE EXPERIMENT II.

The strain was derived from the original material through Guinea-pig 2950, and was inoculated on August 14, 1908, when it had been 144 days in artificial cultivation.
The culture used was the 9th generation, 15 days old.

CALF 1405.
Subcutaneous.
Dose : 92·0 mg.
Killed : November 23, 1908 (when well).
101 days.
P.M.—General tuberculosis, severe, but not apparently progressive.

CULTURE.
Strain derived from popliteal gland of Calf 1405. Inoculated on February 1, 1909, after 70 days artificial cultivation. The culture used was the 5th generation, 12 days old.

RABBITS.

Number	Method.	Dose.	Duration of Life.	Result.
1971	Subcut.	10·0 mg.	D. 162 days	Local T. and T. of lungs and kidneys. Death from other causes.
1972	Subcut.	10·0 mg.	D. 111 „	Slight G. T. insufficient to account for death.

CALF 1527.
Subcutaneous.
Dose : 50·0 mg.
Died : April 1, 1909.
59 days.
P.M.—General tuberculosis.

CULTURE.
Derived from the mediastinal gland of Calf 1527. Inoculated on April 27, 1909, after 26 days artificial cultivation. The culture used was the 3rd generation, 8 days old.

RABBITS.

Number.	Method.	Dose.	Duration of Life.	Result.
2139	Subcut.	10·0 mg.	D. 50 days	G. T.
2140	Subcut.	10·0 mg.	D. 120 „	Chronic G. T. (not severe).

CALF 1557.
Subcutaneous.
Dose : 44·0 mg.
Killed : July 21, 1909.
85 days.
P.M.—General tuberculosis of moderate severity, not apparently progressive.

CULTURE.
Derived from the popliteal gland of Calf 1557. Inoculated on September 11, 1909, after 52 days artificial cultivation. The culture used was the 3rd generation, 12 days old.

RABBITS.

Number.	Method.	Dose.	Duration of of Life.	Result.
2322	Intrav.	1·0 mg.	D. 15 days	Acute G. T.
2321	Intrav.	0·1 mg.	D. 21 „	G. T.
2320	Intrav.	0·01 mg.	D. 22 „	G. T.
2323	Subcut.	1·0 mg.	D. 101 „	G. T.
2324	Subcut.	0·5 mg.	D. 159 „	G. T.

CALF 1591.
Subcutaneous.
Dose : 50·0 mg.
Killed : December 10, 1909.
90 days.
P.M.—General tuberculosis, not severe, and retrogressive.

CULTURE
Derived from the popliteal gland of Calf 1591. Inoculated on Feb. 24, 1910. The culture used was the 4th generation, 15 days old.

RABBITS.

Number.	Method.	Dose.	Duration of Life.	Result.
2447	Subcut.	10·0 mg.	D. 73 days	G. T.
2448	Subcut.	10·0 mg.	K. 94 „	G. T.
2449	Subcut.	10·0 mg.	D. 58 „	G. T.

GUINEA-PIGS 3995-4000.
(Six.) Subcut. Dose : 1 mg. each.
One died in 37 days (early slight G. T.), and one in 70 days (chronic G.T.) ; the rest were killed after 70 days (chronic G. T.).

RABBITS.

Number.	Method.	Dose.	Duration of Life.	Result.
2506	Subcut.	10·0 mg.	K. 70 days	G. T., severe in lungs.
2507	Subcut.	10·0 mg.	D. 69 „	G. T., death from other causes.
2508	Subcut.	10·0 mg.	K. 70 „	Slight G. T.
2509	Subcut.	10·0 mg.	D. 45 „	Early slight G. T.

VIRUS H. 105. "G.S."—*continued.*

VIRULENCE TESTS ON MONKEYS AND GUINEA-PIGS OF THE CULTURE DERIVED FROM THE ORIGINAL MATERIAL.

The strain was derived from the original material through Guinea-pig 2950, and was inoculated on May 22, 1908, when it had been in artificial cultivation a total period of 60 days. The culture used was the 5th generation, 17 days old.

MONKEY 175.

Subcutaneous.
Dose: 1·0 mg.
Died: July 8, 1908.
47 days.
P.M.—General tuberculosis.

GUINEA-PIGS.

Number.	Method.	Dose.	Duration of Life.	Result.
3078	Intrap.	0·1 mg.	D. 31 days	G. T.
3080	Subcut.	1·0 mg.	D. 188 „	G. T.
3079	Subcut.	0·1 mg.	D. 138 „	G. T.

The strain was derived from the original material through Guinea-pig 2950 and was inoculated on August 14, 1908, when it had been in artificial cultivation a total period of 144 days. The culture used was the 9th generation, 15 days old.

MONKEY 203.

Subcutaneous.
Dose: 0·1 mg.
Killed: August 31, 1908 (accidentally).
17 days.
P.M.—Caseous local lesion: two vertebral glands slightly enlarged and caseous. No T. elsewhere, but one tubercle bacillus found in a smear from spleen.

MONKEY 205.

Subcutaneous.
Dose: 1·0 mg.
Died: October 9, 1908.
56 days.
P.M.—General tuberculosis.

VIRULENCE TESTS ON MONKEYS AND GUINEA-PIGS OF CULTURES OBTAINED AT DIFFERENT STAGES OF THE CALF PASSAGE EXPERIMENT: II.

Culture from the Mediastinal Gland of Calf 1527 (2nd Calf).

Inoculated on April 27, 1909, after 26 days artificial cultivation. The culture used was the 3rd generation, 8 days old.

MONKEY 313.

Subcutaneous.
Dose: Slightly less than 1·0 mg.
Died: July 12, 1909.
76 days.
P.M.—General tuberculosis, severe.

MONKEY 315.

Subcutaneous.
Dose: 1·0 mg.
Died: July 10, 1909.
74 days.
P.M.—General tuberculosis, severe.

GUINEA-PIGS.

Number.	Method.	Dose.	Duration of Life.	Result.
3734	Intrap.	0·1 mg.	D. 21 days.	G. T.
3735	Subcut.	0·1 mg.	D. 54 „	G. T.

Culture from the Popliteal Gland of Calf 1557 (3rd Calf).

Inoculated on September 11, 1909, after 52 days artificial cultivation. The culture used was the 3rd generation, 12 days old.

RHESUS MONKEY 357.

Subcutaneous.
Dose: 1·0 mg.
Died: Oct. 23, 1909.
42 days.
P.M.—General tuberculosis, not very severe.

RHESUS MONKEY 359.

Subcutaneous.
Dose: 1·0 mg.
Died: Oct. 22, 1909.
41 days.
P.M.—General tuberculosis, not severe.

VIRUS H. 105. "G.S."—*continued.*

VIRULENCE TESTS ON MONKEYS AND GUINEA-PIGS OF CULTURES OBTAINED AT DIFFERENT STAGES OF THE CALF PASSAGE EXPERIMENT I.

Culture from the Lung of Calf 1449 (1st Calf).

Inoculated on April 8, 1909, after 191 days artificial cultivation

The culture used was the 11th generation, 7 days old.

RHESUS MONKEY 303.
Subcutaneous.
Dose : 1·0 mg.
Died : May 22, 1909.
44 days.
P.M.—General tuberculosis.

RHESUS MONKEY 305.
Subcutaneous.
Dose : 1·0 mg.
Died : May 1, 1909.
23 days.
P.M.—Local tuberculosis with a few disseminated lesions. Death due apparently to cold.

GUINEA-PIGS.

Number.	Method.	Dose.	Duration of Life.	Result.
3699	Intrap.	0·1 mg.	D. 19 days	G.T.
3700	Subcut.	0·1 mg.	D. 80 „	G.T.

Culture from the Portal Gland of Calf 1521 (2nd Calf).

Inoculated on April 8, 1909, after 35 days artificial cultivation

The culture used was the 4th generation, 9 days old.

RHESUS MONKEY 297.
Subcutaneous.
Dose : 1·0 mg.
Died : May 13, 1909.
35 days.
P.M.—General tuberculosis, apparently insufficient to account for death.

RHESUS MONKEY 299.
Subcutaneous.
Dose : 1·0 mg.
Died : May 2, 1909.
24 days.
P.M.—Local tuberculosis and one tubercle in lung. Death due apparently to cold.

RHESUS MONKEY 301.
Intramuscular.
Dose : 1·0 mg.
Killed when dying : May 13 1909.
35 days.
P.M.—General tuberculosis apparently sufficient to account for death. Local disease severe.

GUINEA-PIGS.

Number.	Method.	Dose.	Duration of Life.	Result.
3697	Intrap.	0·1 mg.	D. 48 days	G.T.
3698	Subcut.	0·1 mg.	D. 48 „	G.T.

Culture from the Bronchial Gland of Calf 1465 (3rd Calf).

Inoculated on July 6, 1909, after 27 days artificial cultivation.

The culture used was the 3rd generation, 8 days old.

RHESUS MONKEY 341.
Subcutaneous.
Dose : 1·0 mg.
Died : August 18, 1909.
43 days.
P.M.—General tuberculosis, not severe.

RHESUS MONKEY 343.
Subcutaneous.
Dose : 1·0 mg.
Died : August 30, 1909.
55 days.
P.M.—General tuberculosis.

CALF 1449. Virus H. 105. "G.S."

Subcutaneous inoculation of culture derived from the original material through Guinea-pig 2950

Dose—48·0 milligrammes.

Date of Inoculation—May 22, 1908. [Age about 12 weeks.]

Killed when in good health—September 29, 1908. [130 days after inoculation.]

Clinical Notes.

The calf remained well during the experiment.

Temperature.

On the seventh day after inoculation the temperature rose to 40·0° C. and reached a maximum (40·8° C.) on the 10th day; it then slowly declined to the normal. The pyrexia lasted 27 days in all. Subsequently the temperature remained normal.

Tuberculin Test.

August 18, 1908. [88 days after inoculation.] Dose, 2·0 cc. Reacted. Rise of temperature, 1·9° C.

Weights.

	cwt.	qrs.	lbs.
May 22, 1908	1	0	19
September 29, 1908	1	3	12

Total gain of weight.—2 qrs. 21 lbs.

Average rate of gain per week.—4·2 lbs.

POST-MORTEM EXAMINATION.

The carcass was in good condition.

Local Lesion.—At the seat of inoculation on the left side of the neck there was a prominent fluctuating tumour measuring 9 by 6 by 5 cm.; on section it was a cyst filled with firm caseous masses and yellowish watery fluid with suspended caseous flocculi; the walls were of fibrous tissue 5 mm. in greatest thickness lined internally with granulation tissue.

Left Prescapular Gland.—The left prescapular gland measured 7 by 4 by 2·8 cm. and showed on section more than three quarters of its substance caseous. The caseous substance was partially softened, the firmer portions being almost completely separated by caseo-pus from the surrounding fibrous capsule.

Right Prescapular Gland.—The right prescapular gland measured 6·5 by 2·5 by 1 cm. and showed in the cortex three caseous gritty nodules 2 mm. in diameter.

Prepectoral Glands.—On the left side one a centimetre in diameter showed in the cortex several caseous gritty nodules like those in the right prescapular gland. Another contained one pinhead-sized caseo-calcareous tubercle.

On the right side three contained each one small tubercle.

Cervical Glands.—All the glands on the left side contained discrete caseous gritty nodules up to 2 mm. in diameter, fairly numerous in the upper cervical, sparsely scattered in the rest.

The glands on the right side each contained a few similar nodules.

Axillary Glands.—Each axillary gland contained a few yellow caseous gritty tubercles.

Thorax.

Pleura.—Normal.

Lungs.—The lungs were crepitant throughout, and at first sight appeared perfectly normal; on close inspection however sparsely scattered minute tubercles, the largest not a millimetre in diameter, were seen just under the pleura. Altogether 18 were counted, 12 of which had minute calcareous centres, the rest being grey and homogeneous throughout. One or two similar tubercles were seen on section of the lung.

Besides the small tubercles two larger nodules, one the size of a millet seed and one that of a hemp seed, were seen under the pleura; the small one was calcareous, the large one caseous and softened (a culture was made from the latter).

Thoracic Glands.—The bronchial and mediastinal glands were not obviously enlarged; they showed on section a moderate number of irregular yellow calcareous or calcareo-caseous nodules varying in size from a pin's head to a hemp seed.

Heart.—Normal.

Abdomen.

Omentum.—On the ventral surface there was a pedunculated nodule the size of a split pea with a calcareo-caseous centre and fibrous margin; there were two similar but smaller nodules on the omentum close to its attachment to the rumen.

Peritoneum.—Normal.

Spleen.—The spleen was normal in size and showed in the pulp after careful search six miliary tubercles with calcareous centres and grey margins.

Liver.—In the substance of the liver just under the capsule there was one miliary calcareous tubercle with a grey margin; it projected slightly from the surface where it was surrounded by a filmy grey zone.

Portal Glands. — The portal glands were not enlarged and contained fairly numerous calcareous tubercles, many occurring in small groups.

Kidneys and Suprarenal Bodies.—Normal.

Coeliac Glands.—One coeliac gland was closely beset with irregular calcareous nodules up to a hemp seed in size; the others contained small scattered calcareous tubercles.

Lumbar Glands.—Each lumber gland contained scattered tubercles varying from a pin's head to a millet seed; the smaller ones were calcareous, the larger caseo-calcareous.

Iliac Glands.—The iliac glands were not enlarged and showed in the cortex scattered minute calcareous tubercles.

Alimentary Tract.

Tongue, Pharynx, Tonsils.—Normal.

The Retro-pharyngeal, Submaxillary, and Parotideal Glands contained a moderate number of discrete yellow caseous gritty nodules ranging from one or less up to about two millimetres in diameter; in one parotideal gland there were two or three larger caseous nodules.

Intestines. — All the Peyer's patches contained numerous soft yellow foci up to a millet seed in size; the mucous membrane over many of them was slightly raised, the raised patch often showing a depression in the centre over the focus. The mucous membrane also showed numerous slightly raised patches some congested up to 5 mm. in diameter, which could be distinctly felt between the finger and thumb; on section these showed in the submucous tissue soft caseous foci.

There were yellow foci in the lymphoid tissue in the large intestine.

Mesenteric Glands.—All the mesenteric glands were slightly enlarged and were rather extensively tuberculous; they showed in the cortices moderately numerous discrete calcareous nodules ranging up to 5 mm. in diameter, and yellow calcareous or calcareo-caseous patches formed by aggregated nodules.

Ileo-Colic Glands.—The ileo-colic glands were similarly but on the whole not so severely affected.

Various Lymphatic Glands.

Precrural and Popliteal Glands.—These glands were distinctly enlarged and closely beset with yellow caseous gritty nodules varying in diameter up to three or rather more millimetres.

Pudic, Gluteal, and Ischiatic Glands.—These were not obviously enlarged and contained scattered caseo-calcareous nodules similar to those in the precrural.

Testicles.—Normal.

Microscopical Examinations.

Two crushed tubercles from the Lung.—A few tubercle bacilli seen.

Emulsion of caseous nodule from the Lung.—A few tubercle bacilli seen.

Emulsion of two nodules from the Mediastinal Gland.—A few tubercle bacilli seen.

Emulsion of nodules from a Popliteal Gland.—A few tubercle bacilli seen.

Smear from two foci from the Small Intestine.—No tubercle bacilli seen.

CALF 1405. Virus H. 105. "G.S."

Subcutaneous inoculation of culture derived from the original material through Guinea-pig 2950.

Dose—92·0 milligrammes.

Date of Inoculation—August 14, 1908. [Age about 6 months.]

Killed when in good health—November 23, 1908. [101 days after inoculation.]

Clinical Notes.

A raised firm flattened swelling of moderate size developed at the seat of inoculation on the left side of the neck, and the adjacent prescapular gland became very much enlarged. On October 19, 66 days after inoculation, the local tumour measured 12 by 8 by 5 cm., and the prescapular gland was 10 cm. in length. The calf, which had been unwell during the third and fourth weeks after inoculation (when the temperature was very high), was now well and in good condition.

Subsequently the tumour and gland diminished slightly in size, and the general health of the calf remained good.

Temperature.

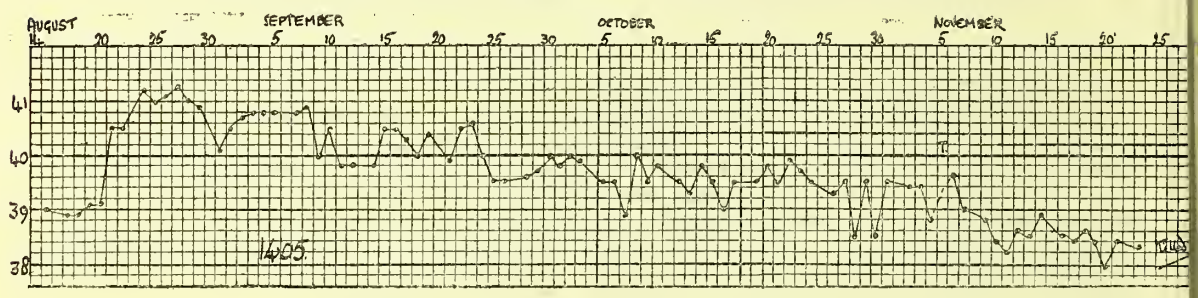

Tuberculin Test.

November 4, 1908. [82 days after inoculation.]
Dose, 2·0 cc. Reacted. Rise of temperature, 2·6° C.

Weights.

	cwt.	qrs.	lbs.
August 14, 1908	1	2	26
November 23, 1908	1	3	23

Total gain of weight.—25 lbs.

Average rate of gain per week.—1·7 lbs.

POST-MORTEM EXAMINATION.

The carcass was in good condition.

Local Lesion.—In the subcutaneous tissues on the left side of the neck there was a lenticular mass measuring 10 by 7 by 4 cm., of dense yellow caseous substance, slightly gritty around the margins and beginning to break down under the skin; it was surrounded by a zone of translucent fibroid tissue, 5 mm. or more in thickness, studded with calcareous tubercles; the skin over it was much thickened and also contained calcareous tubercles.

Left Prescapular Gland.—The left prescapular gland measured 8 by 5 by 4·5 cm., and weighed 4⅓ ozs.; it was composed throughout of dense pinkish yellow caseated substance, slightly gritty from calcification; the capsule was much thickened.

Right Prescapular Gland.—The right prescapular gland measured 6 by 2·5 by 1 cm., and contained two hemp-seed sized caseous nodules and a few small calcareous tubercles.

Prepectoral Glands.—On the left side, one (1·5 cm. in diameter) was three-quarters caseous and calcareous; another contained a few small calcareous tubercles; in a third there was one minute yellow point.

Cervical Glands.—On the left side, one in the middle of the neck the size of a thrush's egg was dense caseous and gritty throughout; the rest were normal in size and contained one or two small calcareous tubercles.

On the right side two only were affected, containing a few small calcareous tubercles.

Thorax.

Lungs.—The lungs collapsed well; they contained fairly numerous calcareous tubercles with fibrous margins ranging from less than 1 mm. to about 2 mm. in diameter; the tubercles were more numerous in the cephalic than the caudal lobes, and in the former were in several places closely aggregated together, the aggregations corresponding to patches of collapse or consolidation; around many of the tubercles in the caudal lobes were small angular red areas of consolidation, and in the antero-ventral parts there were a few consolidated lobules which were closely beset with tubercles.

Thoracic Glands.—The bronchial and dorsal mediastinal glands were much enlarged; they were very firm and on section were very closely beset with calcareous tubercles extensively replacing the gland substance; around the margins of most of the larger glands there was a narrow almost continuous caseo-calcareous zone; towards the centre of each of the glands the tubercles were not so closely aggregated as in the cortex.

A gland just within the entrance to the thorax on the left side was much enlarged and showed about a third of its substance dense caseous and gritty, while the rest was beset with calcareous tubercles.

Heart.—Under the endocardium of the right ventricle there were two grey tubercles, the largest about twice the size of a millet seed.

On the pericardium at the root of the great vessels there were several patches of pinkish vegetations.

Pleura.—There were a few patches of vegetations on the costal pleura and on the diaphragm.

Abdomen.

On the peritoneal surface of the diaphragm near the xiphisternum there was a pinkish fleshy outgrowth.

Omentum and Parietal Peritoneum.—Normal.

Spleen.—The spleen was greatly enlarged and weighed 1 lb. 7 ozs.; on the surface there were a few small congested connective tissue outgrowths; on section the pulp was packed almost as closely as possible with caseo-calcareous nodules with grey margins ranging in diameter from 1·5 to 3 mm.

Liver.—In the substance of the liver under the capsule scattered grey tubercles varying from 0·5 to a little more than 1 mm. were seen; when crushed the majority of these were homogeneous, a few were calcareous; there was also one grey nodule the size of a hempseed with a calcareous centre; on section tubercles similar to those on the surface were seen scattered evenly thoughout.

Portal Glands.—The portal glands were perhaps slightly enlarged and were closely beset with discrete miliary calcareous tubercles.

Coeliac Glands.—Two were slightly enlarged and closely beset with calcareous tubercles which in places had coalesced to form irregular patches.

Kidneys.—In the cortex of the left kidney there were about half-a-dozen translucent grey tubercles, the largest the size of a millet seed; there were similar but rather more numerous tubercles in the cortex of the right.

Suprarenal Bodies.—The left suprarenal showed in the cortex five caseo-calcareous nodules with grey translucent margins, the largest 4 mm. in diameter; the right contained seven similar nodules, the largest rather more than 5 mm. in diameter.

Renal Gland.—The renal gland was closely beset with small calcareous tubercles.

Lumbar Glands.—One lumbar gland was closely beset with discrete irregular calcareous tubercles, others contained a few only.

Iliac Glands.—The iliac glands showed in the cortex scattered irregular calcareous tubercles.

Alimentary Tract.

Pharynx.—There were a few softened caseous tubercles in the corrugated mucous membrane of the vault of the pharynx.

Tonsils.—The left tonsil contained one, the right six, yellow calcareous tubercles.

The Parotideal and Retro-pharyngeal Glands contained scattered calcareous tubercles.

The Submaxillary Glands contained fairly numerous small calcareous tubercles.

Intestines.—The long Peyer's patch showed half-a-dozen submucous caseous tubercles and several small raised patches of mucous membrane with a central ulcer; the patches could be felt between the finger and thumb as distinct thickenings but on section there was no sign of caseation or calcification; most of the other Peyer's patches showed similar ulcerated patches and in the centres of many of these calcareous grains were found.

The mucous membrane of the caecum showed numerous small ulcers with raised margins without caseation or calcification; the colon showed four similar ulcers.

Mesenteric Glands.—All the mesenteric glands were affected; a few in the posterior part of the mesentery were closely beset with calcareous tubercles, the others contained a smaller number of tubercles, discrete and aggregated together into nodular patches.

Ileo-Colic Glands.—These were closely beset with calcareous tubercles.

Eyes.—Normal.

Trachea.—The mucous membrane of the trachea showed eight slightly raised sharply defined pinkish areas elongated in the direction of the long axis of the trachea; the largest about 8 mm. in greatest diameter were caseo-calcareous in the centre and ulcerated on the surface.

Various Lymphatic Glands.

The Popliteal Glands were enlarged and closely beset with nodules ranging up to 5 mm. in diameter; the larger ones were caseo-calcareous, the smaller calcareous.

The Precrural, Pudic, Gluteal and Ischiatic Glands showed in the cortex scattered irregular calcareous tubercles ranging in size from a pin's head to a millet seed.

Haemo-Lymph Glands.—All the haemo-lymph glands in the body contained calcareous tubercles; some contained one, others two or more.

Microscopical Examination.

Emulsion of Tubercles from the Spleen.—No tubercle bacilli seen.

Emulsion of Tubercles from the Popliteal Gland.—No tubercle bacilli seen.

CALF 1521. Virus H. 105. "G.S."

Subcutaneous inoculation of culture derived from the popliteal gland of Calf 1449.

Dose—50·0 milligrammes.

Date of Inoculation—December 16, 1908. [Age about 10 weeks.]

Killed when very ill—March 4, 1909. [78 days after inoculation.]

Clinical Notes.

The course of the disease was similar to that frequently seen in calves inoculated with 10·0 mg. of a virus of Group I.

Temperature.

On the 16th day after inoculation the temperature rose to 40·0° C. A period of regular pyrexia followed which lasted 24 days (maximum temperature 40·4° C.

minimum 39·9° C.). During the remaining period of the experiment (38 days) the temperature was raised and irregular (maximum 40·3° C., minimum 38·8° C.).

Weights.

	qrs.	lbs.
December 16, 1908	3	12
March 4, 1909	3	10

Total loss of weight.—2 lbs.

POST-MORTEM EXAMINATION.

The carcass was emaciated.

Local Lesion.—In the subcutaneous tissues at the seat of inoculation there was an elongated firm tumour measuring 19 by 8 by 3 cm.; on section it was composed of pinkish-yellow caseo-necrotic substance adherent to and infiltrating to a slight extent both the skin and the muscle; in the middle of the tumour there was a cavity filled with clear yellow fluid under tension; the walls of the cavity were ragged.

Left Prescapular Gland.—The left prescapular gland measured 8 by 4·3 by 4 cm. and was dense yellow and caseous throughout, and very slightly gritty from calcification.

Right Prescapular Gland.—The right prescapular gland measured 6 by 3·4 by 1·5 cm. and was very nodular on the surface. On section it contained numerous nodules the largest 8 mm. in diameter, many of which had coalesced to form larger nodules; the gland substance was extensively replaced by them; the nodules were firm yellow and caseous, and slightly gritty from calcification, and had broad grey margins infiltrated with early caseous streaks and foci.

Prepectoral Glands.—On the left side the rounded gland showed the cortex caseous; the reniform gland contained a large caseating patch and three or four pea-sized nodules; of two small glands one was caseous almost throughout, the other had a small caseating patch in the cortex.

The prepectoral glands on the right side were enlarged and beset with nodules similar to those in the right prescapular.

Cervical Glands.—On the left side one in the middle of the neck the size of a kidney bean was caseous throughout; others on this side and all those on the right were also enlarged and composed almost throughout of firm caseating tissue.

Thorax.

Pleura.—Normal.

Lungs.—The cephalic lobes of the lungs with the exception of a few lobules around the margins were red and hepatised; the caudal lobes were mottled with irregular red patches which in the antero-ventral parts had run together forming large solid areas. The surfaces of both lungs except the posterior parts of the caudal lobes were closely studded with slightly raised greyish-yellow nodules up to 5 or more millimetres in diameter; in many places they were aggregated together forming masses which partly replaced the larger lobules.

On section the lung parenchyma with the exception of the posterior parts of the caudal lobes was closely beset with caseating nodules, here and there confluent; in the postero-dorsal parts of the caudal lobes discrete nodules were less numerous than in the anterior parts, but there were numerous firm greyish yellow caseating lobules.

Thoracic Glands.—The bronchial and dorsal mediastinal glands were much enlarged (combined weight, 7 ozs.) and very indurated; on section they were composed of dense caseating tuberculous tissue slightly gritty from calcification; they were not quite caseous throughout, a small amount of translucent grey tissue still remaining. The capsules of some of the glands were much thickened.

Heart.—In the muscle wall of the right auricle there were half-a-dozen caseating nodules, the largest the size of a hemp-seed. In the muscle of the left ventricle near the apex, just under the pericardium, there was a pea-sized caseating nodule; in the interventricular septum forming a projection into the right ventricle there was a caseating nodule 1 cm. in diameter.

Abdomen.

Omentum.—On the ventral surface of the omentum there were three flattened caseating nodules the largest 3 mm. in diameter.

Parietal Peritoneum.—There was one small caseating nodule on the peritoneum in the pelvis.

Spleen.—The spleen was enlarged (weight 9¾ ozs.) and was packed almost as closely as possible with yellow caseous slightly gritty nodules varying from 1 to 3 mm. in diameter, the majority being about 2 mm.

Liver.—The liver contained scattered tubercles irregularly distributed; they varied from a mere point up to about 1 mm. in diameter; the larger ones were yellowish-white, the smaller greyish-white.

Portal Glands.—The portal glands were greatly enlarged and were dense and caseous throughout and slightly gritty from calcification.

Kidneys.—On the surface of the left kidney there were ten and on that of the right twelve caseous tubercles, the largest 2 mm. in diameter; there were similar tubercles in the depth of the cortex.

Suprarenal Bodies.—Each suprarenal body contained three caseous nodules the largest 3 mm. in diameter.

Coeliac Glands.—All the glands in this group were enlarged and composed practically throughout of dense yellowish-white caseous substance slightly gritty from calcification.

Alimentary Tract.

Tongue and Larynx.—Normal.

Pharynx.—The corrugated mucous membrane in the vault of the pharynx was closely beset with caseous nodules, and the mucous membrane over them was ulcerated.

Tonsils.—The tonsillar substance was extensively replaced by caseous nodules.

The Submaxillary, Retropharyngeal, and Parotideal Glands were much enlarged, varying from 4·5 to 7 cm. in greatest diameter; on section they were tuberculous throughout, being composed of dense congested caseating tissue slightly gritty from calcification.

Gastric Glands.—The gastric glands were enlarged and caseating, but were not so extensively tuberculous as the mesenteric glands.

Mesenteric Glands.—All the mesenteric glands were greatly enlarged and formed very prominent tumours in the mesentery; they were firm and composed throuhout of gritty yellowish-white caseous substance in a scanty matrix of translucent grey tissue.

The Ileo-colic and Colic Glands were all enlarged and caseating throughout.

Intestines.—The Peyer's patches of the small intestine were closely studded with yellow caseous nodules up to a hemp seed in size many of which were aggregated together; the mucous membrane over most of them was ulcerated and the caseous substance was exposed and in some cases in process of being expelled en masse; some of the ulcers were large, especially where several nodules had run together, and had congested thickened margins; the long Peyer's patch was more closely beset than any of the other patches and had a very irregular nodular congested surface.

The mucous membrane of the large intestines was also closely studded with nodules smaller than in the small intestine; those in the lower part of the intestine were not ulcerated and had caseous centres; in the upper part the majority had ulcerated and the caseous substance had disappeared.

Eyes.—The iris of the right eye contained a caseous tubercle. The left eye was normal.

Trachea.—Normal.

Various Lymphatic Glands.

The Renal, Pudic, and some of the Lumbar Glands were much enlarged and yellow and caseous practically throughout; *the other Lumbar Glands* were closely beset with caseating tubercles.

The Precrural, Popliteal, Iliac, Ischiatic and Gluteal, Axillary and Ventral Mediastinal Glands were much enlarged and closely beset with caseating nodules similar to those in the right prescapular gland.

The Vertebral Glands were all enlarged and caseating.

Microscopical Examination.

Emulsion of Bronchial Gland.—Numerous tubercle bacilli.

Emulsion of Portal Gland.—Numerous tubercle bacilli.

Smear from a tubercle from the Right Eye.—Numerous tubercle bacilli.

Smear from a caseous plug from a nodule in the Small Intestine.—Very numerous tubercle bacilli.

CALF 1525. Virus H. 105. "G.S."

Subcutaneous inoculation of culture derived from the lung of Calf 1449.

Dose—50·0 milligrammes.

Date of Inoculation—December 16, 1908. [Age about 10 weeks.]

Killed when in good health—March 19, 1909. [93 days after inoculation.]

Clinical Notes.

The calf remained well during the experiment and grew normally.

Temperature.

The temperature rose on the 7th day to 39·8° C. and reached 40·9° C. on the 16th day; it remained high (above 40·0° C.) until the 21st day after inoculation and then suddenly fell to the normal. The temperature subsequently remained normal except for a sudden rise to 40·0° C. on the 35th day after inoculation.

Weights.

	cwt.	qrs.	lbs
December 16, 1908	0	3	8
March 19, 1909	1	1	20

Total gain of weight.—2 qrs. 12 lbs.

Average rate of gain per week.—5 lbs.

POST-MORTEM EXAMINATION.

The carcass was in good condition.

Local Lesion.—At the seat of inoculation on the left side of the neck there was a cystic tumour measuring 10 by 5·5 by 3·5 cm. with fibrous wall and caseous partly softened contents; there was a small opening in the skin which communicated with the interior of the tumour.

Left Prescapular Gland.—The left prescapular gland measured 5·5 by 3 by 2·5 cm. and showed about two-thirds composed of dense caseo-calcareous substance which in one spot had broken down to form caseo-pus.

Right Prescapular Gland.—The right prescapular gland measured 3·5 by 1·8 by 1 cm. and was normal on section.

Prepectoral Glands.—On the left side there was a spherical gland 1 cm. in diameter which was dense and caseo-calcareous throughout. The rest of the prepectoral glands were normal.

Cervical Glands.—One on the left side not enlarged contained a caseo-calcareous patch replacing about a quarter of the gland substance. The rest were normal.

Thorax.

Lungs.—The lungs were crepitant throughout. The left lung showed under the pleura seven, the right two miliary tubercles with minute calcareous centres. No tubercles were seen on section.

Thoracic Glands.—The left bronchial gland showed in the cortex seven calcareous tubercles. In the long mediastinal gland there were two yellow calcareous tubercles. Other thoracic glands were normal.

Abdomen.

Small Intestines.—The mucous membrane of the lower part of the ileum was closely studded with raised rounded nodules, the majority about 5 mm. in diameter, in the centre of each of which there was a small crater frequently with congested margins; on section they appeared to be local thickenings of the mucous membrane, the submucous tissue not being obviously thickened and showing no sign of caseation; the peritoneal surface was normal; these nodules gradually became less and less numerous as one proceeded towards the anterior end and in the duodenum only an occasional one was encountered (probably not tuberculous).

In the long Peyer's patch there were scattered softened caseous foci; other Peyer's patches were normal; one contained one or two caseous foci.

Large Intestine.—The mucous membrane of the caecum and first part of the colon showed numerous small ulcers with raised thickened margins; the bases were not thickened and there was no sign of caseation; the ulcers quickly became less numerous as one proceeded down the colon, the mucous membrane of the rest of the large intestine being normal (probably not tuberculous).

Mesenteric Glands.—The mesenteric glands contained sparsely-scattered calcareous tubercles.

Ileo-Colic Glands.—One ileo-colic gland showed a moderate number of tubercles in the cortex; the rest resembled the mesenteric.

Suprarenal Bodies.—In the cortex of the right there were two miliary calcareous tubercles; the left was normal.

Peripheral Lymphatic Glands.

Popliteal Glands.—The cortex of the right contained one, that of the left two, minute whitish calcareous foci.

Ischiatic Glands.—One contained a calcareous focus.

Other organs and glands were normal.

Microscopical Examination.

Smear from a Soft Focus in a Peyer's Patch.—No tubercle bacilli.

Scraping from Normal Mucous Membrane in the Small Intestine.—No tubercle bacilli.

Smear from the Centre of a raised Nodule in the Small Intestine.—No tubercle bacilli.

CALF 1465. Virus H. 105. "G.S."

Subcutaneous inoculation of culture derived from the portal gland of Calf 1521.

Dose—20·0 milligrammes.

Date of Inoculation—April 8, 1909. [Age about 7 months.]

Killed when in good health—June 9, 1909. [62 days after inoculation.]

Clinical Notes.

The calf remained well and grew normally during the experiment.

Temperature.

The temperature rose to 40·2° C. on the fourth day after inoculation but immediately fell to the normal. On the 11th day it again rose, reached 40·6° C on the 16th day and remained high (maximum 40·5° C., minimum 39·2° C.) until the 37th day; on the 39th day the temperature was normal and it remained normal subsequently.

Weights.

		cwt.	qrs.	lbs.
April 8, 1909	... ...	1	2	1
June 9, 1909	... ...	2	0	14

Total gain of weight.—2 qrs. 13 lbs.

Average rate of gain per week.—7·6 lbs.

POST-MORTEM EXAMINATION.

The carcass was in good condition.

Local Lesion.—At the seat of inoculation on the right side of the neck there was a firm tumour measuring 14 by 6·5 cm. in area ; it was composed of a mass of dense yellow caseo-necrotic substance 2·5 cm. in thickness, gritty around the margins ; the skin over it was much thickened.

Right Prescapular Gland.—The right prescapular gland measured 7 by 4·5 by 3·5 cm. and was composed nearly throughout of dense pinkish-yellow slightly gritty caseous substance ; the capsule in places was greatly thickened.

Left Prescapular Gland.—The left prescapular gland measured 4·5 by 2·4 by 1·2 cm. and showed in the cortex two yellowish-white caseous foci.

Prepectoral Glands.—Three prepectoral glands on the left side contained five small caseous tubercles. On the right side one contained four caseous tubercles.

Axillary Glands.—The right axillary gland contained one caseous focus ; the left was normal.

Cervical Glands.—On the left side the lower cervical showed a number of calcareous tubercles in the cortex ; other cervical glands contained each a few small caseous tubercles.

Thorax.

Lungs.—The lungs were normal in general appearance ; they showed under the pleura sparsely scattered tubercles varying from a mere point up to a millet seed in size ; some of the larger ones had opaque centres, one of which was found to be gritty. A few similar tubercles were seen on section.

Thoracic Glands.—The bronchial and mediastinal glands were not apparently enlarged ; they showed on section moderately numerous miliary calcareo-caseous and caseo-calcareous tubercles in the cortices.

Heart and Pleura.—Normal.

Abdomen.

Omentum and Peritoneum.—Normal.

Spleen.—The spleen was slightly enlarged and showed in the pulp moderately numerous evenly distributed tubercles varying from 1·5 to 2 mm. in diameter ; they were caseous and gritty in the centre and had grey margins.

Liver.—Just under the capsule of the liver there were a dozen grey translucent tubercles, the largest 1 mm. in diameter ; one had a calcareous centre ; sparsely scattered grey foci were seen on section.

Portal Glands.—The portal glands were not enlarged ; they showed however in the cortex a moderate number of discrete gritty caseous tubercles the largest the size of a millet seed.

Coeliac Glands.—One resembled the portal glands ; another contained one caseous tubercle ; the rest were normal.

Kidneys.—On the surface of the left four grey tubercles, the largest 1 mm. in diameter, were seen ; on section one was found in the depth of the cortex. On the surface of the right there was one minute grey tubercle.

Suprarenal Bodies.—In the cortex of one there was a minute greyish-white tubercle. The other was normal.

Iliac Glands.—The iliac glands contained a few minute caseous tubercles.

Renal Glands.—The renal glands contained moderately numerous small caseous tubercles.

Lumbar Glands.—The lumbar glands contained a few minute caseous foci.

Alimentary Tract.

Tongue, Pharynx, Tonsils.—Normal.

Submaxillary Glands.—Normal.

Retro-pharyngeal Glands.—Each contained a few caseous foci.

Parotideal Glands.—In one there was a caseous tubercle ; the other was normal.

Intestines.—Three Peyer's patches contained each one slightly raised nodule soft and yellow in the centre, in another there were four similar nodules. The large intestine was normal.

Mesenteric Glands.—These contained sparsely scattered groups of small caseous tubercles and one or two larger isolated ones which were gritty from calcification.

Ileo-Colic Glands.—There were a few groups of small caseous tubercles in these glands.

Testes.—Normal.

Various Lymphatic Glands.

Precrural Glands.—In one there were four and in the other two minute whitish tubercles.

Popliteal Glands.—In one there was a millet-seed sized caseous tubercle, in the other a few caseous foci.

One Gluteal and one *Ischiatic Gland* contained each one minute caseous focus ; the others were normal.

Pudic Glands.—Normal.

Microscopical Examination.

Emulsion of Spleen.—A few tubercle bacilli.

Emulsion of Bronchial Gland.—A moderate number of tubercle bacilli.

CALF 1573. Virus H. 105. "G.S."

Subcutaneous inoculation of culture derived from the bronchial gland of Calf 1465.

Dose—47·0 milligrammes.

Date of Inoculation—July 6, 1909. [Age about 12 weeks.]

Killed when in good health—October 28, 1909. [114 days after inoculation.]

Clinical Notes.

The calf showed no sign of serious illness during the experiment and its rate of growth was but little slower than that of a healthy calf of the same age.

Temperature.

The temperature rose to 40·0° C. on the 9th day and reached a maximum (40·5° C.) on the 10th day. It fluctuated between 40·0° and 40·4° C. for a week, and then gradually declined to the normal; the pyrexia lasted forty days in all. Subsequently the temperature remained normal.

*Tuberculin Test.**

August 6, 1909. [31 days after inoculation.] Dose, 1·0 cc. Rise of temperature, 0·6° C.

Weights.

	cwt.	qrs.	lbs.
July 6, 1909	1	0	14
October 28, 1909	1	3	10

Total gain in weight.—2 qrs. 24 lbs.

Average rate of gain per week.—5·3 lbs.

POST-MORTEM EXAMINATION.

The carcass was in good condition.

Local Lesion.—At the seat of inoculation on the left side of the neck there was a large fluctuating tumour measuring 18 by 11 by 7 cm. and weighing 2 lbs. On section it was a cyst with thick fibrous walls and serous and breaking-down caseous contents.

Left Prescapular Gland.—The left prescapular gland measured 10 by 5·5 by 5·5 cm. and was composed throughout of dense gritty caseous substance surrounded by a thick fibrous capsule.

Right Prescapular Gland.—The right prescapular gland measured 5 by 2·5 by 1·5 cm. and contained a moderate number of caseous gritty nodules up to a hempseed in size.

Prepectoral Glands.—On the left side one 1 cm. in diameter was caseo-calcareous throughout; another was kidney-shaped and measured 4 cm. in length, it showed on section numerous yellow points; another smaller one was similar.

The glands on the right side contained discrete tubercles.

Cervical Glands.—Two on the left side in the lower part of the neck were moderately large and partly caseo-calcareous, the rest contained each a few discrete tubercles.

Thorax

Pleura.—On the costal pleura there were two fleshy fibrous growths containing caseous foci, and two haemorrhagic fibrous nodules loosely attached, the largest the size of a hempseed.

Lungs.—The lungs were pink and crepitant throughout with the exception of a few collapsed lobules near the root; these were beset with fibrous tubercles with calcareous centres. The fringes around the margins of the lungs were in places hypertrophied, and contained here and there firm fleshy growths.

On the dorsal surfaces of the lobes there were a few flat superficial reddish growths one or two of which contained small tubercles; in the right middle lobe there was a nodule lobular in outline and 1 cm. in diameter which projected from the dorsal surface, the projecting portion having overhanging margins; on section it was fibrous and beset with caseo-calcareous tubercles; there was a similar but smaller nodule in the margin of the right caudal lobe. The lung showed scattered throughout its substance tubercles ranging up to 2 mm. in diameter, they had fibrous margins and the larger ones had caseo-calcareous centres and the smaller ones calcareous centres; they were not evenly distributed and appeared to be more numerous on the surface under the pleura and in the ventral parts of the cephalic lobes than elsewhere; in the depth of the lung there were two or three larger reddish-grey nodules (largest 1 cm.) containing caseo-calcareous foci and occupying parts of a lobule.

Thoracic Glands.—The bronchial and dorsal mediastinal glands showed a moderate degree of enlargement; their cortices were closely beset with calcareo-caseous tubercles, discrete and aggregated together to form irregular patches.

Heart.—In the wall of the right auricle, causing a projection into the cavity, there was a pea-sized grey fibrous nodule showing no sign of caseation or calcification; the heart was otherwise normal.

Abdomen.

Omentum.—On the ventral surface of the omentum there were half-a-dozen flattened nodules ranging up to 3 mm. in greatest diameter; the two largest had caseo-calcareous centres, the rest were grey and translucent.

Parietal Peritoneum.—Normal.

Spleen.—The spleen was enlarged, weighing 1 lb. 3 oz., and showed on the surface congested connective tissue processes. The pulp was closely beset with nodules of two kinds; one kind was grey and translucent and ranged up to a millet seed in size, and tended to occur in groups, the other was softened caseous and gritty and fibrous around the margins and ranged up to 3 or 4 mm. in diameter.

Liver.—Attached to the thin margin of the liver there was a fibrous nodule about 8 mm. in diameter containing caseous points; the substance of the liver showed a moderate number of evenly-distributed tubercles ranging up to nearly 2 mm. in diameter (majority 1 mm. or less); the larger ones had caseo-calcareous centres, the smaller were greyish or had calcareous centres.

Portal Glands.—The portal glands were enlarged and their cortices closely beset with caseous slightly gritty tubercles mostly discrete but here and there aggregated together into small groups.

Coeliac Glands.—The coeliac glands were enlarged and closely beset with more or less discrete calcareous and caseo-calcareous tubercles.

Kidneys.—In the cortex of each on the surface as well as in the depth there was a moderate number of greyish-white tubercles 1 to 2 mm. in diameter; they were not definitely caseous and showed no sign of calcification.

Suprarenal Bodies.—In one there was a millet-seed sized caseous and slightly gritty tubercle; in the other there were two caseous nodules with grey margins, one the size of a hemp- the other that of a millet-seed.

Renal Glands.—The renal glands contained nodules similar to but rather less numerous than those in the portal glands.

Lumbar Glands.—The lumbar glands were slightly enlarged and moderately closely beset with caseo-calcareous tubercles.

Iliac Glands.—The iliac glands contained a moderate number of caseo-calcareous nodules up to a hempseed in size.

* The test was made during the period of pyrexia; no marked rise of temperature therefore resulted from it.

Alimentary Tract.

Tongue, Pharynx, Tonsils.—Normal.

The Retro-pharyngeal, Submaxillary, and Parotideal Glands contained each a moderate number of caseo-calcareous nodules ranging up to a hempseed in size.

Intestines.—One small Peyer's patch in the small intestine showed two caseous tubercles, another a grey nodule containing caseous points, and there were in the long Peyer's patch a few caseous and softened tubercles.

The large intestine was normal.

Mesenteric and Ileo-Colic Glands.—In the cortex of each there were several calcareo-caseous nodules varying from 2 to 10 mm. in diameter; the larger ones were irregular in outline and were composed apparently of aggregated tubercles.

Various Lymphatic Glands.

The Precrural, Popliteal, Pudic, and Gluteal Glands contained each a moderate number of caseo-calcareous nodules ranging up to a hempseed in size.

The Axillary Glands contained a few similar nodules.

Ischiatic Glands.—Normal.

Haemo-lymph Glands.—One haemo-lymph gland was enlarged and contained tubercles.

Eyes.—Normal.

Testes.—Normal.

Thymus.—In the thymus there were four large nodules ranging up to 1 cm. in diameter, with fibrous walls and muco-purulent contents.

Microscopical Examination.

Emulsion of Nodule from Lung.—No tubercle bacilli seen.

Emulsion of Nodules from Precrural Gland.—A few tubercle bacilli.

Muco-pus from Nodule in Thymus.—A few tubercle bacilli.

CALF 1527. Virus H. 105. "G.S."

Subcutaneous inoculation of culture derived from the popliteal gland of Calf 1405.

Dose—50·0 milligrammes.

Date of Inoculation—February 1, 1909. [Age 4 months.]

Died—April 1, 1909. [59 days after inoculation.]

Clinical Notes.

The course of the illness was similar to that usually seen in calves suffering from severe general tuberculosis.

Temperature.

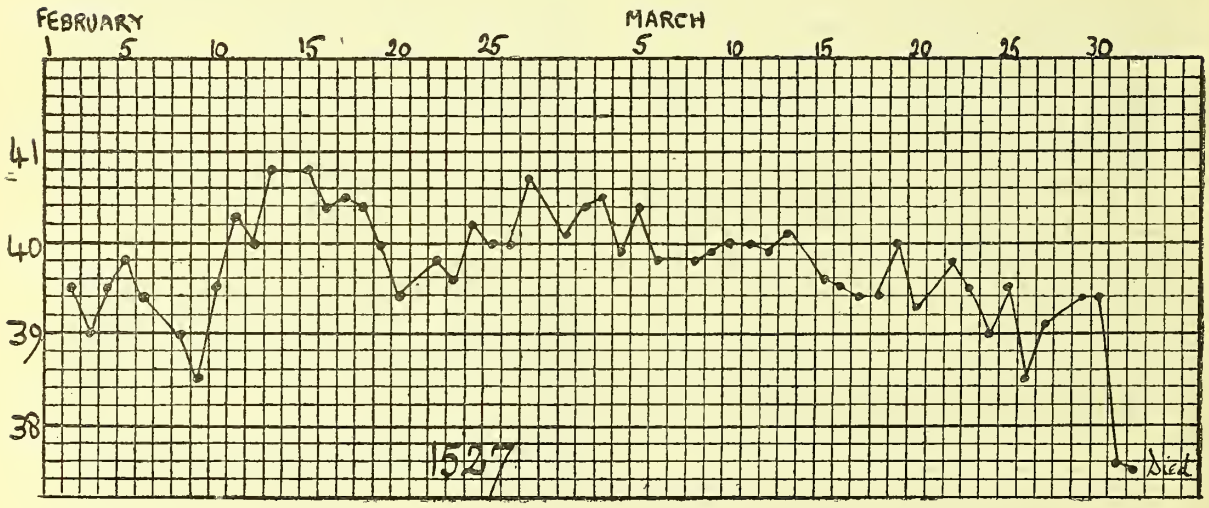

Weights.

	qrs.	lbs.
February 1, 1909	3	19
April 1, 1909	3	8

Total loss of weight.—11 lbs.

POST-MORTEM EXAMINATION.

The carcass was thin.

Local Lesion.—At the seat of inoculation on the left side of the neck there was a firm tumour measuring 12 by 7 by 3·5 cm. composed of pinkish-yellow caseo-necrotic substance containing a cavity 3 cm. in greatest diameter filled with turbid yellow serous fluid; the skin was adherent and slightly infiltrated; the muscles were also infiltrated, at one part rather deeply.

Left Prescapular Gland.—The left prescapular gland measured 9 by 4·5 by 4·2 cm. and was dense yellow and caseous throughout; the caseous substance contained sparsely scattered minute calcareous foci.

Right Prescapular Gland.—The right prescapular gland measured 4 by 2 by 1 cm. and showed in the cortex numerous caseous nodules ranging from 1 to 2·5 mm. in diameter.

Prepectoral Glands.—On the left side one the size of a thrush's egg was dense and caseous throughout The cortices of the other glands on this side and of those on the opposite side were closely beset with caseous nodules up to 2 mm. in diameter.

Cervical Glands.—On the left side the lower cervical was much enlarged measuring 4 cm. in diameter, and was composed throughout of caseating tuberculous tissue not so far advanced as the prescapular.

Two or three other small glands showed parts of their cortex caseating; other cervical glands on this side and all those on the right contained caseating nodules similar to those in the peripheral lymphatic glands but in some they had become confluent.

Thorax.

Pleura.—On the costal pleura the fringes along the margins of the ribs were slightly hypertrophied in patches and contained scattered tubercles similar to those on the omentum.

On the pleural surface of the diaphragm were congested connective tissue tufts, some granular patches and slightly raised discrete grey tubercles.

Lungs.—The lungs weighed 4 lbs. 12 ozs.; both cephalic lobes, the right middle, and both caudal lobes with the exception of the dorsal parts, were quite solid and light reddish in colour; the right cephalic lobe was very firm and showed a great increase in interstitial connective tissue and only a few sparsely scattered tubercles—the consolidation of this lobe was probably antecedent to the inoculation. The other consolidated tissue on section was firm, greyish-red, and infiltrated with irregular caseous foci which by uniting together gave the cut surfaces in places an appearance of early diffuse caseous infiltration; the crepitant parts of the dorsal lobes which represented a very small portion of the lung was moderately closely beset with grey miliary caseating tubercles.

Thoracic Glands.—The dorsal mediastinal and bronchial glands were enlarged, weighing together $4\frac{3}{4}$ ozs. On section their cortices were composed of firm grey tissue, mottled with small irregular yellow patches, many containing minute calcareous foci. The medullary parts were deeply congested.

Heart.—In the muscle wall of the right auricle there were a dozen caseating nodules, the largest 3 mm. in diameter; some of these projected on the endocardial, others on the pericardial surface.

Abdomen.

Omentum.—The omentum showed on the ventral surface about a dozen loosely attached flattened caseating tubercles, the largest the size of a millet seed.

Peritoneum.—Normal.

Spleen.—The spleen weighed 11 ozs.; it was firm and showed the pulp moderately closely beset with yellow caseous tubercles, the largest the size of a millet seed.

Liver.—The surface of the liver showed a network of fine fibrous trabeculae. The substance of the liver contained moderately numerous minute evenly distributed greyish opaque tubercles, the largest rather less than 1 mm. in diameter.

Portal Glands.—The portal glands were enlarged; the cortices were firm and composed throughout of nodular caseating masses, slightly gritty from calcification.

Coeliac Glands.—The coeliac glands were enlarged and composed of dense caseating slightly gritty tuberculous tissue.

Kidneys.—On the surface of the left kidney there were two submiliary grey tubercles; none was seen on section.

On the surface of the right there were five minute grey tubercles; in the medulla there was one grey millet-seed sized tubercle.

Suprarenal Bodies.—In the cortex of the left there were four in that of the right three yellow caseous tubercles, the largest the size of a millet seed.

Lumbar and Iliac Glands.—The lumbar and iliac glands were enlarged and closely beset with coalescing caseating nodules.

Alimentary Tract.

Tonsils.—Both tonsils contained a number of caseous nodules up to 3 mm. in diameter.

Pharynx.—In the corrugated mucous membrane there were fairly numerous caseous nodules; there were a few congested tubercles on the dorsal surface of the soft palate.

In the mucous membrane on the side of the tongue there was a single caseous tubercle with an ulcerated surface.

Intestines.—All the Peyer's patches of the small intestine showed moderately numerous caseous nodules up to 2 mm. in diameter, the majority ulcerated.

The solitary follicles of the large intestine were enlarged but not caseous. No tubercles were seen under the mucous membrane.

Mesenteric Glands.—All the mesenteric glands were slightly enlarged, and the cortices extensively replaced by firm grey areas in a state of early caseation.

Ileo-Colic Glands.—The cortices of these glands were composed throughout of reddish-grey tissue infiltrated with a yellow caseous network.

Larynx.—There was a caseous tubercle in the mucous membrane just below one of the vocal chords, and an ulcerated caseous nodule at the junction of the two chords.

Trachea.—The mucous membrane showed scattered congested spots without caseation.

Eyes.—Normal.

Peripheral Lymphatic Glands.

The submaxillary and retro-pharyngeal glands were slightly enlarged and closely beset with caseating nodules in places confluent.

Other peripheral lymphatic glands were closely beset with discrete caseous nodules, the largest 2·5 to 3 mm. in diameter.

Microscopical Examination.

Emulsion of Mediastinal Gland.—Numerous tubercle bacilli.

CALF 1557. Virus H. 105. "G.S."

Subcutaneous inoculation of culture derived from the mediastinal gland of Calf 1527.

Dose—44·0 milligrammes.

Date of Inoculation—April 27, 1909. [Age 13 weeks.]

Killed when in good health—July 21, 1909. [85 days after inoculation.]

Clinical Notes.

A large tumour developed at the seat of inoculation which became soft and fluctuating and finally (on July 13) opened and discharged caseo-purulent matter; the adjacent prescapular gland was much enlarged. The general health of the calf remained good during the entire period of the experiment; it was killed on July 21 on account of the continuous discharge from the abscess.

Temperature.

On the 11th day after inoculation the temperature rose to 40·0° C. It remained high for twelve days and then dropped suddenly to the normal. The highest

temperature recorded during the period of pyrexia was 40·7° C. Subsequently the temperature was approximately normal.

Weights.

	cwt.	qr.	lbs.
April 27, 1909	1	1	5
July 21, 1909	2	0	8

Total gain of weight.—3 qrs. 3 lbs.

Average rate of gain per week.—7·2 lbs.

POST-MORTEM EXAMINATION.

The carcass was fat.

Local Lesion.—At the seat of inoculation on the left side of the neck there was a firm tumour measuring 9·5 by 7 by 4 cm. showing an irregular funnel-shaped ulcer discharging tenacious caseo-pus. On section the tumour was found to be composed mainly of thickened skin (2 cm. in greatest thickness); in the subcutaneous tissues there was a small irregular cavity containing caseo-pus surrounded by a thick pinkish fibroid wall; this communicated with the exterior through the opening in the skin.

Left Prescapular Gland.—The left prescapular gland measured 8 by 5 by 3·4 cm. and was dense caseous and gritty practically throughout; the capsule was thickened, very greatly on the convex surface.

Right Prescapular Gland.—The right prescapular gland was enlarged measuring 7 by 3 by 1·5 cm. and contained numerous spherical caseous and softened nodules with thick fibrous walls ranging up to 4 mm. in diameter.

Prepectoral Glands.—On the left side one the size of a pigeon's egg was composed throughout of dense caseous substance gritty around the margins, the capsule was much thickened. Another gland the size of a pea was similar, a third contained four caseous tubercles.

On the right side two glands contained five caseous nodules.

Cervical Glands.—On the left side four contained scattered caseous nodules up to a hempseed in size.

Every gland on the right side contained a few caseous gritty nodules.

Thorax.

Lungs.—The lungs were crepitant throughout; they contained scattered calcareous tubercles with grey margins up to 1 mm. in diameter; twelve were counted on the surface in an area 5 ins. square; in the thin marginal parts of the lung there were several larger nodules ranging up to a hempseed in size, these were caseous with fibrous margins.

Thoracic Glands.—The bronchial and mediastinal glands showed a moderate degree of enlargement; they showed their cortices extensively replaced by calcareous patches; some were calcareous almost throughout, in others only about two-thirds were affected; in the latter the normal parts of the cortex contained scattered caseous nodules.

Heart.—In the muscle wall of the right auricle there were two calcareous tubercles.

Pleura.—Normal.

Abdomen.

Omentum and Peritoneum.—On the ventral surface of the omentum there was a hempseed-sized fibrous nodule with a caseous centre. The peritoneum was normal.

Spleen.—The spleen was enlarged (weight 1 lb. 2 ozs.), and was moderately closely beset with caseous gritty nodules with grey margins ranging from 1 to 3 mm.; the majority were about 2 mm. in diameter.

Liver.—The liver substance contained scattered opaque whitish calcareous tubercles, the largest rather less than 1 mm. in diameter.

Portal Glands.—The portal glands were slightly enlarged and moderately closely beset with calcareous tubercles up to a millet seed in size.

Pancreatic Glands.—These resembled the portal glands.

Coeliac Glands.—One was enlarged and contained numerous discrete caseous slightly gritty nodules varying from a millet to a hempseed in size; the others contained similar but less numerous nodules.

Kidneys.—In the cortex of the right kidney just under the capsule there were two submiliary grey tubercles with calcareous centres; in the medulla of this kidney there was a hempseed-sized fibrous nodule with a calcareous centre.

In the cortex of the left there was one grey tubercle with an opaque centre, and in the medulla there was a nodule similar to that in the right.

Suprarenal Bodies.—In the cortex of one there were six, and in that of the other five caseous gritty nodules with narrow fibrous margins, the largest rather more than 2 mm. in diameter.

Lumbar Glands.—One was slightly enlarged and closely beset with calcareous tubercles, a few slightly caseous, up to a millet seed in size; the rest were normal in size and contained each a few caseous gritty tubercles.

Renal Glands.—In the cortices of the renal glands there were moderately numerous small calcareous tubercles.

Alimentary Tract.

Tongue, Tonsils, Pharynx.—Normal.

The Parotideal, Submaxillary, and Retro-pharyngeal Glands contained moderately numerous greenish-yellow caseous nodules with fibrous margins, the largest 4 mm. in diameter.

Stomach.—In the wall of the stomach there were several caseous and softened nodules.

Intestines.—In each Peyer's patch there were a few caseous and softened nodules, some gritty ranging up to a hempseed in size; they were smallest and least numerous in the lower part of the ileum.

The large intestine showed one submucous caseous tubercle.

Mesenteric and Ileo-Colic Glands.—The mesenteric glands were slightly enlarged and showed in the cortices moderately numerous calcareous or calcareo-caseous tubercles here and there aggregated together.

The ileo-colic glands resembled the mesenteric.

Testicles.—Normal.

Various Lymphatic Glands.

The Precrural, Popliteal and Pudic Glands were enlarged and contained numerous discrete caseous nodules, varying from a millet to a hempseed in size, but mainly of an intermediate size; the nodules were spherical and stood up from the cut surface; they were slightly gritty and had thin fibrous capsules.

The Iliac, Ischiatic, Gluteal, and Axillary Glands contained similar nodules sparsely scattered.

Microscopical Examination.

Emulsion of Popliteal Gland.—A few tubercle bacilli.

Emulsion of Bronchial Gland.—A few tubercle bacilli.

CALF 1591. Virus H. 105. "G.S."

Subcutaneous inoculation of culture derived from the popliteal gland of Calf 1557.

Dose—50·0 milligrammes.

Date of Inoculation—September 11, 1909. [Age about 8 weeks.]

Killed when in good health—December 10, 1909. [90 days after inoculation.]

Clinical Notes.

The calf remained well during the experiment and increased normally in weight and size.

Temperature.

There was a period of slight pyrexia commencing on the ninth day after inoculation and lasting 16 days (maximum 39·9° C.). Subsequently the temperature was normal.

Weights.

	cwt.	qrs.	lbs.
September 11, 1909	0	3	10
December 10, 1909	1	2	15

Total gain of weight.—3 qrs. 5 lbs.

Average rate of gain per week.—7 lbs.

POST-MORTEM EXAMINATION.

The carcass was in good condition.

Local Lesion.—In the subcutaneous tissues on the left side of the neck there was a lenticular caseous mass (15 by 8·5 by 2·5 cm.) gritty around the margins and breaking down in the centre and surrounded by a fibrous capsule; the skin over it was thickened and the muscles beneath it showed a small fibrous mass, beset with calcareous tubercles, continuous with the capsule.

Left Prescapular Gland.—The left prescapular gland measured 8·5 by 4·5 by 3·5 cm. and showed about three-quarters of the substance composed of dense caseous substance, the rest contained calcareous tubercles.

Right Prescapular Gland.—The right prescapular gland measured 4 by 2 by 1·3 cm. and showed in the cortex several caseo-calcareous nodules varying up to 2·5 mm. in diameter.

Prepectoral Glands.—On the left side one the size of a walnut was dense and caseous throughout and slightly gritty from calcification; the capsule was much thickened; another 8 mm. in diameter was in a similar condition; three others each contained a few small tubercles.

Those on the right side contained a few calcareo-caseous tubercles.

Cervical Glands.—On the left side one of the lower glands was partly caseous and partly calcareous. Other cervical glands contained discrete calcareous or calcareo-caseous tubercles in varying number.

Thorax.

Pleura.—The pleura covering the tendon of the diaphragm was covered in places with a continuous layer, in others with plaques, of vascular connective tissue outgrowths; there were no tubercles.

There were lines of similar tissue along the anterior margins of the posterior ribs, and plaques, not so well developed as on the diaphragm, on the pleura covering the pericardium.

Lungs.—On the pleura of the ventral surface of the caudal lobes there were several loosely-attached soft pinkish connective tissue outgrowths; there were a few similar growths attached to the thin margins of the lobes.

The lung parenchyma was crepitant and collapsed normally; it contained a moderate number of evenly-distributed calcareous tubercles with grey margins, the largest the size of a millet seed, the smallest very minute.

Thoracic Glands.—The bronchial and dorsal mediastinal glands showed a moderate degree of enlargement; the cortices were firm and closely beset with calcareous tubercles discrete and aggregated together forming in some of the larger glands extensive calcareous patches.

Heart.—The endocardium of the right auricle showed a pinhead-sized grey tubercle. In the apex of a papilla in the right ventricle there was a hempseed-sized grey fibrous nodule. In the muscle wall of the left auricle there were two nodules and in the wall of the left ventricle one, similar to that on the right side with the exception that two contained calcareous grains in the centre. There was a small fibrous nodule just under the endocardium of the left ventricle.

Abdomen.

Omentum.—On the ventral surface there were three soft connective tissue growths and elsewhere a patchy hypertrophy of the connective tissue fringes.

Parietal Peritoneum.—Normal.

Spleen.—On the surface of the spleen were a good many vascular connective tissue tufts and outgrowths but no tubercles. On section the pulp contained moderately numerous discrete caseous gritty tubercles ranging from 1 to 2 mm. in diameter.

Liver.—On the convex surface of the liver there were a few small flattened fleshy growths. The substance contained numerous evenly distributed submiliary calcareous tubercles with grey margins.

Portal Glands.—The cortices were closely beset with irregular miliary calcareous tubercles and showed here and there a caseous tubercle.

Coeliac Glands.—One was slightly enlarged and closely beset with irregular calcareous tubercles; others not enlarged contained a small number of similar tubercles.

Kidneys.—In the cortex of each there was a moderate number of greyish translucent tubercles ranging in size from a mere point up to 1 mm.; the larger ones had opaque caseous centres.

Suprarenal Bodies.—The left showed in the cortex four caseous tubercles one of which was gritty. In the cortex of the right there were about a dozen caseous tubercles, the largest 2 mm. in diameter.

Renal Glands.—The renal glands were slightly enlarged and moderately closely beset with calcareous or calcareo-caseous tubercles.

Lumbar Glands.—The lumbar glands contained a moderate number of calcareous or calcareo-caseous tubercles.

Alimentary Tract.

Tongue, Pharynx, Tonsils.—Normal.

The Submaxillary, Parotideal, and Retro-pharyngeal Glands showed in the cortices a moderate number of calcareo-caseous tubercles here and there aggregated together.

Small Intestines.—The long Peyer's patch contained moderately numerous soft whitish foci 1 to 2 mm. in diameter; four other patches contained from one to three similar foci; the rest were normal.

Large Intestine.—Normal.

Mesenteric Glands.—Those at the posterior extremity of the mesentery showed in the cortices a moderate number of irregular caseo-calcareous nodules (aggregated tubercles) and calcareo-caseous tubercles; in the glands anterior to these the tubercles became less and less numerous and were very scanty in the glands at the anterior end of the mesentery.

Ileo-Colic Glands.—These contained rather more numerous tubercles, here and there aggregated together, than the posterior mesenteric glands.

Eyes.—Normal.

Testes.—Normal.

Various Lymphatic Glands.

All the peripheral lymphatic glands (except those mentioned above) showed in the cortices a moderate number of caseo-calcareous tubercles ranging up to about 2 mm. in diameter.

Haemo-lymph Glands.—Several of these glands were found to contain caseous gritty nodules.

Microscopical Examination.

Focus from Peyer's Patch in Small Intestine.—A few tubercle bacilli.

Emulsion of Tubercles from Popliteal Gland.—A moderate number of tubercle bacilli.

RHESUS MONKEY 175. Virus H. 105. "G.S."

(A young animal.)

Subcutaneous inoculation of culture derived from the original material through Guinea-pig 2950.

Dose—1·0 milligramme.

Date of Inoculation—May 22, 1908.

Died—July 8, 1908. [47 days after inoculation.]

Clinical Notes.

The monkey gradually became ill weak and thin; the respiration remained normal. During the last week of life the monkey was very emaciated, and could scarcely crawl about his cage.

Weight at death—1460 grammes.

POST-MORTEM EXAMINATION.

The carcass was emaciated.

Local Lesion.—The skin of the back behind the left scapula over the last three ribs showed an ulcer 3 by 2 cm. in area with raised rounded undermined margins and inverted edges. The floor was dry, reddish, and covered with a thin adherent yellowish layer. The base was formed by the muscles which were beset with caseous tubercles. The floor of the ulcer under the skin was covered with caseo-pus, and the subcutaneous and muscular tissues for a short distance around the margins showed firm caseous nodules and patches.

Axillary Glands.—The glands on the right side were not enlarged; they contained two miliary caseous tubercles.

On the left side there were two enlarged glands, each 1 cm. in diameter, which were caseous and softened throughout. Another small gland contained a millet-seed sized caseous tubercle.

Cervical Glands.—Behind the left clavicle one small gland showed a millet-seed sized caseous tubercle. Other cervical glands showed no sign of caseation.

Vertebral Glands.—In the 10th and 11th interspaces on the left side there were two yellow and caseous softened glands, each about 1 cm. in greatest diameter.

In the 12th interspace on this side there was a small gland which was caseous throughout.

Thorax.

Lungs.—The lungs were pink and crepitant throughout. They contained moderately numerous evenly distributed shotty tubercles with caseous centres and grey margins ranging from about 0·5 to a little more than 1 mm. in diameter. In the right caudal lobe there was a pea-sized caseating nodule.

Bronchial Glands.—The bronchial glands were slightly enlarged, and contained scattered caseous and softened nodules up to 2 mm. in diameter.

Heart.—Normal.

Pleura.—Normal.

Abdomen.

Omentum and Peritoneum.—The omentum showed scattered caseous tubercles, the largest a millimetre in diameter.

The parietal peritoneum was normal.

There were two pinhead-sized caseous tubercles on the meso-colon, and two irregular caseous tubercles situated close together and originating apparently in a lacteal vessel in the mesentery.

A gland near the pylorus in the small omentum was partly caseous.

Spleen.—The spleen was enlarged, measuring 4·5 by 2·8 by 1·4 cm. and was closely beset with yellow caseous tubercles, the largest about 2 mm. in diameter.

The splenic lymphatic glands contained a few yellowish caseous tubercles, the largest 1·5 mm. in diameter.

Liver.—The liver was enlarged and closely and evenly beset with greyish-white tubercles (the larger ones slightly yellowish) ranging in size from a mere point to rather more than 1 mm. in diameter.

Two glands on the pancreas near the hilum of the liver were enlarged and closely beset with yellow caseous coalescing tubercles up to 2 mm. in diameter.

Kidneys.—The left kidney showed on the surface two minute greyish-white tubercles. In the depth of the cortex three caseous tubercles the largest the size of a millet seed were seen.

On the surface of the right there were three pinhead-sized greyish-white tubercles, and there were two in the depth of the cortex.

Suprarenal Bodies.—In the cortex of the right suprarenal there were two miliary caseous tubercles. The left was normal.

Lumbar Glands.—One lumbar gland contained a number of discrete caseous tubercles.

Iliac and Ilio-sacral Glands.—These glands were slightly enlarged and contained each two or three small caseous tubercles.

Alimentary Tract.

Tongue, Pharynx, Tonsils.—Normal.

Submaxillary and Pharyngeal Glands.—Each submaxillary gland contained a pinhead-sized caseous tubercle, and there were two or three minute caseous tubercles in each pharyngeal gland.

Intestines.—Normal.

Mesenteric Glands.—There were about half-a-dozen minute caseous tubercles in the mesenteric glands.

Ileo-Colic and Colic Glands.—Normal.

Inguinal Glands.—On the left side two, the larger the size of a pea, were caseous throughout. Two others, and those on the right side contained each two or three caseous tubercles.

Larynx and Trachea.—Normal.

Brain.—Normal.

Testicles.—Normal.

Microscopical Examination.

Tubercle from Submaxillary Gland.—Tubercle bacilli very numerous.

Tubercle from Right Suprarenal Body.—Tubercle bacilli very numerous.

RHESUS MONKEY 205. Virus H. 105. "G.S."

(A young animal.)

Subcutaneous inoculation of culture derived from the original material through Guinea-pig 2950.

Dose—1·0 milligramme.

Date of Inoculation—August 14, 1908.

Died—October 9, 1908. [56 days after inoculation.]

Clinical Notes.

The monkey remained well and lively for about six weeks after the inoculation; it then lost appetite and became depressed and inactive; weakness and emaciation followed and it died at the close of the eighth week after inoculation.

The weight at death was 1370 grammes.

POST-MORTEM EXAMINATION.

The carcass was emaciated.

Local Lesion.—At the seat of inoculation over the left scapula there was a large ulcer with considerably undermined margins and thin necrotic edges; the exposed floor measured 4 cm. in diameter and was haemorrhagic and necrotic; under the skin immediately around the ulcer there was brownish ill-formed pus and further out still a zone of caseous substance breaking down towards the ulcer.

Axillary Glands.—On the left side there were four enlarged glands; one a centimetre in diameter was caseous and softened practically throughout, the rest were smaller and showed varying degrees of caseation of the cortex.

On the right side one slightly enlarged gland contained a group of caseous tubercles.

Cervical Glands.—On the left side a small gland was beset with caseous tubercles; the rest were normal.

Vertebral Glands.—On the left side there was a chain of six enlarged caseous and softened glands the largest 1 cm. in greatest diameter.

Other vertebral glands were normal.

Thorax.

Pleura, Heart.—Normal.

Lungs.—The lungs were voluminous and emphysematous and showed no areas of collapse; they contained a moderate number only of evenly distributed tubercles varying from a mere point up to a millet seed in size; the smallest ones were grey and translucent throughout, the larger ones caseous in the centre.

Thoracic Glands.—The bronchial glands were slightly enlarged. The praetracheo-bronchial glands contained a few tubercles. The intertracheo-bronchial glands contained rather numerous caseous tubercles.

Abdomen.

The peritoneal cavity contained an excess of serous fluid.

Omentum.—The omentum contained numerous small translucent grey tubercles.

Peritoneum.—Normal.

Spleen.—The spleen was enlarged, measuring 5·5 by 2·5 by 1·5 cm. and was closely beset with softened yellow caseous nodules varying in size from about 1·5 up to 2·5 mm.

Liver.—The liver was enlarged, pale and very soft and contained moderately numerous evenly distributed caseous tubercles with grey margins, the largest the size of a millet seed.

A small gland on the neck of the gall-bladder contained several miliary caseous tubercles.

The gland on the head of the pancreas was enlarged and closely beset with caseous tubercles.

Two small glands in the gastro-splenic omentum were caseous.

Kidneys.—The kidneys each showed in the cortex a few grey tubercles up to a millet seed in size, the larger with caseous centres.

Suprarenal Bodies.—Normal.

Lumbar Glands.—Three lumbar glands were slightly enlarged and contained each two or three soft caseous nodules.

Iliac Glands.—Normal.

Alimentary Tract.

Tongue, Pharynx, Tonsils.—Normal.

Submaxillary Glands.—A submaxillary gland on each side contained one miliary caseous tubercle.

Retro-pharyngeal Glands.—Normal.

Intestines.—Normal.

Mesenteric Glands.—Normal.

Brain.—Normal.

Inguinal Glands.—One left inguinal gland contained a few caseous foci. Other inguinal glands were normal.

RHESUS MONKEY 203. Virus H. 105. "G.S."

(A young animal.)

Subcutaneous inoculation of culture derived from the original material through Guinea-pig 2950.

Dose—0·1 milligramme.

Date of Inoculation—August 14, 1908.

Killed (accidentally)—August 31, 1908. [17 days after inoculation.]

Clinical Notes.

The monkey had been well since the inoculation. Death was due to accident, the monkey having got entangled head downwards in the bars of its cage.

Weight at death—1200 grammes.

POST-MORTEM EXAMINATION.

The carcass was in good condition.

Local Lesion.—In the subcutaneous tissues over the left scapula there was a softened caseous mass measuring 3 by 2 by 1 cm.; the skin over it was intact.

Axillary Glands.—Normal.

Vertebral Glands.—Two vertebral glands on the left side in the 7th and 8th interspaces were slightly enlarged and caseous throughout.

There was no sign of tuberculosis elsewhere.

Microscopical Examination.

Scraping from spleen substance.—One tubercle bacillus seen.

RHESUS MONKEY 303. Virus H. 105. "G.S."

(A young animal.)

Subcutaneous inoculation of culture derived from the lung of Calf 1449.

Dose—1·0 milligramme.

Date of Inoculation—April 8, 1909.

Died—May 22, 1909. [44 days after inoculation.]

POST-MORTEM EXAMINATION.

The carcass was thin. Its weight was 2300 grammes.

Local Lesion.—Over the last four ribs on the right side there was an oval ulcer 4 cm. in length with thin undermined margins; the exposed floor was dry and scabby; the floor beneath the margins was moist and covered with ill-formed pus.

Axillary Glands.—On the right side one the size of a swallow's egg was caseous practically throughout, another contained a few tubercles in the cortex, two others were enlarged but not caseous; the left axillary glands appeared normal.

Cervical Glands.—Normal.

Vertebral Glands.—On the right side extending from the 8th to the 11th interspaces there was a chain of four caseous glands, the largest the size of a split pea.

Thorax.

Lungs.—The lungs were voluminous and crepitant except for a small patch of red hepatisation in the right caudal lobe at a point where the lung was adherent to the enlarged vertebral glands. The lung parenchyma contained moderately numerous shotty caseous tubercles with grey margins, the largest the size of a millet seed.

Bronchial Glands.—The bronchial glands were slightly enlarged and contained discrete caseous tubercles.

Pleura.—Normal.

Heart.—The muscles and valves were normal.

The pericardial sac was filled with clear yellow fluid.

Abdomen.

The peritoneal cavity contained a slight excess of yellow serous fluid.

Omentum.—The omentum showed a moderate number of minute pearly-grey tubercles.

Parietal Peritoneum.—Normal.

Spleen.—The spleen was enlarged, measuring 7 by 3·6 by 2 cm. and closely beset with yellow caseous and softened nodules varying in diameter up to 2 mm., in places confluent.

The Splenic Lymphatic Glands were slightly enlarged and contained a few caseous foci.

Liver.—The liver was normal in colour and texture and showed distributed evenly throughout the substance a moderate number of opaque tubercles ranging from a mere point up to a millimetre in diameter; the great majority were less than 0·5 mm. and were grey or greyish yellow; the larger ones were yellow and caseous.

The gland near the pylorus was slightly enlarged and showed in the cortex discrete caseous tubercles. Two glands on the head of the pancreas were similarly affected.

Kidneys.—Each kidney showed in the cortex scattered miliary tubercles beginning to caseate. In the depth of the cortex of one there was a yellow caseous tubercle the size of a millet seed.

Suprarenal Bodies.—Normal.

Lumbar Glands.—The lumbar glands were slightly enlarged and contained discrete caseous tubercles.

Mesenteric Glands.—There was a minute caseous focus or two in the mesenteric glands.

The remaining organs and glands were examined and found normal.

RHESUS MONKEY 305. Virus H. 105. "G.S."

(A young animal.)

Subcutaneous inoculation of culture derived from the lung of Calf 1449.

Dose—1·0 milligramme.

Date of Inoculation—April 8, 1909.

Died—May 1, 1909. [23 days after inoculation.]

Clinical Notes.

The animal died after a short illness, apparently from cold. The weight at death was 2200 grammes.

POST-MORTEM EXAMINATION.

Local Lesion.—At the seat of inoculation over the right scapula there was a caseous and softened mass the size of a pigeon's egg, the skin over which had broken down.

Axillary Glands.—On the left side one the size of a large pea was caseous throughout, another was partly caseous. Those on the right side were normal.

Vertebral Glands.—On the right side three glands in the 8th and 9th interspaces were enlarged up to a split pea in size and caseous throughout.

Lungs.—One miliary grey tubercle was seen, otherwise the organ was normal.

Thoracic Glands.—A gland just within the entrance to the thorax on the right side was slightly enlarged and extensively caseous. The bronchial glands were normal.

Spleen.—The spleen was not enlarged; it showed in the pulp sparsely scattered miliary caseous tubercles.

Kidneys.—In the cortex of one kidney there was a grey miliary tubercle.

The remaining organs and glands were examined and found normal.

RHESUS MONKEY 297. Virus H. 105. "G.S."

(A young animal.)

Subcutaneous inoculation of culture derived from the portal gland of Calf 1521.

Dose—1·0 milligramme.

Date of Inoculation—April 8, 1909.

Died—May 13, 1909. [35 days after inoculation.]

Clinical Notes.

The animal was ill for ten days, and showed extreme weakness, loss of appetite and emaciation. There was no increase in respiration.

The weight at death was 1470 grammes.

POST-MORTEM EXAMINATION.

The carcass was emaciated.

The amount of tuberculosis appeared insufficient to account for death.

Local Lesion.—Over the right scapula at the seat of inoculation there was a circular ulcerated area measuring 3·5 cm. in diameter. The margins were slightly thickened and undermined and under them there was a layer of caseo-pus; the floor of the ulcer was composed of granulation tissue.

Vertebral Glands.—On the right side in the 7th and 9th interspaces there were two soft caseous glands; one measured 0·5 cm. the other 4 mm. in diameter. Other vertebral glands were normal.

Axillary Glands.—On the right side there was one enlarged gland (1·2 cm.) soft and caseous throughout. Another (0·9 cm.) contained one miliary caseous tubercle and several minute foci.

On the left side a slightly enlarged gland was half occupied by a softened caseous nodule; a second gland was normal.

Cervical Glands.—Normal.

Thorax.

Lungs.—There were moderately numerous translucent tubercles evenly distributed over the surface of the lungs; they varied in size from a mere point up to 1·5 mm. in diameter; the majority were quite small and were translucent throughout, the larger had opaque yellow caseous centres. A few similar tubercles were seen on section.

Bronchial Glands.—One praetracheo-bronchial gland on the right side and one on the left were slightly enlarged and contained two or three small yellowish-white caseous tubercles each; a very small gland on the right side showed a single caseous focus and an enlarged gland on the left side also contained one.

One interbronchial gland on the left side contained two small whitish tubercles, the rest were normal.

Heart and Pleura.—Normal.

Abdomen.

Omentum and Peritoneum.—Three minute opaque whitish tubercles were seen in the omentum. The peritoneum was normal.

Spleen.—The spleen was perhaps a little enlarged; about a dozen tubercles were seen from the surface, they were yellowish in colour and dimly seen through the capsule. On section there were moderately numerous yellow caseous miliary tubercles distributed throughout the substance.

Liver.—Two dozen opaque whitish tubercles were counted on the convex surface of the liver and 17 on the concave surface. They varied in size from a mere point up to 1 mm. in diameter. Similar tubercles were seen with difficulty on section, very sparsely distributed.

Portal Glands.—There were two portal glands which were enlarged and filled with small whitish caseous tubercles. Three small glands lying along the neck of the gall-bladder contained each one or two small whitish caseous tubercles about 1 mm. in diameter.

Coeliac Glands.—The coeliac glands were normal in size; four minute whitish foci were seen in the cortex of one.

Kidneys.—Half-a-dozen very minute grey tubercles were seen on the surface of each kidney. None was seen on section.

Submaxillary Glands.—The one on the right contained two minute caseous foci; in the left there was one minute focus.

All the remaining organs and glands were examined and found normal.

Microscopical Examination.

Smear from a Portal Gland.—Tubercle bacilli moderately numerous.

RHESUS MONKEY 299. Virus H. 105. "G.S."

(A young animal.)

Subcutaneous inoculation of culture derived from the portal gland of Calf 1521.

Dose—1·0 milligramme.

Date of Inoculation—April 8, 1909.

Died—May 2, 1909. [24 days after inoculation.]

Clinical Notes.

The monkey died prematurely, apparently of cold.

The weight at death was 1470 grammes.

POST-MORTEM EXAMINATION.

The carcass was thin.

Local Lesion.—In the subcutaneous tissues over the right scapula there was a thin-walled cyst the size of a pullet's egg filled with mucoid caseo-pus; the skin over it was intact.

Axillary Glands.—On the right side one showed a small caseous patch; another was enlarged but not caseous; the glands on the left side were normal.

Cervical Glands.—In the right posterior triangle

behind the scapula there were two caseous and softened glands the size of hemp seeds.

Vertebral Glands.—In the 7th and 8th interspaces on the right side the glands were enlarged up to a small split pea in size and were caseous throughout; another in the third space on this side was enlarged but not caseous; the rest were normal.

Lungs.—Just under the pleura of one of the lobes a grey tubercle with an opaque centre was seen.

There was no sign of tuberculosis anywhere else in the body.

Microscopical Examination.

Tubercle from Lung.—No tubercle bacilli seen.

RHESUS MONKEY 301. Virus H. 105. "G.S."

(A young animal.)

Intramuscular inoculation of culture derived from the portal gland of Calf 1521.

Dose—1·0 milligramme.

Date of Inoculation—April 8, 1909.

Killed when dying—May 13, 1909. [35 days after inoculation.]

Clinical Notes.

The illness was similar in character to that of its fellow, Monkey 297, but there was no emaciation. The weight at death was 1,600 grammes.

POST-MORTEM EXAMINATION.

The carcass was thin.

Local Lesion.—The skin at the seat of inoculation appeared normal. On removing it a large flat swelling was seen measuring 6 by 5·2 cm.; its anterior margin was just below the right scapula on the right side. On section the swelling was composed of yellow breaking-down caseous substance; it was situated between two layers of muscle, infiltrating both, and was 2 cm. in greatest thickness. The inoculation was evidently intramuscular.

The intercostal muscles below the tumour, between the 8th and 9th and the 9th and 10th ribs were infiltrated with minute yellowish caseous tubercles; the infiltration extended 3 cm. outwards from the heads of the ribs.

Vertebral Glands.—Between the 8th and 10th interspaces on the right side close to the spinal column there was a yellow mass measuring 2·5 by 0·8 cm. which projected slightly into the thorax. This mass consisted of three large caseo-purulent glands with thin fibrous capsules. In the 7th interspace there was a yellow pea-sized nodule similar on section. Other vertebral glands were normal.

Axillary Glands.—On the right side two axillary glands were enlarged and soft, the largest measuring 2 by 0·6 cm. On section the large gland contained a caseous nodule the size of a sweet-pea seed. The other gland contained two or three whitish foci with congested margins.

The left axillary glands were normal in size and on section.

Cervical Glands.—Of two glands lying immediately under the right clavicle, the larger measured 1 by 0·8 cm. and was composed throughout of firm caseous substance; the other was slightly enlarged and appeared normal on section.

Other cervical glands were normal.

Thorax.

Lungs.—Very sparsely scattered tubercles ranging from a mere point up to rather less than 1 mm. in diameter were seen on the surfaces of the lungs; ten were counted on the right and there was a similar number on the surface of the left. A few similar tubercles were seen on section. The majority were opaque and greyish, and the larger ones were yellowish-white, soft and caseous.

Bronchial Glands.—The praetracheo-bronchial gland on the right side was slightly enlarged and contained one whitish focus; the gland on the opposite side contained two similar foci.

One intertracheo-bronchial gland contained a whitish tubercle. The others were normal.

Pleura.—There were two small whitish tubercles on the costal pleura. On the pleural surface of the pericardium there was a whitish opaque tubercle 1 mm. in diameter.

Heart.—Normal.

Abdomen.

Omentum.—In the omentum there were two minute opaque white caseous tubercles. The omental glands were normal.

Peritoneum.—The parietal peritoneum was normal. On the mesentery there were two yellowish-white caseous tubercles, 1 mm. in diameter.

Spleen.—The spleen was slightly enlarged, measuring 4·8 by 2·5 cm. It showed numerous white miliary tubercles some clearly seen and projecting just perceptibly on the surface, others dimly seen through the capsule. On section the tubercles were irregularly distributed, in most places numerous; they varied from 0·5 to 2 mm. in diameter and were soft, and white or yellowish-white in colour.

Liver.—The liver showed on the surface numerous tubercles varying in size from a mere point to 1 mm. in diameter. The majority were quite small. Most of them were yellowish-white and opaque; the smallest were grey; some had grey margins and yellowish centres.

Similar tubercles were moderately numerous in the substance of the liver.

Portal Glands.—One was slightly enlarged and contained a minute whitish focus; another contained several similar foci.

The glands lying along the gall-bladder were normal.

Coeliac Glands.—Normal.

Kidneys.—On the surface of the left kidney six whitish foci were seen, the majority minute, one about 0·5 mm. in diameter; four similar foci were seen on section. Six similar tubercles were seen on the surface of the right and seven or eight on section, the largest not quite 1 mm. in diameter.

Renal Glands.—One contained a minute whitish focus; the other was normal.

Lumbar Glands.—One contained two minute foci.

Iliac Glands.—Normal. One ilio-sacral gland contained a whitish focus.

Inguinal Glands.—The right inguinal glands were normal. On the left side one gland contained two minute whitish foci.

Ventral Mediastinal Glands.—One on the left side contained an aggregation of minute whitish tubercles.

The remaining organs and glands were examined and found normal.

RHESUS MONKEY 341. Virus H. 105. "G.S."

(A young animal.)

Subcutaneous inoculation of culture derived from the bronchial gland of Calf 1465.

Dose—1·0 milligramme.

Date of Inoculation—July 6, 1909.

Died—August 18, 1909. [43 days after inoculation.]

POST-MORTEM EXAMINATION.

The carcass was emaciated. Its weight was 1050 grammes.

Local Lesion.—In the subcutaneous tissues of the back just behind the right scapula, there was an empty cavity the skin over which was thinned and showed a number of ulcers; its walls were formed by granulation tissue covered with a thin layer of caseo-pus.

Axillary Glands.—Two on the right side the largest the size of a pea were caseous and softened throughout. Another smaller gland contained discrete caseous tubercles.

On the left side one the size of a large pea was caseous throughout.

Cervical Glands.—In the left posterior triangle there were three caseous and softened glands the largest the size of a pea. In the right there was one hemp-seed sized caseous and softened gland.

Vertebral Glands.—On the right side the glands in the 6th to the 11th interspaces were enlarged, ranging in size from a hemp seed to a large pea and were caseous and softened throughout.

On the left side there were four similar glands.

Thorax.

Lungs.—The lungs were crepitant and collapsed normally. They contained sparsely scattered grey tubercles with grey margins, the largest the size of a millet seed.

The Bronchial Glands were not enlarged, they contained each one or two minute caseous tubercles.

Heart and Pleura.—Normal.

Abdomen.

Omentum.—The omentum contained scattered minute grey foci and two or three caseous tubercles.

Peritoneum.—Normal.

Spleen.—The spleen was slightly enlarged and showed on section a moderate number of yellow caseous tubercles, the largest 1 mm. in diameter.

Splenic Lymphatic Glands.—Normal.

Liver.—The liver was normal in colour and showed fairly numerous evenly distributed tubercles ranging from a mere point up to a millet seed in size, the larger ones yellowish-white, the smaller greyish-white.

The glands on the pancreas were normal in size and showed in the cortices scattered caseous tubercles.

Kidneys.—The left kidney showed on the surface three millet-seed sized caseous tubercles with grey margins, and in the depth of the cortex four similar but rather smaller tubercles.

On the surface of the right there were two minute grey tubercles, and in the depth a millet-seed sized caseous tubercle.

Suprarenal Bodies.—Normal.

Alimentary Tract.

Tongue.—There was a caseous tubercle under the mucous membrane at the base of the tongue.

Pharynx and Tonsils.—Normal.

Submaxillary Glands.—One gland contained a caseous focus.

Intestines.—Normal.

Mesenteric Glands.—There were a few caseous tubercles up to a millet seed in size in the mesenteric glands.

Colic Glands.—Two colic glands contained each one caseous tubercle.

Inguinal Glands.—There were four minute caseous tubercles in the right inguinal glands; the left were normal.

RHESUS MONKEY 343. Virus H. 105. "G.S."

(A young animal.)

Subcutaneous inoculation of culture derived from the bronchial gland of Calf 1465.

Dose—1·0 milligramme.

Date of Inoculation—July 6, 1909.

Died—August 30, 1909. [55 days after inoculation.]

POST-MORTEM EXAMINATION.

The carcass was in poor condition. Its weight was 1140 grammes.

Local Lesion.—Over the posterior ribs on the right side there was an ulcer measuring 4 by 2 cm. in area with a reddish granular floor discharging pus, partially covered with a brownish scab.

Axillary Glands.—On the right side two were caseous and softened throughout while two others contained discrete caseous tubercles.

On the left side one the size of a large pea was caseous throughout, two others contained discrete tubercles.

The Cervical Glands appeared normal.

Vertebral Glands.—In the 8th to the 10th interspaces on the right side there were three caseous and softened glands the largest 1 cm. in greatest diameter; between the upper dorsal vertebrae and the trachea there were two enlarged glands the cortices of which were beset with caseous tubercles. Other vertebral glands were normal.

Thorax.

Lungs.—The lungs were crepitant and showed moderately numerous grey miliary tubercles with caseous centres, evenly distributed throughout.

Bronchial Glands.—The bronchial glands were slightly enlarged and contained discrete caseous tubercles.

Heart and Pleura.—Normal.

Abdomen.

Omentum and Peritoneum.—The omentum contained numerous grey translucent miliary tubercles. The peritoneum was normal.

Spleen.—The spleen was enlarged measuring 6 by 3·5 by 1·5 cm. and was closely beset with caseous and softened nodules ranging up to 2·5 mm. in diameter.

The Splenic Lymphatic Glands were slightly enlarged, one contained one the other two miliary caseous tubercles.

Liver.—The liver was normal in colour and contained only a moderate number of tubercles ranging up to a millet seed in size; the larger ones were caseous in the centre, the smaller ones were grey throughout.

The glands on the pancreas were enlarged and showed their cortices filled with caseous tubercles.

Kidneys and Suprarenal Bodies.—Normal.

Iliac and Lumbar Glands.—There was a caseous tubercle or two in the iliac glands, and there were numerous caseous tubercles in the enlarged lumbar glands.

Alimentary Tract.

Tongue, Pharynx, Tonsils, Intestines.—Normal.

Submaxillary and Retropharyngeal Glands.—These glands contained scattered miliary caseous tubercles.

The Mesenteric, Ileo-colic and Colic Glands contained scattered tubercles.

Inguinal Glands.—On the right side one contained three caseous and softened tubercles; those on the left side were normal.

Brain.—Normal.

RHESUS MONKEY 313. Virus H. 105. "G.S."

(A young animal.)

Subcutaneous inoculation of culture derived from the mediastinal gland of Calf 1527.

Dose—Slightly less than 1·0 milligramme.

Date of Inoculation—April 27, 1909.

Died—July 12, 1909. [76 days after inoculation.]

POST-MORTEM EXAMINATION.

The carcass was thin. The weight at death was 1720 grammes.

Local Lesion.—Just below the angle of the right scapula there was an ulcer 1 cm. in diameter discharging pus, leading into a space in the subcutaneous tissues measuring 3 by 2 cm.; the space was lined internally with granulation tissue covered with ill-formed pus.

Axillary Glands.—On the right side one the size of a thrush's egg was caseous and softened practically throughout; others on this side and those on the left were normal.

Cervical Glands.—On the right side, one the size of a pea was caseous throughout; on the left one contained a millet-seed sized caseous tubercle.

Vertebral Glands.—On the right side, extending from the 9th to the 11th interspaces there was a mass composed of three caseous and softened glands which had fused together; in each of the spaces above and below these there was a small softened and caseous gland.

On the left side in the 11th interspace there was a gland with a hemp-seed sized caseous nodule.

Thorax.

Lungs.—The lungs were full and did not collapse; they were however largely crepitant, their surfaces being mottled with irregular red patches of congestion some quite airless; the lung parenchyma was closely beset with caseous nodules ranging from 1 to nearly 3 mm. in diameter, the majority 1·5 to 2 mm.; they stood up from the cut surface and readily shelled out.

Bronchial Glands.—The cortices of the inter-bronchial glands were extensively replaced by caseous nodules; the praetracheo-bronchial were not so severely affected and contained discrete nodules.

Heart, Pericardium, and Pleura.—Normal.

Abdomen.

Omentum and Peritoneum.—The omentum contained numerous minute greyish-white and grey translucent tubercles and a number of larger caseous nodules ranging up to a hemp seed in size. The parietal peritoneum was normal.

Spleen.—The spleen was greatly enlarged, measuring 8 by 4·5 by 2·5 cm., and its pulp was almost entirely replaced by caseous and softened nodules up to 5 mm. in diameter.

Three of the splenic lymphatic glands contained each a caseous and softened nodule.

Liver.—The liver contained a moderate number of evenly-distributed yellow caseous nodules varying from 1 to 3 mm. in diameter.

Two glands on the head of the pancreas were slightly enlarged and their cortices closely beset with caseous nodules up to 2·5 mm. in diameter.

Kidneys.—The right showed on the surface about two dozen caseous nodules up to 2·5 mm. in diameter, and a few similar nodules were seen in the depth.

There was a similar number in the cortex of the left and a few in the depth.

Suprarenal Bodies.—Normal.

Iliac and Lumbar Glands.—The iliac glands contained each one or two caseous nodules.

The lumbar glands contained several caseous tubercles up to a millet seed in size.

Alimentary Tract.

Tongue, Pharynx, Tonsils.—Normal.

Submaxillary Glands.—One on the left side contained one caseous nodule, one on the right contained two.

Stomach.—There were two caseous tubercles in the wall of the stomach.

Intestines.—Here and there in the wall of the small intestine there was a caseous tubercle. The large intestine was normal.

Mesenteric Glands.—The mesenteric glands contained one caseous tubercle.

Ileo-colic Glands.—Normal.

Colic Glands.—Three were slightly enlarged and caseous.

Brain.—There were two caseous nodules 2 mm. in diameter in the cerebral cortex, one in the left parietal, the other in the left temporo-sphencidal lobe; both nodules were adherent to the dura mater.

Inguinal Glands.—The inguinal glands on the right side contained two caseous and softened nodules; those on the left side were normal.

Pudic Glands.—Two pudic glands contained each a caseous and softened nodule, the largest 3 mm. in diameter.

RHESUS MONKEY 315. Virus H. 105. "G.S."

(A young animal.)

Subcutaneous inoculation of culture derived from the mediastinal gland of Calf 1527.

Dose—1·0 milligramme.

Date of Inoculation—April 27, 1909.

Died—July 10, 1909. [74 days after inoculation.]

POST-MORTEM EXAMINATION.

The carcass was emaciated. The weight at death was 1550 grammes.

Local Lesion.—The skin on the right side over the lower ribs and anterior lumbar region showed an ulcer 5 by 3·5 cm. in area, with a smooth red floor showing patches of caseo-necrotic substance, and undermined inverted margins; the muscular tissues around the margins of the ulcer were beset with caseous nodules and there were numerous discrete caseous tubercles up to 2 mm. in the subcutaneous tissues between the posterior margins of the ulcer and the great trochanter of the femur.

Axillary Glands.—On the right side there were three large glands the largest 1·5 cm. in length which were caseous and softened throughout. Two small glands were also caseous throughout and another contained discrete caseous nodules.

On the left side two glands each contained a few caseous nodules up to 2·5 mm. in diameter.

Cervical Glands.—On the right side one in the posterior triangle contained a caseous tubercle, on the left side two contained each one caseous tubercle.

Vertebral Glands.—On the right side extending from the 8th to the 10th interspace there was a caseous and softened mass 2·5 cm. in greatest diameter formed apparently by the fusion of two glands; in a corresponding situation on the opposite side there were two glands each of which contained two caseous nodules.

Thorax.

Lungs.—The lungs were fuller and firmer than normal, but crepitant with the exception of some irregular red patches in the left caudal lobe and here and there in the right; they contained moderately numerous evenly distributed yellow caseous tubercles ranging from 1 to 2 mm. in diameter.

The Bronchial Glands were congested and slightly enlarged, and each contained a few caseous tubercles.

Heart.—In the muscle wall of the right auricle there was a millet-seed sized caseous tubercle.

Pleura.—Normal.

Abdomen.

Omentum and Peritoneum.—In the omentum there were scattered caseous nodules varying in size from a millet seed to a small pea.

On the mesentery and mesocolon there were sparsely-scattered yellow caseous tubercles.

The parietal peritoneum was normal.

Spleen.—The spleen was enormously enlarged, measuring 10 by 5 by 2 cm.; it was firm and showed under the capsule numerous yellow slightly projecting nodules; on section the pulp was extensively replaced by yellow caseous and softened nodules the largest 4 mm. in diameter.

Splenic Glands.—Three splenic lymphatic glands were slightly enlarged and contained each three or four millet-seed sized caseous tubercles.

Liver.—The liver was normal in colour and showed sparsely scattered throughout its substance yellow caseous tubercles varying from a pin-head to a millet seed in size.

The Pyloric and Portal Glands were enlarged and their cortices closely filled with yellow caseous tubercles up to 2 mm. in diameter.

Kidneys.—Each kidney showed in the cortex a moderate number of evenly distributed caseous tubercles up to a millet seed in size.

Suprarenal Bodies.—One showed in the cortex a miliary caseous tubercle.

Lumbar and Iliac Glands.—One lumbar gland was caseous throughout, the other contained discrete caseous nodules.

On the right side two iliac glands contained four caseous and softened nodules; those on the left side were normal.

Alimentary Tract.

Tongue, Pharynx, Palate, Tonsils.—Normal.

The Submaxillary Glands on each side contained from one to three caseous nodules.

The Pharyngeal Glands were slightly enlarged and each contained a few caseous nodules.

Intestines.—Normal.

A gland near the cardiac end of the oesophagus contained four caseous tubercles.

Mesenteric Glands.—The mesenteric glands contained two caseous tubercles and there was one in an ileo-colic gland.

Colic Glands.—Three colic glands contained each a caseous nodule.

Genito-Urinary System.

Testes.—The right testicle contained a firm caseous nodule 5 mm. in diameter; in the left there was a caseous tubercle 2 mm. in diameter.

Epididymes.—The epididymis on each side contained a few caseous nodules up to a hemp seed in size.

Pudic Glands.—One pudic gland contained a caseous nodule.

Inguinal Glands.—All the inguinal glands on the right side were enlarged and caseous practically throughout. On the left side the glands contained three caseous and softened nodules the largest the size of a hemp seed.

RHESUS MONKEY 357. Virus H. 105. "G.S."

(A young animal.)

Subcutaneous inoculation of culture derived from the popliteal gland of Calf 1557.

Dose—1·0 milligramme.

Date of Inoculation—September 11, 1909.

Died—October 23, 1909. [42 days after inoculation.]

POST-MORTEM EXAMINATION.

The carcass was thin. Its weight was 1700 grammes.

Local Lesion.—The skin of the back over the angle of the right scapula showed an ulcer measuring 3·5 by 2·5 cm. in area with thin undermined margins and caseous floor.

The muscles beneath the ulcer showed a few caseous tubercles.

Axillary Glands.—On the right side one 1 cm. in diameter was caseous throughout, another was three quarters caseous, a third contained two caseous tubercles.

On the left side two contained each two or three minute caseous tubercles.

Cervical Glands.—In the posterior triangle on each side there were two enlarged glands, one the size of a small pea was caseous throughout, the other smaller one was partly caseous.

A right upper cervical gland contained a caseous tubercle.

Vertebral Glands.—On the right side a gland in the eighth interspace the size of a large pea was caseous throughout; another in the 9th space contained a small caseous nodule. Other vertebral glands were normal.

Thorax.

Pleura.—There was a millet-seed sized caseous tubercle on the pleural surface of the pericardium.

Lungs.—The lungs were crepitant but collapsed only partially; they contained numerous evenly distributed shotty caseous tubercles with grey margins the largest the size of a millet seed. There were also minute translucent tubercles scattered about.

Bronchial Glands. — The praetracheo - bronchial glands were slightly enlarged and contained each a few caseous tubercles.

The intertracheo-bronchial glands were also slightly enlarged and contained a moderate number of caseous tubercles.

Abdomen.

The peritoneal cavity was full of clear serous fluid.

Omentum. — The omentum contained scattered minute grey tubercles and four caseous tubercles up to a pin's head in size.

Meso-colon.—There was one caseous tubercle on the meso-colon.

Spleen.—The spleen was enlarged, measuring 6 by 3 by 1·5 cm., and showed the pulp moderately closely beset with yellow caseous tubercles ranging in size up to that of a millet seed.

The splenic lymphatic glands were slightly enlarged, and contained miliary caseous tubercles.

Liver.—The liver was slightly paler than normal, and contained scattered caseous tubercles varying from a mere point up to 1 millimetre in diameter.

The gland on the head of the pancreas was slightly enlarged, and showed in the cortex numerous discrete miliary caseous tubercles.

The pyloric gland contained half-a-dozen caseous tubercles.

Kidneys.—The right kidney showed in the cortex two minute caseous tubercles; in that of the left there were two on the surface and one in the depth.

Iliac and Lumbar Glands.—Three iliac glands contained each one caseous tubercle. A lumbar gland contained several caseous tubercles.

Mesenteric Glands.—The mesenteric glands were slightly enlarged and contained about half-a-dozen caseous tubercles.

Inguinal Glands.—The inguinal glands on each side contained two or three miliary caseous tubercles.

Submaxillary Glands.—Each group of submaxillary glands contained two or three caseous tubercles.

The remaining organs and glands were examined and found normal.

RHESUS MONKEY 359. Virus H. 105. "G.S."

(A young animal.)

Subcutaneous inoculation of culture derived from the popliteal gland of Calf 1557.

Dose—1·0 milligramme.

Date of Inoculation—September 11, 1909.

Died—October 22, 1909. [41 days after inoculation.]

POST-MORTEM EXAMINATION.

The carcass was thin. Its weight was 1500 grammes.

Local Lesion.—The skin over the right scapula showed a small ulcer which led into a large flat space in the subcutaneous tissues lined with granulation tissue, in the walls of the space there was a small quantity of pus.

Axillary Glands.—On the right side three were caseous and softened practically throughout, a fourth was partly caseous; on the left side one gland the size of a pea was caseous throughout.

Cervical Glands.—On the right side one in the posterior triangle the size of a large pea was caseous throughout.

Vertebral Glands.—On the right side two, one in the 8th and one in the 9th interspace, were the size of split peas and were caseous and softened throughout.

Thorax.

Lungs.—The lungs were crepitant throughout and contained numerous evenly distributed miliary tubercles, some were grey and translucent but the majority had caseous centres.

Bronchial Glands.—The bronchial glands were perhaps slightly enlarged; they contained altogether about a dozen miliary caseous tubercles.

Abdomen.

Omentum.—The omentum contained scattered minute translucent grey tubercles and a few pinhead-sized caseous tubercles.

Liver.—The liver was pale and showed sparsely scattered submiliary greyish-white tubercles.

Spleen.—The spleen was normal in size and contained a moderate number of miliary caseous tubercles.

One splenic lymphatic gland contained a caseous tubercle.

Kidneys.—The left kidney showed in the cortex four submiliary grey tubercles; there were about half-a-dozen tubercles in the cortex of the right kidney, one was caseous the others were grey.

A gastric gland and the gland on the head of the pancreas were slightly enlarged and beset with caseous tubercles.

The mesenteric glands contained three caseous tubercles, and there was one caseous tubercle in an ileo-colic gland.

Submaxillary Glands.—Those on the left side contained two caseous tubercles; those on the right were normal.

The remaining organs and glands were examined and found normal.

VIRUS H. 105. "G.S."

ABSTRACTS OF THE POST-MORTEM NOTES OF RABBITS INOCULATED WITH CULTURES DERIVED FROM THE CALVES USED IN THE PASSAGE EXPERIMENTS WITH THE VIRUS.

1.—Subcutaneous Inoculations.

Source of Culture Inoculated.	Dose in Milli-grammes.	Number of Rabbit.	Weight in Grammes.		Duration of Life.	Result.
			Initial.	Final.		
						Series *a*.
Calf 1449 (1st calf) Popliteal gland.	5·0 mg.	2084	1,750	1,400	Died 116 days	General tuberculosis, moderately severe. There was a nodular caseous local tumour and the nearest glands were caseous. The thin margins of the lungs were solid and caseous, the surface elsewhere showed numerous grey or yellowish tubercles in places confluent; on section the lungs were crepitant and contained a moderate number of caseous miliary tubercles. The kidneys were enlarged and showed on the surfaces numerous tubercles with caseous centres, and a few larger wedge-shaped nodules caseous with grey margins; the medullae showed many caseous streaks. There were a few small foci in the liver, appendix, and on the mesentery. Several lymphatic glands contained caseous tubercles.
	1·0 mg.	2083	2,570	1,700	Died 96 days	General tuberculosis, moderately severe. The local lesion was caseous and softened, and the adjacent glands were caseous or contained caseous nodules. The lungs were enlarged but crepitant and contained numerous miliary caseous tubercles, confluent posteriorly; in the thin margins there were several caseous patches. The kidneys were closely beset with caseous tubercles with grey margins. One bronchial and most of the abdominal lymphatic glands contained caseous tubercles; there were caseous tubercles on the mediastinal pleura, and a few minute foci in the liver.
Lung.	10·0 mg.	2085	1,770	1,100	Died 144 days	General tuberculosis, severe. There were two walnut-sized softened caseous nodules at the seat of inoculation and the nearest glands were caseous. The lungs were large and composed almost entirely of dense caseous substance. The cortices of the kidneys were very closely beset with caseous tubercles, and showed also a number of caseous nodules up to a pea in size; caseous tubercles and streaks were seen in the medullae. There were caseous tubercles in all the lymphatic glands, tubercles on the omentum, and one or two tubercles on the pleura and in the spleen.
	10·0 mg.	2086	1,470	1,420	Died 145 days	Slight general tuberculosis; the cause of death was not apparent. The local lesion was small and caseous; the nearest gland was very large, caseous, and softened. The lungs showed caseating patches in the thin margins, some caseous thin-walled nodules in the caudal lobes, and scattered tubercles elsewhere. The kidneys showed on the surface a few caseous nodules with grey margins, and on section a few caseous and softened streaks. There were a few caseous tubercles on the pleura.
Calf 1521 (2nd calf) Portal gland.	1·0 mg.	2293	1,450	870	Died 46 days	General tuberculosis (equal in severity to that produced by a bovine tubercle bacillus).
	1·0 mg.	2294	2,650	1,550	Died 109 days	Slight generalised tuberculosis; death was due to paralysis of the hind quarters. The local lesion was a thin-walled cyst filled with caseo-pus, and the nearest glands were partly caseous. The lungs contained scattered caseating nodules, the largest the size of a split pea. There was a caseous tubercle in one kidney, and no tuberculosis elsewhere.

VIRUS H. 105. "G.S."—*continued.*

ABSTRACTS OF THE POST-MORTEM NOTES OF RABBITS INOCULATED WITH CULTURES DERIVED FROM THE CALVES USED IN THE PASSAGE EXPERIMENTS WITH THE VIRUS—*continued.*

SUBCUTANEOUS INOCULATIONS—*continued.*

Source of Culture Inoculated.	Dose in Milli-grammes.	Number of Rabbit.	Weight in Grammes.		Duration of Life.	Result.
			Initial.	Final.		
Calf 1465 (3rd calf) Bronchial gland.	1·0 mg.	2384	2,000	1,250	Died 122 days	Chronic general tuberculosis, not severe. There was a thin-walled baggy cyst containing caseo-purulent masses at the seat of inoculation ; the adjacent gland was partly caseo-purulent. The lungs showed in the thin margins half-a-dozen firm caseous patches, and elsewhere a number of miliary caseous tubercles with grey margins. Each kidney showed a moderate number of caseous tubercles and caseous streaks ; in one there was also a projecting pea-sized grey nodule with caseous foci. One or two caseous tubercles were seen in a coeliac and a popliteal gland, and in the iris of one eye.
	1·0 mg.	2385	1,450	2,700	Killed 139 days	Very slight generalised tuberculosis. There was a thin-walled cyst containing caseo-pus at the seat of inoculation, and the nearest gland was caseo-purulent. The lungs contained a few small nodules with caseous or calcareous centres. In one kidney there was a grey tubercle. No tuberculosis elsewhere.
Calf 1573 (4th calf) Lung.	10·0 mg.	2483	1,800	1,420	Died 71 days	General tuberculosis. There were two cystic local lesions, and the nearest glands were tuberculous. The lungs were enlarged and composed of firm reddish tissue beset with caseous tubercles, and caseous patches. The kidneys showed moderately numerous tubercles some small and grey others larger with caseous centres. All the lymphatic glands contained caseous nodules or tubercles. The spleen was slightly enlarged and the liver showed a few tubercles (?).
	10·0 mg.	2484	1,750	1,250	Died 74 days	General tuberculosis. The lungs were enlarged and closely beset with caseous tubercles in places confluent. The cortices of the kidneys were closely beset with projecting caseating nodules. There were scattered tubercles in the liver and spleen and all the lymphatic glands were tuberculous.
	10·0 mg.	2485	2,020	1,520	Died 66 days	General tuberculosis. There was a caseous and softened lesion at the seat of inoculation and the nearest glands were tuberculous. The lungs were large and were composed of reddish consolidated tissue containing caseous foci and (in the caudal lobes) large caseous areas. The tracheal glands were partly caseous. The kidneys showed numerous grey tubercles with caseous centres and the spleen scattered caseous tubercles ; all the lymphatic glands contained caseous tubercles.
	10·0 mg.	2486	1,520	1,300	Died 113 days	General tuberculosis. Local tuberculosis. The lungs were beset with caseous nodules in places confluent ; in the kidneys were moderately numerous grey tubercles with minute caseous centres, caseous streaks, and (in one) caseo-pus in the pelvis. Some of the lymphatic glands contained caseous tubercles.
	10·0 mg.	2487	1,700	1,420	Died 75 days	General tuberculosis. Local lesion ; caseous nodules in scapular glands. The lungs were partly composed of consolidated caseating tissue and partly closely beset with caseous nodules ; there were a few tubercles in the spleen and a few doubtful foci in the liver. The kidneys showed each a moderate number of grey tubercles and one or two grey nodules with caseous foci. All the lymphatic glands were affected.

	10·0 mg.	2488	1,850	1,370	Died 55 days	General tuberculosis. The lungs were closely beset with caseating nodules in places confluent. The spleen contained scattered caseous tubercles. There was a moderate number of caseating tubercles in each kidney. All the lymphatic glands were affected, many containing numerous caseous tubercles.
						Series β.
Calf 1405 (1st calf) Popliteal gland.	10·0 mg.	2139	1,700	1,190	Died 50 days	General tuberculosis, not severe. There was a large ulcerated tumour at the seat of inoculation and the nearest glands contained caseous patches. The lungs were crepitant and contained a moderate number of miliary grey tubercles with caseous centres. The spleen showed scattered caseous submiliary tubercles. The kidneys showed numerous grey nodules from 1 to 4 mm. in diameter with caseous centres, a few causing slight projections. The portal and coeliac glands contained caseous tubercles.
	10·0 mg.	2140	1,450	1,100	Died 120 days	Chronic general tuberculosis, not severe. There was a large dry scabby ulcer, and the nearest glands were caseous. The lungs showed in the thin margins caseous gritty patches and elsewhere scattered caseous gritty tubercles and a few grey ones. Each kidney showed on the surface numerous pits and a moderate number of caseo-calcareous tubercles, and on section a few caseous streaks. There were gritty caseous nodules in the bronchial glands and two or three minute yellow points in the spleen.
Calf 1527 (2nd calf) Mediastinal gland.	1·0 mg.	2323	1,220	1,100	Died 101 days	General tuberculosis. The local lesion was a thin-walled cyst filled with caseo-pus, and the nearest glands were caseous. The lungs contained a moderate number of miliary caseous nodules and a few split-pea sized nodules. The cortices of the kidneys were closely beset with firm caseous pea-sized nodules, prominent and on section wedge shaped. There were one or two caseous tubercles in the liver, spleen, and several lymph glands.
	0·5 mg.	2324	1,550	1,370	Died 159 days	General tuberculosis. The local lesion was a thin-walled cyst filled with caseo-pus and the nearest glands contained caseous nodules. The thin margins of the lungs were caseating and elsewhere there were moderately numerous grey miliary tubercles. The cortices of the kidneys were filled with firm projecting caseating nodules (typical bovine nodules). There was early tuberculosis of the costal pleura; the omentum was filled with tubercles and there were caseous tubercles on the mesentery and meso-colon. The popliteal and iliac glands contained caseous nodules and the coeliac glands caseous foci.
Calf 1557 (3rd calf) Popliteal gland.	10·0 mg.	2447	1,750	1,350	Died 73 days	General tuberculosis. The local lesion was caseous and partly softened, and the nearest glands contained caseous nodules. The lungs were crepitant, and showed on the surface moderately numerous irregular caseating nodules and tubercles in places confluent; in the depth the nodules and tubercles were less numerous. The kidneys were enlarged, and their cortices were filled with caseating tubercles. There were two caseating tubercles on the surface of the heart. Many lymphatic glands contained one or more caseous tubercles.
	10·0 mg.	2448	1,650	1,850	Killed 94 days	General tuberculosis. There was a softened local lesion, and the nearest glands were caseous and softened. The lungs contained caseating nodules moderately numerous and here and there confluent on the surface, less numerous in the depth; the larger bronchi were filled with caseo-pus. The cortices of the kidneys were rather closely beset with caseating nodules (up to 3 mm.), the larger ones projecting slightly. Both eyes were tuberculous and disorganised, and one lachrymal gland contained two caseous nodules. The dilated end of the ileum and the appendix showed scattered caseous tubercles.
	10·0 mg.	2449	1,500	1,100	Died 58 days	General tuberculosis. There was a large caseous local lesion, and the nearest glands were caseating. The lungs were crepitant, but contained fairly numerous firm caseous nodules, for the most part discrete. There were scattered submiliary caseous tubercles in the spleen, and a few whitish tubercles in the liver; the portal glands were caseating. In the cortex of each kidney fairly numerous grey miliary tubercles with caseous centres were seen. A caseous tubercle was seen in each popliteal gland.

VIRUS H. 105. "G.S."—*continued.*

ABSTRACTS OF THE POST-MORTEM NOTES OF RABBITS INOCULATED WITH CULTURES DERIVED FROM THE CALVES USED IN THE PASSAGE EXPERIMENTS WITH THE VIRUS—*continued.*

SUBCUTANEOUS INOCULATIONS—*continued.*

Source of Culture Inoculated.	Dose in Milli-grammes.	Number of Rabbit.	Weight in Grammes.		Duration of Life.	Result.
			Initial.	Final.		
Calf 1591 (4th calf) Popliteal gland.	10·0 mg.	2506	3,050	2,550	Killed 70 days (when ill.)	Local tuberculosis, tuberculosis of lungs (severe) and kidneys (moderately severe). There was an abscess at the seat of inoculation and the nearest glands were extensively caseous. The lungs were closely beset with grey caseating nodules becoming confluent. The cortices of the kidneys showed numerous caseating tubercles some projecting. There was no tuberculosis elsewhere.
	10·0 mg.	2507	4,000	3,000	Died 69 days	Local tuberculosis, tuberculosis of lungs (severe) and kidneys (moderately severe). Death resulted from a secondary infection. The lungs were large and extensively tuberculous on the surface; internally they were crepitant and contained discrete tubercles. There were moderately numerous small caseous tubercles in the kidneys. The portal gland contained caseous tubercles.
	10·0 mg.	2508	3,070	2,600	Killed 70 days	Local tuberculosis; the lungs and kidneys contained scattered tubercles; there was no tuberculosis elsewhere
	10·0 mg.	2509	2,990	2,120	Died 45 days	Very slight general tuberculosis. Death from pneumonia.

2.—Intravenous Inoculations.

					Series α.	
Calf 1521 (2nd calf) Portal gland.	1·0 mg.	2292	1,650	1,200	Died 18 days	General miliary tuberculosis.
	0·01 mg.	2290	1,700	1,300	Died 32 days	Severe general tuberculosis.
					Series β.	
Calf 1527 (2nd calf) Mediastinal gland.	1·0 mg.	2322	1,650	1,100	Died 15 days	Acute generalised tuberculosis.
	0·1 mg.	2321	1,520	1,000	Died 21 days	General miliary tuberculosis.
	0·01 mg.	2320	1,520	1,250	Died 22 days	General tuberculosis.

VIRUS H. 106. "K.R."

LUPUS.

VIRUS H. 106. "K.R." [Lupus.]

CULTURE INOCULATIONS.

I.—April 28, 1908.

The strain was derived from the original material through Guinea-pig 2952, and had been in artificial cultivation a total period of 38 days.

The culture used was the 3rd generation, 14 days old.

RABBITS.

Number.	Method.	Dose.	Duration of Life.	Result.
1835	Intrav.	1·0 mg.	K. 160 days	T. of kidneys only.
1836	Intrav.	0·1 mg.	D. 22 ,,	Slight general T.
1837	Intrav.	0·01 mg.	D. 2 ,,	No cause of death found.
1838	Subcut.	50·0 mg.	K. 160 ,,	Local lesion only.
1839	Subcut.	20·0 mg.	K. 160 ,,	Local lesion only.

GUINEA-PIGS.

Number.	Method.	Dose.	Duration of Life.	Result.
3033	Intrap.	1·0 mg.	D. 45 days	G. T. (not severe).
3034	Subcut.	1·0 mg.	,,	
3032	Subcut.	0·1 mg.	D. 218 ,,	Local T. Cause of death not apparent.

MONKEY 155.

Subcutaneous.

Dose : 1·0 mg.

Died : June 7, 1908.

40 days.

P.M.—Early general tuberculosis. The cause of death was not apparent.

CALF 1403.

Subcutaneous.

Dose : 50·0 mg.

Killed : August 18, 1908.

112 days.

P.M.—No tuberculosis. The tumour at the seat of inoculation was composed of thickened skin and a small mass of fibroid tissue ; there was no caseation or calcification. The left prescapular gland was normal.

VIRUS H. 106. "K.R."—*continued.*

CULTURE INOCULATIONS—*continued.*

II.—May 15, 1908.

The strain was derived from a single colony, one of three which grew on an egg tube sown with the original material ; the total duration of artificial cultivation was 91 days.

The 4th generation of culture was used, 17 days old.

RABBITS.

Number.	Method.	Dose.	Duration of Life.	Result.
1857	Intrav.	0·1 mg.	K. 143 days	Slight T. of kidneys.
1858	Intrav.	0·01 mg.	K. 143 „	One nodule in the lung.
1859	Subcut.	50·0 mg.	K. 143 „	Local lesion only.

RAT 61.

Intraperitoneal.

Dose : 55·0 mg.

Died : 141 days.

P.M.—No definite tuberculosis except in omentum ; numerous T.B. all over the body.

FOWLS.

Number.	Method.	Dose.	Duration of Life.	Result.
103	Intrav.	10·0 mg.	D. 45 days	Few translucent tubercles in lungs ; T.B. in spleen.
105	Intrav.	50·0 mg.	K. 129 „	No visible lesions. T.B. in spleen.

CALF 1403. Virus H. 106. "K.R."

Subcutaneous inoculation of culture derived from the original material through Guinea-pig 2952.

Dose—50·0 milligrammes.

Date of Inoculation—April 28, 1903. [Age about 10 weeks.]

Killed when in good health—August 18, 1908. [112 days after inoculation.]

Clinical Notes.

The calf remained well during the experiment.

Temperature. (Chart to July 8.)

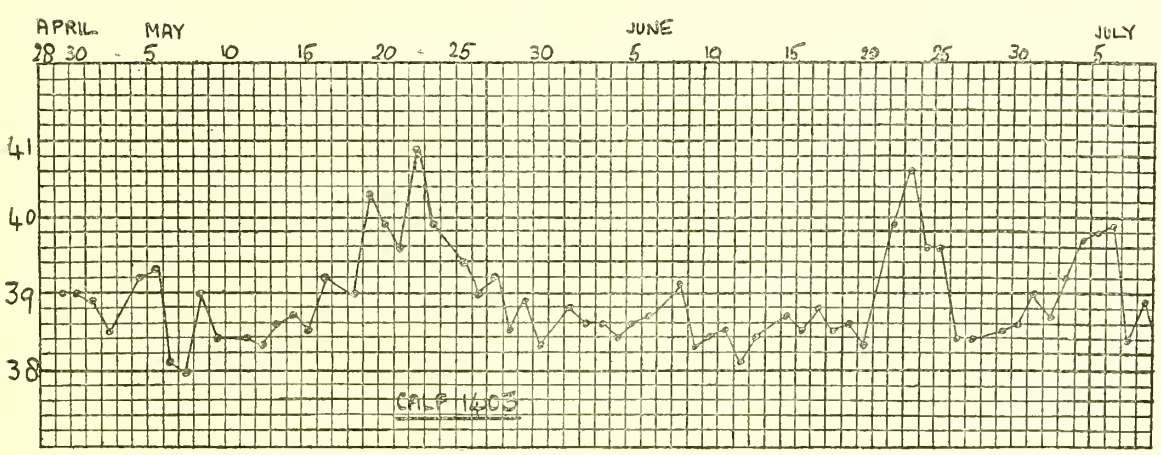

From July 8 to August 18 the temperature was approximately normal.

Weights.

	cwt.	qr.	lbs.
April 28, 1908	1	0	7
August 18, 1908	1	3	15

Total gain of weight.—3 qrs. 8 lbs.

Average rate of gain per week.—5·7 lbs.

POST-MORTEM EXAMINATION.

The carcass was in good condition.

Local Lesion.—At the seat of inoculation on the left side of the neck there was a slightly raised firm tumour measuring 6 by 4 by 2 cm. showing on the surface a raised scar ; on section the tumour was composed of very thick skin and a small subcutaneous mass of brownish fibroid tissue ; there was no sign of caseation or calcification.

Left Prescapular Gland.—The left prescapular gland measured 5·5 by 2·5 by 1·5 cm. and showed no sign of tuberculosis on section.

Right Prescapular Gland.—The right prescapular gland measured 5 by 2·5 by 1 cm. and was normal on section.

Prepectoral, Cervical, and Axillary Glands.—Normal.

Thorax.

Pleura.—Normal.

Lungs.—The right anterior lobe was firm solid and airless and greyish-red in colour ; on section it was tough and fibrous, the bronchi being dilated and full of muco-pus.

The rest of the lung was normal.

Thoracic Glands.—The dorsal mediastinal and bronchial glands were normal. Two glands on the right side of the trachea were much enlarged and were composed throughout of glandular tissue somewhat denser than normal (hyperplasia)

Heart.—Normal.

Abdomen.

Omentum and Peritoneum, Spleen, Liver, Kidneys, and Suprarenal Bodies.—Normal.

Portal, Renal, Lumbar, and Iliac Glands.—Normal.

Alimentary Tract.

Tongue, Pharynx, Palate, Tonsils ; Submaxillary, Parotideal and Retro-pharyngeal Glands.—Normal.

Intestines and Mesenteric Glands.—Normal.

Testicles.—Normal.

Various Lymphatic Glands.

Procrural, Popliteal, Gluteal, Ischiatic, Pudic.—Normal.

RHESUS MONKEY 155. Virus H. 106. "K.R."

(A young animal.)

Subcutaneous inoculation of culture derived from the original material through Guinea-pig 2952.

Dose—1·0 milligramme.

Date of Inoculation—April 28, 1908.

Died—June 7, 1908. [40 days after inoculation.]

Clinical Notes.

During the experiment the monkey, though it ate its food readily enough, was never in a vigorous state of health, its low condition being brought about probably by cold.

POST-MORTEM EXAMINATION.

The carcass was in good condition.

Local Lesion.—Over the left scapula there was a prominent tumour measuring 7 by 5 by 2·5 cm. composed of pinkish yellow friable caseo-necrotic substance infiltrating skin and muscles ; near the surface at one part there was a cavity filled with yellow pus, the skin over which was ulcerated.

Axillary Glands.—On the left side there were two enlarged congested glands the substance of which was partly replaced by yellow friable caseous patches.

On the right side one gland only was enlarged but there was no sign of caseation.

Cervical Glands.—On the left side behind the middle of the clavicle there was a large (1 cm. in diameter) thin-walled caseous and softened gland, and a small one with some caseous patches in the cortex.

Other cervical glands were normal.

Vertebral Glands.—On the left side corresponding to the eighth and ninth interspaces were three caseous and softened glands the largest 1 cm. in diameter. Other vertebral glands were normal.

Inguinal Glands.—Normal.

Thorax.

Lungs.—The lungs were crepitant and contained sparsely scattered translucent grey tubercles ranging from a mere point up to 1 mm. in diameter.

Pleura, Heart, Bronchial Glands.—Normal.

Abdomen.

Omentum and Peritoneum.—Normal.

Spleen.—The spleen was not enlarged and contained a moderate number of grey tubercles ranging up to a little more than 1 mm. in diameter.

Liver.—The liver was very pale and showed under the capsule a few minute grey tubercles. None were seen on section.

Portal Gland.—There were two greyish-white foci in the cortex of the portal gland.

Lumbar and Iliac Glands.—Normal.

Kidneys.—Two small grey tubercles were seen on the surface of each kidney.

Suprarenal Bodies.—Normal.

Alimentary Tract.

Tongue, Pharynx, Tonsils.—Normal.

Submaxillary and Pharyngeal Glands.—Normal.

Intestines and Mesenteric Glands.—Normal.

VIRUS H. 107. "H.H."

LUPUS.

VIRUS H. 107. "H.H." [Lupus.]

CULTURE INOCULATIONS, AND PASSAGE EXPERIMENT I.

The strain was derived from the original material through Guinea-pig 2955, and was inoculated on May 25, 1908, when it had been in artificial cultivation a total period of 63 days.

The culture used was the 5th generation, 20 days old.

CALF 1453.

Subcutaneous.

Dose : 50·0 mg.

Killed : September 28, 1908.

126 days.

P.M. — Small fibro-caseous local lesion. Left prescapular gland almost entirely caseo-purulent. In the lungs there were four pea-sized caseo-purulent nodules and four fibro-calcareous tubercles; in the omentum one caseo-purulent nodule ; in the liver three pea-sized fibro-caseo-calcareous nodules ; in the spleen seven similar but smaller nodules.

RABBITS.

Number.	Method.	Dose.	Duration of Life.	Result.
1897	Intrav.	1·0 mg.	D. 18 days	Early G. T.
1898	Intrav.	0·1 mg.	D. 21 „	General miliary T.
1899	Intrav.	0·01 mg.	D. 142 „	G. T.
1900	Intrav.	0·01 mg.	D. 149 „	G. T.
1895	Subcut.	10·0 mg.	D. 38 „	Early slight G.T. (Death from injuries.)
1896	Subcut.	10·0 mg.	D. 49 „	Early G. T.

CULTURE.

Derived from the spleen of Calf 1453. Inoculated on December 8, 1908, after 71 days artificial cultivation. The culture used was the 6th generation, 8 days old.

CALF 1519.

Subcutaneous.

Dose : 50·0 mg.

Died : January 24, 1909.

47 days.

P.M.—General tuberculosis.

RABBITS.

Number.	Method.	Dose.	Duration of Life.	Result.
2077	Intrav.	0·1 mg.	D. 41 days	General miliary T.
2078	Intrav.	0·01 mg.	D. 115 „	Chronic G. T.
2079	Subcut.	10·0 mg.	D. 144 „	Slight G. T., insufficient to account for death.
2080	Subcut.	10·0 mg.	K. 150 „	Slight generalised T.

CULTURE.

Derived from the left bronchial gland of Calf 1519. Inoculated on April 2, 1909, after 68 days artificial cultivation. The culture used was the 4th generation, 18 days old.

CALF 1551.

Subcutaneous.

Dose : 50·0 mg.

Killed : June 11, 1909.

70 days.

P.M.—Slight retrogressive generalised tuberculosis.

RABBITS.

Number.	Method.	Dose.	Duration of Life	Result.
2252	Intrav.	1·0 mg.	D. 17 days	Early G. T.
2251	Intrav.	0·1 mg.	D. 36 „	General miliary T.
2250	Intrav.	0·01 mg.	D. 207 „	Slight T. of lungs and kidneys (? cause of death).
2253	Subcut.	42·0 mg.	D. 145 „	Chronic slight G. T. (? cause of death).

CULTURE.

Derived from the bronchial gland of Calf 1551. Inoculated on July 31, 1909, after 50 days artificial cultivation. The culture used was the 4th generation, 18 days old.

CALF 1577.

Subcutaneous.

Dose : 50·0 mg.

Killed : November 11, 1909.

103 days.

P.M.—Local tuberculosis and a few disseminated lesions.

RABBITS.

Number.	Method.	Dose.	Duration of Life.	Result.
2403	Subcut.	10·0 mg.	K. 116 days	Local T., and very slight T. of lungs.
2404	Subcut.	10·0 mg.	K. 116 „	G. T. not severe.

CULTURE.

Derived from the lung of Calf 1453. Inoculated on January 2, 1909, after 96 days artificial cultivation. The culture used was the 8th generation, 12 days old.

CALF 1505.

Subcutaneous.

Dose: 100·0 mg.

Killed: April 13, 1909.

101 days.

P.M.—Local tuberculosis; scattered ulcerated purulent nodules in the intestines; no tuberculosis elsewhere.

CALF 1513.

Subcutaneous.

Dose: 50·0 mg.

Killed: April 14, 1909.

102 days.

P.M.—Slight retrogressive generalised tuberculosis.

RABBITS.

Number.	Method.	Dose.	Duration of Life.	Result.
2100	Intrav.	1·0 mg.	D. 22 days	G. T.
2101	Intrav.	0·1 mg.	D. 25 „	General miliary T.
2102	Intrav.	0·01 mg.	D. 62 „	G. T.
2103	Subcut.	50·0 mg.	D. 153 „	G. T.
2104	Subcut.	10·0 mg.	D. 22 „	Local T. ? cause of death.

RABBITS inoculated with the culture on April 1, 1909, after 185 days artificial cultivation.

Number.	Method.	Dose.	Duration of Life.	Result.
2247	Subcut.	3·0 mg.	K. 207 days	Local lesion and slight T. of lungs and kidneys.
2246	Subcut.	1·0 mg.	K. 207 „	Local T. and slight T. of lungs.

VIRUS H. 107. "H.H."—*continued.*

CULTURE INOCULATIONS, AND PASSAGE EXPERIMENT II.

The strain was derived from the original material through Guinea-pig 2955, and was inoculated on September 9, 1908, when it had been 170 days in artificial cultivation.

The culture used was the 9th generation, 16 days old.

CALF 1497.

Subcutaneous.

Dose : 80·0 mg.

Killed : December 22, 1908.

104 days.

P.M.—There was a collapsed cyst at the seat of inoculation and the adjacent glands were caseo-calcareous. Scattered grey tubercles were seen in the heart, there were two tubercles in the lungs and one in a suprarenal ; the thoracic glands showed scattered caseo-calcareous tubercles and foci. The small intestine was studded with raised patches in some of which yellow foci were seen and showed also here and there a caseous focus ; and each mesenteric gland contained a few caseo-calcareous tubercles. One portal gland contained calcareous grains.

RABBITS.

Number.	Method.	Dose.	Duration of Life.	Result.
1995	Subcut.	10·0 mg.	D. 165 days	Chronic G. T.
1996	Subcut.	10·0 mg.	D. 18 ,,	Local lesion and early caseation of nearest glands. Death due to injuries.

CULTURE.

Derived from the mediastinal gland of Calf 1497. Inoculated on February 19, 1909, after 59 days artificial cultivation. The culture used was the 5th generation, 13 days old.

CALF 1549.

Subcutaneous.

Dose : 50·0 mg.

Killed : May 27, 1909.

97 days.

P.M.—Slight general tuberculosis, apparently progressive in the thoracic glands.

RABBITS.

Number.	Method.	Dose.	Duration of Life.	Result.
2178	Subcut.	10·0 mg.	D. 138 days	Chronic G. T., not severe.
2179	Subcut.	10·0 mg.	D. 163 ,,	Chronic G. T., not severe.

CULTURE.

Derived from the mediastinal gland of Calf 1549. Inoculated on July 6, 1909, after 40 days artificial cultivation. The culture used was the 4th generation, 8 days old.

CALF 1583.

Subcutaneous.

Dose : 50·0 mg.

Killed : November 10, 1909.

127 days.

P.M.—Local tuberculosis and a few disseminated lesions.

RABBITS.

Number.	Method.	Dose.	Duration of Life.	Result.
2387	Subcut.	10·0 mg.	D. 138 days	Local T. and very slight T. of lungs and kidneys.
2386	Subcut.	1·0 mg.	K. 138 ,,	Generalised T., moderately severe in kidneys.

VIRUS H. 107. "H.H."—*continued.*

VIRULENCE TESTS ON RHESUS MONKEYS AND GUINEA-PIGS OF CULTURES OBTAINED AT DIFFERENT STAGES OF THE CALF PASSAGE EXPERIMENT I.

Cultures from the Lung and Spleen of Calf 1453 (1st Calf).

The strain derived from the lung was inoculated on April 1, 1909, after 185 days artificial cultivation. The culture used was the 13th generation, 17 days old.

RHESUS MONKEY 285.
Subcutaneous.
Dose : 1·0 mg.
Died : May 26, 1909.
55 days.
P.M.—General tuberculosis, not severe (? cause of death).

RHESUS MONKEY 287.
Subcutaneous.
Dose : 1·0 mg.
Died : May 15, 1909.
44 days.
P.M.—General tuberculosis, not severe (? cause of death).

The strain derived from the spleen was inoculated on December 8, 1908, after 71 days artificial cultivation. The culture used was the 6th generation, 8 days old.

GUINEA-PIGS.

Number.	Method.	Dose.	Duration of Life.	Result.
3391	Subcut.	1·0 mg.	D. 74 days	G. T. severe.
3392	Subcut.	1·0 mg.	D. 82 ,,	G. T.

Culture from the Left Bronchial Gland of Calf 1519 (2nd Calf).

Inoculated on April 2, 1909, after 68 days artificial cultivation. The culture used was the 4th generation, 18 days old.

RHESUS MONKEY 293.
Subcutaneous.
Dose : 1·0 mg.
Died : July 7, 1909.
96 days.
P.M.—General tuberculosis, not severe. Death from pleurisy.

RHESUS MONKEY 295.
Subcutaneous.
Dose : 1·0 mg.
Killed (well) : Nov. 12, 1909.
224 days.
P.M.—Chronic general tuberculosis, severe in spleen slight in other organs.

GUINEA-PIGS.

Number.	Method.	Dose.	Duration of Life.	Result.
3663	Intrap.	0·1 mg.	D. 29 days	G. T.
3664	Subcut.	0·1 mg.	D. 233 ,,	G. T.

Culture from the Bronchial Gland of Calf 1551 (3rd Calf).

Inoculated on July 31, 1909, after 50 days artificial cultivation. The culture used was the 4th generation, 18 days old.

RHESUS MONKEY 353.
Subcutaneous.
Dose 1·0 mg.
Died : October 1, 1909.
62 days.
P.M.—Slight general tuberculosis (? cause of death).

RHESUS MONKEY 355.
Subcutaneous.
Dose : 1·0 mg.
Died : November 22, 1909.
114 days.
P.M.—Chronic general tuberculosis.

VIRUS H. 107. "H.H."—*continued.*

CULTURE INOCULATIONS—*continued.*

MAY 25, 1908.

The strain was derived from the original material through Guinea-pig 2955, and had been in artificial cultivation a total period of 63 days. The culture used was the 5th generation, 20 days old.

MONKEY 167.

Subcutaneous.
Dose : 1·0 mg.
Died : August 25, 1908.
92 days.
P.M.—Spontaneous alimentary infection.

CATS.

Number.	Method.	Dose.	Duration of Life.	Result.
49	Intrap.	1·0 mg.	K. 262 days	Local tuberculosis only.
51	Subcut.	1·0 mg.	D. 99 „	Local T. A few indefinite foci in the lungs. Death from injuries.

GUINEA-PIGS.

Number.	Method.	Dose.	Duration of Life.	Result.
3081	Intrap.	1·0 mg.	D. 28 days	G. T.
3083	Intrap.	0·1 mg.	D. 98 „	G. T.
3082	Subcut.	1·0 mg.	D. 116 „	G. T.
3084	Subcut.	0·1 mg.	D. 171 „	G. T. Death immediately due to pseudo-T. of the mesenteric glands.

SEPTEMBER 9, 1908.

The strain was derived from the original material through Guinea-pig 2955, and had been 170 days in artificial cultivation. The culture used was the 9th generation, 16 days old.

RHESUS MONKEY 219.

Subcutaneous.
Dose : 1·0 mg.
Died : September 29, 1908.
20 days.
P.M.—Small cavity at seat of inoculation filled with caseo-pus. No sign of tuberculosis elsewhere. The cause of death was not apparent.

RHESUS MONKEY 221.

Subcutaneous.
Dose : 1·0 mg.
Died : October 5, 1908.
26 days.
P.M.—Thin-walled cyst containing caseo-pus at seat of inoculation. Two miliary grey tubercles in spleen. The cause of death was not apparent.

VIRUS H. 107. "H.H."—*continued.*

CULTURE INOCULATIONS—*continued.*

NOVEMBER 10, 1908.

The strain was derived from the original material through Guinea-pig 2955, and had been 232 days in artificial cultivation.

The culture used was the 12th generation, 17 days old.

RHESUS MONKEY 247.

Subcutaneous.

Dose : 1·0 mg.

Died : December 29, 1908.

49 days.

P.M.—Local tuberculosis ; about a dozen grey tubercles in the lungs, two or three in the liver, and a moderate number of small softened caseous nodules and a few grey tubercles in the spleen. One thoracic and one pancreatic gland contained caseous tubercles.

RHESUS MONKEY 249.

Subcutaneous.

Dose : 1·0 mg.

Died : November 23, 1908.

13 days.

P.M. — Local lesion only. The cause of death was not apparent.

RHESUS MONKEY 251.

Subcutaneous.

Dose : 1·0 mg.

Died : December 30, 1908.

50 days.

P.M. — General tuberculosis of moderate severity.

FOWLS.

Number.	Method.	Dose.	Duration of Life.	Result.
141	Intrav.	10·0 mg.	D. 32 days	Acute T.
143	Intrav.	10·0 mg.	D. 30 „	No macroscopic tuberculosis. T.B. in organs.

DECEMBER 12, 1908.

Inoculation of an emulsion of the lungs of Fowl 141, containing moderately numerous T.B.

FOWL 149.

Intramuscular.

Large dose.

Killed after 191 days.

P.M.—No tuberculosis.

RABBITS.

Number.	Method.	Dose.	Duration of Life.	Result.
2081	Intrav.	Small	K. 146 days	Slight T. of lungs and kidneys.
2082	Intrav.	Small, but larger than 2081.	D. 144 „	G.T.

CALF 1453. Virus H. 107. "H.H."

Subcutaneous inoculation of culture derived from the original material through Guinea-pig 2955.

Dose—50·0 milligrammes.

Date of Inoculation—May 25, 1908. [Age about 5 months.]

Killed when in good health—September 28, 1908. [126 days after inoculation.]

Clinical Notes.

The calf remained in good health during the experiment, but did not grow well.

Temperature.

The temperature was irregular and slightly raised for a period of one month commencing eleven days after the inoculation (maximum, 40·2° C. ; minimum, 38·5° C.). Subsequently the temperature was quite normal.

Tuberculin Test.

August 18, 1908. [85 days after inoculation.] Dose, 2·0 cc. Slight reaction. Rise of temperature, 0·7° C.

Weights.

	cwt.	qrs.	lbs.
May 25, 1908	1	3	4
September 28, 1908	2	0	7

Total gain of weight.—1 qr. 3 lbs.

Average rate of gain per week.—1·7 lbs.

POST-MORTEM EXAMINATION.

The carcass was in good condition.

Local Lesion.—At the seat of inoculation on the ight side of the neck there was a small fibrous lesion measuring 5 by 5 by 2 cm. beset with caseo-purulent nodules with thick fibrous walls varying up to 1 cm. in diameter.

Left Prescapular Gland.—The left prescapular gland measured 8 by 5 by 4 cm. and was soft and fluctuating ; on section its substance was almost entirely replaced by yellow caseo-pus containing a few solid caseous masses ; the caseo-pus was contained in three compartments which did not communicate, each surrounded by a fibrous capsule lined internally with granulation tissue.

Right Prescapular Gland.—The right prescapular gland measured 5·3 by 2·5 by 1 cm. and was normal on section.

Prepectoral, Cervical, and Axillary Glands.—Normal.

Thorax.

Pleura.—Normal.

Lungs.—The lungs were crepitant throughout ; they contained four pea-sized nodules with fibrous walls and yellow caseo-purulent gritty contents, and four smaller nodules with fibrous walls and calcareous centres.

Bronchial and Mediastinal Glands.—The substance of the glands was a little tougher than normal, but showed no sign of tuberculosis.

Heart.—Normal.

Abdomen.

Omentum and Peritoneum.—The omentum showed two large calcareous nodules (parasitic) and one pea-sized fibrous-walled caseo-purulent nodule. The peritoneum was normal.

Spleen.—The pulp contained seven caseo-calcareous nodules with fibrous margins ranging from about 1·5 to 4· mm. in diameter.

Liver.—In the liver substance there were three pea-sized nodules with fibrous capsules and dry caseo-calcareous contents.

Portal Glands.—Normal.

Kidneys and Suprarenal Bodies.—Normal.

Renal, Lumbar and Iliac Glands.—Normal.

Alimentary Tract.

Tongue, Pharynx, Tonsils.—Normal.

Submaxillary, Retro-pharyngeal, and Parotideal Glands.—Normal.

Intestines and Mesenteric Glands.—Normal.

Various Lymphatic Glands.

Precrural, Popliteal, Gluteal, Ischiatic, Pudic.—Normal.

Microscopical Examinations.

Emulsion of a Lung Nodule.—Two tubercle bacilli seen.

Emulsion of a Liver Nodule.—No tubercle bacilli seen.

Emulsion of a Spleen Nodule.—No tubercle bacilli seen.

CALF 1497. Virus H. 107. "H.H."

Subcutaneous inoculation of culture derived from the original material through Guinea-pig 2955.

Dose—80·0 milligrammes.

Date of Inoculation—September 9, 1908. [Age about 18 weeks.]

Killed when in good health—December 22, 1908. [104 days after inoculation.]

Clinical Notes.

A tumour of moderate size developed at the seat of inoculation, which became soft and fluctuating, and then opened and discharged caseo-pus. The left prescapular gland became enlarged and nodular. The health of the calf remained good during the experiment.

Temperature.

There was a period of pyrexia commencing on the seventh day after inoculation and lasting eighteen

days; the highest temperature recorded was 41·4° C. Subsequently the temperature remained approximately normal.

Tuberculin Test.

November 4, 1908. [56 days after inoculation.] Dose, 2·0 cc. Reacted. Rise of temperature, 1·7° C.

Weights.

	cwt.	qrs.	lbs.
September 9, 1908	1	2	7
December 22, 1908	1	3	13

Total gain of weight.—1 qr. 6 lbs.

Average rate of gain per week.—2·2 lbs.

POST-MORTEM EXAMINATION.

The carcass was in good condition.

Local Lesion.—At the seat of inoculation on the left side of the neck there was a firm tumour, measuring 6 by 6 by 3 cm.; it was composed of greatly thickened skin, and a subcutaneous patch of translucent fibroid tissue containing a small collapsed cavity filled with yellow caseo-pus, and scattered yellow caseo-calcareous nodules of various sizes. The cavity communicated with the exterior through a short sinus which ended at the bottom of a funnel-shaped depression in the skin.

Left Prescapular Gland.—The left prescapular gland measured 6 by 3 by 1·5 cm.; on longitudinal section it showed three yellow caseo-calcareous sharply defined nodules 1·3 to 2·5 cm. in greatest diameter, and a few similar smaller nodules up to a hemp seed in size; about two-thirds of the gland substance were replaced.

Prepectoral Glands.—One on the left side was much enlarged, measuring 3 cm. in greatest diameter; it was composed of dense caseo-calcareous substance beginning to break down at one margin, and was surrounded by a thick fibrous capsule; the others were normal.

Right Prescapular Gland.—Normal.

Cervical and Axillary Glands.—Normal.

Thorax.

Lungs.—Under the pleura one yellow cheesy caseous tubercle, 1·5 mm. in diameter, was found; there was also one grey miliary tubercle with a slightly opaque, not gritty, centre; no other tubercles were seen, either on the surface or on section.

Thoracic Glands.—The bronchial and dorsal mediastinal glands were normal in size; they showed in the cortex scattered calcareous foci and yellow caseo-calcareous tubercles, the largest rather larger than a millet seed; they readily shelled out from the gland substance.

Heart.—Under the endocardium of the right auricle there were about ten grey semi-translucent fibrous tubercles, the largest 2·5 mm. in diameter; on the endocardium of the right ventricle there were a few raised pearly grey tubercles.

Pleura.—Normal.

Abdomen.

Omentum and Peritoneum, Spleen, Liver, and Kidneys.—Normal.

Suprarenal Bodies.—In the cortex of the right suprarenal there was an opaque submiliary yellowish tubercle; the left was normal.

Portal Glands.—One portal gland contained sparsely-scattered calcareous grains.

Coeliac, Renal, Lumbar, and Iliac Glands.—Normal

Alimentary Tract.

Tongue, Pharynx, Tonsils.—Normal.

Retro-pharyngeal, Submaxillary, and Parotideal Glands.—Normal.

Intestines.—The mucous membrane of the small intestine throughout its whole length was studded with numerous slightly-raised grey patches which could be felt between the finger and thumb and appeared to be due to thickening of the submucosa; the mucous membrane over the majority was intact; a good many, however, had a depression in the centre; in some of them there were soft yellow foci but the majority showed no sign of caseation; here and there a caseous focus was seen in the normal submucous tissue.

The large intestine was normal.

Mesenteric Glands.—In the cortex of each gland there were a few yellow caseo-calcareous or calcareous tubercles, ranging from 0·5 mm. or less to 2 mm. in diameter; a few of the larger ones were caseous and not perceptibly gritty; they readily shelled out, leaving a cavity.

Ileo-Colic Glands.—These resembled the mesenteric.

Testicles.—Normal.

Various Lymphatic Glands.

Precrural, Popliteal, Gluteal, Ischiatic, Pudic.—Normal.

Microscopical Examination.

(Smears from :—)

Emulsion of Left Prepectoral Gland.—Tubercle bacilli numerous.

Emulsion of Tubercles from Long Mediastinal Gland.—Tubercle bacilli moderately numerous.

Caseous Tubercle from Lung.—A moderate number of tubercle bacilli.

Tubercle from Right Suprarenal.—Tubercle bacilli moderately numerous; more numerous than in smears from the intestine.

Yellow Focus from Small Intestine.—A moderate number of tubercle bacilli.

Raised Patch of Mucous Membrane from Small Intestine.—Three tubercle bacilli seen.

CALF 1519. Virus H. 107. "H.H."

Subcutaneous inoculation of culture derived from the spleen of Calf 1453.

Dose—50·0 milligrammes.

Date of Inoculation—December 8, 1908. [Age about 15 weeks.]

Died—January 24, 1909. [47 days after inoculation.]

Clinical Notes.

The course of the disease was similar to that usually seen in calves suffering from acute tuberculosis, but more prolonged.

Temperature.

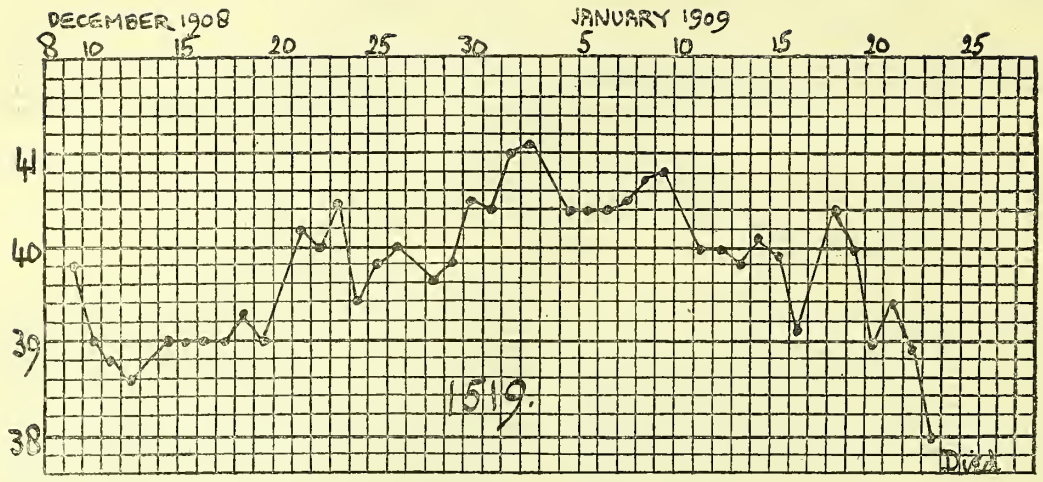

Weights.

			cwt.	qr.	lbs.
December 8, 1908	...	...	1	1	0
January 24, 1909	...	...	0	3	19

Total loss of weight.—1 qr. 9 lbs.

Average rate of loss per week.—5·5 lbs.

POST-MORTEM EXAMINATION.

The carcass was emaciated.

Local Lesion.—At the seat of inoculation on the left side of the neck there was a small firm tumour measuring 9 by 7 by 2·5 cm.; it was composed of yellow caseous substance, situated partly in the subcutaneous tissues and partly in the muscles; the latter were not uniformly infiltrated but showed irregular yellow caseous tracts; in the centre of the tumour there was a small cavity containing serous fluid.

Left Prescapular Gland.—The left prescapular gland measured 8 by 4·3 by 3·5 cm. and on section showed the cortex composed of dense caseating tissue speckled with points of congestion; the cortex was not uniformly caseous, foci and patches of translucent grey tissue still remaining.

Right Prescapular Gland.—The right prescapular gland measured 4·5 by 1·6 by 0·7 cm.; one or two minute grey points were seen in the cortex.

Prepectoral Glands.—On the left side one, 1·5 cm. in diameter, was firm and caseating throughout; another very small one was grey with a few minute foci; another contained a few minute grey foci.

On the right side one showed a few doubtful points; the others appeared normal.

Cervical Glands.—One on the left side low down was congested and showed grey points; the rest were normal in size and no definite tubercles were seen though now and then a doubtful grey point was revealed.

Thorax.

Pleura.—The fringes along the margins of the ribs were congested but there were no tubercles.

Lungs.—The lungs were heavy (weight 6 lbs. 6 ozs.) and extensively consolidated; only a small portion of each caudal lobe on the dorsal surface, extending from just behind the root of the lung to the tip of the lobe, and some isolated lobules in the anterior lobes, contained air, and this tissue was congested and showed some solid lobules; the rest of the lung was dark red very firm and quite airless.

On section the solid lobules were composed of greyish-red firm tissue closely peppered with minute greyish-white tubercles and most of the bronchi were filled with muco-pus; there were also numerous tubercles in the crepitant lobules but these were grey and almost transparent and not so obvious as those in the consolidated lobules.

Thoracic Glands.—The bronchial and dorsal mediastinal glands were much enlarged and weighed altogether 8 ozs. On section their cortices were composed of firm grey translucent tissue closely infiltrated with yellow caseous foci, in some glands forming a fine network, and some moss-like caseous patches. The medullary parts of the glands were congested and oedematous.

Heart.—The endocardium of the right auricle and right ventricle showed several small clusters of pearly grey granules.

Abdomen.

Omentum and Peritoneum.—Normal.

Spleen.—The spleen appeared a little enlarged; it was soft and flabby and the pulp contained numerous grey miliary tubercles.

Liver.—The liver was normal in size and general appearance; on close inspection numerous minute just visible grey tubercles were seen evenly distributed throughout the substance.

Portal Glands.—The portal glands were slightly enlarged; their cortices were grey and speckled with yellowish-white foci which in places had run together forming a fine network.

Kidneys.—The cortical substance of each kidney showed numerous pale grey submiliary tubercles and one or two grey miliary tubercles with slightly opaque centres.

Suprarenal Bodies.—In the cortex of each suprarenal there were fairly numerous greyish-white submiliary tubercles.

Coeliac Glands.—One was enlarged and resembled the portal glands; the others showed a few minute doubtful points.

Renal and Lumbar Glands.—One lumbar and the renal glands showed the cortices speckled with yellowish foci; the other lumbar glands contained discrete early foci.

Iliac Glands.—A moderate number of minute greyish points were seen in the cortices of the iliac glands.

Alimentary Tract.

Tongue, Pharynx.—Normal.

Tonsils.—One tonsil contained two soft yellow foci (smear, no T.B.).

The Submaxillary, Parotideal and Retro-pharyngeal Glands were congested and showed minute grey or yellowish-grey foci some with a ring of congestion around them.

Intestines.—The mucous membrane was congested in patches, and the walls were thin and atrophied. No tubercles were seen.

Mesenteric and Ileo-Colic Glands.—No tubercles were seen.

Testicles.—Normal.

Various Lymphatic Glands.

Popliteal Glands.—A few minute grey foci were seen in the cortex of each.

Precrural Glands.—No definite foci were seen in either.

Axillary, Gluteal, and Ischiatic, Pudic.—No tubercles were seen in these glands.

Microscopical Examinations

Scraping from the Spleen Pulp.—Tubercle bacilli moderately numerous.

Scraping from the Popliteal Gland.—Tubercle bacilli numerous.

Scraping from the Lung Substance.—Tubercle bacilli more numerous than in the popliteal gland.

Tubercle from Suprarenal Body.—Tubercle bacilli moderately numerous.

Emulsion of Left Bronchial Gland.—Tubercle bacilli very numerous.

Soft yellow focus from the Tonsil.—No tubercle bacilli.

CALF 1505. Virus H. 107. "H.H."

Subcutaneous inoculation of culture derived from the lung of Calf 1453.

Dose—100·0 milligrammes.

Date of Inoculation—January 2, 1909. [Age about 5 months.]

Killed when in good health—April 13, 1909. [101 days after inoculation.]

Clinical Notes.

The calf remained in good health during the experiment.

Temperature.

On the 8th day after inoculation the temperature rose to 39·9° C. and reached 40·0° C. on the 11th day: it then slowly returned to the normal, and remained normal subsequently.

Weights.

	cwt.	qrs.	lbs.
January 2, 1909	1	3	6
April 13, 1909	2	1	14

Total gain of weight.—2 qrs. 8 lbs.

Average rate of gain per week.—4·3 lbs.

POST-MORTEM EXAMINATION.

The carcass was in good condition.

Local Lesion.—The local lesion consisted of a flat patch of pinkish fibroid tissue measuring 8 by 5 by 1·5 cm. containing a small cavity filled with caseo-pus, and of greatly thickened skin.

Left Prescapular Gland.—The left prescapular gland measured 6 by 3·3 by 2·5 cm. and showed about three-quarters of its substance composed of dense pinkish-yellow slightly gritty caseous substance. The capsule of the gland was thickened and most of the rest of the gland was fibroid.

Right Prescapular Gland.—The gland measured 4·5 by 2 by 1·2 cm. and was normal on section.

Prepectoral Glands.—On the left side one contained a fibro-caseo-calcareous nodule 1 cm. in diameter; the others were normal. The glands on the right side were normal.

Intestines.—The mucous membrane of the small intestine showed scattered along its whole length raised circular nodules flattened on the upper surface with a small congested ulcer in the centre containing soft yellow pus; on section the base was thickened and grey.

There was a similar nodule in the large intestine.

Mamma.—The mammary tissue was normal.

Some saline was injected into each of the mammary sinuses and a small quantity of slightly turbid fluid recovered from each; the fluid from the two fore-quarters was mixed together and used to inoculate guinea-pigs and culture tubes; that from the two hind-quarters was similarly treated.

There was no sign of tuberculosis elsewhere in the body.

Microscopical Examination.

Smears from the pus in a nodule from the Small Intestine.—Two tubercle bacilli seen.

Fluid recovered from the mammary sinuses (two fore-quarters).—No tubercle bacilli.

Fluid recovered from the mammary sinuses (two hind quarters).—No tubercle bacilli.

Animals Inoculated.

Guinea-pigs inoculated intraperitoneally with the fluid recovered from the mammary sinuses:

Fluid from the fore-quarters.	3707, 3708	Dose about 2·0 cc. each.
Fluid from the hind-quarters.	3705, 3706	Dose 2·5 cc. each.

All the guinea-pigs were killed, two after 28 and two after 44 days, and found healthy.

CALF 1513. Virus H. 107. "H.H."

Subcutaneous inoculation of culture derived from the lung of Calf 1453.

Dose—50·0 milligrammes.

Date of Inoculation—January 2, 1909. [Age about 5 months.]

Killed when in good health—April 14, 1909. [102 days after inoculation.]

Clinical Notes.

The calf remained in good health during the experiment.

Temperature.

On the 10th day after inoculation the temperature rose to 39·8° C.; during the next four days it was

approximately normal; on the 15th day 40·8° C. was recorded. The temperature remained high until the 22nd day when 40·8° C. was again recorded; it then rapidly fell to the normal, and was normal during the remaining period of the experiment (about ten weeks).

Weights.

	cwt.	qrs.	lbs.
January 2, 1909	1	1	17
April 14, 1909	1	3	22

Total gain of weight.—2 qrs. 5 lbs.

Average rate of gain per week.—4·2 lbs.

POST-MORTEM EXAMINATION.

The carcass was in good condition.

Local Lesion.—In the superficial muscles on the left side of the neck there was an elastic somewhat flattened tumour measuring 8 by 6 by 3 cm.; on section it was composed of caseous breaking-down substance surrounded by a thin fibrous capsule.

Left Prescapular Gland.—The left prescapular gland measured 6 by 3·3 by 2·5 cm. and showed on section two caseous nodules very gritty around the margins, one 3 cm. and the other 1·5 cm. in greatest diameter. There were besides in the cortex a few caseo-calcareous nodules, the largest the size of a pea. About half the gland was occupied by tuberculous tissue. The large nodule had in its centre a cavity filled with serous fluid under tension.

Right Prescapular Gland.—The right prescapular gland measured 4·5 by 2 by 1 cm. and was normal on section.

Prepectoral Glands.—On the left side one 1·5 cm. in diameter showed more than three-quarters of its substance composed of dense caseous gritty substance; the capsule was thickened. Another contained a caseous gritty nodule the size of a barley grain; the rest were normal.

Cervical Glands.—On the left side the lower cervical gland was much enlarged, measuring 3·3 cm. in greatest diameter, and was fibro-caseo-calcareous practically throughout. Other cervical glands were normal.

Thorax.

Lungs.—No tubercles were seen on the surface or on section.

Thoracic Glands.—The bronchial and dorsal mediastinal glands were a little enlarged and from the outside appeared normal; they felt, however, harder than normal and showed on section the substance extensively replaced by calcareous patches composed of aggregated calcareous tubercles; in some of the glands the tubercles were arranged around the periphery of a white fibrous patch; in all of the glands there was a zone of normal gland tissue between the tuberculous patches and the capsule so that nothing abnormal was visible from the exterior.

Heart.—The endocardium of the right auricle showed a cluster of raised pearly-grey tubercles, the largest about 1·5 mm. in diameter. On the endocardium of the right ventricle there was a moderate number of pearly-grey tubercles, the largest 1 mm. in diameter.

Abdomen.

Spleen.—Normal.

Liver.—Under the capsule of the liver on the anterior surface one grey translucent tubercle the size of a millet seed was seen. No tubercles were seen on section.

Kidneys.—Normal.

Suprarenal Bodies.—In the cortex of the left there were two millet-seed sized calcareous tubercles with grey fibrous margins. The right was normal.

Portal Glands.—The portal glands were not enlarged; they contained, however, moderately numerous yellow calcareous tubercles the size of millet seeds.

Coeliac Glands.—These contained altogether about half-a-dozen tubercles, one the size of a millet seed, caseous and gritty, the others smaller and calcareous.

Pancreatic Glands.—These contained one or two minute calcareous grains.

Renal Glands.—Both renal glands contained scattered minute calcareous tubercles.

Alimentary Tract.

Tongue, Pharynx, Tonsils.—Normal.

Intestines.—Every Peyer's patch in the small intestine contained one or two soft yellow foci.

The large intestine was normal.

Mesenteric and Ileo-colic Glands.—The mesenteric glands contained scattered irregular yellow calcareous tubercles and foci. There were similar tubercles in the ileo-colic glands, here and there aggregated together into groups.

The Peripheral Lymphatic Glands were all normal.

All glands and organs not hitherto mentioned were examined and found normal.

Microscopical Examination.

Emulsion of a small Mediastinal Gland—Tubercle bacilli numerous.

Smear from a yellow focus in a Peyer's patch.—A few tubercle bacilli seen

---

CALF 1551. Virus H. 107. "H.H."

Subcutaneous inoculation of culture derived from the left bronchial gland of Calf 1519.

Dose—50·0 milligrammes.

Date of Inoculation—April 2, 1909. [Age 15 weeks.]

Killed when in good health—June 11, 1909. [70 days after inoculation.]

Clinical Notes.

The calf remained well during the experiment, except for some constitutional disturbance at the period of high temperature, and grew normally.

Temperature.

On the 11th day after inoculation the temperature rose to 40·2° C.; 41·1° C. was reached on the 18th day, and the same temperature was recorded on the 20th and 21st days. The temperature then slowly declined to the normal and remained normal subsequently. The pyrexia was of 30 days total duration.

Weights.

	cwt.	qrs.	lbs
April 2, 1909	1	0	17
June 11, 1909	1	3	0

Total gain of weight.—2 qrs. 11 lbs.

Average rate of gain per week.—6·7 lbs.

POST-MORTEM EXAMINATION.

The carcass was in good condition.

Local Lesion.—At the seat of inoculation on the left side of the neck there was a fluctuating swelling measuring 10 by 6 by 4·5 cm. composed of greatly

thickened skin and a caseous softening mass surrounded by a fibrous capsule.

Left Prescapular Gland.—The left prescapular gland measured 8·5 by 4·5 by 3·3 cm. and showed about two-thirds of its substance composed of a dense caseous gritty mass separated from the capsule in most directions by normal gland tissue ; at the hilum of the gland there was a mass of fibrous tissue.

Right Prescapular Gland.—The right prescapular gland measured 5·5 by 2·5 by 1·3 cm. and showed in the cortex three or four small caseous gritty tubercles.

Prepectoral Glands.—On the left side one, 1 cm. in diameter, was caseo-calcareous practically throughout ; another contained three small tubercles.

On the right side one gland contained two small tubercles.

Cervical Glands.—On the left side four contained scattered caseo-calcareous tubercles. Nearly all the glands on the right side contained two or three small tubercles.

Thorax.

Lungs.—The lungs were pink and crepitant, and appeared perfectly normal on the surface and on section.

Thoracic Glands.—The bronchial and mediastinal glands were normal in size ; they showed in the cortices a varying number, in some moderately numerous, of discrete irregular calcareous tubercles ; in one there was an aggregation of calcareo-caseous tubercles set in fibroid tissue the size of a broad bean.

Heart and Pleura.—Normal.

Abdomen.

Omentum and Peritoneum.—Normal.

Spleen.—The spleen was normal in size. On section one softened caseous nodule the size of a hemp seed was seen.

Liver.—Under the capsule on the anterior surface three minute grey tubercles were seen and one millet-seed-sized grey tubercle with a calcareous centre.

On section a few minute grey foci were seen.

Portal Glands.—The portal glands were not enlarged ; they showed in the cortices not very numerous discrete calcareo-caseous tubercles mostly minute, the size of a grain of sand ; a few were larger irregular yellow and ranging up to a millet seed in size.

Coeliac Glands.—These were not enlarged but contained a moderate number of miliary caseous gritty tubercles.

Kidneys.—In the depth of the cortex of the right there was a small grey tubercle ; the left was normal.

Suprarenal Bodies.—In the cortex of the right there were three grey tubercles, the largest 2 mm. in diameter with caseous centres.

The left was normal.

Alimentary Tract.

Tongue, Pharynx, Tonsils.—Normal.

The Pharyngeal, Parotideal, and Submaxillary Glands contained scattered caseous tubercles, some gritty.

Intestines.—Every Peyer's patch contained softened caseous foci up to 2 mm. in diameter in moderate numbers ; the mucous membrane over some of them showed a small opening through which the caseous substance could be expressed.

The large intestine was normal.

Mesenteric Glands.—Each gland showed in the cortex moderately numerous irregular yellow calcareous or calcareo-caseous tubercles mostly discrete, but here and there aggregated together into groups.

Ileo-colic Glands.—The ileo-colic glands contained similar tubercles.

Testicles.—Normal.

Various Lymphatic Glands.

Precrural Glands.—In the right there were about a dozen caseous tubercles, the largest the size of a millet seed, the majority however were minute ; calcareous grains were detected in most of the tubercles.

The left contained three or four caseous tubercles, the largest 1 mm. in diameter slightly gritty from calcification.

Popliteal Glands.—In each there were three caseous gritty tubercles.

The Pudic, Iliac, Renal, Lumbar, Gluteal, and Ischiatic Glands contained scattered caseous or caseo-calcareous tubercles.

Microscopical Examination.

Emulsion made from a Bronchial Gland.—A few tubercle bacilli.

Emulsion made from a Mediastinal Gland.—A moderate number of tubercle bacilli.

CALF 1577. Virus H. 107. "H.H."

Subcutaneous inoculation of culture derived from the bronchial gland of Calf 1551.

Dose—50·0 milligrammes.

Date of Inoculation—July 31, 1909. [Age 15 weeks.]

Killed when in good health—November 11, 1909. [103 days after inoculation.]

Clinical Notes.

The calf remained well during the experiment and grew normally.

Temperature.

The temperature was irregular and slightly raised during the first three weeks after the inoculation (maximum 39·8° C. on the 12th day). Subsequently the temperature remained normal except for a slight rise (to 39·4° C.) on the 60th day.

Tuberculin Test.

October 29, 1909. [90 days after inoculation.] Dose, 2·0 cc. Reacted. Rise of temperature, 2·4° C.

Weights.

	cwt.	qrs.	lbs.
July 31, 1909	0	3	19
November 11, 1909	1	3	10

Total gain of weight.—3 qrs. 19 lbs.

Average rate of gain per week.—7 lbs.

POST-MORTEM EXAMINATION.

The carcass was fat.

Local Lesion.—In the subcutaneous tissues on the left side of the neck there was a cyst measuring 7 by 4 by 2·5 cm. with fibrous walls and caseo-purulent contents ; the skin over it was thickened.

Left Prescapular Gland.—The left prescapular gland measured 5·7 by 3·7 by 2·5 cm. and showed about two-thirds of its substance replaced by pinkish caseous masses, some beginning to soften.

Right Prescapular Gland.—The right prescapular gland measured 4·5 by 2·4 by 1·3 cm. and was normal on section.

Prepectoral Glands.—On the left side the rounded gland was 1·3 cm. in diameter and was composed throughout of dense caseous substance; another gland contained a hempseed-sized calcareous nodule.

Those on the right side were normal.

Cervical Glands.—On the left side in the lower part of the neck a gland contained a fibrous nodule with calcareous points; the rest of the glands were normal.

Thorax.

Lungs.—Normal.

Thoracic Glands.—The bronchial and dorsal mediastinal glands contained sparsely scattered minute tubercles or foci, some calcareous, some caseous and slightly gritty.

Abdomen.

Suprarenal Bodies.—In the cortex of each there was a grey miliary tubercle with a minute calcareous centre.

Portal Glands.—A minute calcareous focus was found in one.

Mesenteric Glands.—One gland showed in the cortex a minute calcareous focus.

Ileo-Colic Glands.—In the cortex of one there was a caseous focus.

There was no sign of tuberculosis in any other organ or gland.

4·0 cc. of saline were injected into each of the four quarters of the udder of the calf, and about 3·0 cc. were recovered in each case; the recovered fluid was very slightly milky. Microscopical examination of the fluids from the quarters showed no tubercle bacilli; in that from the L.F. quarter a few alveolar cells were seen, and in that from the R.H. quarter there was a moderate number of alveolar, and a few epithelial cells.

Guinea-pigs Inoculated.

Guinea-pig 3914 (P.) 3·0 cc. of fluid from the L.H. quarter.

Guinea-pig 3915 (P.) 3·0 cc. of fluid from the R.H. quarter.

Guinea-pig 3916 (P.) 3·0 cc. of fluid from the L.F. quarter.

Guinea-pig 3917 (P.) 3·0 cc. of fluid from the R.F. quarter.

Nos. 3915 and 3917 died in 16 and 28 days; the remaining two were killed after 60 days; all were free from tuberculosis.

CALF 1549. Virus H. 107. "H.H."

Subcutaneous inoculation of culture derived from the mediastinal gland of Calf 1497.

Dose—50·0 milligrammes.

Date of Inoculation—February 19, 1909. [Age 10 weeks.]

Killed when in good health—May 27, 1909. [97 days after inoculation.]

Clinical Notes.

The calf remained well during the experiment—except for some constitutional disturbance accompanying the high temperature during the third and fourth weeks—and grew normally.

Temperature.

The temperature was normal until the 10th day after inoculation; it then gradually rose, reaching a maximum of 41·4° on the 18th day; the temperature then slowly declined to the normal and remained normal subsequently. The pyrexia was of five weeks duration.

Weights.

	cwt.	qrs.	lbs.
February 19, 1909	1	0	11
May 27, 1909	1	3	9

Total gain of weight.—2 qrs. 26 lbs.

Average rate of gain per week.—5·8 lbs.

POST-MORTEM EXAMINATION.

The carcass was in good condition.

Local Lesion.—At the seat of inoculation on the left side of the neck there was a prominent fluctuating tumour measuring 12 by 6·5 by 5 cm.; on section it was a thin fibrous-walled cyst filled with caseo-pus and breaking-down caseous masses; the wall was lined internally with granulation tissue.

Left Prescapular Gland.—The left prescapular gland measured 8 by 4 by 2·5 cm. and showed about three-quarters of its substance dense pinkish-yellow and caseous; the caseous masses were gritty around the margins; the capsule of the gland in the hilum was greatly thickened.

Right Prescapular Gland.—The right prescapular gland measured 5·7 by 2·3 by 1 cm. and showed in the cortex one caseous gritty tubercle.

Prepectoral Glands.—On the left side one contained three calcareous tubercles. The rest were normal.

Cervical Glands.—The cervical glands were not enlarged; two on the left and six on the right contained from one to six minute calcareous tubercles.

Thorax.

Pleura.—Normal.

Lungs.—Each caudal lobe showed on the external surface of the thin antero-ventral portions irregular grey patches composed of aggregated tubercles and around them numerous discrete tubercles; the tubercles on section were calcareous with fibrous margins; the patches and tubercles were included in an area about 6 cm. in greatest diameter, and were symmetrically placed in each lobe; in the thin ventral parts of the cephalic lobes there were groups of similar tubercles, in places aggregated together to form grey fibrous patches beset with calcareous foci, but mainly occurring in loose clusters.

The rest of the lung was crepitant and contained sparsely scattered grey fibrous tubercles many with calcareous centres; there were besides a few caseous gritty nodules the size of wheat grains.

Thoracic Glands.—The bronchial and dorsal mediastinal glands were much enlarged and very firm; on section they showed dense caseous tracts gritty around the margins and patches of calcareous tubercles extensively replacing the gland substance—*e.g.*, about two-thirds of the left bronchial was tuberculous and more than half of the cortex of the long mediastinal gland was dense and caseous; the capsules of the glands showed localised thickenings situated near the dense caseous patches.

Heart.—The muscle wall of the right auricle contained about thirty grey nodules varying from 2 up to 6 mm. in diameter; some of the larger ones projected from both surfaces, others either on the endocardial or pericardial surface; the majority had calcareous centres. Under the endocardium of the right ventricle

there were about two dozen similar grey nodule the largest the size of a hemp seed, the majority of these were, however, small and free from central calcification.

Pulmonary Artery.—On the internal surface of the first few inches were several small raised fibrous tubercles.

Abdomen.

Omentum and Peritoneum.—Normal.

Spleen.—The spleen showed in the pulp a moderate number of caseo-calcareous tubercles with grey margins the largest the size of a millet seed ; twelve were counted in an area of the cut surface 5 cm. square.

Liver.—The substance of the liver showed scattered calcareous tubercles the majority less than 1 mm. in diameter, a few about the size of a millet seed.

Portal Glands.—The portal glands were enlarged firm and on section showed the substance extensively replaced by fibro-calcareo-caseous nodular patches.

Coeliac Glands.—One coeliac gland was slightly enlarged and extensively calcareo-caseous ; the others contained discrete tubercles.

Pancreatic Glands.—The pancreatic glands were beset with more or less discrete calcareous tubercles.

Kidneys.—In the depth of the cortex of the left kidney there were two grey tubercles. On the surface of the right there were four grey tubercles and in the depth of the cortex one tubercle ; in the medulla there was a millet-seed sized grey tubercle with a minute opaque centre.

Suprarenal Bodies.—In the cortex of the left suprarenal body there were twelve nodules with grey margins and caseo-calcareous centres ranging up to 3 mm. in diameter ; there were nine similar nodules in the cortex of the right.

Iliac Glands.—There were about half-a-dozen small calcareous tubercles in each iliac gland.

Renal Glands.—The renal glands were slightly enlarged and closely beset with calcareous tubercles.

Lumbar Glands.—There were similar but less numerous tubercles in the lumbar glands.

Mamma.—The mamma was well-developed ; there was a small quantity of turbid fluid in the milk sinuses (saline had just previously been injected) and many of the milk ducts contained short plugs of purulent substance.

The fluid recovered from the sinuses with a pipette after injecting saline was milky and deposited on standing yellow pus composed of the plugs from the ducts.

Alimentary Tract.

Tongue, Pharynx, Tonsils.—Normal.

Submaxillary and Retro - pharyngeal Glands.—Normal.

Parotideal Glands.—The left contained one the right two tubercles.

Intestines.—The mucous membrane of the small intestine was closely studded with slightly raised congested nodules, the majority about 5 mm. in diameter ; each showed a small ulcer in the centre and a slightly thickened base, some showed yellow pus filling up the ulcer but the majority were free from any sign of caseation or calcification. All the Peyer's patches were thickened and the lymphoid tissue was beset with calcareous patches and foci ; the mucous membrane over the patches as well as over many of the small tubercles was ulcerated.

The large intestine was normal.

Mesenteric Glands.—The cortices of the mesenteric glands were closely beset with calcareous tubercles ; in many of them the tubercles had coalesced to form irregular calcareous patches.

Ileo-colic Glands.—The ileo-colic glands were similarly affected.

Various Lymphatic Glands.

Axillary Glands.—The left contained a caseo-calcareous tubercle 2 mm. in diameter ; the right was normal.

Precrural, Ischiatic, Gluteal, and Pudic Glands.—Normal.

Popliteal Glands.—One was normal, the other contained a millet-seed sized caseous tubercle.

Haemo-lymph Glands.—Several haemo-lymph glands were found to contain a small tubercle or two.

Microscopical Examinations.

Emulsion of the long mediastinal gland.—A moderate number of tubercle bacilli seen.

Fluid recovered from the hind quarters of the udder after injecting sterile saline solution.—A few tubercle bacilli seen.

Fluid recovered from the fore quarters. — A few tubercle bacilli seen.

CALF 1583. Virus H. 107. "H.H."

Subcutaneous inoculation of culture derived from the mediastinal gland of Calf 1549.

Dose—50·0 milligrammes.

Date of Inoculation—July 6, 1909. [Age about 11 weeks.]

Killed when in good health—November 10, 1909. [127 days after inoculation.]

Clinical Notes.

The calf remained well during the experiment and grew normally.

Temperature.

There was a very slight rise of temperature commencing on the 15th day after inoculation and lasting six days (maximum 39·7° C.). Subsequently the temperature remained normal.

Tuberculin Tests.

I. August 16, 1909. [41 days after inoculation.]
Dose, 2·0 cc. Reacted. Rise of temperature, 2·2° C.
II. October 29, 1909. [115 days after inoculation.]
Dose, 2·0 cc. Reacted. Rise of temperature, 1·4° C.

Weights.

	cwt.	qrs.	lbs.
July 6, 1909	1	0	1
November 10, 1909	1	3	19

Total gain of weight.—3 qrs. 18 lbs.

Average rate of gain per week.—5·6 lbs.

POST-MORTEM EXAMINATION.

The carcass was in good condition.

Local Lesion.—On the left side of the neck there was a small tumour measuring 6 by 4 by 1·5 cm. composed of thickened skin and a thin fibrous-walled cyst containing caseous masses and turbid watery fluid.

Left Prescapular Gland.—The left prescapular gland measured 4·8 by 2 by 1·5 cm. and showed on section towards one end a fibrous nodule the size of a

kidney bean containing two softened caseous collections and scattered calcareous foci ; in the rest of the gland there were about half a-dozen caseo-calcareous nodules ranging in size up to a hemp seed.

Right Prescapular Gland.—(4·7 by 1·8 by 1·2 cm.). Normal on section.

Prepectoral Glands.—Normal.

Cervical Glands.—On the left side one in the middle of the neck was slightly enlarged, indurated, and beset with calcareous foci. The rest were normal.

Thorax.

Lungs.—Normal.

Thoracic Glands.—The bronchial and dorsal mediastinal glands were not enlarged. The right bronchial contained one calcareous tubercle ; the others scattered calcareous tubercles, mainly minute, a few nearly the size of a millet seed.

Abdomen.

Suprarenal Bodies.—In the cortex of the left there was a minute calcareous focus. The right was normal.

Coeliac Glands.—One contained two minute whitish foci.

Portal Glands.—In one there were a few minute calcareous foci ; the others were normal.

Ileo-colic Glands.—In the cortex of one there was a minute calcareous focus.

There was no sign of tuberculosis in any other organ or gland. The udder was small and showed very little glandular tissue.

Guinea-pigs Inoculated.

4·0 cc. of saline were injected into each of the four quarters of the mamma, and about 3·0 cc. were recovered from each. Smear preparations were made from all the fluids but no tubercle bacilli were seen.

Guinea-pig 3910 (P.) 3·0 cc. of fluid from L.H. quarter.

Guinea-pig 3911 (P.) 3·0 cc. of fluid from R.H. quarter.

Guinea-pig 3912 (P.) 3·0 cc. of fluid from L.F. quarter.

Guinea-pig 3913 (P.) 3·0 cc. of fluid from R.F. quarter.

All were killed 56 days later ; they showed no sign of tuberculosis.

RHESUS MONKEY 167. Virus H. 107. "H.H."

(A young animal.)

Subcutaneous inoculation of culture derived from the original material through Guinea-pig 2955.

Dose—1·0 milligramme.

Date of Inoculation—May 25, 1908.

Died—August 25, 1908. [92 days after inoculation.]

Clinical Notes.

The monkey had been noticed to be ill for some weeks before death ; it gradually became very weak and emaciated ; during the last 10 days of life it was noticed to be breathing with difficulty—evidently caused by some obstruction in the throat.

The weight at death was 1750 grammes.

POST-MORTEM EXAMINATION.

Summary :—Spontaneous Tuberculosis.

The carcass was emaciated.

Local Lesion.—In the subcutaneous tissues of the back just behind the posterior angle of the left scapula there was a flat space measuring 3 cm. in greatest diameter containing a small quantity of caseo-pus, the skin over which showed several openings and was covered with dried discharge.

Axillary Glands.—On the left side one contained two caseous tubercles on the right side two contained each one minute caseous tubercle. Other axillary glands were normal.

Cervical Glands.—Normal.

Vertebral Glands.—Three vertebral glands in the 7th to the 9th interspaces on the left side were slightly enlarged and partly caseous.

Thorax.

Lungs.—The lungs were crepitant and contained sparsely scattered caseous tubercles varying in size from about 1 up to 5 mm , the larger ones composed apparently of several smaller ones aggregated together.

Bronchial Glands.—The bronchial glands were not enlarged ; the intertracheo-bronchial contained three softened caseous nodules up to 2·5 mm. in diameter. The praetracheo-bronchial glands were normal.

A gland on the right side of the trachea just within the entrance to the thorax was enlarged and caseous throughout.

Pleura and Heart.—Normal.

Abdomen.

Omentum and Peritoneum.—Normal.

Spleen.—The spleen was not enlarged : it showed in the pulp scattered caseous and softened tubercles ranging in size from a pin's head to a millet seed.

In the gastro-splenic omentum near the hilum of the spleen there was a gland 1 cm. in diameter which was caseous and softened throughout.

Liver.—The liver was normal in general appearance and showed on the surface three or four small greyish tubercles, the largest about 0·5 mm. in diameter. No tubercles were seen on section.

On the head of the pancreas near the hilum of the liver there were three small glands containing discrete caseous tubercles.

Kidneys.—Each kidney showed on the surface a moderate number of tubercles ranging from 0·5 to a little more than 1 mm. in diameter ; the larger ones were yellow and caseous, the smaller grey and translucent.

Suprarenal Bodies.—Normal.

Iliac and Lumbar Glands.—Normal.

Alimentary Tract.

Tongue.—There was a caseous ulcer at the base of the tongue.

Pharynx.—The mucous membrane of the pharynx in the neighbourhood of the tonsils was extensively ulcerated, the floors of the ulcers being caseous.

Retro-pharyngeal Glands.—The retro-pharyngeal glands were greatly enlarged, yellow and caseous, and softened throughout ; they projected into the pharynx and almost completely closed up the space between the posterior wall of the pharynx and the soft palate.

Submaxillary Glands.—The submaxillary glands on each side were slightly enlarged and partly caseous.

Stomach.—The mucous membrane showed six tuberculous ulcers with raised margins and caseous bases.

Small Intestines.—The mucous membrane of the small intestine was extensively ulcerated. Thirty ulcers in all were counted, and these were distributed along the whole length of the gut. They varied in size, some being less than 5 mm., others as much as 1·5 or 2 cm. in greatest diameter; the larger ones were very irregular, had thick caseous bases, and were studded on the peritoneal surface with caseous tubercles which in places extended on to the mesentery.

Large Intestine.—The mucous membrane of the caecum showed about a dozen congested tuberculous ulcers with raised margins and caseous bases. There were a few similar ulcers in the colon.

Gastric Glands.—Near the cardiac end of the stomach there were three caseous softened glands the largest the size of a pea; along the great curvature of the stomach there were four similar glands.

Near the pylorus there were two small glands containing discrete caseous tubercles.

Mesenteric Glands.—The mesenteric glands were all greatly enlarged, the largest being the size of a pigeon's egg. The majority were fused together and formed a large nodular mass; they were soft and fluctuating, and filled with caseo-pus.

The Ileo-Colic and most of the *Colic Glands* were large caseous and softened.

Brain.—Normal.

Inguinal Glands.—Normal.

Microscopical Examination.

Pus from Mesenteric Gland.—Tubercle bacilli very numerous.

RHESUS MONKEY 219. Virus H. 107. "H.H."

(A young animal.)

Subcutaneous inoculation of culture derived from the original material through Guinea-pig 2955.

Dose—1·0 milligramme.

Date of Inoculation—September 9, 1908.

Died—September 29, 1908. [20 days after inoculation.]

Clinical Notes.

The monkey was first noticed to be ill after a cold night a fortnight after the inoculation; he looked depressed and seedy and refused food; he became weak and lost flesh; during the last two days of life the respirations were slightly accelerated.

POST-MORTEM EXAMINATION.

The carcass was in poor condition.

Local Lesion.—In the muscles over the right shoulder there was a cavity about 1 cm. in greatest diameter filled with caseo-pus.

Axillary and Vertebral Glands.—One of the right axillary glands and one of the vertebral glands was enlarged but showed no sign of caseation.

Lungs.—The lungs were mottled with small patches of congestion; the ventral halves of the right middle and anterior lobes were red and collapsed as was also the antero-ventral portion of the right caudal lobe.

Other organs and glands appeared normal.

RHESUS MONKEY 221. Virus H. 107. "H.H."

(A young animal.)

Subcutaneous inoculation of culture derived from the original material through Guinea-pig 2955.

Dose—1·0 milligramme.

Date of Inoculation—September 9, 1908.

Died—October 5, 1908. [26 days after inoculation.]

Clinical Notes.

This monkey was noticed to be unwell on the same day as its fellow, No. 219, and the progress of the illness was similar but more prolonged; no increase in respiration however was noticed as in the case of monkey 219. The weight at death was 1520 grammes.

POST-MORTEM EXAMINATION.

The carcass was in poor condition.

Local Lesion.—Over the lower ribs on the right side there was a raised swelling measuring 5 by 3 cm.; this on section was composed of caseo-pus with a thin wall of fibrous tissue surrounding.

Axillary and Vertebral Glands.—Some of the axillary glands and two vertebral glands on the right side were enlarged and rather soft, but showed no sign of caseation.

Spleen.—The spleen was normal in size and showed in the pulp two grey miliary tubercles.

The Lungs, Liver, and Kidneys were perfectly normal to the naked eye, and there was nothing to account for the death of the animal, which was probably the result of exposure to cold.

Microscopical Examination.

A smear from the spleen pulp showed no tubercle bacilli.

A smear from a spleen tubercle showed a moderate number of tubercle bacilli.

RHESUS MONKEY 247. Virus H. 107. "H.H."

(A young animal.)

Subcutaneous inoculation of culture derived from the original material through Guinea-pig 2955.

Dose—1·0 milligramme.

Date of Inoculation—November 10, 1908.

Died—December 29, 1908. [49 days after inoculation.]

Clinical Notes.

The monkey remained well and in good condition during the experiment. The weight at death was 2320 grammes.

Nothing was found at the post-mortem examination to account for death.

POST-MORTEM EXAMINATION.

The body was in good condition, and there was plenty of subcutaneous and abdominal fat.

Local Lesion.—The skin over the right scapula showed an oval ulcer, measuring 3 by 1·7 cm. in area, with slightly inverted and considerably undermined margins and irregular granular floor, covered with a thin layer of caseo-pus. The base of the ulcer was a layer of congested fibroid tissue, 1 mm. thick, adherent to the muscles.

Axillary Glands.—In the right axilla there was a group of four enlarged glands, the largest 1·5 cm. in greatest diameter. This one showed about three-quarters of its substance replaced by caseous softened areas; another was half caseous; the third contained a few caseous nodules; the fourth was firm, but showed no sign of caseation. The left axillary glands were normal.

Cervical Glands.—Normal.

Inguinal Glands.—One of the right inguinal glands contained a hemp-seed sized softened caseous nodule.

Vertebral Glands.—On the right side two were very slightly enlarged and caseous throughout.

Thorax.

Lungs.—The lungs showed just under the pleura about a dozen tubercles, ranging from a mere point to about 1 mm. in diameter. Two or three of the larger ones had opaque centres; the rest were grey and translucent. A few minute tubercles were seen on section.

Bronchial Glands.—Normal.

On the right side of the trachea within the thorax there was a slightly enlarged gland which contained four caseous nodules, the largest 2 mm. in diameter.

Heart and Pericardium.—Normal.

Pleura.—Normal.

Abdomen

Omentum and Peritoneum.—Normal.

Spleen.—The spleen was normal in size and showed in the pulp a moderate number of softened yellow caseous nodules, ranging from 1 mm. up to a little more than 2 mm. in diameter; there were also a few submiliary translucent grey tubercles.

Splenic Lymphatic Glands.—Normal.

Liver.—The liver was pale and showed under the capsule two submiliary grey tubercles, slightly opaque in the centre. On section one miliary caseous tubercle was found.

The gland near the head of the pancreas on the portal vein showed two or three small caseous tubercles.

Kidneys and Suprarenal Bodies.—Normal

Lumbar and Iliac Glands.—Normal.

Alimentary Tract.

Tongue, Pharynx.—Normal.

Pharyngeal and Submaxillary Glands.—Normal.

Intestines.—Normal.

Mesenteric, Ileo-Colic, and Colic Glands.—Normal.

Microscopical Examination.

Tubercle from Liver.—Tubercle bacilli numerous.

RHESUS MONKEY 249. Virus H. 107. "H.H."

(A young animal.)

Subcutaneous inoculation of culture derived from the original material through Guinea-pig 2955.

Dose—1·0 milligramme.

Date of Inoculation—November 10, 1908.

Died—November 23, 1908. [13 days after inoculation.]

POST-MORTEM EXAMINATION.

In the subcutaneous tissues of the back there was a small haemorrhagic necrotic patch.

The nearest glands appeared normal.

The lungs, liver, spleen, and kidneys were perfectly normal to the naked eye.

The intestines and the various lymphatic glands of the thorax and abdomen were also normal.

Nothing was found to account for the death of the animal.

RHESUS MONKEY 251. Virus H. 107. "H.H."

(A young animal.)

Subcutaneous inoculation of culture derived from the original material through Guinea-pig 2955.

Dose—1·0 milligramme.

Date of Inoculation—November 10, 1908.

Died—December 30, 1908. [50 days after inoculation.]

Clinical Notes.

The monkey remained well and in good condition during the experiment.

The weight at death was 1500 grammes.

Nothing was found at the post-mortem examination to account for the death of the animal.

POST-MORTEM EXAMINATION.

The body was in good condition, and there was a moderate amount of subcutaneous fat.

Local Lesion.—The skin over the right scapular showed an ulcer measuring 4 by 3 cm. in area with irregular undermined margins and pinkish granular floor partly covered with a dry scab partly with caseo-pus. The base was thin fibrous and congested.

Axillary Glands.—On the right side one 1·5 cm. in greatest diameter was about three-quarters caseous and softened, another small one showed the cortex partly caseous, a third contained a millet-seed sized caseous tubercle.

On the left side one contained a pinhead-sized caseous tubercle. The rest were normal.

Cervical Glands.—On the right side one the size of a large pea was caseous and softened nearly throughout; in the fatty tissues around this there were three millet-seed sized caseous tubercles.

The glands on the left side were normal.

Inguinal Glands.—Normal.

Vertebral Glands.—One vertebral gland in the 10th interspace on each side contained a minute caseous tubercle.

Thorax.

Lungs.—The lungs were crepitant throughout, slightly congested, and contained fairly numerous tubercles ranging in size from a mere point up to that of a millet seed; the larger ones had caseous centres the rest were grey and translucent.

Thoracic Glands.—The praetracheo-bronchial glands were normal. The intertracheo-bronchial glands contained four small caseous tubercles.

Heart, Pericardium, and Pleura.—Normal.

Abdomen.

Omentum.—The omentum showed a few caseous tubercles up to a millet seed in size and numerous minute translucent grey foci.

Peritonum.—There were many minute grey tubercles and two caseous tubercles on the meso-colon.

There were two caseous tubercles on the mesentery.

The parietal peritoneum was normal.

Spleen.—The spleen was slightly enlarged (4·5 by 2·5 by 1·5 cm.) and showed in the pulp moderately numerous caseous nodules ranging from 0·5 to 2 mm. in diameter.

Splenic Lymphatic Glands.—One contained one, another three, caseous tubercles.

Liver.—The liver was pale and showed on the surface scattered opaque whitish tubercles, the largest 1 mm. in diameter. They were not evenly distributed, in one place seven were counted in an area 2 cm. square, in another the same area showed two only. Similar tubercles were seen on section.

Two slightly enlarged glands on the head of the pancreas showed in the cortex a moderate number of discrete caseous tubercles.

Kidneys.—The kidneys showed in the cortex a moderate number of translucent grey tubercles, the largest 1 mm. in diameter. A few of the larger ones had minute opaque centres. Similar tubercles were seen on section but these were not so numerous as on the surface.

Suprarenal Bodies.—Normal.

Lumbar Glands.—One lumbar gland was enlarged and beset with caseous tubercles.

Alimentary Tract.

Tongue and Pharynx.—Normal.

Submaxillary and Pharyngeal Glands.—Normal.

Intestines.—Under the mucous membrane of the ileum there was one miliary caseous tubercle.

The large intestine was normal.

Mesenteric, Ileo-Colic, and Colic Glands.—Normal.

In the areolar tissue of the right groin there was a millet-seed sized caseous tubercle.

RHESUS MONKEY 285. Virus H. 107. "H.H."

(A young animal.)

Subcutaneous inoculation of culture derived from the lung of Calf 1453.

Dose—1·0 milligramme.

Date of Inoculation—April 1, 1909.

Died—May 26, 1909. [55 days after inoculation.]

POST-MORTEM EXAMINATION.

The carcass was thin. The weight at death was 1250 grammes. The cause of death was not apparent.

Local Lesion.—The skin over the right scapula at the seat of inoculation showed an oval ulcer 4 cm. in greatest diameter the floor of which was covered with a dry caseous scab; the skin around the margins was thickened, inverted, and slightly undermined, the floor beneath it showing soft caseo-pus; the muscles were not infiltrated.

Axillary Glands.—On the right side one slightly enlarged gland contained a caseous tubercle. The rest were normal.

Cervical Glands.—The cervical glands appeared normal.

Vertebral Glands.—One on the right side was slightly enlarged but not caseous.

Thorax.

Lungs.—The lungs were crepitant and contained a

moderate number of evenly-distributed grey miliary tubercles only a few of which had opaque centres.

Thoracic Glands.—The praetracheo-bronchial glands were slightly enlarged and showed caseous tubercles in the cortices.

The intertracheo-bronchial glands were normal.

Abdomen.

Omentum.—There were two grey tubercles in the omentum.

Spleen.—The spleen was normal in size and showed scattered greyish bodies a millimetre or more in diameter, a few of which were slightly more opaque than the others.

The gland near the pylorus showed minute caseous foci.

The gland on the head of the pancreas contained two or three similar caseous foci.

Inguinal Glands.—On the left side one contained a pinhead-sized caseous tubercle.

All other organs and glands were examined and found normal.

Microscopical Examination.

Greyish Body from Spleen. — Tubercle bacilli numerous.

RHESUS MONKEY 287. Virus H. 107. "H.H."

(A young animal.)

Subcutaneous inoculation of culture derived from the lung of Calf 1453.

Dose—1·0 milligramme.

Date of Inoculation—April 1, 1909.

Died—May 15, 1909. [44 days after inoculation.]

POST-MORTEM EXAMINATION.

The carcass was thin. The weight at death was 1420 grammes. The cause of death was not apparent.

Local Lesion.—At the seat of inoculation just below the right scapula there was a large ulcer measuring 6 by 3 cm. the floor of which was covered with a thin film of greenish-yellow pus, beneath it there was a layer of infiltrated muscles about 2 mm. in thickness; under the margins of the ulcer there was a zone 8 mm. in width composed of yellow caseo-necrotic substance.

Axillary Glands.—Two axillary glands on the right side measured 1 cm. in diameter each; one was soft and caseous throughout and the other showed in the cortex a soft caseous nodule measuring nearly 3 mm. in diameter; the glands on the left side were normal.

Cervical Glands.—In the right posterior triangle there was a gland 1 cm. in diameter which was caseous and softened throughout. The glands on the left side were normal.

Vertebral Glands.—In the 7th to the 10th interspaces on the right side there were enlarged and softened caseous glands, the largest, in the 7th, measuring 8 mm. in diameter, and the smallest, in the 10th, 3 mm. in diameter.

Thorax.

Lungs.—The lungs were crepitant and showed on the surfaces a moderate number of evenly distributed translucent grey tubercles, varying in size from a mere point up to 1 mm. in diameter; a few of the larger ones had opaque centres. On section four small greyish-white tubercles were seen.

Bronchial Glands.—The bronchial glands were not enlarged and appeared normal.

Abdomen.

Omentum.—The omentum contained two millet-seed sized caseous tubercles.

On the meso-colon there were four similar tubercles.

Spleen.—The spleen was enlarged and measured 5 by 2·5 cm. On the convex surface just beneath the capsule there were four yellowish-white submiliary caseous tubercles; similar tubercles were very sparsely scattered throughout its substance.

Liver.—The under surface of the right lobe of the liver showed seven small greyish-white tubercles, the left lobe one similar tubercle; there were two similar tubercles in the substance of the liver.

Portal Glands.—The portal glands were slightly enlarged and oedematous; one showed in the cortex three small whitish caseous tubercles, another one similar tubercle.

Kidneys.—The kidneys were pale, otherwise normal.

Suprarenal Bodies.—Normal.

Lumbar Glands.—The lumbar glands contained a few minute greyish-white foci.

All other organs and glands were examined and found normal.

Microscopical Examination.

Smear from the Spleen.—Very numerous tubercle bacilli.

Smear from the Liver.—A moderate number of tubercle bacilli.

Smear from the Kidney.—No tubercle bacilli.

RHESUS MONKEY 293. Virus H. 107. "H.H."

(A young animal.)

Subcutaneous inoculation of culture derived from the left bronchial gland of Calf 1519.

Dose—1·0 milligramme.

Date of Inoculation—April 2, 1909.

Died—July 7, 1909. [96 days after inoculation.]

POST-MORTEM EXAMINATION.

The carcass was thin. Its weight was 1320 grammes.

Death resulted from pleurisy following a secondary infection of the local lesion.

Local Lesion.—Over the right lower ribs there was a foul-smelling ulcer with a necrotic floor; the tissues beneath and around it were oedematous.

Axillary Glands.—On the right side one was caseous throughout, two others were partly caseous; on the left side the glands were normal.

Cervical Glands.—On the right side one near the sternal end of the clavicle, another in the posterior triangle, each the size of a small pea, were caseous throughout.

On the left side there were three caseous tubercles in the posterior triangle, but the glands appeared normal.

Vertebral Glands.—On the right side in the middle of the back there were three caseous and softened glands, the largest 8 mm. in diameter.

Thorax.

Pleura.—The right caudal lobe of the lung was adherent to the ribs and diaphragm, the parietal pleura in these regions being covered with a layer of fibrino-purulent lymph.

Lungs.—The lungs were crepitant with the exception of a few small irregular patches of collapse; they contained scattered caseous tubercles with grey margins, the largest rather larger than a millet seed.

The Bronchial Glands were slightly enlarged and contained altogether about a dozen caseous and softened nodules, the largest 3 mm. in diameter.

Heart (muscle and valves) and Pericardium.—Normal.

Abdomen.

Omentum and Peritoneum.—The omentum contained half-a-dozen caseous nodules, the largest the size of a hemp seed; there were a few similar nodules on the mesocolon. The parietal peritoneum was normal.

Spleen.—The spleen was slightly enlarged, measuring 5 by 2·5 by 1·2 cm.; it contained numerous caseous and softened nodules, the largest the size of a pea, those under the capsule causing projections from the surface.

One splenic lymphatic gland contained a millet-seed sized caseous tubercle.

Liver.—The liver showed in the substance just under the capsule a caseous and softened nodule 3 mm. in diameter and in the depth one 2 mm. in diameter; otherwise the liver was normal.

The gland on the head of the pancreas was slightly enlarged and its cortex completely replaced by softened and caseous nodules.

Kidneys.—In the cortex of the right kidney there were two caseous tubercles, the largest 2 mm. in diameter and in the cortex of the left there were three similar tubercles.

Suprarenal Bodies.—The left contained three caseous tubercles, the largest the size of a millet seed: the right was normal.

Lumbar Glands.—Two lumbar glands up to a pea in size were caseous throughout; three others contained a discrete nodule or two.

Alimentary Tract.

Tongue, Pharynx, Tonsils.—Normal.

Submaxillary Glands.—On the right side two were enlarged and caseous throughout.

Pharyngeal Glands.—Both pharyngeal glands were enlarged and caseous.

Intestines.—There was a caseous nodule in the wall of the small intestine not ulcerated internally.

The large intestine was normal.

Mesenteric, Ileo-colic, and Colic Glands.—The mesenteric glands were normal in size and contained four caseous tubercles, the largest the size of a millet seed.

The ileo-colic glands on one side were caseous throughout, one on the other side contained a caseous tubercle 2 mm. in diameter.

Three small colic glands on the descending colon were caseous throughout.

Inguinal Glands.—The inguinal gland on the right side contained a hemp seed-sized caseous and softened nodule; in those on the left side there were four caseous and softened nodules, the largest 5 mm. in diameter.

RHESUS MONKEY 295. Virus H. 107. "H.H."

(A young animal.)

Subcutaneous inoculation of culture derived from the left bronchial gland of Calf 1519.

Dose—1·0 milligramme.

Date of Inoculation—April 2, 1909.

Killed when in good health—November 12, 1909. [224 days after inoculation.]

POST-MORTEM EXAMINATION.

The carcass was in good condition; there was plenty of subcutaneous and abdominal fat; its weight was 1570 grammes.

Local Lesion.—In the skin of the back on the right side there was a fibrous scar with a small caseous nodule in the subcutaneous tissues beneath it.

Axillary Glands.—On each side there was an enlarged caseous and softened gland.

Cervical Glands.—Normal.

Vertebral Glands.—On the right side in the 6th interspace there was a caseous and softened gland 1 cm. in diameter.

Thorax.

Lungs.—The lungs were crepitant; the right cephalic lobe contained a hemp-seed sized caseous nodule, the right caudal lobe a pea-sized caseous and softened nodule, a millet-seed sized tubercle and a grey pin-head sized tubercle; the left lobes contained about half a dozen miliary caseous tubercles.

Bronchial Glands.—The praetracheo-bronchial gland on the right side was the size of a pea and caseous throughout; one of the intertracheo-bronchial glands on the right side contained a caseous nodule 2 mm. in diameter.

Diaphragm.—In the muscle on the right side there was a caseous nodule with a thick fibrous wall measuring 1 cm. in greatest diameter.

Abdomen.

Omentum.—The omentum contained two caseous and softened nodules, the largest not so large as a hempseed.

Spleen.—The spleen was much enlarged, measuring 6·5 by 3·5 by 2 cm; on section it was packed almost as closely as possible with caseous and softened nodules the largest about 4 mm. in diameter; they were of a polygonal shape due to the closeness with which they were packed.

Liver.—The liver was normal in general appearance and showed very sparsely scattered minute greyish-white tubercles.

Portal Glands.—On the head of the pancreas there

were two glands each of which contained a small softened caseous nodule.

Kidneys.—In the cortex of one there was a millet-seed sized grey tubercle with a caseous centre; in that of the other there was a caseous and softened nodule 3 mm. in diameter.

Ileo-colic Glands.—One contained a pea-sized caseous and softened nodule.

Submaxillary Glands.—On the right side one the size of a hemp seed was caseous. The others were normal.

Muscles.—In the intercostal muscles on the left side there were two caseous and softened nodules.

Brain.—In the cortex of the left temporo-sphenoidal lobe there was a caseous nodule the size of a hemp seed.

The remaining organs and glands were examined and found normal.

Microscopical Examination.

Smear from nodule in diaphragm.—One tubercle bacillus seen.

RHESUS MONKEY 353. Virus H. 107. "H.H."

(A young animal.)

Subcutaneous inoculation of culture derived from the bronchial gland of Calf 1551.

Dose—1·0 milligramme.

Date of Inoculation—July 31, 1909.

Died—October 1, 1909. [62 days after inoculation.]

POST-MORTEM EXAMINATION.

The carcass was emaciated. Its weight was 1200 grammes.

The cause of death was not apparent.

Local Lesion.—The skin over the posterior ribs on the right side showed an ulcer about a centimetre in diameter leading into a small flat space in the subcutaneous tissues the floor of which was composed of granulation tissue and the base of a thin layer of reddish-grey tissue containing caseous foci.

Axillary Glands.—On the right side one the size of a broad bean was cystic and filled with greenish-yellow pus; on the left side one gland contained two caseous tubercles.

Cervical Glands.—The glands on the right side were normal; on the left two were enlarged and the cortices replaced by caseous and softened nodules the largest the size of a hemp seed.

Vertebral Glands.—One in the 8th interspace on the right side hemispherical and about 1 cm. in greatest diameter, was caseous and softened throughout; another in the 9th interspace a much smaller one was similarly affected.

Other vertebral glands were normal.

Thorax.

Lungs.—The lungs were pink and crepitant throughout, and showed under the pleura of the dorsal parts of the caudal lobes a moderate number of translucent grey tubercles ranging in size up to that of a millet seed; there were similar tubercles on the surface of the other parts of the lung, but much more sparsely scattered; the majority of the tubercles were homogeneous and almost glassy, but a few of the larger ones had minute opaque centres.

On section of the lung similar tubercles were very sparsely scattered throughout.

Bronchial Glands.—One intertracheo - bronchial gland contained four caseous tubercles, the rest were normal.

Abdomen.

Omentum.—The omentum contained four tubercles, two caseous in the centre.

Spleen.—The spleen was much smaller than normal measuring 3·5 cm. in length 1·6 cm. in breadth and 0·5 cm. in thickness. It contained in the pulp about two dozen caseous tubercles with grey margins the largest the size of a millet seed.

Liver.—Three minute grey tubercles were seen under the capsule, there was none on section.

The gland on the head of the pancreas contained one pinhead-sized caseous tubercle.

Kidneys.—The right kidney showed in the cortex two grey miliary tubercles, in that of the left there were two doubtful grey foci.

There was no sign of tuberculosis elsewhere in the body.

RHESUS MONKEY 355. Virus H. 107. "H.H."

(A young animal.)

Subcutaneous inoculation of culture derived from the bronchial gland of Calf 1551.

Dose—1·0 milligramme.

Date of Inoculation—July 31, 1909.

Died—November 22, 1909. [114 days after inoculation.]

POST-MORTEM EXAMINATION.

The carcass was emaciated. Its weight was 1500 grammes.

Local Lesion.—The skin over the right scapula showed a small ulcer covered with a dry scab. In the muscles beneath there were a few caseous and softened nodules.

Axillary Glands.—On the right side one the size of a sparrow's egg was caseous throughout, another the size of a pea and one the size of a hemp-seed were also caseous throughout. On the left side one contained a millet-seed sized caseous tubercle.

Cervical Glands.—Normal.

Vertebral Glands.—In the 8th to the 11th interspaces there was a mass of enlarged caseous and

softened glands to which the right caudal lobe was intimately adherent, the capsule of one of the glands tearing on removing the lung. On the left side a gland in the 11th intercostal space was enlarged and caseous.

Pleura.—The costal pleura on the right side showed along the 7th and 11th interspaces a row of caseous nodules extending from near the vertebral glands to the costal cartilages; the pleura over the latter showed several discrete caseous nodules and groups of caseous nodules. To one of the latter the right middle lobe of the lungs was intimately adherent.

The pleura on the right side of the diaphragm showed three flattened caseous and softened nodules the largest 1 cm. in diameter.

The pleura on the left side was normal.

Lungs.—On the right side the lung was adherent to the enlarged vertebral glands and the pleural nodules. The right middle lobe was more than three-quarters consolidated and was composed of caseous and softened areas surrounded by reddish-grey tissue. The other lobes were crepitant and contained three caseous nodules, one 8 mm. the others 3 mm. and 2 mm. in diameter, and scattered miliary tubercles, some grey, others caseous in the centre.

Bronchial Glands.—The praetracheo-bronchial on the right side and the intertracheo-bronchial glands were enlarged, caseous, and softened throughout. The praetracheo-bronchial glands on the left side appeared normal.

Abdomen.

Omentum.—In the omentum there were two caseous nodules, the largest the size of a hemp-seed and scattered submiliary tubercles.

Spleen.—The spleen showed a moderate degree of enlargement (it measured 6 by 3 by 1·5 cm.) and contained a moderate number of discrete caseous and softened nodules ranging from 1 to 4 mm. in diameter, the majority being about 3 mm.; some projected prominently from the surface, i.e., more than half the diameter.

Liver.—The liver was normal in colour; it contained about half a dozen caseous nodules the largest 5 mm. in diameter and scattered greyish-white tubercles.

On the head of the pancreas there were two ? slightly enlarged glands which contained a few caseous and softened nodules up to a hemp seed in size.

Kidneys.—The cortex of the right kidney contained two caseous nodules 2·5 mm. in diameter, and one grey miliary tubercle with an opaque centre; that of the left contained about a dozen nodules, one caseous and softened and 5 mm. in diameter, the rest miliary with opaque centres.

Mesenteric Glands.—One contained a pea-sized caseous and softened nodule.

Near a submaxillary salivary gland there was a millet-seed sized caseous tubercle.

The remaining organs and glands were examined and found normal.

CAT 51. Virus H. 107. "H.H."

Subcutaneous inoculation of culture derived from the original material through Guinea-pig 2955.

Dose—1·0 milligramme.

Date of Inoculation—May 25, 1908. [Weight: 1550 grammes.]

Died—September 1, 1908. [99 days after inoculation.]

POST-MORTEM EXAMINATION.

The cause of death was not apparent.

Local Lesion.—On the right side of the abdomen there was an ulcer the size of a shilling covered with a scab; on removal of the latter it was seen that the edges of the ulcer were clean cut and the floor covered with a thin layer of granulation tissue; there was no caseation or thickening of the tissues around.

Inguinal and Manubrial Glands.—A right inguinal gland contained a yellowish-white caseous nodule the size of a pea.

A manubrial gland on the same side was slightly enlarged and showed small caseous areas in the cortex.

Lungs.—The right caudal lobe was partly hepatised (red); both caudal lobes showed on the surface yellowish-grey foci with the consistency of the lung tissue and also three or four grey miliary tubercles with soft whitish centres.

Other organs and glands were normal.

Microscopical Examination.

Smear from a Lung Tubercle.—No tubercle bacilli; numerous other organisms.

CAT 49. Virus H. 107. "H.H."

Intraperitoneal inoculation of culture derived from the original material through Guinea-pig 2955.

Dose—1·0 milligramme.

Date of Inoculation—May 25, 1908. [Weight: 1100 grammes.]

Killed when in good health—February 11, 1909. [262 days after inoculation.]

POST-MORTEM EXAMINATION.

Local Lesion.—In the muscles of the abdominal wall there was a flat mass of tough yellowish caseated tissue measuring 2 by 1·5 by 0·5 cm. showing on section soft dry chalky white patches not perceptibly gritty.

Omentum.—In the omentum there was a mass of fatty tissue embedded in which were softened caseo-calcareous nodules up to a hemp seed in size mainly discrete but here and there aggregated together.

There was no sign of tuberculosis elsewhere.

VIRUS H. 107. "H.H."

ABSTRACTS OF THE POST-MORTEM NOTES OF RABBITS INOCULATED WITH CULTURES DERIVED FROM THE CALVES USED IN THE PASSAGE EXPERIMENTS WITH THE VIRUS.

1.—Subcutaneous Inoculations.

Source of Culture.	Dose in Milli-grammes.	Number of Rabbit.	Weight in Grammes.		Duration of Life.	Result.
			Initial.	Final.		
Series *a*.						
Calf 1453 (1st calf) Spleen.	10·0 mg.	2079	1,800	2,070	Died 144 days	Slight generalised tuberculosis ; the cause of death was not apparent. There was a very large thin-walled cyst filled with pus, and the nearest glands were enlarged and caseous. The lungs showed in the thin margins a few caseous patches and elsewhere a very few grey tubercles with caseous centres. Each kidney contained a caseous tubercle and one a few caseous streaks also. There was no tuberculosis elsewhere.
	10·0 mg.	2080	1,700	1,720	Killed 150 days	Slight generalised tuberculosis. The local lesion was ulcerated and nodular ; the adjacent glands appeared normal. Around the margins of the lungs there was a band of caseating tissue, and in the substance a few caseous tubercles. In each kidney a few caseous tubercles and one or two caseous wedges were seen. There was caseo-pus in both kneejoints.
Lung.	50·0 mg.	2103	3,600	2,200	Died 153 days	General tuberculosis. Very large caseous and softening local lesion ; nearest glands enlarged caseous and softened. The greater part of the lungs were solid and caseous, the rest of the lungs was crepitant and contained discrete caseating nodules. There were caseous tubercles in most of the lymphatic glands of the body. A few minute caseous foci were seen in the spleen. The surface of the kidneys showed scars and caseous miliary tubercles ; on section caseous streaks were seen ; the calyces of one kidney contained caseo-pus. One testicle was beset with caseous tubercles.
	3·0 mg.	2247	2,000	2,520	Killed 207 days	Very slight generalised tuberculosis. There was a thin-walled cyst filled with pus at the seat of inoculation and the nearest glands were normal. The lungs contained three caseous nodules and a few minute tubercles, and one or two tubercles were seen in each kidney. There was no tuberculosis elsewhere.
	1·0 mg.	2246	2,000	2,200	Killed 207 days	Local tuberculosis and tuberculosis of lungs (not severe). The local tumour was composed of thick caseous material enclosed in a thin capsule. The adjacent glands contained caseous nodules. Half of the cephalic lobes of the lungs was solid and caseating and in the margins of the caudal lobes there were several caseating nodules and patches. There was no tuberculosis elsewhere.
Calf 1519 (2nd calf) Left bronchial gland.	42·0 mg.	2253	2,050	1,100	Died 145 days	Slight generalised tuberculosis. The cause of death was not apparent. Small caseous local lesion ; calcareous grains in adjacent scapular gland. The lungs were crepitant and contained five large firm caseous masses and scattered minute tubercles. In the cortex of each kidney there were scattered wedge-shaped projecting caseating nodules, and in the papillary zone of each kidney one caseous tubercle. Each lachrymal gland contained a caseous nodule.

Calf 1551 (3rd calf) Bronchial gland.	10·0 mg.	**2403**	1,600	2,000	Killed 116 days	Local tuberculosis. There was a rather large thin-walled cyst at the seat of inoculation partly filled with caseo-pus, and the adjacent gland contained four grey tubercles with caseous centres. There was no tuberculosis elsewhere.
	10·0 mg.	**2404**	2,000	1,820	Killed 116 days	General tuberculosis, not severe. The local lesion was a thin-walled cyst containing thick caseo-pus, and the nearest gland contained caseous nodules. The lungs showed caseating patches in the thin margins, and elsewhere scattered grey tubercles (up to 2 mm.), the larger ones caseous in the centre. In the cortex of each kidney there was a moderate number of miliary tubercles with caseous centres and a few larger projecting nodules. The epididymis of one testicle was caseous; there was tuberculosis of one eye, and the adjacent lachrymal gland contained a caseous nodule.
Series β.						
Calf 1497 (1st calf) Mediastinal gland.	10·0 mg.	**2178**	2,190	1,120	Died 138 days	Chronic general tuberculosis, not severe. The local lesion was flat, caseous, and softened, and the nearest glands contained caseous patches. The lungs contained caseous patches in the thin margins, and elsewhere a few caseating nodules and scattered tubercles up to a millet seed in size, the larger caseous. The kidneys showed a moderate number of caseous tubercles and a few caseous streaks; in the pelvis of one there was mucoid material with caseous flocculi. A few caseous tubercles were seen on the mesentery, in the appendix, and in the dilated end of the ileum; several mammary glands were caseous. There were caseous tubercles in the iris of one eye, and the cornea lens and humours were opaque. In the portal glands a caseous tubercle or two were seen.
	10·0 mg.	**2179**	1,540	1,150	Died 163 days	Chronic general tuberculosis, not severe. There was an ulcerated caseous and softened local lesion, and the adjacent glands were caseating throughout. The lungs showed on the surface a few small caseous patches and caseous tubercles; on section only one or two tubercles were seen. The bronchial glands were caseous and softened. The pericardium (pleural surface) was covered with flattened caseous growths (smear, a few T.B.) and the costal pleura on the left side was similarly but less severely affected. Small translucent tubercles were seen on the omentum. The spleen showed well-marked Malpighian bodies, and there were a few miliary caseous tubercles in the kidneys. A renal gland was caseous, and a portal gland contained a caseous tubercle. One testicle was caseous throughout. One caseous tubercle was seen in the heart.
Calf 1549 (2nd calf) Mediastinal gland.	10·0 mg.	**2387**	1,600	1,250	Died 138 days	Slight generalised tuberculosis. The cause of death was not apparent. The local lesion was a large lobulated thin-walled tumour filled with caseo-pus. Two tracheal glands were thin-walled cysts containing caseo-pus; one scapular gland was enlarged. In the lungs there were two or three minute tubercles. One kidney showed three depressed scars with small grey nodules containing caseous foci, wedge-shaped on section; the other kidney showed one scar, and a fine caseous streak.
	1·0 mg.	**2386**	2,150	2,450	Killed 138 days	Slight generalised tuberculosis. The local lesion was a cyst with caseo-purulent contents; each of the adjacent glands contained a caseo-purulent nodule. The lungs showed in the thin margins a few grey nodules with caseous foci, and elsewhere sparsely scattered minute tubercles. In the cortex of each kidney there was a moderate number of caseous nodules with grey margins, up to a pea in size, many of which projected from the surface. There was no tuberculosis elsewhere.

VIRUS H. 107. "H.H."—*continued.*

ABSTRACTS OF THE POST-MORTEM NOTES OF RABBITS INOCULATED WITH CULTURES DERIVED FROM THE CALVES USED IN THE PASSAGE EXPERIMENTS WITH THE VIRUS—*continued.*

2.—Intravenous Inoculations.

Source of Culture.	Dose in Milligrammes.	Number of Rabbit.	Weight in Grammes.		Duration of Life.	Result.
			Initial.	Final.		
			Series *a*.			
Calf 1453 (1st calf) Spleen.	0·1 mg.	**2077**	2,250	1,370	Died 41 days	General miliary tuberculosis.
	0·01 mg.	**2078**	2,400	1,700	Died 115 days	Chronic general tuberculosis. The lungs were crepitant and contained in the thin margins some irregular caseating patches, and elsewhere grey tubercles, some with caseous centres. There were scattered caseous tubercles iu the .spleen, and some grey tubercles in the liver. The surfaces of the kidneys were very scarred, and each showed several grey mulberry-like nodules up to a pea in size, which were wedge-shaped and extended iuwards, some to the apex of the papilla (the papilla in one case was almost entirely caseous); many of the calyces contained caseo-pus. One testicle was enlarged and caseous, and the epididymis contained a caseous nodule. There were numerous early grey tubercles in omentum, and a few perlsucht nodules on pleura. The portal glands contained caseous tubercles.
Calf 1453. Lung.	1·0 mg.	**2100**	2,800	1,920	Died 22 days	General tuberculosis.
	0·1 mg.	**2101**	1,900	1,370	Died 25 days	General miliary tuberculosis.
	0·01 mg.	**2102**	1,700	1,200	Died 62 days	General miliary tuberculosis.
Calf 1519 (2nd calf) Left bronchial gland.	1·0 mg.	**2252**	1,650	1,250	Died 17 days	Early general tuberculosis
	0·1 mg.	**2251**	1,700	1,100	Died 36 days	General miliary tuberculosis.
	0·01 mg.	**2250**	1,750	1,350	Died 207 days	Very slight chronic general tuberculosis. The cause of death was not apparent. The lungs showed on the surface scattered flat caseous nodules, and in the depth a few caseous tubercles. There were two or three caseous tubercles or foci in each kidney.

VIRUS H. 108. "H.R."

LUPUS.

VIRUS H. 108. "H.R." [Lupus.]

CULTURE INOCULATIONS, AND PASSAGE EXPERIMENTS I. & II.

The strain was derived from the original material through Guinea-pig 2957, and was inoculated on May 19, 1908, when it had been in artificial cultivation a total period of 57 days.

The culture used was the 5th generation, 14 days old.

CALF 1417.

Subcutaneous.

Dose: 50·0 mg.

Killed: September 21, 1908.

125 days.

P.M. — In the lungs there was a small fibro-caseous nodule and a few minute glassy tubercles; in the spleen seven caseous gritty tubercles; in the liver eight tubercles with minute calcareous centres. Nearly all the lymphatic glands contained caseous gritty tubercles or nodules; the long mediastinal gland contained a caseating nodule 1 cm. in diameter.

RABBITS.

Number.	Method.	Dose.	Duration of Life.	Result.
1871	Intrav.	1·0 mg.	D. 21 days	G. T.
1872	Intrav.	0·1 mg.	D. 136 ,,	G. T. severe.
1873	Intrav.	0·01 mg.	K. (ill) 155 days.	G. T.
1874	Subcut.	10·0 mg.	K. 155 days	Slight chronic G. T.
1875	Subcut.	10·0 mg.	D. 90 ,,	G. T.

CULTURE.

The strain was derived from the lung of Calf 1417. It was inoculated on January 5, 1909, after 106 days artificial cultivation. The culture used was the 7th generation, 21 days old.

CALF 1539.

Subcutaneous.

Dose: 50·0 mg.

Died: January 21, 1909.

16½ days.

P.M.—Acute tuberculosis.

RABBITS.

Number.	Method.	Dose.	Duration of Life.	Result.
2105	Intrav.	0·1 mg.	D. 20 days	G. T.
2106	Intrav.	0·01 mg.	D. 24 ,,	G. T.
2107	Subcut.	10·0 mg.	D. 39 ,,	G. T.
2108	Subcut.	10·0 mg.	D. 31 ,,	General miliary T.

CULTURE

Derived from the bronchial gland of Calf 1539. Inoculated on April 27, 1909, after 96 days artificial cultivation. The culture used was the 9th generation, 5 days old.

RABBITS inoculated with the culture on April 22, 1909, after 213 days artificial cultivation.

Number.	Method.	Dose.	Duration of Life.	Result.
2309	Subcut.	10·0 mg.	D. 37 days	G. T.
2310	Subcut.	36·0 mg.	D. 44 ,,	G. T.

CALF 1509.

Subcutaneous.

Dose: 50·0 mg.

Killed when dying: May 26, 1909.

29 days.

P.M.—Acute general tuberculosis.

RABBITS.

Number.	Method.	Dose.	Duration of Life.	Result.
2325	Subcut.	10·0 mg.	D. 36 days	G. T.
2326	Subcut.	10·0 mg.	D. 44 ,,	G. T.

CULTURE.

The strain was derived from the mediastinal gland of Calf 1417. It was inoculated on January 19, 1909, after 120 days artificial cultivation. The culture used was the 6th generation, 13 days old.

CALF 1537.

Subcutaneous.

Dose : 50·0 mg.

Killed : April 28, 1909.

99 days.

P.M. — Slight general tuberculosis, apparently slowly progressive.

CULTURE

Derived from the mediastinal gland of Calf 1537. Inoculated on October 6, 1909, after 161 days artificial cultivation. The culture used was the 8th generation, 15 days old.

CALF 1533.

Subcutaneous.

Dose : 50·0 mg.

Killed : April 27, 1909.

98 days.

P.M.—Slight retrogressive generalised tuberculosis.

RABBITS.

Number.	Method.	Dose.	Duration of Life.	Result.
2118	Intrav.	0·1 mg.	D. 54 days	G. T.
2119	Intrav.	0·01 mg.	D. 116 ,,	G. T., not severe.
2120	Subcut.	10·0 mg.	D. 193 ,,	Chronic G.T. (slight).
2121	Subcut.	10·0 mg.	D. 122 ,,	Chronic G.T. (not severe).

RABBIT inoculated with the culture on April 22, 1909, after 213 days artificial cultivation.

2311	Subcut.	10·0 mg.	K. 206 days	G. T., not severe.

For continuation of this branch of the Passage Experiment, see page 424.

CALF 1605.

Subcutaneous.

Dose : 50·0 mg.

Died : November 29, 1909.

54 days.

P.M.—Severe general tuberculosis.

RABBITS.

Number.	Method.	Dose.	Duration of Life.	Result.
2465	Subcut.	10·0 mg.	D. 35 days	G. T.
2466	Subcut.	10·0 mg.	D. 23 ,,	Early G. T. (? cause of death).
2467	Subcut.	10·0 mg.	D. 74 ,,	G. T.

Three more Rabbits were inoculated with the culture on November 30, 1909.

Number.	Method.	Dose.	Duration of Life.	Result.
2478	Subcut.	10·0 mg.	D. 68 days	G. T.
2479	Subcut.	10·0 mg.	D. 73 ,,	G. T.
2477	Subcut.	8·0 mg.	D. 59 ,,	G. T.

VIRUS H. 108. "H.R."—*continued.*

Passage through Calf 1417 and Rabbit 2311. (*See* page 423.)

CULTURE

Derived from the kidney of Rabbit 2311. Inoculated on December 22, 1909, after 36 days artificial cultivation. The culture used was the 2nd generation, 10 days old.

RABBITS.

Number.	Method.	Dose.	Duration of Life.	Result.
2498	Subcut.	10·0 mg.	D. 63 days	G. T.
2499	Subcut.	10·0 mg.	D. 43 „	G. miliary T.
2500	Subcut.	10·0 mg.	D. 57 „	G. T.

CULTURE

Derived from the lung of Rabbit 2311. Inoculated on December 22, 1909, after 36 days artificial cultivation. The culture used was the 2nd generation, 10 days old.

RABBITS.

Number.	Method.	Dose.	Duration of Life.	Result.
2501	Subcut.	9·0 mg.	D. 61 days	G. T.
2502	Subcut.	10·0 mg.	D. 69 „	G. T. not severe.

CULTURE INOCULATIONS, AND PASSAGE EXPERIMENT III.

The strain was derived from the original material through Guinea-pig 2957, and was inoculated on September 9, 1908, when it had been in artificial cultivation a total period of 170 days.

The culture used was the 10th generation, 16 days old.

CALF 1421.

Subcutaneous.

Dose : 88·0 mg.

Killed : December 19, 1908.

101 days.

P.M.—There was a small local lesion composed of fibroid tissue and thickened skin ; the left prescapular gland was mainly occupied by a caseo-calcareous mass. The thoracic glands contained calcareous foci, discrete and in groups. In the spleen there was a moderate number of small tubercles with calcareo-caseous centres. One or two tubercles were seen in the liver, small intestine, and several abdominal glands.

RABBITS.

Number.	Method.	Dose.	Duration of Life.	Result.
1997	Subcut.	10·0 mg.	D. 159 days	Local T., and slight retrogressive T. of lungs and kidneys ; death from other causes.
1998	Subcut.	10·0 mg.	D. 85 „	Slight G. T. Death probably due to septic local lesion.

CULTURE

Derived from the spleen of Calf 1421.

The 5th generation, 11 days old, was used for inoculation on February 26, 1909. Duration of artificial cultivation, 69 days.

CALF 1553.

Subcutaneous.

Dose : 50·0 mg.

Killed : June 2, 1909.

96 days.

P.M.—Slight generalised tuberculosis, apparently retrogressive.

RABBITS.

Number.	Method.	Dose.	Duration of Life.	Result.
2180	Subcut.	10·0 mg.	D. 234 days	Chronic G.T., not severe.
2181	Subcut.	10·0 mg.	D. 208 „	Chronic G.T., not severe.

VIRUS H. 108. "H.R."—*continued.*

VIRULENCE TESTS ON MONKEYS, GUINEA-PIGS, AND FOWLS OF THE CULTURE DERIVED FROM THE ORIGINAL MATERIAL

The strain was derived from the original material through Guinea-pig 2957, and was inoculated on May 19, 1908, when it had been in artificial cultivation a total period of 57 days. The culture used was the 5th generation, 14 days old.

GUINEA-PIGS.

Number.	Method.	Dose.	Duration of Life.	Result.
3052	Intrap.	1·0 mg.	D. 34 days	G. T.
3054	Intrap.	0·1 mg.	D. 44 „	G. T.
3053	Subcut.	1·0 mg.	D. 82 „	G. T.
3055	Subcut.	0·1 mg.	D. 159 „	G. T.

RHESUS MONKEY 165.

Subcutaneous.

Dose : 1·0 mg.

Died : August 23, 1908.

96 days.

P.M. — General tuberculosis of moderate severity.

FOWLS.

Number.	Method.	Dose.	Duration of Life.	Result
107	Peri-venous.	1·0 mg.	K. 126 days	Local T. only.
109	Intra-venous.	10·0 mg.	D. 28 „	Early general miliary T.

VIRUS H. 108. "H.R."—*continued.*

VIRULENCE TESTS ON RHESUS MONKEYS AND GUINEA-PIGS OF CULTURES OBTAINED AT DIFFERENT STAGES OF THE CALF PASSAGE EXPERIMENTS I. AND II.

Cultures from the Lung and Mediastinal Gland of Calf 1417 (1st calf).

The strain derived from the lung was inoculated on April 22, 1909, after 213 days artificial cultivation. The culture used was the 11th generation, 21 days old.

RHESUS MONKEY 307.
Subcutaneous.
Dose: 1·0 mg.
Died: May 20, 1909.
28 days.
P.M. — General tuberculosis, severe.

RHESUS MONKEY 309.
Subcutaneous.
Dose: 1·0 mg.
Died: May 21, 1909.
29 days.
P.M.—General tuberculosis.

The strain derived from the mediastinal gland was inoculated on April 22, 1909, after 213 days artificial cultivation. The culture used was the 13th generation, 23 days old.

RHESUS MONKEY 311.
Subcutaneous.
Dose: 1·0 mg.
Died: September 13, 1909.
144 days.
P.M.—Chronic general tuberculosis.

Guinea-pigs were inoculated with the culture derived from the lung on January 5, 1909, after 106 days artificial cultivation.

GUINEA-PIGS.

Number.	Method.	Dose.	Duration of Life.	Result.
3421	Intrap.	0·1 mg.	D. 20 days	G. T.
3422	Subcut.	0·1 mg.	D. 44 ,,	Severe G. T.

Cultures from the Mediastinal Gland of Calf 1537 (2nd calf).

The strain derived from the mediastinal gland was inoculated on November 30, 1909, after 216 days artificial cultivation.
The culture used was the 11th generation, 11 days old.

RHESUS MONKEY 361.
Subcutaneous.
Dose: 1·0 mg.
Died: Jan. 22, 1910.
53 days.
P.M.—Severe general tuberculosis.

RHESUS MONKEY 363.
Subcutaneous.
Dose: 1·0 mg.
Died: Jan. 27, 1910.
58 days.
P.M.—Severe general tuberculosis.

GUINEA-PIGS.

Number.	Method.	Dose.	Duration of Life.	Result.
3920	Subcut.	1·0 mg.	D. 55 days	G. T
3921	Subcut.	1·0 mg.	D. 48 ,,	G. T
3922	Subcut.	1·0 mg.	D. 52 ,,	G. T
3923	Subcut.	1·0 mg.	D. 70 ,,	G. T.
3924	Subcut.	1·0 mg.	D. 61 ,,	G. T. severe.
3925	Subcut.	1·0 mg.	D. 67 ,,	G. T. severe.
3926	Subcut.	1·0 mg.	D. 43 ,,	G. T. severe.
3927	Subcut.	1·0 mg.	D. 69 ,,	G. T. severe.
3928	Subcut.	1·0 mg.	D. 50 ,,	G. T.
3929	Subcut.	1·0 mg.	D. 50 ,,	G. T.

CALF 1417. Virus H. 108. "H.R."

Subcutaneous inoculation of culture derived from the original material through Guinea-pig 2957.

Dose—50·0 milligrammes.

Date of Inoculation—May 19, 1908. [Age about 9 weeks.]

Killed when in good health—September 21, 1908. [125 days after inoculation.]

Clinical Notes.

The calf was unwell during the period of high temperature, but was in good health during the latter period of the experiment, and was in good condition when killed.

Temperature.

On the 10th day the temperature rose to 39·8° C. and reached a maximum of 40·5° C. on the 16th day. The temperature was raised during 41 days in all. During the remaining period of the experiment the temperature was quite normal.

Tuberculin Test.

August 18, 1908. [91 days after inoculation.] Dose, 2·0 cc. Reacted. Rise of temperature, 2·3° C.

Weights.

	cwt.	qrs.	lbs.
May 19, 1908	0	3	18
September 21, 1908	1	0	19

Total gain of weight.—1 qr. 1 lb.

Average rate of gain per week.—1·6 lbs.

POST-MORTEM EXAMINATION.

The carcass was in good condition.

Local Lesion.—The local lesion consisted of a small patch of thickened skin with an irregular scar in the centre, and a small subcutaneous patch of fibrous tissue.

Left Prescapular Gland.—The left prescapular gland measured 6·5 by 3·5 by 3 cm. and showed three-quarters or more of its substance composed of dense caseous material, gritty and breaking down into caseo-pus around the margins; the capsule was thickened.

Right Prescapular Gland.—The right prescapular gland measured 4·6 by 2 by 0·9 cm. and showed one caseous nodule 3 mm. in diameter and a few calcareous tubercles situated just under the capsule.

Prepectoral Glands.—One on the left side contained several caseo-calcareous tubercles, another a minute calcareous focus. On the right side one contained two caseo-calcareous tubercles.

Cervical Glands.—The cervical glands were not enlarged; they contained from one to three or four caseous gritty tubercles up to a millet seed in size; the glands on the right side had more tubercles than those on the left.

Axillary Glands.—Normal.

Thorax.

Lungs.—The lungs were crepitant throughout. Under the pleura of the left cephalic lobe there was a fibrous nodule 4 mm. in diameter with a caseous centre; about half a dozen minute glassy tubercles were also seen, these crushed easily and were not calcareous; no tubercles were seen on section.

Thoracic Glands.—The bronchial and dorsal mediastinal glands were not enlarged; they contained scattered caseo-calcareous tubercles varying in size from a mere point up to about 2 mm. in diameter. The long mediastinal gland contained rather more tubercles than the other glands; at one extremity of this gland there was a firm nodule about 1 cm. in diameter, showing on section a coarse yellow caseous meshwork.

Pleura, Heart.—Normal.

Abdomen.

Omentum and Peritoneum.—Normal.

Spleen.—The spleen contained seven caseous gritty tubercles ranging from 1 to 2·5 mm. in diameter.

Liver.—In the substance of the liver under the capsule four grey tubercles the largest 1 mm. in diameter were seen; each had a minute calcareous centre. In the depth two minute yellow tubercles and two millet-seed sized grey tubercles with minute calcareous centres were found.

Portal Glands.—The portal glands were not enlarged; their cortices contained fairly numerous irregular calcareo-caseous or calcareous nodules up to about 5 mm. in diameter, confluent in places.

Kidneys and Suprarenal Bodies.—Normal.

Renal Gland.—Six minute calcareous foci were seen in the cortex of the renal gland.

Coeliac Glands.—The coeliac glands were not enlarged, and contained each three or four yellow caseous gritty tubercles, the largest the size of a hemp seed.

Lumbar Glands.—The lumbar glands contained a moderate number of caseous tubercles, some gritty.

Alimentary Tract.

Tongue, Pharynx, Tonsils.—Normal.

Submaxillary Glands.—Each contained three or four caseous tubercles up to a millet seed in size; a few were slightly gritty.

Retro-pharyngeal Glands.—In each there were fairly numerous calcareous foci and a few softened caseous tubercles up to a millet seed in size.

Parotideal Glands.—The left contained four softened caseous tubercles, the largest the size of a hemp seed; in the right there was a softened caseous nodule and a caseo-calcareous tubercle.

Intestines.—Normal.

Mesenteric Glands.—Two at the posterior end of the mesentery were a little enlarged and showed their cortices extensively replaced by irregular yellow calcareo-caseous nodules; the other mesenteric glands contained each a moderate number of discrete calcareo-caseous nodules with fibrous capsules, the largest 5 mm. in diameter; some were quite spherical, others irregular.

Ileo-Colic Glands.—Some contained large calcareo-caseous patches; others discrete tubercles.

Various Lymphatic Glands.

Precrural.—In the cortex of each there were several calcareous or calcareo-caseous tubercles, the largest the size of a millet seed, with fibrous walls; many projected half their diameter from the surface.

Iliac, Popliteal, Pudic, and Gluteal.—These glands resembled the precrural, but one or two showed also a caseous nodule or two.

Testicles.—Normal.

Microscopical Examination.

Emulsion of Nodule from the Lung.—Two ? tubercle bacilli seen.

Emulsion of Nodule from the Long Mediastinal Glands.—A few tubercle bacilli seen.

CALF 1421. Virus H. 108. "H.R."

Subcutaneous inoculation of culture derived from the original material through Guinea-pig 2957.

Dose—88·0 milligrammes.

Date of Inoculation—September 9, 1908. [Age about six months.]

Killed when in good health—December 19, 1908. [101 days after inoculation.]

Clinical Notes.

A tumour of moderate size developed at the seat of inoculation on the left side of the neck; it became thin-walled, soft, and fluctuating, then opened and discharged caseo-purulent material and rapidly diminished in size, being finally represented by a small, hard, flat swelling, the skin over which showed a healed ulcer.

The prescapular gland adjacent to the lesion became moderately enlarged (measuring 9 cm on October 19), but afterwards diminished in size.

The health of the calf was good throughout the period of the experiment.

Temperature.

On the 8th day after inoculation the temperature rose to 39·6° C. and reached a maximum of 40·8° C. on the 14th day; it then slowly declined to the normal; the pyrexia lasted 19 days in all. The temperature remained normal subsequently.

Tuberculin Test.

November 4, 1908. [56 days after inoculation.] Dose, 2·0 cc. Reacted. Rise of temperature, 2·1° C.

Weights.

	cwt.	qrs.	lbs.
September 9, 1908	1	3	7
December 19, 1908	2	1	7

Total gain of weight.—2 qrs.

Average rate of gain per week.—3·9 lbs.

POST-MORTEM EXAMINATION.

The carcass was in good condition.

Local Lesion.—The lesion at the seat of inoculation on the left side of the neck consisted of a patch of thickened skin, 2 cm. in greatest thickness and 7 cm. in area, in the middle of which there was a pyramidal mass of pinkish translucent fibroid tissue containing calcareous grains; the apex of the pyramid was at the surface of the skin in the centre of a shallow depression.

Left Prescapular Gland.—The left prescapular gland measured 5 by 3 by 2·5 cm.; on section two-thirds of its substance were occupied by a tuberculous mass, which was caseous in the centre and calcareous around the margins; the mass was surrounded by a fibrous capsule.

Right Prescapular Gland.—The right prescapular gland measured 4·5 by 2 by 1 cm., and was normal on section.

Prepectoral Glands.—Normal.

Thorax.

Lungs.—The lungs were perfectly normal in general appearance, and no tubercles were seen either on the surface or on section.

Thoracic Glands.—The bronchial and mediastinal glands were normal in size; the bronchial and the long mediastinal glands showed in the cortex several groups of loosely aggregated yellow calcareous foci and also discrete calcareous foci; in the smaller mediastinal glands there were sparsely-scattered calcareous foci.

Heart, Pericardium; Pleura.—Normal.

Abdomen.

Omentum and Peritoneum.—Normal.

Spleen.—The spleen was normal in size; it showed in the pulp a moderate number of evenly distributed tubercles, the largest about the size of a millet seed, some with calcareous, others with calcareo-caseous centres.

Liver.—Under the capsule on the anterior surface a minute tubercle with a calcareous centre was seen; there were also sparsely scattered yellow foci, not apparently tuberculous; similar yellow foci were seen in the depth.

Portal Glands.—Two showed in the cortex a few minute calcareous foci; in one there was besides a a millet-seed sized caseo-calcareous tubercle.

Kidneys.—Normal.

Suprarenal Bodies.—Normal.

Iliac Glands.—The left iliac gland showed in the cortex two caseo-calcareous tubercles, the right contained one.

Renal and Lumbar Glands.—Normal.

Alimentary Tract.

Tongue, Pharynx, Tonsils.—Normal.

Retro-pharyngeal, Submaxillary, and Parotideal Glands.—Normal.

Intestines.—One Peyer's patch contained a caseous tubercle the size of a millet seed. The large intestine was normal.

Mesenteric Glands.—A few minute calcareous tubercles were found in the mesenteric glands.

Ileo-Colic Glands.—One contained two calcareous tubercles.

Testicles.—Normal.

Various Lymphatic Glands.

Axillary, Precrural, Popliteal, Gluteal, Ischiatic, Pudic.—Normal.

Microscopical Examination.

Emulsion of Tubercles from Spleen.—No tubercle bacilli seen.

Smear from caseous Tubercle in a Peyer's patch.—No tubercle bacilli seen.

CALF 1539. Virus H. 108. "H.R."

Subcutaneous inoculation of culture derived from the lung of Calf 1417.

Dose—50·0 milligrammes.

Date of Inoculation—January 5, 1909. [Age about 10 weeks.]

Died—January 21, 1909. [16½ days after inoculation.]

Clinical Notes.

On the 10th day after inoculation the calf was unwell and from the twelfth day onwards refused food. The respiration was noticed to be accelerated on the twelfth day; it gradually became more difficult and laboured, and the calf died on the evening of the sixteenth day after inoculation.

Temperature.

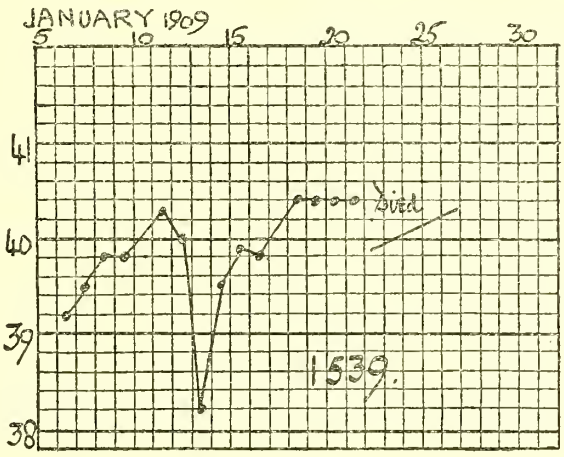

Weights.

	qrs.	lbs.
January 5, 1909	3	26
January 21, 1909	3	8

Total loss of weight.—18 lbs.

Average rate of loss per week.—7·6 lbs.

POST-MORTEM EXAMINATION.

The carcass was emaciated.

Local Lesion.—At the seat of inoculation on the left side of the neck there was a flat firm tumour measuring 10 by 6 by 2 cm.; it was composed of reddish fibroid tissue containing irregular yellow caseo-necrotic tracts, one of which had broken down, forming a cavity filled with serous fluid.

Left Prescapular Gland.—The left prescapular gland measured 7·5 by 4·5 by 3 cm.; the cortex was composed practically throughout of firm translucent grey tissue closely infiltrated with a yellow caseous network.

Right Prescapular Gland.—The right prescapular gland measured 3·7 by 1·7 by 0·8 cm. and showed in the cortex scattered minute grey foci.

Prepectoral Glands.—On the left side one the size of a pea was firm and reddish grey; another was beset with small tubercles; two others, very small ones, contained one or two minute foci.

The glands on the right side showed one or two minute tubercles.

Cervical Glands.—On the left side one in the lower part of the neck was slightly enlarged and showed two-thirds of its substance composed of firm reddish-grey tissue, speckled with greyish-white points. Two others (one on the right side) showed early foci. The rest were normal.

Thorax.

Lungs.—The lungs were deeply congested and extensively consolidated, the posterior parts of the caudal lobes only containing air; the lung parenchyma was peppered as closely as possible with minute grey tubercles, the condition resembling that following an intravenous inoculation.

Thoracic Glands.—The dorsal mediastinal and bronchial glands showed a moderate degree of enlargement; on section they were friable, deeply congested, and of a reddish-grey colour; no definite tubercles were seen.

Heart.—The endocardium of the right auricle and ventricle showed numerous raised pearly-grey granules; the heart muscle was normal.

Pleura.—Normal.

Abdomen.

Omentum.—The omentum showed on its ventral surface a moderate number of grey miliary tubercles, many congested around the margins.

Parietal Peritoneum.—Normal.

Spleen.—The spleen was flabby and slightly enlarged; the pulp was soft and dark red; no tubercles were seen nor were there any Malpighian bodies visible.

Liver.—The liver was paler than normal, with a yellowish tint; the substance was closely peppered with minute grey tubercles.

Portal Glands.—The portal glands were a little enlarged; they were very oedematous and their cortices appeared greyer than normal; there were no definite tubercles.

Kidneys.—On the surface of the right kidney four minute greyish opaque tubercles were seen; on section there were similar tubercles scattered about in the depth of the cortex, some very minute and barely visible.

On the surface of the left kidney only one tubercle was seen; in the depth of the cortex a good many were detected, the majority just visible to the naked eye.

Suprarenal Bodies.—No tubercles were seen.

Coeliac, Lumbar, Renal, and Iliac Glands.—All showed in the cortex a few minute greyish foci, many with congested margins.

Alimentary Tract.

Tongue, Pharynx, Tonsils.—Normal.

Intestines.—The mucous membrane of the small intestine was deeply congested; no tubercles were seen.

The mucous membrane of the caecum was congested, he colon was normal.

Mesenteric and Ileo-Colic Glands.—No tubercles were seen in these glands.

Various Lymphatic Glands.

The Precrural, Popliteal, Gluteal, Ischiatic, Pudic, Axillary, Submaxillary, Retro-pharyngeal, and Parotideal Glands all showed in the cortex a few minute greyish foci, many with congested margins. Some of the foci were very minute and were barely visible to the naked eye.

Microscopical Examinations.

Scraping from the Spleen.—A moderate number of tubercle bacilli.

Scraping from the Portal Gland.—A moderate number of tubercle bacilli.

Scraping from the Renal Gland.—A moderate number of tubercle bacilli.

Scraping from the Mucous Surface of the Small Intestine.—No tubercle bacilli.

Emulsion of the Left Bronchial Gland.—Tubercle bacilli moderately numerous.

CALF 1509. Virus H. 108. "H.R."

Subcutaneous inoculation of culture derived from the bronchial gland of Calf 1539.

Dose—50·0 milligrammes.

Date of Inoculation—April 27, 1909. [Age 7 months.]

Killed when dying—May 26, 1909. [29 days after inoculation.]

Clinical Notes.

The course of the disease was similar to that usually seen in cases of acute tuberculosis, being marked by weakness, emaciation and rapid respiration; the calf was in a dying condition when killed on the 29th day.

Temperature.

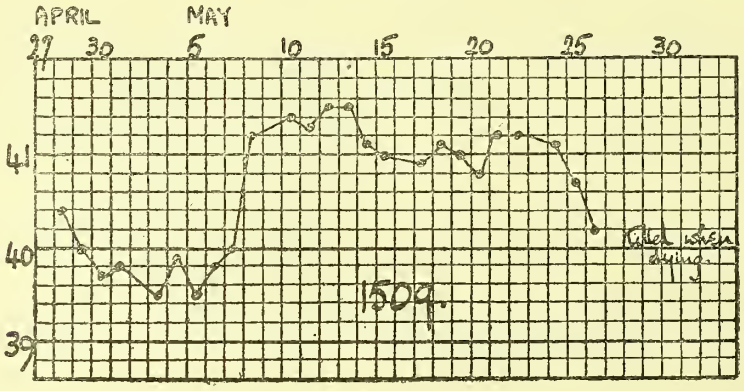

Weights.

			cwt.	qrs.	lbs.
April 27, 1909	...	...	2	2	24
May 26, 1909	...	...	2	1	14

Total loss of weight.—1 qr. 10 lbs.

Average rate of loss per week.—9 lbs.

POST-MORTEM EXAMINATION.

The carcass was very thin.

Local Lesion.—At the seat of inoculation on the left side of the neck there was a firm caseo-necrotic tumour measuring 11 by 8 by 4·5 cm.; half the tumour was formed by infiltrated muscles, the rest was situated in the subcutaneous tissues; the skin was infiltrated in its deeper layers.

Left Prescapular Gland.—The left prescapular gland measured 11 by 7 by 4·5 cm.; its cortex was composed partly of dense homogeneous yellow caseous substance and partly of greyish-red tissue closely beset with caseous tubercles.

Right Prescapular Gland.—The right prescapular gland measured 4·2 by 2 by 0·8 cm. and showed a moderate numoer of caseous tubercles.

Prepectoral Glands.—On the left side one 3·5 cm. in greatest diameter was dense yellow and caseous throughout; another slightly smaller was not so advanced in caseation, a third showed grey patches in the cortex.

On the right side the prepectoral glands contained a few small tubercles.

Cervical Glands.—The left lower cervical gland was enlarged and showed on section firm reddish tissue containing caseous points; two smaller ones showed small grey patches; the upper glands on each side contained a few tubercles and the lower one on the right side showed numerous caseous tubercles in the cortex; one or two others contained each a small tubercle.

Thorax.

Pleura.—Normal.

Lungs.—The lungs filled the chest and did not collapse; they weighed 16 lbs.; the cephalic, middle, and more than half of the caudal lobes were reddish in colour firm and quite airless, and showed under the pleura very numerous minute greyish-white tubercles and a few larger caseous tubercles; on section these lobes were composed of reddish tissue very closely beset with minute whitish or greyish-white tubercles; in some places the tubercles were so numerous as to replace almost completely the reddish tissue.

The dorsal portions of the caudal lobes showed extensive interstitial emphysema ; the lung tissue was congested and crepitant except for an occasional lobule and contained numerous (though not apparently so numerous as in the solid portions) tubercles varying up to a millet seed in size, the larger ones being distinctly yellow and caseous.

The bronchi in the solid portions were filled with muco-pus.

Thoracic Glands.—The bronchial and dorsal mediastinal glands were much enlarged and weighed together 1 lb. 2 oz. On section their cortices were firm and of a pale greyish colour, caused apparently by closely aggregated tubercles, and showed discrete caseous foci and several irregular caseous patches where the caseous foci had run together.

Heart.—On the endocardium of the right auricle there was one grey tubercle ; on that of the right ventricle there were about a dozen caseous tubercles.

The heart muscle and valves were normal.

Abdomen.

Omentum.—On the ventral surface of the omentum there were a few reddish tubercles.

Peritoneum.—Normal.

Spleen.—The spleen was enlarged and showed on section moderately numerous evenly distributed caseous tubercles with grey margins ranging from 1 to 2 mm. in diameter.

Liver.—The liver was normal in general appearance ; it showed in the substance a moderate number of evenly distributed minute yellow tubercles.

Portal Glands.—The portal glands were enlarged and oedematous ; the cortices were closely beset with grey tubercles with caseous centres ; these were aggregated together, forming grey patches beset with irregular caseous foci.

Coeliac Glands.—These were slightly enlarged and showed numerous grey tubercles in the cortices, some with caseous centres.

Kidneys.—On the surface of each kidney there were sparsely scattered tubercles ranging up to 1 mm. in diameter ; they were grey and translucent or greyish-white and opaque. Similar tubercles were scattered about in the depth of the cortex.

Suprarenal Bodies.—In the cortex of the right there were about half-a-dozen minute greyish-white tubercles ; in that of the left a few similar tubercles and one pin-head-sized caseous tubercle.

The Renal and Lumbar Glands were closely beset with miliary caseating tubercles.

Alimentary Tract.

Tongue, Tonsils, Larynx.—Normal.

Pharynx.—There were a few caseous tubercles in the corrugated mucous membrane of the roof of the pharynx.

Intestines.—Four Peyer's patches were affected ; two showed each one small ulcer with a caseous floor ; the other two contained three caseous tubercles.

The large intestine was normal.

Mesenteric Glands.—The mesenteric glands contained scattered grey miliary tubercles some showing early caseation.

Ileo-colic Glands.—The ileo-colic glands resembled the mesenteric.

Mamma.—Normal.

Various Lymphatic Glands.

The Precrural, Popliteal, Gluteal, Ischiatic, Axillary, Retro-pharyngeal, Submaxillary, Parotideal, Pudic, and Iliac Glands showed in their cortices moderately numerous caseating tubercles varying in size up to that of a millet seed.

CALF 1533. Virus H. 108. "H.R."

Subcutaneous inoculation of culture derived from the mediastinal gland of Calf 1417.

Dose—50·0 milligrammes.

Date of Inoculation—January 19, 1909. [Age about 16 weeks.]

Killed when in good health—April 27, 1909. [98 days after inoculation.]

Clinical Notes.

The calf remained well during the experiment.

Temperature.

Slight and irregular pyrexia commenced on the 13th day after inoculation and lasted 36 days ; the maximum temperature recorded during this period was 40·0° C., the minimum 38·5° C. Subsequently the temperature was normal.

Weights.

	cwt.	qrs.	lbs.
January 19, 1909	1	0	10
April 27, 1909	1	2	19

Total gain of weight.—2 qrs. 9 lbs.

Average rate of gain per week.—4·6 lbs.

POST-MORTEM EXAMINATION.

The carcass was in good condition.

Local Lesion.—At the seat of inoculation on the left side of the neck there was an elongated fluctuating tumour measuring 17·5 by 8·5 by 6·5 cm. On section it was a thin-walled cyst filled with light-brownish caseo-pus containing some firm caseous masses ; the wall was lined internally with granulation tissue, and the cavity was crossed by a few fibrous cords.

Left Prescapular Gland.—The left prescapular gland measured 8·8 by 4·5 by 3·8 cm., and was composed practically throughout of dense caseous substance gritty chiefly around the margins.

Right Prescapular Gland.—The right prescapular gland measured 4·7 by 2 by 1·1 cm., and showed in the cortex seven caseous gritty tubercles, the largest nearly 2 mm. in diameter.

Prepectoral Glands.—On the left side one, a flattened gland, measured 3 cm. in greatest diameter and was closely beset with calcareous tubercles ; another contained one or two. One on the right side contained several miliary tubercles ; another small one contained a single tubercle.

Cervical Glands.—On the left side one in the lower part of the neck was enlarged and two-thirds caseo-calcareous. Two others contained discrete tubercles. On the right side three contained each one tubercle, a fourth contained two caseo-calcareous tubercles.

Thorax.

Lungs.—The lungs were normal in general appearance, after careful search seven nodules were seen on the surface of the left, just under the pleura, and eight on that of the right ; they varied in size from a millet- to a hemp-seed or rather larger ; the two largest ones were situated in the thin margin of the left caudal lobe. The nodules were grey and had calcareous or caseo-calcareous centres. Only one tubercle was found in the depth of the lung.

Thoracic Glands.—The bronchial and dorsal mediastinal glands were slightly enlarged and contained a moderate number of discrete yellow caseo-calcareous tubercles ranging up to 2 mm. in diameter.

Heart and Pleura.—Normal.

Abdomen.

Omentum and Peritoneum.—Normal.

Spleen.—The spleen was slightly enlarged; the pulp contained a moderate number of evenly-distributed caseous gritty tubercles with fibrous margins, ranging from 1·5 to 3 mm. in diameter; from 30 to 36 were counted in an area of the cut surface 5 cm. square.

Liver.—On the surface, just under the capsule, as well as in the depth of the liver substance, there were scattered caseous gritty nodules with fibrous margins ranging from 1 to 3 mm. in diameter; they were less numerous than in the spleen, ten only being counted in an area on the surface 5 cm. square.

Portal Glands.—The portal glands were slightly enlarged and showed their cortices closely beset with calcareo-caseous tubercles in many places aggregated together.

Coeliac Glands.—The coeliac glands resembled the portal.

Pancreatic Glands.—There were similar tubercles in the pancreatic glands, but not so numerous.

Kidneys.—On the surface of the right one pinhead-sized caseo-calcareous tubercle was seen; in the depth of the cortex there was a similar slightly larger tubercle. In the cortex of the left there was one minute grey focus.

Suprarenal Bodies. — The right contained two caseous gritty nodules with grey margins 4 mm. in diameter. In the cortex of the left there was one pinhead-sized caseous tubercle.

Renal Glands.—In one renal gland there was a moderate number of caseo-calcareous tubercles, the largest the size of a millet seed.

Lumbar Glands.—The lumbar glands contained similar and moderately numerous tubercles, all however remaining discrete.

Alimentary Tract.

Tongue, Pharynx, Palate, Tonsils.—Normal.

Retro-pharyngeal Glands.—Each showed scattered caseo-calcareous tubercles.

Submaxillary and Parotideal Glands.—These glands contained discrete caseous softened gritty nodules up to 4 mm. in diameter.

Intestines.—Nearly every Peyer's patch in the small intestine contained a few caseo-calcareous tubercles; the mucous membrane over them was intact.

The large intestine was normal.

Mesenteric Glands.—All the mesenteric glands contained dense caseo-calcareous nodules the majority large; the glands in the posterior part of the mesentery were most affected and in them the nodules were larger than in the others, one gland was more than three-quarters tuberculous and several others had more than half their substance caseo-calcareous; these glands were slightly enlarged.

Ileo-Colic Glands.—The ileo-colic resembled the terminal mesenteric glands.

Mammary Gland.—Normal.

Some saline was injected into each of the mammary sinuses and a small quantity of slightly turbid fluid recovered from each.

Various Lymphatic Glands.

Precrural Glands.—In the cortex of each there was a moderate number of discrete yellow caseous gritty tubercles, the largest nearly 2 mm. in diameter.

The Pudic, Popliteal, Axillary, and Iliac Glands contained similar tubercles, but not so numerous as in the precrural glands.

The Ischiatic and Gluteal Glands each contained a few tubercles.

The Ventral Mediastinal Glands contained tubercles.

Haemo-lymph Glands.—In every haemo-lymph gland examined one caseo-calcareous tubercle was found.

Microscopical Examinations.

Emulsion of small Mediastinal Gland.—Tubercle bacilli scanty.

Emulsion of a Tubercle from the Lung.—No tubercle bacilli.

Saline withdrawn from the forequarters of the Mamma.—No tubercle bacilli.

Saline withdrawn from the hindquarters of the Mamma.—No tubercle bacilli.

Animals Inoculated.

Guinea-pigs were inoculated intraperitoneally with the fluids recovered from the mammary sinuses; one, No. 3736, with a small quantity of mixed fluids from the fore-quarters, and one, No. 3737, with that from the hind-quarters. They were killed after 72 days; No. 3736 showed slight general tuberculosis; No. 3737 was free from tuberculosis.

CALF 1537. Virus H. 108. "H.R."

Subcutaneous inoculation of culture derived from the mediastinal gland of Calf 1417.

Dose—50·0 milligrammes.

Date of Inoculation—January 19, 1909. [Age about 15 weeks.]

Killed when in good health—April 28, 1909. [99 days after inoculation.]

Clinical Notes.

The calf remained well during the experiment.

Temperature.

On the 11th day after inoculation the temperature rose to 40·0° C. and reached a maximum of 40·7° C. on the 16th day. The temperature then slowly declined to the normal (the period of pyrexia lasting 44 days in all), and remained normal subsequently.

Weights.

	cwt.	qrs.	lbs.
January 19, 1909	0	3	26
April 28, 1909	1	2	12

Total gain of weight.—2 qrs. 14 lbs.

Average rate of gain per week.—5 lbs.

POST-MORTEM EXAMINATION.

The carcass was in good condition.

Local Lesion.—In the superficial muscular tissues on the left side of the neck there was a cyst measuring 8·5 by 6·5 by 3·5 cm. with very thick fibrous walls and caseous contents partly solid and partly softened.

Left Prescapular Gland.—The left prescapular gland measured 6 by 3·5 by 3 cm., and, save for a small portion at one extremity, was dense and caseous throughout, the caseous mass being gritty only around the margins; the capsule was much thickened.

Right Prescapular Gland.—The right prescapular gland measured 4·8 by 2 by 1 cm. and showed in the cortex one caseous and softened nodule the size of a hemp seed, slightly gritty.

Prepectoral Glands.—On the left side one the size of a hemp-seed was partly caseo-calcareous, another

contained a caseo-calcareous nodule 1 cm. in diameter; in a third there was a minute gritty focus. The glands on the right side were normal.

Cervical Glands.—On the left side the lower cervical gland was enlarged measuring 2·4 cm. in diameter, and was composed practically throughout of dense caseous gritty substance; another anterior to it contained a pea-sized caseo-calcareous nodule; a small gland in the middle of the neck contained a minute calcareous focus.

In the cervical gland near the angle of the jaw on the left side there was one calcareous tubercle; the corresponding gland on the opposite side contained several tubercles, the largest the size of a millet seed. Other cervical glands were normal.

Thorax.

Lungs.—The lungs were crepitant throughout; they showed on the surface under the pleura moderately numerous minute grey tubercles, the largest 1 mm. in diameter, the majority of which had calcareous centres; there were besides eight caseo-calcareous nodules with fibrous margins, the largest about 4 mm. in diameter. On section, tubercles similar to those seen on the surface were distributed evenly throughout the parenchyma; in the depth of the right caudal lobe two large nodules were felt; one was about 1 cm., the other rather more than 2 cm. in diameter; the smaller one was composed of reddish fibroid tissue containing calcareo-caseous foci; the other was caseo-calcareous and had a fibrous margin, it was adherent to the wall of a bronchus which showed internally an irregular deep ulcer, the floor of which was composed of the caseous substance of the nodule. In the depth of this lobe there were also three caseous gritty nodules, the largest the size of a pea.

Thoracic Glands.—The bronchial and dorsal mediastinal glands were slightly enlarged; they showed on section in the cortices a moderate number of irregular calcareous tubercles and a few irregular nodules up to a hemp seed. In the long mediastinal there were in addition to single tubercles three nodules, one a firm caseo-calcareous nodule with firm fibrous margins measured 2 by 1·5 by 1·2 cm.; the other two were smaller and composed of aggregated calcareous or caseo-calcareous tubercles embedded in glandular tissue which was firmer than the tissue in other parts of the gland.

Pleura and Heart.—Normal.

Abdomen.

Omentum and Peritoneum.—Normal.

Spleen.—In the spleen pulp five grey miliary tubercles with calcareous centres and three caseous gritty nodules 2 to 3·5 mm. in diameter were found.

Liver.—The capsule on the anterior surface of the liver showed a number of small fibrous tags. In the substance under the capsule three minute calcareous foci were found, one was surrounded by a fibrous capsule; on section minute yellow calcareous foci were sparsely distributed throughout the substance.

Portal Glands.—Each portal gland contained a moderate number of irregular yellow calcareous nodules up to about 4 mm. in diameter, the larger ones composed apparently of several smaller ones aggregated together.

Coeliac Glands.—In each there were a few minute calcareous tubercles.

Kidneys.—In the superficial part of the cortex of the right kidney just beneath the capsule there were about twenty grey translucent miliary tubercles some with minute opaque centres.

Tubercles similar but rather less numerous were seen on the surface of the left kidney and in the depth of the cortex of each kidney.

Suprarenal Bodies.—Each suprarenal body was closely beset with caseo-calcareous nodules with grey fibrous margins ranging from 2 to 4 mm. in diameter.

Alimentary Tract.

Tongue, Pharynx, Tonsils.—Normal.

The Submaxillary, Retro-pharyngeal and Parotideal Glands contained scattered calcareous tubercles ranging from a mere point up to a millet seed; some of the larger ones seemed slightly caseous.

Intestines.—All the Peyer's patches in the small intestine were thickened and considerably raised above the surface; they showed numerous irregular ulcers of various sizes with thickened margins and base infiltrated with calcareous deposit in the form chiefly of foci and coarse streaks which projected from, and could be felt on passing the finger over, the floor. The mucous membrane of the intestine elsewhere showed numerous raised flattened nodules up to a split pea in size, all of which had a central ulcer; some of these contained a small quantity of caseopus, but the majority were free from caseation or calcification.

The mucous membrane of the large intestine was studded with similar nodules, but the ulcers in many were much larger and there was no sign of caseation or calcification in any; some were merely a ring of raised mucous membrane surrounding an ulcer with smooth floor.

Mesenteric Glands.—Each mesenteric gland showed in the cortex a moderate number of irregular calcareous tubercles and nodules, they were larger in the posterior mesenteric, and resembled the nodules in the portal glands.

Ileo-Colic Glands.—These glands contained similar tubercles and nodules and some large patches composed of aggregated nodules.

Testicles.—Normal.

Various Lymphatic Glands.

Precrural Glands.—Each contained three or four minute calcareous foci; in the left there was besides a soft caseous gritty nodule about 2 mm. in diameter.

Popliteal Glands.—In the cortex of the left there were three, and in that of the right four calcareous foci.

Iliac Glands.—There were a few similar foci in the iliac glands.

Lumbar and Renal Glands.—Each contained a few similar foci.

Axillary Glands.—Each contained one calcareous focus.

Gluteal Glands.—Normal.

Ischiatic Glands.—In one there were two calcareous foci; the other was normal.

Haemo-lymph Glands.—Many haemo-lymph glands were enlarged and contained submiliary calcareous tubercles.

Microscopical Examination.

Emulsion of nodule from Lung.—Tubercle bacilli scanty.

Emulsion of nodule from Long Mediastinal Gland.—A few tubercle bacilli seen.

CALF 1605. Virus H. 108. "H.R."

Subcutaneous inoculation of culture derived from the mediastinal gland of Calf 1537.

Dose—50·0 milligrammes.

Date of Inoculation—October 6, 1909. [Age about 14 weeks.]

Died—November 29, 1909. [54 days after inoculation.]

Clinical Notes.

The course of the disease was similar to that which has frequently followed the inoculation of bovine tubercle bacilli.

Temperature.

On the 12th day after inoculation the temperature rose to 40·1° C. It remained high (maximum 40·5° C., minimum 39·6° C.) until the animal died on the 54th day.

Weights.

	cwt.	qr.	lbs.
October 6, 1909	1	1	6
November 29, 1909	1	0	21

Total loss of weight.—13 lbs.

Average rate of loss per week.—1·6 lbs.

POST-MORTEM EXAMINATION.

The carcass was thin.

Local Lesion.—The tumour at the seat of inoculation on the left side of the neck weighed with attached skin 1 lb. 2 ozs., and measured 16 by 9 by 6 cm.

On section it was composed of whitish-yellow caseous substance infiltrating both the skin and the subjacent muscles and containing a loculated cavity filled with clear serous fluid.

Left Prescapular Gland.—The left prescapular gland was very large; it weighed 9 ozs. and measured 11 by 5·5 by 5 cm. On section it was dense pinkish-yellow and caseo-necrotic throughout.

Right Prescapular Gland.—The right prescapular gland measured 4 by 1·7 by 0·8 cm. and on section contained four congested hemp-seed sized caseating nodules.

Prepectoral Glands.—The round gland on the left side measured 3·5 cm. in diameter and was similar on section to the left prescapular. The kidney-shaped gland and a third (spherical) gland, 1 cm. in diameter, showed early caseation of their cortices.

One of the right prepectoral glands was occupied by confluent whitish tubercles, and two others contained one or two tubercles each.

Cervical Glands.—The lower cervical gland on the left side was very large, measuring 4·5 by 4·3 by 3 cm., and on section was similar to the left prescapular gland.

Of the other cervical glands on this side and those on the right many were slightly enlarged and all contained one or more caseating tubercles.

Axillary Glands.—The left was normal; the right contained several minute tubercles.

Thorax.

Pleura.—The costal pleura showed along the margins of nearly all the ribs on the left side and of several on the right reddish growths in which were numerous tubercles mostly minute; and showed also several caseating nodules, the largest of which was lenticular, 7 mm. in diameter, and loosely attached.

The pleural surface of the pericardium was extensively covered with tuberculous growths, and the pleural surface of the diaphragm showed red patches large and small (the largest was 2 by 1·5 cm. in area), which were closely filled with tubercles, mostly minute. All but one of the patches were quite thin; the exception measured 3 mm. in thickness; on section it was soft and pulpy and had a granular appearance, being filled with minute tubercles.

Lungs.—The lungs were large and filled the chest. They weighed 7 lbs. 9 ozs. The anterior and middle lobes, and the anterior and inferior portions of the caudal lobes, were dark red in colour and thickly studded with irregular greyish-yellow tubercles and nodules from 1 to 5 or 6 mm. in diameter in many places becoming confluent; the remainder of the caudal lobes showed irregular dark-red areas of various sizes and similar but less numerous tubercles and nodules.

The lymphatic fringes along the margins of the lungs were in several places congested and hypertrophied and contained numerous minute greyish-yellow tubercles; one or two loosely attached flattened nodules were also seen.

The anterior halves of the lungs were on section found to be almost completely consolidated, portions sinking in water, and closely filled with irregular confluent caseating tubercles and nodules forming in places small patches.

In the posterior halves of the caudal lobes there was a moderate amount of crepitant and functional lung tissue remaining; pieces just floated in water. They contained numerous caseating tubercles and nodules similar to those in the anterior halves of the lungs, and there were several large caseating areas occupying whole lobules; many lobules also were solid and haemorrhagic, but were not more closely filled with tubercles than surrounding lobules.

Thoracic Glands.—The bronchial and mediastinal glands were much enlarged, and weighed 12 ozs. The long mediastinal gland measured 13·5 by 6·5 by 2·5 cm.

On section the cortices of the glands were composed of firm pinkish-grey tissue, infiltrated with yellow caseous patches and fine caseous networks.

Heart.—The right auricle showed under the endocardium a hemp-seed sized caseating nodule. The heart was otherwise normal.

Larynx and Trachea.—Normal.

Abdomen.

Omentum.—The omentum showed three flattened lenticular nodules with congested margins, the largest measuring 7·5 by 4 mm., firm and caseous on section, and a moderate number of tubercles up to 1 mm. in diameter, the smaller translucent, the larger opaque.

Parietal Peritoneum.—Normal.

Spleen.—The spleen was slightly enlarged. The substance was moderately closely beset with yellow caseous nodules ranging from 2 to 5 mm. in diameter; the majority were about 3 to 4 mm.

Liver.—The liver showed on the convex surface a moderate number of yellowish-white tubercles and nodules ranging from 1 to 7 mm. in diameter, the larger ones being flattened and slightly projecting; other tubercles more deeply situated were more or less dimly seen through the capsule. On the under surface similar tubercles and nodules were seen; the larger ones were more prominent than those on the convex surface. On section the tubercles were opaque, and the larger nodules were yellow and caseous in the centre.

A moderate number of tubercles from 1 to 2 mm. in diameter similar to those on the surface were evenly distributed throughout the substance of the liver; one rather larger tubercle was seen, situated in the wall of the portal vein and projecting into the lumen.

Portal Glands. — The portal glands were much enlarged and almost entirely composed of confluent caseating nodules.

Coeliac Glands.—One was enlarged and similar to the portal glands, the others showed discrete caseating nodules.

Kidneys.—The kidneys were pale. Each showed on the surface about 40 yellowish-white tubercles from 1 to 3 mm. in diameter, the majority slightly projecting the surface; the right showed also one nodule 5 mm. in diameter. A moderate number of similar tubercles were seen in the depth (cortex and medulla) of each kidney. The tubercles were firm and opaque on section.

Suprarenal Bodies.—The left was normal. The right contained one hemp-seed sized tubercle with a calcareous centre.

Alimentary Tract.

Tongue, Pharynx, Palate, Tonsils.—Normal.

Both Retro-pharyngeal, both Parotideal, and both Submaxillary Glands each contained several caseating tubercles about 2 mm. in diameter.

Small Intestines.—In the long Peyer's patch in the ileum there were four hemp-seed sized caseating tubercles. Three other Peyer's patches in the small intestine contained each a caseating tubercle.

Large Intestine.—Normal.

Mesenteric and Ileo-colic Glands.—All the mesenteric glands contained a moderate number of caseating nodules up to a hemp seed in size.

In the ileo-colic glands there were similar and slightly more numerous nodules.

Mamma.—The mamma was very small and undevoloped, and showed no sign of tuberculosis.

Eyes.—The right eye showed in the ciliary processes one small whitish tubercle.

Various Lymphatic Glands.

The Precrural, Popliteal, Iliac, Gluteal, and Pudic Glands each contained a few caseating nodules up to 3 mm. in diameter.

The Renal Glands were rather closely beset with caseating tubercles and nodules.

The Lumbar Glands contained many caseating tubercles and nodules up to 4 mm. in diameter.

The Ischiatic Glands were normal.

Several of the haemolymph glands contained caseous tubercles.

Microscopical Examinations.

Smear from Long Mediastinal Gland. — Very numerous tubercle bacilli.

Smear from Pudic Gland. — Numerous tubercle bacilli.

CALF 1553. Virus H. 108. "H.R."

Subcutaneous inoculation of culture derived from the spleen of Calf 1421.

Dose—50·0 milligrammes.

Date of Inoculation—February 26, 1909. [Age 7 weeks.]

Killed when in good health—June 2, 1909. [96 days after inoculation.]

Clinical Notes.

The calf remained well during the experiment and grew normally.

Temperature.

There was a slight rise of temperature commencing on the 9th day after inoculation and lasting 15 days (maximum 40·2° C.) ; otherwise the temperature was normal during the experiment.

Weights.

	cwt.	qrs.	lbs.
February 26, 1909	1	0	0
June 2, 1909	1	3	16

Total gain of weight.—3 qrs. 16 lbs.

Average rate of gain per week.—7·3 lbs.

POST-MORTEM EXAMINATION.

The carcass was in good condition.

Local Lesion.—On the left side of the neck, at the seat of inoculation, there was a fluctuating tumour measuring 9 by 7·5 by 5 cm. ; on section it was a cyst with moderately thick fibrous wall, lined with gritty granulation tissue and caseo-purulent contents.

Left Prescapular Gland.—The left prescapular gland measured 8 by 4·5 by 3·5 cm. and was caseous and calcareous practically throughout ; in one place the caseous substance had undergone softening.

Right Prescapular Gland.—The right prescapular gland measured 5 by 2·2 by 1 cm. and contained about a dozen caseous gritty nodules varying from 2 to 5 mm. in diameter.

Prepectoral Glands.—One on the left side was much enlarged 3 cm. in greatest diameter and was dense and caseous throughout ; the capsule was greatly thickened. Two others on this side contained each two caseo-calcareous tubercles.

One on the right side contained one tubercle.

Cervical Glands.—On the left side three glands in the lower part of the neck were enlarged, the largest measuring 2·5 cm. in greatest diameter ; two were caseous throughout and slightly gritty from calcification, the third showed a calcareous patch replacing about one-third of its substance ; the upper cervical on each side contained scattered caseous gritty tubercles, the rest with one exception contained one or two caseous gritty tubercles.

Thorax.

Lungs.—One minute grey tubercle was seen under the pleura ; none was seen on section.

Thoracic Glands.—The bronchial and mediastinal glands were not enlarged ; they contained a moderate number of discrete calcareous tubercles the largest the size of a millet seed.

Heart and Pleura.—Normal.

Abdomen.

Omentum and Peritoneum.—Normal.

Spleen.—The pulp contained four caseous gritty nodules 2 to 3 mm. in diameter.

Liver.—On the surface under the capsule there were four opaque greyish tubercles ; one tubercle was seen on section.

Portal Glands.—The portal glands were not enlarged ; they were similar on section to the thoracic glands.

Pancreatic Glands.—In one there were a few tubercles.

Coeliac Glands.—The coeliac glands were very slightly enlarged ; one was calcareo-caseous almost throughout, another contained calcareous patches, two others discrete calcareous tubercles.

Kidneys.—In the cortex of each kidney there were two or three small grey tubercles.

Suprarenal Bodies.—In the cortex of the left there was one and in that of the right four caseous gritty tubercles with fibrous walls the largest 2 mm. in diameter.

Alimentary Tract.

Tongue, Pharynx, Palate, Tonsils.—Normal.

The Retro-pharyngeal, Submaxillary, and Parotideal Glands contained scattered softened caseous gritty nodules the largest 5 mm. in diameter.

Intestines.— All the Peyer's patches contained some a few others a moderate number of yellow gritty foci; the mucous membrane of each patch showed a varying number of small ulcers with no sign of central caseation: these possibly marked the sites of tubercles which had ulcerated through; in the lower part of the intestine the mucous membrane showed numerous slightly raised nodules, each of which had an opening or small ulcer in the centre; the nodules could be felt between finger and thumb as distinct thickenings, but on section there was no sign of caseation or calcification.

The mucous membrane of the large intestine showed similar nodules.

Mesenteric Glands.—In the cortices there was a moderate number of calcareous tubercles, mostly discrete, but here and there aggregated together into small groups.

Ileo-colic Glands.—These glands showed calcareous patches and discrete calcareous tubercles.

Larynx and Trachea.—Normal.

Testes.—Normal.

Various Lymphatic Glands.

Precrural Glands.—In each there were about half-a-dozen caseous and softened gritty nodules varying in diameter up to 5 mm.

The Popliteal, Iliac, Ischiatic and Right Gluteal Glands contained sparsely scattered (from two to six) caseous gritty nodules ranging up to 2 or 3 mm. in diameter. The left gluteal gland was normal.

Pudic Glands.—Each gland contained one softened caseous gritty nodule, the largest 5 mm. in diameter.

RHESUS MONKEY 165. Virus H. 108. "H.R."

(A young animal.)

Subcutaneous inoculation of culture derived from the original material through Guinea-pig 2957.

Dose—1·0 milligramme.

Date of Inoculation—May 19, 1908.

Died—August 23, 1908. [96 days after inoculation.]

Clinical Notes.

The monkey remained apparently in good health until within four or five days of death, when it lost its appetite, and looked ill and depressed. There were no other symptoms; the respiration was normal. The monkey gradually sank and was found dead on the morning of August 23. The weight at death was 1660 grammes.

POST-MORTEM EXAMINATION.

The carcass was in fair condition.

Local Lesion.—Over the left scapula there was a slightly raised firm swelling flattened on the surface measuring 3 by 2·5 cm. in area; the skin over it was congested adherent and showed three punched out openings covered with dried discharge each about 2 mm. in diameter; on section the tumour was composed of dense yellowish-white caseous substance surrounded by a zone of grey fibroid tissue, 1 mm. thick, adherent to the skin and underlying muscles.

Axillary Glands.—The glands on the right side were not enlarged; they contained altogether four miliary caseous tubercles.

On the left side one gland measured 1·5 by 1 cm. and was caseous and softened throughout; another 8 mm. in diameter was partly caseous; two smaller ones contained discrete caseous tubercles. None of the glands was adherent to the skin.

Cervical Glands.—On the right side behind the clavicle there was a gland the size of a small pea which was caseous and softened throughout.

On the left side there were two caseous and softened glands behind the middle of the clavicle and one close to its articulation with the sternum; near the former two there was a smaller gland containing discrete caseous tubercles. Other cervical glands were normal.

Vertebral Glands.—On the left side in the seventh interspace there was a caseous and softened gland the size of a split pea. Other vertebral glands were normal.

Thorax.

Lungs.—The lungs were voluminous and did not collapse on opening the chest. The ventral parts of the anterior and posterior lobes on each side were red and hepatised; the right middle lobe was red and solid almost throughout; the rest of the lungs was congested and emphysematous. The parenchyma contained fairly numerous evenly distributed grey tubercles ranging from about 0·5 to a little more than 1 mm. in diameter; most of the larger tubercles had minute caseous centres, the rest were homogeneous throughout.

Bronchial Glands.—The bronchial glands were enlarged and congested, two of the intertracheo-bronchial glands contained each one miliary caseous tubercle; no tubercles were seen in the other glands.

Heart and Pleura.—Normal.

Abdomen.

Omentum, Mesentery and Parietal Peritoneum.—Normal.

Meso-colon.—On the meso-colon there were two grey miliary tubercles with minute caseous centres.

Spleen.—The spleen was not enlarged (5·5 by 2·5 by 1 cm.) and contained a moderate number of discrete yellow caseous and softened nodules ranging in diameter from 1 to 3 mm.; eight were counted in a square centimetre of the cut surface.

Splenic Gland.—One splenic lymphatic gland contained an opaque white tubercle the size of a millet seed.

Liver.—The liver was normal in size and general appearance, it showed in the substance sparsely scattered tubercles ranging up to 1·5 mm. in diameter; many of the smaller ones were grey and homogeneous, the rest had caseous centres.

The gland on the head of the pancreas near the hilum of the liver was enlarged, and its cortical substance extensively replaced by yellow caseous and softened areas up to 3 mm. in diameter.

A gland on the small omentum near the pylorus was enlarged, and beset with caseous nodules.

Kidneys.—Both kidneys showed on the surface a moderate number of miliary caseous tubercles and a few smaller translucent grey ones; 24 to 30 were seen on the surface of each. A few caseous tubercles were found in the depth of the cortex.

Suprarenal Bodies.—Normal.

Iliac and Lumbar Glands.—One iliac gland contained a pinhead-sized caseous tubercle.

The lumbar glands were deeply congested; in one there was a hemp seed sized caseous nodule.

Alimentary Tract.

Tongue. Pharynx, Tonsils.—Normal.

Submaxillary Glands.—One on the right side contained a pinhead sized caseous tubercle; the others were normal.

Pharyngeal Glands.—Normal.

Intestines.—Normal.

Mesenteric Glands.—The glands in the anterior part of the mesentery were slightly enlarged and showed their cortices extensively caseous; several of the other glands showed discrete caseous tubercles or irregular early caseous patches.

Ileo-Colic Glands.—Each contained one miliary caseous tubercle.

Colic Glands.—All the colic glands were larger than normal and many contained one or two caseous miliary tubercles.

Inguinal Glands.—Normal.

Brain.—Normal.

Microscopical Examination.

Tubercle from Ileo-Colic Gland.	Extremely numerous tubercle bacilli, many small clumps and some large ones: resembled a pure culture.
Tubercle from Submaxillary Gland.	

RHESUS MONKEY 307. Virus H. 108. "H.R."

(A young animal.)

Subcutaneous inoculation of culture derived from the lung of Calf 1417.

Dose—1·0 milligramme.

Date of Inoculation—April 22, 1909.

Died—May 20, 1909. [28 days after inoculation.]

POST-MORTEM EXAMINATION.

The carcass was emaciated. Its weight was 1900 grammes.

Local Lesion.—The skin over the lower angle of the right scapula showed an ulcer about 2 cm. in diameter leading into a collapsed cavity, 4 cm. in greatest diameter, containing a small quantity of caseo-pus. The deep wall of the cavity was lined with haemorrhagic granulation tissue.

Axillary Glands.—On the right side two the size of sparrows eggs were caseous throughout; a third contained discrete caseous tubercles.

On the left side two slightly enlarged glands contained discrete caseous tubercles.

Cervical Glands.—One on the right side contained a millet seed-sized caseous tubercle; those on the left appeared normal.

Vertebral Glands.—On the right side one in the 7th and one in the 9th interspaces were enlarged, the largest, 8 mm. in greatest diameter, caseous and softened throughout.

On the left side one in the 11th interspace contained caseous tubercles.

Thorax.

Lungs.—The lungs were crepitant; the right caudal lobe was slightly adherent to the enlarged vertebral glands; the lung parenchyma contained scattered caseous tubercles with grey margins ranging from 1 mm. to 2 mm. in diameter.

Bronchial Glands.—The bronchial glands were not enlarged but contained scattered pinhead-sized caseous tubercles.

Heart and Pleura.—Normal.

Abdomen.

Omentum.—The omentum showed two or three caseous tubercles and a few minute grey ones.

Parietal Peritoneum.—Normal.

Spleen.—The spleen was enlarged measuring 6 by 3·3 by 2 cm., and showed the pulp replaced by yellow softened nodules ranging up to 2 mm. in diameter and everywhere becoming confluent.

There were a few miliary caseous tubercles in the splenic lymphatic gland.

Liver.—The liver was greatly enlarged, the substance was pale and very closely beset with discrete caseous tubercles varying from 0·5 to 1·5 mm. in diameter.

The Gland on the head of the Pancreas was enlarged and showed the cortex completely replaced by coalescing caseous tubercles.

Kidneys.—The kidneys were pale and soft; on the surface of the left there was one and on that of the right two miliary caseous tubercles; in the depth of the cortex of the left one tubercle was found and in that of the right three.

Suprarenal Bodies.—Normal.

Lumbar and Iliac Glands.—The lumbar glands were enlarged and closely beset with caseous tubercles. One iliac gland contained two caseous tubercles.

Alimentary Tract.

Tongue, Pharynx, Tonsils.—Normal.

Submaxillary Glands.—Each contained a few caseous tubercles.

There was a caseous tubercle in the submaxillary salivary glands.

Retro-pharyngeal Glands.—There were a few tubercles in each gland.

Gastric Glands.—Two near the cardiac end showed numerous caseous tubercles in their cortices.

Intestines.—Normal.

The Mesenteric and Ileo-colic Glands contained scattered miliary caseous tubercles.

Colic Glands.—One contained a caseous tubercle.

Inguinal Glands.—Each group contained a moderate number of miliary caseous tubercles.

RHESUS MONKEY 309. Virus H. 108. "H.R."

(A young animal.)

Subcutaneous inoculation of culture derived from the lung of Calf 1417.

Dose—1·0 milligramme.

Date of Inoculation—April 22, 1909.

Died—May 21, 1909. [29 days after inoculation.]

POST-MORTEM EXAMINATION.

The carcass was emaciated. Its weight was 1870 grammes.

Local Lesion.—In the subcutaneous tissues of the back on the right side behind the scapula there was an abscess about the size of a pullet's egg filled with caseo-pus; the walls were thin and composed of a fibrous membrane lined internally with a layer of firm caseous substance.

Axillary Glands.—On the right side one slightly enlarged gland showed caseous and softened patches in the cortex; the rest were free from caseation.

On the left side one gland contained a caseous tubercle.

Cervical Glands.—On the right side in the posterior triangle one gland contained a caseous tubercle; on the left, two the size of small peas were caseous and softened throughout.

Vertebral Glands.—On the right side extending from the 8th to the 12th interspace there was a chain of caseous and softened glands the largest 1 cm. in diameter; on the left side in a corresponding position there were three slightly enlarged partly caseous glands.

Thorax.

Lungs.—The lungs were crepitant and adherent on the right side to the enlarged vertebral glands. The lung parenchyma contained scattered miliary grey tubercles, the majority with minute caseous centres.

Bronchial Glands.—The praetracheo-bronchial glands contained three caseous tubercles; an inter-bronchial gland was slightly enlarged and showed a patch of aggregated tubercles.

Pleura.—The parietal pleura was normal except where the lungs were adherent to the enlarged vertebral glands.

Heart.—Normal.

Abdomen.

Omentum and Peritoneum.—Normal.

Spleen.—The spleen was slightly enlarged, and moderately closely beset with yellow caseous tubercles the largest the size of a millet seed.

One splenic lymphatic gland contained four miliary caseous tubercles.

Liver.—The liver contained moderately numerous evenly distributed caseous tubercles ranging from a point up to a millet seed in size.

Portal Gland.—The portal gland was slightly enlarged, and the cortex closely beset with caseous tubercles.

Kidneys.—The right kidney showed on the surface one caseous tubercle and one in the depth of the cortex; there were no tubercles on the surface of the left and only one caseous tubercle was found in the depth.

Suprarenal Bodies.—Normal.

Iliac Glands.—Normal.

Lumbar Glands.—One lumbar gland was slightly enlarged and filled with caseous tubercles.

Alimentary Tract.

Tongue, Pharynx, Tonsils; Submaxillary and Retro-pharyngeal Glands; Intestines.—Normal.

Gastric Glands.—A gland near the cardiac end of the stomach and one on the pylorus were slightly enlarged and showed discrete caseous tubercles in the cortex.

Mesenteric Glands.—Normal.

Ileo-Colic Glands.—One contained several minute caseous foci.

Inguinal Glands.—Each group contained a few miliary caseous tubercles.

RHESUS MONKEY 311. Virus H. 108. "H.R."

(A young animal.)

Subcutaneous inoculation of culture derived from the mediastinal gland of Calf 1417.

Dose—1·0 milligramme.

Date of Inoculation—April 22, 1909.

Died—September 13, 1909. [144 days after inoculation.]

POST-MORTEM EXAMINATION.

The carcass was emaciated. Its weight was 2,350 grammes.

Local Lesion.—In the subcutaneous tissues over the posterior ribs on the right side there was a flat caseous patch measuring 5 by 3 by about 7 cm. the skin over which was adherent puckered and showed several small ulcers.

Axillary Glands.—All the glands on the right side were much enlarged caseous and softened throughout, on the left side there was one the size of a thrush's egg which was caseous throughout.

Cervical Glands.—On the right side one gland contained a hemp seed-sized caseous nodule; on the left side there were three caseous and softened glands the size of large peas. An upper cervical gland on each side was slightly enlarged and caseous.

Vertebral Glands.—On the right side in the 8th, 9th, and 10th interspaces there were three large glands each a centimetre in diameter which were fused together and caseous and softened throughout.

Other vertebral glands were normal.

Thorax.

Pleura.—The costal pleura on the right side showed about a dozen raised millet seed-sized caseous tubercles.

Lungs.—The right caudal lobe of the lungs was adherent to the enlarged vertebral glands, and there were several slender adhesions between the left lung and the costal pleura.

The lung tissue was crepitant and contained moderately numerous evenly distributed shotty caseous nodules with grey margins ranging from 1 to 3 mm. in diameter (the majority about 2 mm.) here and there becoming confluent; the antero-ventral tip of the left caudal lobe contained a bean-sized caseating nodule.

Bronchial Glands.—The bronchial glands were moderately enlarged and were firm and caseous throughout with the exception of one praetracheo-bronchial gland which contained discrete caseous nodules.

Heart.—Normal.

Abdomen.

Omentum.—The omentum contained about a score of shotty caseous nodules ranging up to 2 mm. in diameter.

Parietal Peritoneum.—Normal.

Spleen.—The spleen showed a moderate degree of enlargement measuring 5·5 by 3 by 1·5 cm. and was moderately closely beset with caseous and softened nodules, the largest about 5 mm. in diameter; yellow nodules projected from the surface.

Splenic Lymphatic Glands.—Normal.

Liver.—The liver was very pale and contained scattered caseous nodules varying in size up to that of a pea, the majority firm, a few softened and bile-stained.

On the head of the pancreas there was a slightly enlarged gland whose cortex was filled with caseous nodules up to a hemp seed in size.

Kidneys.—The right kidney showed in the cortex half-a-dozen caseous nodules varying from 1 to 3 mm. in diameter.

In the cortex of the left kidney there were four caseous nodules, the largest 2 mm. in diameter.

Suprarenal Bodies.—Normal.

Lumbar Glands.—Two lumbar glands were slightly enlarged, but caseous practically throughout.

Mesenteric Glands.—These glands were normal in size and contained four caseous and softened nodules, the largest the size of a hemp seed.

Inguinal Glands.—On the right side one contained a hemp seed-sized caseous and softened nodule, those on the left side were normal.

The organs and glands not mentioned were examined and found normal.

RHESUS MONKEY 361. Virus H. 108. "H.R."

(A young animal.)

Subcutaneous inoculation of culture derived from the mediastinal gland of Calf 1537.

Dose—1·0 milligramme.

Date of Inoculation—November 30, 1909.

Died—January 22, 1910. [53 days after inoculation.]

POST-MORTEM EXAMINATION.

The carcass was emaciated. Its weight was 1,550 grammes.

Local Lesion.—Over the right scapula there was a circular ulcer 3 cm. in diameter with a dry floor; the margins were thin and slightly undermined, the floor of the ulcer here showing yellow pus; there were a few caseous tubercles in the muscles beneath the ulcer.

Axillary Glands.—On the right side all were enlarged and caseous throughout; on the left one contained a caseous nodule.

Cervical Glands.—Normal.

Vertebral Glands.—On the right side three glands were slightly enlarged and caseous throughout; on the left side there was one caseous gland.

Thorax.

Pleura.—The pleura was congested and showed a few small caseous tubercles.

Lungs.—The lungs filled the chest and collapsed only slightly; the parenchyma was extensively and irregularly hepatised (red); it contained numerous miliary caseous tubercles, in many places aggregated together.

Bronchial Glands.—These were moderately enlarged and caseous almost throughout.

Heart.—The pericardial sac was full of fluid. The muscle of the right auricle contained a caseous tubercle.

Abdomen.

The peritoneal cavity contained an excess of fluid.

Omentum.—The omentum was congested and closely beset with miliary caseous tubercles.

Peritoneum.—Normal.

Spleen.—The spleen was enlarged, 5·5 cm. in length, and packed almost as closely as possible with yellow caseous nodules up to a hemp-seed in size.

Splenic Lymphatic Glands.—These contained caseous tubercles.

Liver.—The liver contained numerous caseous tubercles up to 2 mm. and numbers of small tubercles less than 0·5 mm. in diameter.

Portal Glands.—These were enlarged and caseous practically throughout.

Kidneys.—In the cortex of each moderately numerous miliary caseous tubercles were seen.

Lumbar and Iliac Glands.—The former were slightly enlarged and partly caseous; the latter were normal.

Alimentary Tract.

Tongue, Pharynx, Tonsils.—Normal.

Submaxillary and Pharyngeal Glands.—One of the former and one of the latter contained each a caseous tubercle.

Intestines.—Normal.

Mesenteric Glands.—The mesenteric glands contained a few caseous tubercles.

Brain.—Normal.

Inguinal Glands.—These glands contained a few caseous tubercles.

RHESUS MONKEY 363. Virus H. 108. "H.R."

(A young animal.)

Subcutaneous inoculation of culture derived from the mediastinal gland of Calf 1537.

Dose—1·0 milligramme.

Date of Inoculation—November 30, 1909.

Died—January 27, 1910. [58 days after inoculation.]

POST-MORTEM EXAMINATION.

The carcass was emaciated.

Local Lesion.—The local lesion was a hemispherical breaking-down caseous mass 4·5 cm. in diameter.

Axillary Glands.—On the right side all the glands were enlarged and caseous. On the left side one pea-sized gland was partly caseous.

Cervical Glands.—In the posterior triangle on each side there was a group of enlarged caseous glands. One in the middle of the neck on the right side contained a caseous tubercle.

Vertebral Glands.—One opposite the 2nd interspace on the right side was large and caseous throughout; two in the middle of the column, one on each side, were slightly enlarged and caseous throughout.

Thorax.

Pleura.—There was one tubercle on the costal pleura.

Heart.—Normal.

Lungs.—The lungs were voluminous and diffusely hepatised and contained numerous caseous nodules varying in size from a millet-seed to a pea.

Bronchial Glands.—The bronchial glands were enlarged and caseous practically throughout.

Diaphragm.—The tendon of the diaphragm, chiefly near the muscle, showed numerous caseous tubercles seen on both surfaces.

Abdomen.

The peritoneal cavity was full of yellow serous fluid.

Omentum.—The omentum was congested, thickened, and closely peppered with minute caseous tubercles; it was intimately adherent to the spleen which it almost completely surrounded.

Meso-colon.—The meso-colon showed moderately numerous small caseous tubercles.

Mesentery.—Normal.

Parietal Peritoneum.—There was a patch of caseous tubercles on the peritoneum over the lower ribs on the right side.

Spleen.—The spleen was very greatly enlarged (9·5 by 5 by 3·5 cm.) and was adherent to the parietal wall of the abdomen; the pulp was packed as closely as possible with caseous and softened nodules.

Liver.—The substance contained numerous caseous nodules ranging from a millet to a hemp seed, the larger softened.

The glands on the head of the pancreas and two in the hilum of the liver were enlarged and caseous throughout.

Kidneys.—In the cortex of each kidney there were a few caseous tubercles.

Suprarenal Bodies.—Normal.

Lumbar and Iliac Glands.—The former were enlarged and caseous throughout, the latter contained caseous nodules.

Alimentary Tract.

Tongue, Pharynx, Tonsils.—Normal.

Retro-pharyngeal Glands.—On the right side, one the size of a small pea was caseous throughout.

Submaxillary Glands.—On the left side, one was slightly enlarged and partly caseous.

Intestines.—Not examined.

Mesenteric Glands.—The mesenteric glands contained a few caseous tubercles.

Ileo-colic and Colic Glands.—These were slightly enlarged and each contained a caseous tubercle or two.

Inguinal Glands.—The glands on one side were partly caseous, those on the other contained discrete tubercles.

Brain.—Normal.

VIRUS H. 108. "H.R."

ABSTRACTS OF THE POST-MORTEM NOTES OF RABBITS INOCULATED WITH CULTURES DERIVED FROM THE CALVES THROUGH WHICH THE VIRUS HAD BEEN PASSED.

1.—Subcutaneous Inoculations.

Source of Culture.	Dose in Milli-grammes.	Number of Rabbit.	Weight in Grammes.		Duration of Life.	Result.
			Initial.	Final.		
						Series α.
Calf 1417 (1st calf) Lung.	10·0 mg.	2107	1,600	1,350	Died 39 days	General tuberculosis.
	10·0 mg.	2108	1,400	1,010	Died 31 days	General miliary tuberculosis.
	36·0 mg.	2310	1,350	1,050	Died 44 days	General tuberculosis.
	10·0 mg.	2309	1,400	1,420	Died 37 days	General tuberculosis.
Calf 1539 (2nd calf) Bronchial gland.	10·0 mg.	2325	1,450	1,100	Died 36 days	General miliary tuberculosis.
	10·0 mg.	2326	1,740	1,350	Died 44 days	General tuberculosis.
						Series β.
Calf 1417 (1st calf) Mediastinal gland.	10·0 mg.	2120	1,700	2,200	Died 193 days	Slight chronic general tuberculosis (? cause of death). There was a very large thin-walled caseo-purulent cyst at the seat of inoculation, and the nearest gland was caseous. The lungs were crepitant, and showed in the thin margins an incomplete border of caseous substance, and elsewhere scattered caseous tubercles and nodules up to a hemp seed in size. Each kidney showed a scar or two on the surface, and one contained a grey nodule and two caseous streaks. There were a few minute caseous gritty tubercles in the spleen, and a few calcareous tubercles in the portal glands.
	10·0 mg.	2121	1,350	1,350	Died 122 days	Chronic general tuberculosis, not severe. The local lesion was a large thin-walled cyst filled with caseo-pus, and the nearest glands were caseous and softened, or contained caseous patches. The lungs were crepitant, and showed some superficial caseating patches, caseation of the thin margins, and scattered caseating nodules elsewhere. There were about a dozen caseous tubercles in each kidney, and one contained in addition two wedge-shaped nodules. The tracheal glands contained small caseous tubercles, the spleen one caseous tubercle. There were a few caseous tubercles in the areolar tissues of the groin and scapulæ.
	10·0 mg.	2311	1,100	2,700	Killed 206 days	General tuberculosis, not severe. The local lesion was nodular and caseous; the nearest glands were normal. The lungs were crepitant and moderately closely beset with grey miliary tubercles, some with caseous centres; they contained also many caseating nodules (smear, T.B. numerous) and one large thin-walled cyst filled with caseo-pus. There were numerous projecting caseating nodules up to a hemp seed in size in the cortex of each kidney (smear, a few T.B.). The dilated end of the ileum was beset with caseous foci.
Rabbit 2311 (inoculated with culture from Calf 1417). Kidney	10·0 mg.	2498	4,020	3,070	Died 63 days	General tuberculosis.
	10·0 mg.	2499	2,800	1,950	Died 43 days	General miliary tuberculosis.
	10·0 mg.	2500	2,550	1,600	Died 57 days	General tuberculosis.
Lung ...	9·0 mg.	2501	2,970	1,820	Died 61 days	General tuberculosis.
	10·0 mg.	2502	3,550	2,100	Died 69 days	General tuberculosis, not severe.

VIRUS H. 108. "H.R."—*continued*

ABSTRACTS OF THE POST-MORTEM NOTES OF RABBITS INOCULATED WITH CULTURES DERIVED FROM PASSAGE CALVES—*continued.*

1.—SUBCUTANEOUS INOCULATIONS—*continued.*

Source of Culture.	Dose in Milli-grammes.	Number of Rabbit.	Weight in Grammes.		Duration of Life.	Result.
			Initial.	Final.		
Calf 1537 (2nd calf) Mediastinal gland.	10·0 mg.	2465	1,650	1,420	Died 35 days	General miliary tuberculosis.
	10·0 mg.	2467	1,550	1,150	Died 74 days	General tuberculosis.
	10·0 mg.	2478	1,570	1,600	Died 68 days	General tuberculosis.
	10·0 mg.	2479	1,650	1,400	Died 73 days	General tuberculosis.
	8·0 mg.	2477	1,820	1,490	Died 59 days	General tuberculosis.
Series γ.						
Calf 1421 (1st calf) Spleen.	10·0 mg.	2180	2,670	1,750	Died 234 days	Chronic general tuberculosis, not severe. There was a thin-walled cyst with creamy caseous contents; the nearest glands were normal. The lungs showed firm caseous patches in the margins, and a few miliary caseous tubercles elsewhere. There were scattered caseous tubercles on the mediastinal pleura. The kidneys showed on the surface scattered minute caseous foci, and on section fine caseous streaks; one showed also a large patch composed of tubercles with caseous centres which penetrated the substance as a caseous wedge. The right elbow joint was tuberculous; the testicles were atrophied and caseous, and there were small caseous nodules on their peritoneal surfaces and on the meso-testis. There were two fibro-caseous nodules in the intestinal wall (one ulcerated), and one mesenteric gland contained a caseous tubercle.
	10·0 mg.	2181	2,950	1,250	Died 208 days	Chronic general tuberculosis, not severe. The local lesion was a large thin-walled cyst containing caseo-pus. The nearest gland contained calcareo-caseous foci. The lungs showed on the surface and in the thin margins numerous caseo-calcareous nodules and patches, the largest measuring 3 by 4 cm.; the upper portions of the cephalic lobes were solid and caseo-calcareous; on section the lungs showed shotty tubercles and a moderate amount of crepitant tissue. There were a few small grey tubercles in the liver (smear, a few T.B.), one tubercle in a portal gland, one in a suprarenal body, and two in the spleen. Each kidney contained a moderate number of caseous tubercles.

2.—Intravenous Inoculations.

Calf 1417 (1st calf) Lung. Series α.	0·1 mg.	2105	2,150	1,700	Died 20 days	General miliary tuberculosis.
	0·01 mg.	2106	1,550	1,150	Died 24 days	General miliary tuberculosis.
Calf 1417 (1st calf) Mediastinal gland. Series β.	0·1 mg.	2118	2,300	1,600	Died 54 days	General tuberculosis.
	0·01 mg.	2119	2,100	1,200	Died 116 days	General tuberculosis, not severe.

VIRUS H. 109. "M.W."

LUPUS.

VIRUS H. 109. "M.W."

CULTURE INOCULATIONS.

I.—June 12, 1908.

The strain was derived from the original material through Guinea-pig 3002, and had been in artificial cultivation a total period of 50 days.

The culture used was the 4th generation, 13 days old.

CALF 1437.

Subcutaneous.

Dose: 47·0 mg.

Killed: September 26, 1908.

106 days.

P.M.—Cyst at seat of inoculation with caseo-purulent contents. The left prescapular gland contained scattered caseous foci and one cervical gland two small caseous or calcareous nodules. There was no tuberculosis elsewhere.

MONKEY 185.

Subcutaneous.

Dose: 0·1 mg.

Died: August 31, 1908.

80 days.

P.M.—General tuberculosis of moderate severity. (The spleen was enlarged and closely beset with caseous nodules; there were small scattered tubercles in the liver, none in the kidneys; the lungs contained scattered grey tubercles, the majority with caseous centres.)

RABBITS.

Number.	Method.	Dose.	Duration of Life.	Result.
1910	Intrav.	1·0 mg.	D. 15 days	Early G. T.
1911	Intrav.	0·1 mg.	K. 145 „	A few tubercles in lungs, kidneys and muscles.
1912	Intrav.	0·01 mg.	K. 145 „	One tubercle in lung.
1913	Intrav.	0·01 mg.	D. 18 „	Slight T. of lungs and kidneys. Death from (?) gastritis.
1914	Subcut.	1·0 mg.	K. 145 „	Local lesion only.
1915	Subcut.	1·0 mg.	K. 145 „	Local lesion only.

GUINEA-PIGS.

Number.	Method.	Dose.	Duration of Life.	Result.
3122	Intrap.	1·0 mg.	D. 24 days	G. T.
3123	Intrap.	0·1 mg.	D. 53 „	G. T.
3121	Subcut.	1·0 mg.	D. 136 „	Chronic G. T. not very severe.
3124	Subcut.	0·1 mg.	D. 176 „	G. T.

FOWLS.

Number.	Method.	Dose.	Duration of Life.	Result.
111	Intrav.	1·0 mg.	D. 4 days	No T. Cause of death not apparent.
113	Intrav.	1·0 mg.	K. 102 „	No T.

Virus H. 109. "M.W."—*continued.*

CULTURE INOCULATIONS—*continued.*

II.—JULY 27, 1908.

The strain was derived from the original material through Guinea-pig 3002, and had been in artificial cultivation a total period of 95 days.

The culture used was the 8th generation, 14 days old.

GOAT 61.
Subcutaneous.
Dose : 1·0 mg.
Killed : February 9, 1909.
197 days.
P.M.—Small local lesion only.

KID 71.
Suckling Goat 61.
From August 13, 1908, to January 14, 1909.
Killed : January 14, 1909.
154 days.
P.M.—No tuberculosis.

MONKEY 197.
Subcutaneous.
Dose : 1·0 mg.
Died : August 26, 1908.
30 days.
P.M. — Acute general tuberculosis.

RABBITS.

Number.	Method.	Dose.	Duration of Life.	Result.
1938	Subcut.	50·0 mg.	K. 144 days	Local lesion and slight T. of lungs, pleura and kidneys.
1939	Subcut.	10·0 mg.	K. 144 „	Local lesion only.

CALF 1437. Virus H. 109. "M.W."

Subcutaneous inoculation of culture derived from the original material through Guinea-pig 3002.

Dose—47·0 milligrammes.

Date of Inoculation—June 12, 1908. [Age about 13 weeks.]

Killed when in good health—September 26, 1908. [106 days after inoculation.]

Clinical Notes.

The calf remained well during the experiment.

Temperature.

On the 9th day after inoculation the temperature rose to 40·2° C. and reached a maximum of 40·4° C. on the 13th day. The temperature then fell steadily and the normal was reached on the 23rd day, the pyrexia having lasted 15 days. During the remaining period of the experiment the temperature was normal.

Weights.

	cwt.	qrs.	lbs.
June 12, 1908	1	0	24
September 26, 1908	1	2	8

Total gain of weight.—1 qr. 12 lbs.

Average rate of gain per week.—2·6 lbs.

POST-MORTEM EXAMINATION.

The carcass was in good condition.

Local Lesion.—At the seat of inoculation on the eft side of the neck there was a tense cyst measuring 9 by 5 by 4 cm., with not very thick fibrous walls and light brownish-yellow caseo-purulent contents.

Left Prescapular Gland.—The left prescapular gland was slightly enlarged, measuring 5·5 by 2·5 by 1·5 cm., and showed in the cortex sparsely scattered soft yellow caseous foci, a few of which were gritty.

Right Prescapular Gland.—The right prescapular gland measured 5 by 2 by 1 cm., and was normal on section.

Cervical Glands.—One of the lower cervical glands on the left side showed in the cortex a softened caseous nodule about 2 mm. in diameter, and a rather smaller calcareous nodule.

Axillary Glands.—Normal.

Thorax.

Pleura, Lungs, Heart, Thoracic Glands.—Normal.

Abdomen.

Omentum and Peritoneum.—Normal.

Spleen, Liver, Kidneys, and Suprarenal Bodies.—Normal.

Portal, Renal, Lumbar, and Iliac Glands.—Normal.

Alimentary Tract.

Tongue, Pharynx, Palate, Tonsils.—Normal.

Retro-pharyngeal, Submaxillary, and Parotideal Glands.—Normal.

Intestines and Mesenteric Glands.—Normal.

Various Lymphatic Glands.

Precrural, Popliteal, Gluteal, Ischiatic, Pudic.—Normal.

RHESUS MONKEY 185. Virus H. 109. "M.W."

(A young animal.)

Subcutaneous inoculation of culture derived from the original material through Guinea-pig 3002.

Dose—0·1 milligramme.

Date of Inoculation—June 12, 1908.

Died—August 31, 1908. [80 days after inoculation.]

Clinical Notes.

The monkey appeared to be in good health until within a week of death; the illness was of the usual character, characterized by loss of appetite and extreme weakness and emaciation.

POST-MORTEM EXAMINATION.

The carcass was thin.

Local Lesion.—The skin over the right scapula showed an ulcer 2 cm. in greatest diameter covered with a dry caseous scab. The skin around this ulcer, especially in one direction, was thin bluish and considerably undermined. On removing this skin an area was exposed 4 cm. in greatest diameter with an irregular surface covered with caseous substance; the base of this area was formed by fibroid muscular tissue infiltrated with caseous deposit.

Axillary Glands.—On the right side there were three large glands, two the size of large peas, the other measuring 1·4 by 1 cm., all yellow caseous and softened throughout. Another small gland on this side contained two caseous tubercles. The glands on the left side were not enlarged and contained three millet-seed sized caseous tubercles.

Cervical Glands.—One behind the clavicle on the right side, the size of a small pea, was caseous and softened throughout. On the left side in a similar situation there were two caseous glands, the largest the size of a small pea.

Inguinal Glands.—The inguinal glands on each side contained caseous nodules.

Vertebral Glands.—One in the seventh and one in the eighth interspaces on the right side, each the size of a split pea, were soft and caseous throughout; the rest were normal.

Thorax.

Pleura.—Normal.

Lungs.—The lungs were crepitant, and contained scattered tubercles ranging in size from 0·5 to 2 mm.; some of the smallest ones were translucent throughout; the others were caseous with grey margins.

Bronchial Glands.—The intertracheo-bronchial glands were slightly enlarged, and contained four caseous and softened nodules, the largest 2·5 mm. in diameter. The praetracheo-bronchial glands contained similar nodules.

Heart and Pericardium.—Normal.

Trachea.—Normal.

Abdomen.

Omentum.—The omentum contained two miliary caseous tubercles and fairly numerous minute translucent grey tubercles.

Peritoneum, Mesentery, and Meso-colon.—Normal.

Spleen.—The spleen was enlarged, measuring 6 by 3 by 1·5 cm., and was closely beset with yellow softened caseous nodules ranging up to 3·5 mm. in diameter; the nodules were in places so closely crowded together as to be facetted by their neighbours.

Splenic Gland.—One splenic lymphatic gland contained a caseous and softened nodule 3 mm. in diameter.

Liver.—The liver contained scattered evenly-distributed opaque whitish or yellowish-white tubercles, ranging up to 1 mm. in diameter.

The glands on the head of the pancreas were enlarged and their cortices almost completely replaced by softened caseous nodules. The gland near the pylorus contained two millet-seed sized caseous tubercles.

Kidneys.—Normal.

Suprarenal Bodies.—Normal.

Iliac Glands.—One iliac gland contained a softened caseous nodule 2 mm. in diameter.

Lumbar Glands.—Two lumbar glands contained three similar nodules.

Alimentary Tract.

Tongue, Pharynx, Tonsils.—Normal.

Submaxillary Glands.—Two submaxillary glands on the left side contained three softened caseous tubercles; two on the right side each contained a pinhead-sized tubercle.

Retro-pharyngeal Glands.—Normal.

Intestines.—Normal.

Mesenteric, Ileo-Colic, and Colic Glands.—Normal.

Brain.—Normal.

Microscopical Examination.

Tubercle from Lung.—Tubercle bacilli in moderate numbers.

Tubercle from Liver.—Tubercle bacilli moderately numerous.

Tubercle from Spleen.—Tubercle bacilli moderately numerous.

RHESUS MONKEY 197. Virus H. 109. "M.W."

(A young animal.)

Subcutaneous inoculation of culture derived from the original material through Guinea-pig 3002.

Dose—1·0 milligramme.

Date of Inoculation—July 27, 1908.

Died—August 26, 1908. [30 days after inoculation.]

Clinical Notes.

At the close of the third week after inoculation the monkey lost appetite and became thin and ill-looking; weakness and emaciation followed, and the animal sank and died on the 30th day after inoculation. The weight at death was 1070 grammes.

POST-MORTEM EXAMINATION.

The carcass was emaciated.

Local Lesion.—The skin over the right scapula showed a large irregular ulcer measuring 4 by 3 cm. with thin bluish considerably undermined margins and caseous floor, the muscles being infiltrated to a slight extent; the margins of the ulcer beneath the skin were caseous.

Axillary Glands.—On the right side three were enlarged (up to 1 cm.) caseous and softened throughout; one was partly caseous, and another contained a small tubercle.

On the left side one about 8 mm. in diameter was caseous almost throughout, the rest were normal.

Cervical Glands.—One on the left side behind the clavicle contained a softened caseous nodule; behind the clavicle on the right side there were two large glands filled with creamy caseo-pus. The right midcervical gland contained a few discrete caseous tubercles.

Vertebral Glands.—The glands on the right side in the sixth to the ninth interspaces were enlarged and filled with creamy pus. On the left side two in the sixth and seventh interspaces contained each a miliary caseous tubercle.

Thorax.

Lungs.—The lungs were crepitant and collapsed normally; the right caudal lobe was adherent to the enlarged vertebral glands. In the lung parenchyma there were seen just under the pleura altogether about half a dozen grey translucent tubercles varying up to 1 mm. in diameter; one or two similar tubercles were seen in the depth.

Thoracic Glands.—The bronchial glands were slightly enlarged. The praetrachco-bronchial glands showed caseous tubercles in the cortex becoming confluent.

One of the intertracheo-bronchial glands was caseous practically throughout; the other resembled the praetracheo-bronchials.

On the left side of the trachea, just within the thorax, there were two large glands filled with creamy pus; the gland on the opposite side contained two pinhead-sized caseous tubercles.

Heart Muscle and Valves.—Normal.

The pericardial sac was distended with fluid.

Pleura.—Normal.

Trachea.—Normal.

Abdomen.

Omentum.—The omentum contained one pinhead-sized greyish-white tubercle and one or two white pearly tubercles.

There was one pinhead-sized caseous tubercle on the meso-colon.

Peritoneum.—Normal.

Liver.—The liver was pale and closely beset with opaque greyish or greyish-yellow tubercles ranging in size from a mere point up to 1· mm.

The gland on the head of the pancreas near the hilum of the liver was moderately large and showed the cortical substance extensively replaced by yellowish-white breaking-down nodules.

Spleen.—The spleen was perhaps slightly enlarged, measuring 4·8 by 2 by 1 cm. The pulp was closely beset with soft caseous tubercles ranging from about 0·5 to 1·5 mm. in diameter.

Kidneys.—In the cortex of the left kidney just under the capsule there was one caseous tubercle less than 1· mm. in diameter. In the cortex of the right, near the surface, there were two minute greyish-white tubercles, and in the depth two rather larger yellow tubercles.

Suprarenal Bodies.—Normal.

The Iliac and Lumbar Glands contained a few miliary caseous tubercles.

In the gastro-splenic omentum along the hilum of the spleen there were several small glands, each of which contained one or two small caseous tubercles.

Alimentary Tract.

Tongue, Tonsils, Pharynx.—Normal.

The Submaxillary and Retro-pharyngeal Glands were beset with miliary caseous tubercles.

Intestines.—Normal.

Mesenteric Glands.—The mesenteric glands were normal in size and contained altogether four caseous tubercles, the largest the size of a pin's head.

Ileo-Colic and Colic Glands.—Normal.

Brain.—Normal.

Inguinal Glands.—The inguinal glands were slightly enlarged and showed in the cortices discrete soft whitish tubercles up to 1 mm. in diameter.

Microscopical Examination.

Smear from Iliac Gland.—Very numerous tubercle bacilli, the majority long and beaded.

Smear from Liver.—Very numerous tubercle bacilli, the majority long and beaded.

GOAT 61. Virus H. 109. "M.W."

(Adult female.)

Subcutaneous inoculation of culture derived from the original material through Guinea-pig 3002.

Dose—1·0 milligramme.

Date of Inoculation—July 27, 1908.

Killed when in good health—February 9, 1909. [197 days after inoculation.]

ABSTRACT OF POST-MORTEM NOTES.

[For details *see* the "Report on the Excretion of Tubercle Bacilli in Milk."]

At the seat of inoculation there were three hemp-seed sized caseo-purulent nodules with fibrous walls; the adjacent prescapular gland and all other lymphatic glands and the organs were normal.

VIRUS H. 110. "J.B." (*a*).

AND

VIRUS H. 110. "J.B." (*b*).

LUPUS.

VIRUS H. 110. "J.B." (*a*).

CULTURE INOCULATIONS

I.—June 12, 1908.

The strain was derived from the original material through Guinea-pig 3007, and had been in artificial cultivation a total period of 59 days.

The culture used was the 5th generation, 13 days old.

RHESUS MONKEY 183.
Subcutaneous.
Dose : 1·0 mg.
Died : July 12, 1908.
30 days.
P.M. — General tuberculosis.

RHESUS MONKEY 181.
Subcutaneous.
Dose : 0·1 mg.
Died : July 8, 1908.
26 days.
P.M. — Acute general tuberculosis.

RHESUS MONKEY 179.
Subcutaneous.
Dose : 0·01 mg.
Died : August 4, 1908.
53 days.
P.M. — General tuberculosis.

GUINEA-PIGS.

Number.	Method.	Dose.	Duration of Life.	Result.
3119	Intrap.	1·0 mg.	D. 21 days	G. T.
3117	Intrap.	0·1 mg.	D. 17 „	Acute G. T.
3120	Subcut.	1·0 mg.	D. 35 „	G. T. severe.
3118	Subcut.	0·1 mg.	D. 69 „	G. T. severe.

RABBITS.

Number.	Method.	Dose.	Duration of Life.	Result.
1904	Intrav.	1·0 mg.	D. 17 days	Acute miliary T.
1905	Intrav.	0·1 mg.	D. 21 „	G. T.
1906	Intrav.	0·01 mg.	D. 32 „	G. T.
1907	Intrav.	0·01 mg.	D. 32 „	G. T.
1908	Subcut.	8·0 mg.	D. 61 „	G. T.
1909	Subcut.	10·0 mg.	D. 59 „	G. T.

VIRUS H. 110. "J.B." (*a*)—*continued.*

CULTURE INOCULATIONS—*continued.*

II.—July 21, 1908.

(*a*)

The strain was derived from the original material through Guinea-pig 3006, and had been in artificial cultivation a total period of 90 days.

The culture used was the 8th generation, 15 days old.

RABBITS.

Number.	Method.	Dose.	Duration of Life.	Result.
1934	Subcut.	5·0 mg.	D. 41 days	G. T.
1935	Subcut.	1·0 mg.	D. 44 „	G. T.

CALF 1483.

Subcutaneous.

Dose: 50·0 mg.

Died: August 30, 1908.

40 days.

P.M. — General tuberculosis.

(*b*)

The strain was derived from the original material through Guinea-pig 3007, and had been in artificial cultivation a total period of 98 days.

The culture used was the 8th generation, 8 days old.

RABBITS.

Number.	Method.	Dose.	Duration of Life.	Result.
1932	Subcut.	33·0 mg.	D. 30 days	G. T.
1933	Subcut.	10·0 mg.	D. 53 „	G. T.

CALF 1491.

Subcutaneous.

Dose: 50·0 mg.

Died: August 7, 1908.

17 days.

P.M.—Acute general tuberculosis.

VIRUS H. 110. "J.B." (*a*)—*continued.*

FEEDING EXPERIMENTS.

I.

SEPTEMBER 19–OCTOBER 1, 1908.

The strain was derived from the original material through Guinea-pig 3007, and had been 158–170 days in artificial cultivation.

The cultures used were of the 12th to 14th generations, 4 to 9 days old.

PIG 129.

Fed on alternate days for a fortnight, seven times in all.

Dose: The growth from one serum tube on each occasion.

Killed: January 8, 1909.

111 days.

P.M.—Slight retrogressive general tuberculosis.

PIG 131.

Fed on alternate days for a fortnight, seven times in all.

Dose: The growth from one serum tube on each occasion.

Killed: February 11, 1909.

145 days.

P.M.—Slight disseminated tuberculosis.

II.

NOVEMBER 12, 1908.

The strain was derived from the original material through Guinea-pig 3007, and had been 212 days in artificial cultivation.

The culture used was the 18th generation, 10 days old.

RHESUS MONKEY 253.

Fed once.

Dose: 10·0 mg.

Died: December 12, 1908.

30 days.

P.M.—There were numerous small and inconspicuous ulcers in the first part of the small intestine which showed no sign of caseation. The mesenteric glands were much enlarged and caseo-purulent. The spleen and liver showed scattered miliary or submiliary tubercles, the majority grey. Other organs and glands were normal.

CALF 1483. Virus H. 110. "J B." (*a*).

Subcutaneous inoculation of culture derived from the original material through Guinea-pig 3006.

Dose—50·0 milligrammes.

Date of Inoculation—July 21, 1908. [Age about 9 weeks.]

Died—August 30, 1908. [40 days after inoculation.]

Clinical Notes.

The course of the disease was similar to that usually seen in calves inoculated with a virulent virus.

Temperature.

On the third day the temperature rose to 40·1° C. and remained high for 31 days (maximum 40·9° C.); during the last week of life the temperature fell from 40·5° C. to 38·4° C.

Weights.

	qrs.	lbs.
July 21, 1908	3	24
August 30, 1908	2	22

Total loss of weight.—1 qr. 2 lbs.

POST-MORTEM EXAMINATION.

The carcass was emaciated.

Local Lesion.—At the seat of inoculation on the left side of the neck there was a firm tumour measuring 14·5 by 10 by 4 cm., the skin over which was necrosed and ulcerated; on section it was composed of dense caseous substance which contained an irregular cavity filled with necrosed caseous masses; the muscles were infiltrated often to a considerable depth with caseous nodules; the skin where not necrosed showed caseous tubercles.

The lesion was connected to the prescapular gland by a thick caseous cord, and the muscles around the lower extremity of the gland were infiltrated and adherent.

Left Prescapular Gland.—The left prescapular gland measured 8·5 by 5 by 4 cm., and was composed throughout of dense pinkish yellow caseous substance showing early calcification.

Prepectoral Glands.—On the left side one 1·2 cm. in diameter was dense and caseous throughout; two others contained caseous nodules and tubercles.

A prepectoral gland on the right side contained caseous nodules.

Right Prescapular Gland.—The right prescapular gland measured 4·5 by 2 by 0·9 cm. and contained numerous caseous nodules up to a hemp seed in size.

Cervical Glands.—One of the lower cervical glands on the left side was much enlarged and caseating throughout, but not so advanced as the prescapular; the other cervical glands were enlarged and beset with caseating nodules, in many aggregated together.

Thorax.

The pleural cavities contained each a small quantity of yellow serous fluid.

Pleura.—The fringes along the margins of the ribs were in places congested and slightly hypertrophied and contained flattened caseous nodules.

On the pleural surface of the diaphragm there were several congested villous patches containing miliary caseous tubercles.

Lungs.—The lungs were slightly adherent to the sternum and to the pericardium; they were deeply congested, the anterior lobes were extensively hepatised and the caudal lobes were mottled with small red areas. They weighed 4 lbs. 3 ozs.; the parenchyma was closely and evenly beset with caseous tubercles varying in diameter from 1 to 3 mm.; many of the larger ones showed like those in the spleen an opaque central focus.

Thoracic Glands.—The bronchial and mediastinal glands were much enlarged; their cortices were composed of firm greyish-red translucent tissue closely mottled with small irregular yellow caseous areas forming in places a coarse network.

Trachea.—The tracheal mucous membrane showed numerous congested slightly raised caseous areas.

Heart.—In the muscle wall of the right auricle there were two caseous nodules up to a hemp seed in size, and two smaller ones in the wall of the left ventricle. The endocardium was normal.

Abdomen.

Omentum.—The omentum showed on the ventral surface numerous firm yellow congested caseous nodules varying from 1 to 5 or 6 mm. in diameter; the larger ones were lenticular and loosely attached.

Peritoneum.—Normal.

Spleen.—The spleen was greatly enlarged (weight 1 lb. 6 ozs.); the capsular vessels were dilated and engorged with blood; the pulp was firm, and packed almost as closely as possible with firm yellow caseous nodules up to 3 mm. in diameter; every one of the nodules had in the centre an opaque yellowish focus, which was in some cases perceptibly gritty.

Liver.—The liver substance was closely beset with tubercles ranging in size from a mere point up to that of a millet seed; the smaller ones were greyish-white, the larger ones were yellow, and had in the centre opaque foci ? of beginning calcification; several of the subcapsular tubercles were much flattened out.

Portal Glands.—The portal glands were much enlarged, and their cortices composed of firm translucent grey tissue, closely beset with small yellow caseous areas.

Coeliac Glands.—The coeliac glands resembled the portal.

Kidneys.—In the cortex of each kidney, on the surface as well as in the depth, there were fairly numerous yellow caseous tubercles with narrow grey margins up to a millet seed in size; there were a few small tubercles in the medullary zones.

Suprarenal Bodies.—Each suprarenal showed in the cortex two greyish yellow miliary tubercles.

Alimentary Tract.

Tongue.—There was a small ulcer with a caseous floor at the base of the tongue.

Tonsils and Pharynx.—There were a few caseous nodules in each tonsil, and a number in the corrugated mucous membrane in the vault of the pharynx.

The Retro-pharyngeal and Submaxillary Glands were very closely beset with caseous nodules.

Intestines.—A few Peyer's patches contained caseous tubercles, and there were several submucous tubercles in the early part of the duodenum.

There were no tubercles in the large intestine.

Mesenteric, Ileo-Colic, and Colic Glands.—The mesenteric glands contained caseous nodules, numerous in some, sparsely scattered in others.

The ileo-colic and colic glands were similar.

Testicles.—One testicle contained a hempseed-sized caseous nodule.

Eyes.—On the palpebral conjunctiva in each eye there were two or three caseous nodules the surface of which was ulcerated. The eyes themselves were normal.

Various Lymphatic Glands.

All the peripheral lymphatic glands were enlarged and contained numerous yellow caseous nodules varying in size up to about 3 mm.; in many of the glands the nodules were collected together into groups; the larger ones showed in the centre opaque foci similar to those in the spleen nodules.

Hæmolymph Glands.—Practically all the hæmolymph glands contained caseous tubercles.

CALF 1491. Virus H. 110 "J.B." (*a*).

Subcutaneous inoculation of culture derived from the original material through Guinea-pig 3007.

Dose—50·0 milligrammes.

Date of Inoculation—July 21, 1908. [Age about 9 weeks.]

Died—August 7, 1908. [17 days after inoculation.]

Clinical Notes.

The calf quickly became ill and thin: the respiration increased in frequency, finally becoming laboured and difficult, and the calf died on the seventeenth day.

Temperature.

The temperature rose on the second day, and reached a maximum (41·1° C.) on the tenth day: it remained high until the day of death, when a low temperature (38·2° C.) was recorded.

Weights.

	qrs.	lbs.
July 21, 1908	3	21
August 7, 1908	3	4

Total loss of weight.—17 lbs.

POST-MORTEM EXAMINATION.

The carcass was thin.

Local Lesion.—At the seat of inoculation on the left side of the neck there was a slightly raised ill-defined tumour measuring 7 by 5 by 2 cm.; on section it was composed of caseo-necrotic substance honeycombed with cavities filled with serous fluid; the skin and muscles were adherent and infiltrated.

Left Prescapular Gland.—The left prescapular gland measured 7·3 by 4·5 by 2·7 cm. and was dense yellow and caseating practically throughout.

Right Prescapular Gland.—The right prescapular gland measured 3·9 by 1·8 by rather less than 1 cm. and showed in the cortex scattered congested grey tubercles.

Prepectoral Glands.—On the left side one was 1·5 cm. in diameter and was caseous throughout; the rest appeared normal.

On the right side one contained a minute grey tubercle.

Cervical Glands.—On the left side one of the lower cervicals was enlarged firm congested and showed the substance closely beset with minute caseous foci. Several other glands on the left side were enlarged oedematous and showed patches of minute greyish-white tubercles.

On the right side the upper cervical gland contained minute discrete tubercles; none was seen in the others.

Thorax.

Pleura.—Normal.

Lungs.—The lungs weighed 4 lbs. 4 ozs. They were dark red and consolidated throughout with the exception of the posterior tips and the posterior parts of the dorsal borders of the caudal lobes which were still air containing; the parenchyma of the lungs was very closely peppered with minute grey tubercles.

Thoracic Glands.—The dorsal mediastinal and bronchial glands were moderately large, their cortices were firm reddish grey and infiltrated with a fine caseous network.

Heart.—On the endocardium of the right auricle and right ventricle there were numerous small pearly-white raised tubercles. The heart was otherwise normal.

Abdomen.

Omentum.—The omentum showed numerous submiliary grey translucent tubercles.

Peritoneum.—Normal.

Spleen.—The spleen was slightly enlarged; on section the pulp was dark red and coarsely granular, due to enlargement of the Malpighian bodies; close inspection showed numerous minute grey foci, not only in the pulp between the Malpighian bodies, but also in the Malpighian bodies themselves.

Liver.—The liver was paler than normal, and closely and evenly beset with minute grey translucent tubercles, the largest not more than 0·5 mm. in diameter.

Portal Glands.—The portal glands were slightly enlarged, very oedematous, and showed in the cortices early grey translucent patches with minute caseous foci.

Kidneys.—Both kidneys showed on the surface scattered minute grey tubercles; similar foci were seen in the depth of the cortex.

Suprarenal Bodies.—No tubercles were seen in the suprarenal bodies.

The Lumbar and Renal Glands contained numerous submiliary grey translucent tubercles.

Alimentary Tract.

Tongue, Pharynx, Tonsils.—Normal.

Retro-pharyngeal Glands.—The retro-pharyngeal glands showed fairly numerous minute congested grey tubercles, and there were a few in the submaxillary and parotideal glands.

Intestines.—The mucous membrane was congested; no tubercles were seen.

Mesenteric and Colic Glands.—The mesenteric and colic glands contained tubercles similar to those in the peripheral glands (see below).

Mammary Gland.—Normal.

Various Peripheral Glands.

Precrural, Popliteal, Axillary, Gluteal, Ischiatic, Pudic.—All showed in the cortices fairly numerous submiliary grey translucent tubercles (some greyish-white), which stood up from the cut surface.

Microscopical Examination.

(Smears from)

Lung.—Tubercle bacilli numerous.

Liver.—Tubercle bacilli scanty.

Spleen.—Tubercle bacilli in moderate numbers.

RHESUS MONKEY 183. Virus H. 110. "J.B." (*a*).

(A young animal.)

Subcutaneous inoculation of culture derived from the original material through Guinea-pig 3007.

Dose—1·0 milligramme.

Date of Inoculation—June 12, 1908.

Died—July 12, 1908. [30 days after inoculation.]

Clinical Notes.

The monkey remained well to all appearances for three weeks after the inoculation; it then began to lose appetite and energy and became progressively weaker and very thin: death ensued on the 30th day.

Weight at death 1080 grammes.

POST-MORTEM EXAMINATION.

The carcass was emaciated.

Local Lesion.—On the right scapula there was a slightly raised area, the skin over which showed several small openings discharging ill-formed pus. These openings communicated with a flat space in the subcutaneous tissues, lined with caseous substance: the muscles beneath this space were for some distance around infiltrated with yellow caseous deposit, the infiltrated muscles measuring in one direction 5 cm.

Axillary Glands.—On the right side there were five enlarged glands varying in size up to 1·5 cm. all of which were caseous and softened throughout.

On the left side one the size of a pea was partly caseous, two others each contained a small caseous nodule.

Cervical Glands.—Two glands behind the right clavicle, one 1 cm. in diameter, the other a little smaller, were caseous and softened throughout.

Behind the left clavicle there were three caseous and softened glands, the largest the size of a pea.

Vertebral Glands.—On the right side in the 2nd to the 6th interspaces there was a series of six glands (two opposite the sixth interspace) varying in size from a hemp seed to a pea, all caseous and softened throughout. Other vertebral glands were normal.

Thorax.

Pleura.—The pleura near the two glands opposite the sixth interspace showed an eruption of caseous tubercles.

Lungs. — The lungs were pink and crepitant throughout; the apex of the right caudal lobe was adherent to the enlarged vertebral glands. The lung parenchyma contained four caseous shotty tubercles, the largest the size of a millet seed.

Bronchial Glands. — The bronchial glands were slightly enlarged and contained yellow caseous tubercles.

Heart and Pericardium.—Normal.

Abdomen.

There was no fluid in the peritoneal cavity.

Omentum.—The omentum showed one pinhead-sized caseous tubercle near the pylorus, and a moderate number of exceedingly minute early grey tubercles.

Peritoneum.—The parietal peritoneum was normal.

Spleen.—The spleen was slightly enlarged, measuring 4·5 by 2·5 by 1 cm. and was closely beset with yellowish-white caseous tubercles, varying in size from rather less than 0·5 to 2 mm. in diameter.

Splenic Glands.—Three splenic lymphatic glands contained each three or four miliary caseous tubercles.

Liver.—The liver was closely beset with opaque greyish-white tubercles (the larger ones slightly yellowish) ranging in size from a mere point up to rather more than 1 mm. in diameter.

Pancreatic Glands.—Two glands on the anterior border of the pancreas were enlarged and showed their cortices extensively replaced by yellow caseous coalescing nodules.

Kidneys.—The left kidney showed on the surface sixteen tubercles varying from a mere point to a millet seed in size, the smaller ones greyish-white, the larger ones yellow and caseous; a few minute tubercles were seen in the depth of the cortex.

There were about the same number of similar tubercles in the cortex of the right kidney.

Suprarenal Bodies.—Normal.

Lumbar and Iliac Glands.—The lumbar and iliac glands contained discrete caseous tubercles.

Alimentary Tract.

Tongue, Pharynx, Tonsils.—Normal.

Pharyngeal Glands.—Each pharyngeal gland contained one or two caseous tubercles.

Submaxillary Glands.—The submaxillary glands contained discrete caseous tubercles.

Intestines.—A Peyer's patch in the ileum contained a pinhead-sized caseous tubercle, and in the jejunum there were two submucous miliary caseous tubercles. The large intestine was normal.

Mesenteric Glands.—The mesenteric glands contained scattered discrete caseous tubercles.

Ileo-Colic and Colic Glands.—One ileo-colic gland contained a pinhead-sized caseous tubercle, and four colic glands each contained one miliary caseous tubercle.

Brain.—Normal.

Inguinal Glands.—An inguinal gland on each side contained several discrete miliary caseous tubercles.

RHESUS MONKEY 181. Virus H. 110. "J.B." (*a*).

(A young animal.)

Subcutaneous inoculation of culture derived from the original material through Guinea-pig 3007.

Dose—0·1 milligramme.

Date of Inoculation—June 12, 1908.

Died—July 8, 1908. [26 days after inoculation.]

Clinical Notes.

The monkey became ill during the third week after inoculation; the respiration was increased in frequency, the appetite poor; weakness and emaciation followed and the monkey died on the 26th day after inoculation.

The weight at death was 1010 grammes.

POST-MORTEM EXAMINATION.

The carcass was emaciated.

Local Lesion.—Over the right scapula there was a prominent fluctuating swelling measuring 4 by 2·5 by 1·5 cm., the skin over the centre of which was red and thinned; on section it showed in the centre reddish pus, and around the margins moderately firm yellow caseous substance.

Axillary Glands.—On the right side one 9 mm. in greatest diameter was yellow and caseous practically throughout. Another contained a caseous tubercle 2 mm. in greatest diameter. The others were congested, but otherwise normal.

The glands on the left side contained three caseous tubercles.

Cervical Glands.—Behind the right clavicle there were four enlarged glands; one the size of a small pea was caseous and softened throughout; one smaller and two larger ones showed discrete caseous tubercles in the cortex.

Other cervical glands appeared normal.

Vertebral Glands.—One vertebral gland on the right side in the fifth interspace was slightly enlarged and caseous throughout. The others were normal.

Thorax.

Lungs.—The left lung was red and collapsed and almost entirely airless, pieces of the collapsed portions sinking in water.

The right lung was crepitant.

Both lungs contained scattered evenly distributed greyish opaque tubercles up to a pin's head in size.

Bronchial Glands.—The bronchial glands were not enlarged; each contained two or three small greyish-white tubercles.

Heart.—Normal.

Pleura.—Normal.

Abdomen.

Omentum and Peritoneum.—There were a few minute greyish-white tubercles in the omentum. The parietal peritoneum and the mesentery were normal. The meso-colon showed one pinhead-sized greyish-white tubercle.

Spleen.—The spleen was enlarged, and measured 4·5 by 2 by 1·4 cm., and was closely beset with yellow caseous softening tubercles, ranging from about 0·5 mm. to 2 mm. in diameter.

Splenic Lymphatic Glands.—The splenic glands were not enlarged; they contained each two or three pinhead-sized caseous and softened tubercles.

A gland in the small omentum near the pylorus, the size of a split pea showed the cortex extensively replaced by yellowish caseous tubercles.

The gland on the head of the pancreas was enlarged and the cortex was closely beset with coalescing caseous tubercles up to 2 mm. in diameter.

Liver.—The liver was paler than normal, and was closely and evenly beset with opaque greyish-white tubercles ranging in size from a mere point up to a little more than 1 mm. in diameter.

Kidneys.—Each kidney showed in the cortex a few greyish-white tubercles, the largest the size of a pin's head.

Suprarenal Bodies.—Normal.

Lumbar Glands.—There were two minute whitish tubercles in the lumbar glands.

Alimentary Tract.

Tongue, Tonsils, and Pharynx.—Normal.

Pharyngeal and Submaxillary Glands.—Each pharyngeal gland contained a caseous and softened tubercle the size of a pin's head, and there was a minute caseous tubercle in each submaxillary gland.

Intestines.—A Peyer's patch in the ileum contained a small caseous tubercle; otherwise the intestines were normal.

Mesenteric Glands.—There were altogether about half a dozen caseous tubercles up to a millet seed in size in the mesenteric glands.

There was one minute focus in an ileo-colic gland.

The colic glands were normal.

One rectal gland contained a miliary caseous tubercle.

Inguinal Glands.—The inguinal glands were not enlarged; they contained a few soft whitish tubercles.

Larynx and Trachea.—Normal.

Brain.—Normal.

Microscopical Examination.

Caseous Tubercle from Ileum.—Tubercle bacilli moderately numerous.

Tubercle from Submaxillary Gland.—Tubercle bacilli numerous.

RHESUS MONKEY 179. Virus H. 110. "J.B." (*a*).

(A young animal.)

Subcutaneous inoculation of culture derived from the original material through Guinea-pig 3007.

Dose—0·01 milligramme.

Date of Inoculation—June 12, 1908.

Died—August 4, 1908. [53 days after inoculation.]

Clinical Notes.

The course of the disease was similar to that seen in Monkeys 183 and 181 inoculated with this virus.

The weight at death was 1820 grammes.

POST-MORTEM EXAMINATION.

The carcass was emaciated.

Local Lesion.—In the subcutaneous tissues over the right scapula there was a yellow caseous patch measuring 3 by 2·5 by 7 cm. beginning to soften in the centre, the skin over the centre of which was thin reddened and ulcerating.

Axillary Glands.—One on the right side 9 mm. in greatest diameter was partly caseous. Two others contained discrete caseous tubercles.

On the left side, one the size of a large pea showed about half its substance caseous; the rest were congested and perhaps a little enlarged, but contained no tubercles.

Cervical Glands.—On the right side one behind the clavicle the size of a large pea was caseous through-

out, another contained a millet-seed sized caseous tubercle.

On the left side one showed most of the cortex caseous : two others contained each a caseous tubercle.

Vertebral Glands.—On each side in the 8th to 10th interspaces the glands were slightly enlarged and contained each one or two small caseous tubercles.

Thorax.

There was a quantity of blood-stained fluid in each pleural cavity.

Pleura.—Along the margins of some of the ribs there were small patches of reddish tissue beset with grey tubercles.

Lungs.—The lungs were expanded and emphysematous and contained numerous evenly distributed caseous tubercles with grey margins, the largest the size of a millet seed softened and more caseous than the smaller ones. There were patches of congestion but none of consolidation.

Bronchial Glands.—The bronchial glands were enlarged, congested, and contained each a number of discrete caseous tubercles up to a millet seed in size.

Heart and Pericardium.—The heart muscles were mottled with haemorrhages ; no tubercles were seen. There was an excess of fluid in the pericardial sac.

Abdomen.

The peritoneal cavity was filled with clear yellow serous fluid.

Omentum and Peritoneum.—The omentum showed numerous early grey tubercles ; and there were a few minute grey tubercles on the meso-colon.

Spleen.—The spleen was greatly enlarged measuring 6·5 by 4 by 2 cm. and was closely beset with yellow caseous and softened nodules varying in diameter from 1 to 4 mm.

Splenic Glands.—The splenic lymphatic glands were slightly enlarged and deeply congested. Two contained each one pinhead-sized caseous tubercle.

Liver.—The liver was much enlarged pale and closely beset with submiliary greyish-white tubercles, and contained also moderately numerous caseous nodules ranging from a millet seed up to a hemp seed in size.

The Gastric and Pancreatic Glands were slightly enlarged and showed irregular caseous nodules up to 2 mm. in diameter in the cortex.

Kidneys.—The cortex of each kidney was closely beset with yellow caseous tubercles with grey margins, the largest rather more than a millimetre in diameter.

Suprarenal Bodies.—Normal.

Iliac and Lumbar Glands.—The lumbar glands contained a few caseous tubercles ; the iliac glands were congested but not otherwise abnormal.

Alimentary Tract.

Tongue.—There was a yellow focus in the lymphoid tissue at the base of the tongue.

Tonsils, Pharynx, and Larynx.—Normal.

Submaxillary Glands.—The left submaxillary gland contained a millet-seed sized caseous tubercle. The right was normal.

Pharyngeal Glands.—Normal.

Intestines.—Normal.

Mesenteric and Colic Glands.—One mesenteric gland showed early caseous patches in the cortex, and another a small caseous tubercle.

A few of the colic glands each contained a caseous tubercle.

Inguinal Glands.—Normal.

Brain.—Normal.

Microscopical Examination.

Focus from Tongue.—A few tubercle bacilli.

RHESUS MONKEY 253. Virus H. 110. "J.B." (*a*).

(A young animal.)

Fed once (by means of a stomach tube) with culture derived from the original material through Guinea-pig 3007.

Dose—10·0 milligrammes.

Date of Inoculation—November 12, 1908.

Died—December 12, 1908. [30 days after inoculation.]

Clinical Notes.

The monkey's illness lasted a week, the symptoms being loss of flesh and weakness. It ate well during the whole period of the experiment, and was fairly active until the day it died (December 12) when weakness prevented it from climbing to its accustomed perch. The weight at death was 1500 grammes.

POST-MORTEM EXAMINATION.

The carcass was emaciated.

Alimentary Tract.

Tongue, Tonsils, Pharynx.—Normal.

Submaxillary, Pharyngeal and Cervical Glands.—Normal.

Stomach.—The stomach appeared normal.

Intestines.—The mucous membrane of the first part of the intestine, *i.e.*, that of the duodenum and jejunum, showed numerous small ulcers, the largest of which was not more than 2 mm. in diameter ; a few of the ulcers were star-shaped in outline but the majority were merely fine linear transverse fissures clearly seen only on stretching the mucous membrane ; in the ileum the ulcers gradually diminished in numbers, the latter portions not containing any.

There was no thickening of the bases of the ulcers and no sign of caseation around the margins.

The large intestines were normal.

Gastric Glands.—The gastric glands and a few smal glands along the first part of the duodenum were normal.

Mesenteric Glands.—All the mesenteric glands with the exception of the most posterior one were enlarged to two or three times their normal size and showed the cortices almost completely replaced by yellow caseo-purulent substance ; the terminal mesenteric gland was slightly enlarged and showed caseous foci in the cortex.

Ileo-Colic and Colic Glands.—Appeared normal to the naked eye.

Thorax.

Pleura, Lungs, Bronchial Glands, Heart.—Normal.

Abdomen.

Omentum and Peritoneum.—Normal.

Spleen.—The spleen was normal in size and showed in the pulp scattered tubercles varying in diameter up to a little more than 1 mm.; the larger ones were yellowish and the smaller ones greyish in colour.

Splenic Lymphatic Glands.—Normal.

Liver.—The liver was normal in size colour and texture; it showed sparsely scattered submiliary greyish-white tubercles.

Portal Glands and Glands around the Pancreas.—Normal.

Kidneys and Suprarenal Bodies.—Normal.

Axillary and Inguinal Glands.—Normal.

Microscopical Examination.

Smear from Spleen Pulp.—A moderate number of tubercle bacilli.

Smear from Mucous Membrane of Duodenum.—A few tubercle bacilli.

PIG 129. Virus H. 110. "J.B." (*a*).

Fed on alternate days for a fortnight—seven times in all—with culture derived from the original material through Guinea-pig 3007.

Dose—The pig received the growth from one serum tube on each occasion.

Date of Feeding—September 19—October 1, 1908. [Age 16 weeks.]

Killed when in good health—January 8, 1909. [111 days after feeding.]

Clinical Notes.

The pig remained well during the experiment, and increased considerably in weight and size.

Weights.

	cwt.	qrs.	lbs.
September 19, 1908	0	2	2
January 8, 1909	1	0	22

Total gain of weight.—2 qrs. 20 lbs.

Average rate of gain per week.—4·6 lbs.

POST-MORTEM EXAMINATION.

The carcass was in good condition.

Alimentary Tract.

Tongue, Pharynx, Tonsils.—Normal.

Submaxillary Glands.—On each side one near the submaxillary salivary gland was enlarged and its substance extensively replaced by caseous gritty masses which readily shelled out. On the left side near the large gland were two small ones which contained each a caseous nodule. On the right side there was one small gland with a pea-sized caseous nodule.

Between the angle and the articulation of the jaw on each side there was a slightly enlarged gland containing caseous nodules and tubercles.

Retro-pharyngeal Glands.—The one on the left side showed a miliary caseous tubercle, that on the right two caseous gritty nodules the size of hemp-seeds with grey margins.

Cervical Glands.—On the left side two of the glands in the anterior part of the neck contained each a group of three or four caseous nodules up to a pea in size; the lower cervical contained one hemp-seed sized caseous nodule.

On the right side one in the middle of the neck the size of a filbert was composed almost throughout of cheesy caseous substance slightly gritty from calcification.

Small Intestines.—The mucous membrane over every one of the Peyer's patches appeared thickened and was irregularly fissured, the fissures penetrating to the submucous tissue; this fissured or cracked appearance suggested the existence of previous ulceration. In the lymphoid tissue of each patch were scattered calcareous or caseous tubercles; they varied in number in the different patches and were most numerous in the long patch in the ileum; they could be felt between the finger and thumb and were best seen from the serous surface.

Scattered about on the serous surface of the ileum there were a few miliary caseo-calcareous tubercles.

Large Intestines.—Two small submucous tubercles were found in the colon.

Mesenteric Glands.—All the mesenteric glands were enlarged to three or four times their normal size and were, with only one or two exceptions, composed throughout of cheesy caseous substance slightly gritty from calcification; the exceptional glands, at the posterior extremity of the mesentery, contained discrete caseous tubercles.

Ileo-Colic Glands.—Some of the ileo-colic glands were caseous throughout; others contained discrete caseous tubercles and nodules.

Colic Glands.—A few colic glands were caseous throughout, others were partly caseous or contained caseous nodules. Some were normal.

Thorax.

Pleura.—Normal.

Lungs.—The lungs were crepitant and collapsed normally; they contained scattered nodules ranging from about 0·5 to 2·5 mm. in diameter, the majority varied however from 1 to 1·5 mm.; many were grey and translucent throughout, the rest had caseo-calcareous or calcareous centres. Thirty-seven were counted on the surface of the left and forty-three on that of the right.

Bronchial Glands.—The bronchial glands were not enlarged; the left contained one small caseous tubercle, the rest were normal.

Heart.—Normal.

Abdomen.

Omentum and Parietal Peritoneum.—Normal.

Spleen.—The spleen pulp contained one millet-seed sized calcareous tubercle with a fibrous margin.

Splenic Lymphatic Glands.—One in the hilum of the spleen was enlarged and contained a pea-sized caseous nodule.

Liver.—Scattered evenly throughout the liver substance was a moderate number of grey tubercles varying from 0·5 to 1·5 mm. in diameter; in the centre of each tubercle there was a minute calcareous focus.

Portal Glands.—The portal glands were not apparently enlarged ; one, the largest, contained three caseous gritty nodules up to 8 mm. in diameter and a number of discrete caseous tubercles ; two others contained scattered discrete caseous gritty nodules varying from 0·5 to 3 mm. in diameter.

Coeliac Glands.—One a centimetre in diameter was caseous throughout ; four others contained discrete caseous slightly gritty nodules up to 5 mm. in diameter and a few caseous tubercles.

Kidneys and Suprarenal Bodies.—Normal.

Renal Glands.—In one of the renal glands there was a pinhead-sized caseous gritty tubercle.

Lumbar and Iliac Glands.—Normal.

Precrural and Inguinal Glands.—Normal.

Ventral Mediastinal Glands.—In one there was a caseous tubercle, the others were normal.

Microscopical Examination.

Smear from a focus in the Small Intestine.—One tubercle bacillus seen.

PIG 131. Virus H. 110. "J.B." (*a*).

Fed on alternate days for a fortnight—seven times in all—with culture derived from the original material through Guinea-pig 3007.

Dose—The pig received the growth from one serum tube on each occasion.

Date of Feeding—September 19—October 1, 1908. [Age 16 weeks.]

Killed when in good health—February 11, 1909. [145 days after feeding.]

Clinical Notes.

The pig remained well during the experiment, and increased considerably in weight and size.

Weights.

	cwt.	qrs.	lbs.
September 19, 1908	0	1	15
February 11, 1909	1	1	10

Total gain of weight.—3 qrs. 23 lbs.

Average rate of gain per week.—5·1 lbs.

POST-MORTEM EXAMINATION.

The carcass was in good condition.

Alimentary Tract.

Tonsils.—In the substance of each tonsil there were about half a dozen caseo-calcareous tubercles ; the surface of the tonsil was normal.

Pharynx, Tongue.—Normal.

Submaxillary Glands.—On each side there were two slightly enlarged glands, which on section showed from a third to a half of their substance replaced by calcareo-caseous patches ; a small gland on the right side contained two irregular calcareo-caseous nodules, the largest the size of a hemp seed.

Retro-pharyngeal Glands.—The left retro-pharyngeal gland contained an irregular calcareous tubercle.

Cervical Glands.—Normal.

Intestines.—Normal.

Mesenteric Glands.—The mesenteric glands were only slightly enlarged. A few in the anterior part contained discrete irregular calcareo-caseous nodules up to 3 mm. or 4 mm. in diameter ; the rest were composed almost entirely of caseo-calcareous substance which could be readily shelled out ; some of the glands were uniformly caseo-calcareous, but the majority showed aggregated nodules, with a little patch here and there of normal-looking gland tissue.

Ileo-Colic Glands. — These were not so severely affected as the mesenteric ; they contained a varying number of irregular discrete calcareo-caseous nodules and tubercles, the largest gland containing only one tubercle.

Colic Glands.—Several colic glands were normal, but the majority contained discrete calcareous tubercles up to a millet seed in size.

Thorax.

Lungs.—The lungs were perfectly normal in general appearance ; three reddish-grey tubercles less than 1 mm. in diameter were seen under the pleura ; there was also a small nodule 3 mm. in diameter which was evidently of a parasitic origin ; no tubercle were seen on section.

Thoracic Glands, Pleura, Heart.—Normal.

Abdomen.

Peritoneum, Spleen, Kidneys and Suprarenal Bodies.—Normal.

Liver.—The liver showed on the surface, and evenly distributed throughout the substance, sparsely scattered grey translucent tubercles, the largest the size of a millet seed ; two of the tubercles had minute calcareous centres, the rest appeared homogeneous throughout.

Portal Glands.—The portal glands were not enlarged ; they contained altogether three calcareo-caseous nodules, the largest the size of a hemp seed.

Pancreatic Glands.—A gland lying on the head of the pancreas, not enlarged, was beset with irregular calcareous tubercles.

Coeliac Glands.—Two, not apparently enlarged, contained discrete irregular completely calcified tubercles, the largest the size of a millet seed.

Renal, Lumbar, and Iliac Glands.—Normal.

Microscopical Examinations.

Tubercle from the Tonsil.—One tubercle bacillus seen.

Smear from a Mesenteric Gland.—A few tubercle bacilli seen.

VIRUS H. 110. "J.B." (*b*).

CULTURE INOCULATIONS.

I.—December 17, 1908.

The strain was derived from the original material through Guinea-pig 3290, and had been 59 days in artificial cultivation.

The culture used was the 5th generation, 13 days old.

RABBITS.

Number.	Method.	Dose.	Duration of Life.	Result.
2087	Intrav.	1·0 mg.	D. 14 days	G. T.
2088	Intrav.	0·1 mg.	D. 20 „	General miliary T.
2089	Intrav.	0·01 mg.	D. 32 „	General miliary T.
2090	Subcut.	10·0 mg.	D. 35 „	G. T.
2091	Subcut.	10·0 mg.	D. 49 „	G. T.

GUINEA-PIGS.

Number.	Method.	Dose.	Duration of Life.	Result.
3395	Intrap.	0·1 mg.	D. 16 days	Acute T.
3396	Subcut.	0·1 mg.	D. 37 „	G. T.

CALF 1515.

Subcutaneous.

Dose: 50·0 mg.

Killed · January 20, 1908 (when dying).

34 days.

P.M.—General tuberculosis.

II.—February 2, 1909.

The strain was derived from the original material through Guinea-pig 3289, and had been 85 days in artificial cultivation.

The culture used was the 6th generation, 19 days old.

RABBITS.

Number.	Method.	Dose.	Duration of Life.	Result.
2143	Subcut.	50·0 mg.	D. 28 days	G. T.
2144	Subcut.	50·0 mg.	D. 25 „	G. T.
2141	Subcut.	10·0 mg.	D. 36 „	G. T.
2142	Subcut.	10·0 mg.	D. 30 „	G. T.

CALF 1515. Virus H. 110. "J.B." (*b*).

Subcutaneous inoculation of culture derived from the original material through Guinea-pig 3290.

Dose—50·0 milligrammes.

Date of Inoculation—December 17, 1908. [Age about 6 months.]

Killed when dying—January 20, 1909. [34 days after inoculation.]

Clinical Notes.

The course of the disease was similar to that usually seen in calves suffering from acute tuberculosis.

Temperature.

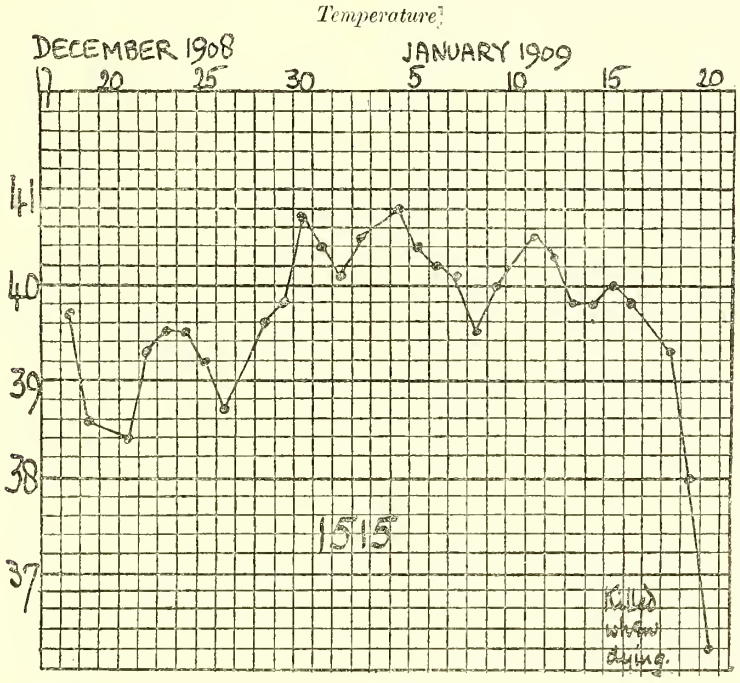

Weights.

	cwt.	qrs.	lbs.
December 17, 1908	1	3	5
January 20, 1909	1	1	19

Total loss of weight—1 qr. 14 lbs.

Average rate of loss per week.—8·4 lbs.

POST-MORTEM EXAMINATION.

The carcass was emaciated.

Local Lesion.—At the seat of inoculation on the left side of the neck there was a firm tumour measuring 14·5 by 10 by 4·5 cm. (with skin and infiltrated muscles). On section the tumour was mainly composed of a mass of pinkish-yellow caseo-necrotic substance breaking down in the centre; to this the skin and muscles were adherent, and both were closely infiltrated with yellow caseous tubercles.

Left Prescapular Gland.—The left prescapular gland was much enlarged measuring 11·5 by 6·5 by 4·5 cm. and was composed throughout of dense congested yellowish caseous substance; the capsule was thickened.

Attached to the lower extremity of the gland was a mass 5 cm. in greatest diameter which showed in the centre a caseous gland the size of a walnut and around the margins fibroid tissue beset with caseous nodules.

Right Prescapular Gland.—The right prescapular gland measured 3·7 by 2 by 1·4 cm. and showed in the cortex caseous nodules varying from 1 to 4 mm. in diameter.

Prepectoral Glands.—On the left side one the size of a thrush's egg was dense yellow and caseous throughout; two others contained discrete tubercles.

The glands on the right side contained each a few discrete caseous nodules.

Cervical Glands.—On the left side near the thorax there was a group of four glands, one the size of a pullet's egg, the largest of the others that of a thrush's; all were dense and caseous throughout resembling the prescapular.

The other glands on this side and all those on the right contained discrete caseous tubercles and nodules.

Thorax.

Pleura.—On the costal pleura there were a few patches of early 'perlsucht.'

Lungs.—The lungs were very large and almost completely filled the thorax; they weighed 7 lbs. 13 ozs.

The anterior lobes were red, firm, and quite airless, except along the dorsal margins, where there was still some crepitant lung tissue; the caudal lobes were mottled with irregular patches of consolidation most numerous in the anterior parts, the antero-ventral portion of the left caudal being extensively hepatised. The lung parenchyma was very closely beset with caseous tubercles with narrow grey margins, they varied very little in size, the majority being about 1 mm. in diameter; the surfaces of the consolidated lobes were closely studded with slightly raised tubercles of larger diameter than those in the depth and in places aggregated together.

Thoracic Glands.—The dorsal mediastinal and bronchial glands were much enlarged, together weighing 11 ozs.; their cortices were composed of firm grey tissue closely infiltrated with yellow caseous foci and small irregular caseous patches, the medullæ were congested and oedematous.

Just within the entrance to the thorax on the left side was a large firm gland 4 cm. in greatest diameter: on section it resembled the prescapular.

Heart.—Normal.

Abdomen.

Omentum.—The omentum showed on its ventral surface altogether about thirty caseating nodules varying up to 5 mm. in greatest diameter; the larger ones were lenticular in outline and loosely attached.

Parietal Peritoneum.—Normal.

Spleen.—The spleen was enlarged, weighing 13 ozs., and the pulp was closely beset with yellow caseous tubercles, the largest 2·5 mm. to 3 mm. in diameter.

Liver.—The liver seemed a little enlarged; the substance contained numerous evenly-distributed caseous tubercles, ranging from rather less than 1 mm. to 2 mm. in diameter; the majority were about 1 mm. in diameter.

Portal Glands.—These glands were much enlarged; their cortices were composed of firm grey tissue, chiefly in the form of nodular masses closely infiltrated with small irregular caseous areas; the medullae were very oedematous.

Gall-bladder.—There were eight caseous tubercles under the mucous membrane of the gall-bladder.

Kidneys.—In the cortex of each kidney, on the surface as well as in the depth, were fairly numerous caseous tubercles with grey margins, the largest 2 mm. in diameter.

Suprarenal Bodies.—In the cortex of the left there were two miliary caseating tubercles; there were two caseous tubercles in the cortex of the right.

Coeliac Glands.—The coeliac glands were enlarged, and their cortices were composed throughout of firm caseating tuberculous tissue.

The Lumbar and Renal Glands were enlarged and closely beset with caseous nodules, the largest 4 mm. in diameter.

Alimentary Tract.

Pharynx.—The mucous membrane of the vault of the pharynx showed one caseous nodule.

Tonsils.—There were four caseous nodules in the right and one in the left.

The Submaxillary, Retro-pharyngeal, and Parotideal Glands contained numerous caseous nodules, varying from 1 mm. to 3 mm.

Intestines.—All but one of the Peyer's patches in the small intestine contained from one to three caseous tubercles; the large patch showed scattered tubercles. The large intestine was normal.

Mesenteric Glands.—The mesenteric glands contained numerous caseous nodules, up to 3 mm. or more in diameter.

Testicles.—Normal.

Eyes.—Normal.

Larynx.—There were two small tubercles on the mucous membrane over the cricoid.

Trachea.—Normal.

Peripheral Lymphatic Glands.

All the peripheral glands contained numerous caseous nodules, varying from one to three and sometimes more millimetres in diameter.

All the haemolymph glands contained caseous nodules.

VIRUS H. 111. "S.E."

LUPUS.

VIRUS H. 111. "S.E."

CULTURE INOCULATIONS

I.—June 13, 1908.

The strain was derived from the original material through Guinea-pig 3009, and had been in artificial cultivation a total period of 51 days.

The culture used was the 5th generation, 14 days old.

MONKEY 189.

Subcutaneous.

Dose : 1·0 mg.

Died : August 14, 1908.

62 days.

P.M.—General tuberculosis, severe in spleen.

MONKEY 191.

Subcutaneous.

Dose : 0·1 mg.

Killed : February 10, 1909. (When well.)

242 days.

P.M.—Local tuberculosis ; slight tuberculosis of lungs and liver, moderately severe chronic tuberculosis of spleen ; one caseous nodule (1·5 cm.) in brain, and patch of caseo-necrosis in the left parietal bone of the skull.

GUINEA-PIGS.

Number.	Method.	Dose.	Duration of Life.	Result.
3125	Intrap.	1·0 mg.	D. 23 days	G. T.
3127	Intrap.	0·1 mg.	D. 79 „	G. T.
3126	Subcut.	1·0 mg.	D. 124 „	G. T.
3128	Subcut.	0·1 mg.	D. 100 „	G. T.

RABBITS.

Number.	Method.	Dose.	Duration of Life.	Result.
1916	Intrav.	1·0 mg.	D. 32 days	G. T.
1917	Intrav.	0·1 mg.	D. 26 „	G. T.
1920	Intrav.	0·01 mg.	D. 56 „	G. T.
1918	Subcut.	10·0 mg.	D. 136 „	Chronic slight G. T. ; death from other causes.
1919	Subcut.	8·0 mg.	K. 207 „	Very slight G. T.

VIRUS H. 111. "S.E."

CULTURE INOCULATIONS—*continued.*

II.—JULY 23, 1908.

The strain was derived from the original material through Guinea-pig 3009, and had been 91 days in artificial cultivation.

The culture used was the 9th generation, 10 days old.

CALF 1429.

Subcutaneous.

Dose : 50·0 mg.

Killed : October 29, 1908.

98 days.

P.M. — There was a thick-walled cyst containing breaking-down caseous substance at the seat of inoculation. The prescapular gland was composed also of breaking-down caseous substance in a fibrous capsule. The thoracic glands contained scattered calcareous grains ; three glands in the throat contained one or two caseous tubercles each.

CALF 1459.

Subcutaneous.

Dose : 50·0 mg.

Killed : October 23, 1908.
(When dying of urethral obstruction.)

92 days.

P.M.—There was a thin-walled cyst containing caseo-pus at the seat of inoculation. The left prescapular gland was three-parts occupied by softening caseo-necrotic substance. The thoracic and mesenteric glands contained scattered caseous tubercles. The portal glands contained three minute tubercles. Each suprarenal body contained 3 or 4 caseous gritty tubercles. In three Peyer's patches there were nearly a dozen small slightly gritty nodules.

RABBITS.

Number.	Method.	Dose.	Duration of Life.	Result.
1936	Subcut.	10·0 mg.	K. 167 days	Chronic G. T. not severe and not obviously progressive.
1937	Subcut.	2–3·0 mg.	D. 138 ,,	G. T.

CALF 1429. Virus H. 111. "S.E."

Subcutaneous inoculation of culture derived from the original material through Guinea-pig 3009.

Dose—50·0 milligrammes.

Date of Inoculation—July 23, 1908. [Age about 5 months.]

Killed when in good health—October 29, 1908. [98 days after inoculation.]

Clinical Notes.

The calf remained well during the experiment.

Temperature.

On the 12th day after inoculation the temperature rose to 40·7° C.; the next day it was 38·7° C.; and on the 18th day 41·3° C. During the following week the temperature ranged between 39·2 and 39·6° C.; subsequently it remained normal.

Weights.

	cwt.	qrs.	lbs.
July 23, 1908	1	2	1
October 29, 1908	2	0	8

Total gain of weight.—2 qrs. 7 lbs.

Average rate of gain per week.—4·5 lbs.

POST-MORTEM EXAMINATION.

The carcass was in good condition.

Local Lesion.—In the subcutaneous tissues on the left side of the neck there was a cyst measuring 9 by 8 by 5 cm. filled with breaking-down caseous substance; the wall was thick and fibrous and lined internally with granulation tissue; the capsule and skin at one part were thinned bulging and breaking-down.

Left Prescapular Gland.—The left prescapular gland measured 7 by 6 by 4 cm. and was soft and fluctuating. On section it was composed almost entirely of breaking- or broken-down caseous substance surrounded by a fibrous capsule; there was a small amount of normal gland tissue at one extremity of the gland.

Right Prescapular Gland.—The right prescapular gland measured 4 by 1·7 by 1 cm. and was normal on section.

Prepectoral Glands.—Normal.

Thorax.

Pleura and Heart.—Normal.

Lungs.—The lungs were normal except for two minute grey foci of a doubtful nature.

Thoracic Glands.—The bronchial and dorsal mediastinal glands were normal in size and showed in the cortices sparsely scattered yellow calcareous grains.

Abdomen.

Omentum and Peritoneum.—Normal.

Spleen, Liver, Kidneys, Suprarenal Bodies.—Normal.

Portal, Renal, Lumbar and Iliac Glands.—Normal.

Alimentary Tract.

Tongue, Pharynx, Palate, Tonsils.—Normal.

Submaxillary Glands.—The left submaxillary gland contained a pinhead-sized yellow caseous tubercle, the right was normal.

Retro-pharyngeal Glands.—There was a minute yellow caseous tubercle in the cortex of the right; in that of the left there was two yellow caseous nodules, one the size of a millet seed the other that of a hemp seed.

Intestines.—Normal.

Mesenteric Glands.—Normal.

Testicles.—Normal.

Various Lymphatic Glands.

Popliteal, Axillary, Gluteal and Ischiatic, Pudic.—Normal.

Precrural.—In the cortex of the right there was a small caseous tubercle; the left was normal.

CALF 1459. Virus H. 111. "S.E."

Subcutaneous inoculation of culture derived from the original material through Guinea-pig 3009.

Dose—50·0 milligrammes.

Date of Inoculation—July 23, 1908. [Age about 10 weeks.]

Killed when dying of urethral obstruction—October 23, 1908. [92 days after inoculation.]

Clinical Notes.

The health of the calf was good until the 22nd October when it suddenly became ill, refused food and seemed unable to rise from the ground; on the next day it was feebler and obviously dying; it was therefore killed.

The post-mortem examination showed the illness to be due to obstruction of the urethra caused probably by a renal calculus.

Temperature.

Seven days after inoculation the temperature rose to 39·8° C.; subsequently it was approximately normal, but irregular, for nearly three months (maximum 39·6° C., minimum 38·0° C.); during the last few days of life the temperature was high (about 40·0° C.).

Weights.

	cwt.	qrs.	lbs.
July 23, 1908	0	3	17
October 23, 1908	1	0	13

Total gain of weight.—24 lbs.

POST-MORTEM EXAMINATION.

The carcass was in good condition.

Local Lesion.—At the seat of inoculation on the left side of the neck there was a fluctuating swelling measuring 8·5 by 5·5 by 5 cm.; on section it was a cyst filled with thick caseo-pus; the wall was thin and fibrous and lined internally with granulation tissue, gritty from calcification.

Left Prescapular Gland.—The left prescapular gland measured 5·8 by 4·5 by 2·5 cm. and showed

more than three-quarters of its substance replaced by firm pinkish caseo-necrotic substance separated from the capsule of the gland by a layer of yellow caseo-pus.

Right Prescapular Gland.—The right prescapular gland measured 3·6 by 1·1 by 0·8 cm. and was normal on section.

Prepectoral Glands.—Normal.

Thorax.

Pleura, Lungs, Heart.—Normal.

Thoracic Glands.—The bronchial and dorsal mediastinal glands were normal in size; the long mediastinal gland contained a dozen or more yellow caseous tubercles and one calcareous focus; in the left bronchial gland there were two submiliary caseous tubercles and in two of the small dorsal mediastinal glands two or three caseous tubercles up to a millet seed in size were seen.

Abdomen.

Omentum and Peritoneum.—Normal.

Spleen, Liver.—Normal.

Portal Glands.—The portal glands contained three minute yellowish-white tubercles.

Kidneys.—The right kidney was enlarged and showed the cortex of most of the lobules congested and beset with irregular yellow foci up to 1 mm. in diameter; the cortex of the kidney was increased in thickness and the substance generally oedematous; the loose tissues around the calyces were very oedematous; in one calyx there was a flake of yellow pus.

The left kidney substance appeared normal; the calyces at one extremity, however, were filled with a granular calculus resembling a mass of moistened salt crystals.

Bladder.—The bladder was greatly distended; the vessels on the outside were injected; the urine was ammoniacal, blood-stained, and contained flakes of yellow pus; the mucous membrane of the bladder was deeply congested.

The corpus spongiosum and corpus cavernosum were hæmorrhagic from extravasated blood; the mucous membrane of the uretha was congested along its whole length and at the angle where it bends round the pubis yellow and necrotic.

No calculi were found in the urethra. The tissues around the urethra were oedematous.

Suprarenal Bodies.—In the cortex of the right suprarenal body there were four and in that of the left three yellow caseous gritty tubercles the largest 2 mm. in diameter.

Renal, Lumbar, and Iliac Glands.—Normal.

Alimentary Tract.

Tongue, Pharynx, Palate, Tonsils.—Normal.

Submaxillary, Retro-pharyngeal and Parotideal Glands.—Normal.

Small Intestines.—Three Peyer's patches contained one, three, and six yellowish-white nodules from 1 to 2·5 mm. in diameter, some slightly gritty from calcification.

Large Intestine.—Normal.

Mesenteric Glands.—Ten yellow caseous tubercles, the largest the size of a millet seed, were found in the mesenteric glands.

Ileo-Colic Glands.—Two contained several discrete yellow caseous tubercles.

Testicles.—Normal.

Various Lymphatic Glands.

Precrural and Popliteal, Axillary, Gluteal, Ischiatic, and Pudic.—Normal.

Microscopical Examination.

Smear from a crushed Tubercle from a Mesenteric Gland.—A few tubercle bacilli.

Smear from a crushed Tubercle from the Small Intestine.
Smear from a crushed Tubercle from an Ileo-colic Gland.
Smear from a crushed Tubercle from a Portal Gland.
} No tubercle bacilli seen.

RHESUS MONKEY 189. Virus H. 111. "S.E."

(A young animal.)

Subcutaneous inoculation of culture derived from the original material through Guinea-pig 3009.

Dose—1·0 milligramme.

Date of Inoculation—June 13, 1908.

Died—August 14, 1908. [62 days after inoculation.]

Clinical Notes.

The monkey slowly became ill: the coat was rough, the animal thin, the appetite poor: weakness and emaciation followed and the animal died on the 62nd day after inoculation. The weight at death was 1100 grammes.

POST-MORTEM EXAMINATION.

The carcass was emaciated.

Local Lesion.—The skin of the back just behind the posterior angle of the scapula showed an irregular ulcer measuring 3·5 by 2 cm. in area, with undermined margins and haemorrhagic floor showing a small amount of caseo-pus chiefly under the overhanging skin. The base of the ulcer was formed by a layer of fibrous tissue 1 mm. thick.

Axillary Glands.—On the right side one the size of a small pea showed the cortex partly caseous; another contained a millet-seed sized caseous tubercle.

On the left side there was a group of five enlarged glands ranging in size from a large pea to a mass 2·5 by 1·5 by 1 cm.; on section all these glands were caseous and softened practically throughout.

Cervical Glands.—On the left side behind the clavicle one small gland contained two caseous nodules rather larger than millet seeds. Other cervical glands were normal.

Vertebral Glands.—In the 9th to the 11th interspaces on the left side there were three caseous and softened glands the largest 1 cm. in diameter.

Thorax.

Pleura.—Normal.

Lungs.—The lungs were pink and crepitant and collapsed normally; they showed a moderate number of minute evenly distributed grey foci and one greyish-white tubercle rather less than 1 mm. in diameter.

Thoracic Glands.—On the left side of the trachea just within the entrance to the thorax there were two enlarged glands each 1 cm. in diameter which on section were caseous throughout.

In a corresponding position on the left side a small gland contained a number of miliary caseous tubercles.

Two intertracheo-bronchial glands contained altogether three caseous tubercles the largest the size of a millet seed.

Two praetracheo-bronchial glands on the right side each contained one pinhead-sized caseous tubercle.

Heart.—Normal.

Abdomen.

Omentum and Peritoneum.—The omentum contained about a dozen caseous tubercles, varying in size up to that of a millet seed. There were two miliary caseous tubercles on the meso-colon. The mesentery was normal.

Spleen.—The spleen was a little enlarged, measuring 4·5 by 3 by 1 cm., and was moderately closely beset with breaking-down caseous nodules, varying from 1 mm. to about 2·5 mm. in diameter.

Splenic Glands.—Three splenic lymphatic glands were slightly enlarged, and contained discrete caseous tubercles.

Liver. — The liver was paler than normal, and contained moderately numerous evenly-distributed greyish-white tubercles, the larger ones slightly yellowish, ranging in size from a mere point up to 1·5 mm. in diameter.

A gland on the head of the pancreas was enlarged and composed throughout of closely aggregated caseous nodules. Another smaller gland near the latter was also caseous throughout.

A gland in the small omentum near the pylorus, the shape of a bean and 7 mm. in length, was caseous throughout.

Kidneys.—The right kidney showed in the cortex scattered greyish-white tubercles, the largest the size of a pin's head; there were similar tubercles in the left kidney.

Suprarenal Bodies.—Normal.

Lumbar Glands.—The lumbar glands were slightly enlarged, and each contained a few miliary caseous tubercles.

Alimentary Tract.

Tongue, Pharynx, Tonsils, Submaxillary and Pharyngeal Glands.—Normal.

Intestines.—Normal.

Mesenteric Glands.—One mesenteric gland contained a hemp-seed sized caseous and softened nodule, which readily shelled out; the rest were normal.

Ileo-Colic and Colic Glands.—Normal.

Inguinal Glands.—The right inguinal glands were normal. On the left side, one, the size of a split pea, was caseous throughout; another contained two millet-seed sized caseous tubercles.

Brain.—Normal.

RHESUS MONKEY 191. Virus H. 111. "S.E."

(A young animal.)

Subcutaneous inoculation of culture derived from the original material through Guinea-pig 3009.

Dose—0·1 milligramme.

Date of Inoculation—June 13, 1908.

Killed when in good health—February 10, 1909. [242 days after inoculation.]

Clinical Notes.

The monkey remained in good health during the experiment. The weight at death was 2650 grammes.

POST-MORTEM EXAMINATION.

The carcass was fat and in good condition.

Local Lesion.—The skin over the left scapula showed a small superficial ulcer measuring 1·5 by 1 cm., the floor of which was covered with reddish granulation tissue. The hair over and around the ulcer was matted together with dried discharge. The tissues beneath the ulcer were not thickened and there were no caseous deposits in the subcutaneous tissues or in the muscles.

Axillary Glands.—On the left side there was a fluctuating mass the size of a walnut composed apparently of several glands fused together which on section was filled with greenish yellow caseo-pus. The glands on the right side were normal.

Cervical Glands.—Normal.

Vertebral Glands.—Opposite the 9th interspace on the left side of the bodies of the vertebrae there was a hemispherical yellow nodule 1·5 cm. in diameter composed of breaking-down caseous substance.

A gland in the 7th interspace on this side contained a millet-seed sized caseous focus.

Other vertebral glands were normal.

Thorax.

Lungs.—The lungs were crepitant and collapsed normally. The left cephalic lobe showed a subpleural millet-seed sized caseous tubercle. The left caudal lobe contained two caseous tubercles, 2 mm. in diameter, one on the surface and one in the depth. There was a similar tubercle in the left middle lobe. The small anterior lobes on the right side contained three caseous nodules the largest 3 mm. in greatest diameter. The right caudal lobe contained a few grey miliary tubercles two with minute opaque centres.

Bronchial Glands.—The bronchial glands were normal in size. The left praetracheo-bronchial contained a pinhead-sized caseous tubercle.

Pleura and Heart.—Normal.

Abdomen.

Omentum and Peritoneum; Kidneys and Suprarenal Bodies.—Normal.

Spleen.—The spleen was slightly enlarged and contained a moderate number of yellow caseous and softened nodules; 30 were counted on the surface, the largest 1 cm. in diameter. Several projected prominently from the surface, one or two more than half their diameter.

Liver.—The liver showed under the capsule scattered greyish-white foci, the largest rather less than 1 mm. in diameter. Similar foci were seen scattered throughout the substance; they were somewhat irregular in outline, and had not the appearance of ordinary tubercles.

The Pancreatic, Splenic, Inguinal, Iliac, and Lumbar Glands were normal.

Alimentary Tract.

Tongue, Pharynx, Submaxillary and Pharyngeal Glands, Intestines.—Normal.

Mesenteric Glands.—One contained a millet-seed sized caseous and softened tubercle; the others were normal.

Colic and Ileo-Colic Glands.—Normal.

Skull.—The inner table of the left parietal bone showed a patch of caseo-necrosis 5 mm. in diameter.

Brain.—In the anterior part of the corpus striatum on the left side there was a softened caseous nodule 1·5 cm. in greatest diameter.

Microscopical Examination.

Smear from three Foci from Liver.—One tubercle bacillus seen.

Smear from Nodule from Spleen.—A few short tubercle bacilli.

Smear from Nodule from Brain.—Scattered small groups of tubercle bacilli.

VIRUS H. 112. "B.B."

LUPUS.

VIRUS H. 112. "B.B."

LUPUS.

CULTURE INOCULATIONS.

JULY 28, 1908.

The strain was derived from the original material through Guinea-pig 3042, and had been in artificial cultivation a total period of 63 days.

The culture used was the 5th generation, 11 days old.

CALF 1427.

Subcutaneous.

Dose : 50·0 mg.

Killed : Nov. 4, 1908.

99 days.

P.M.—The local tumour was composed of soft caseous substance in a thick fibrous capsule. The left pre-scapular gland contained two fibro-caseo-calcareous patches. There were a few small calcareous tubercles in the thoracic glands.

MONKEY 199.

Subcutaneous.

Dose : 1·0 mg.

Died : September 11, 1908.

45 days.

P.M.—Death was the result of cold. There was a firm caseated local tumour ; one axillary gland was partly caseous and several vertebral glands showed a caseous focus or two. A very few minute grey tubercles were seen in the lungs, and a moderate number of small grey tubercles in the spleen the larger with yellowish centres. A pancreatic gland showed two whitish foci.

MONKEY 201.

Subcutaneous.

Dose : 1·0 mg.

Died : September 14, 1908.

48 days.

P.M. — General tuberculosis.

GUINEA-PIGS.

Number.	Method.	Dose.	Duration of Life.	Result.
3183	Intrap.	1·0 mg.	D. 22 days	Early slight G.T.
3185	Intrap.	0·1 mg.	K. 23 „	Early G.T.
3184	Subcut.	1·0 mg.	D. 100 „	G.T.
3186	Subcut.	0·1 mg.	D. 141 „	G.T.

RABBITS.

Number.	Method.	Dose.	Duration of Life.	Result.
1940	Intrav.	1·0 mg.	D. 99 days	T. of lungs and kidneys.
1941	Intrav.	0·1 mg.	K. 146 „	No tuberculosis.
1942	Intrav.	0·01 mg.	K. 146 „	„ „
1943	Intrav.	0·01 mg.	K. 146 „	„ „
1944	Subcut.	10·0 mg.	K. 146 „	Local lesion only.
1945	Subcut.	10·0 mg.	K. 146 „	Local lesion only.

CALF 1427. Virus H. 112. "B.B."

Subcutaneous inoculation of culture derived from the original material through Guinea-pig 3042.

Dose—50·0 milligrammes.

Date of Inoculation—July 28, 1908. [Age about 5 months.]

Killed when in good health—November 4, 1908. [99 days after inoculation.]

Clinical Notes.

The calf remained well during the experiment.

Temperature.

There was a period of pyrexia lasting from the twelfth to the twenty-seventh day after inoculation (maximum 40·4° C.). The temperature was quite normal subsequently.

Weights.

	cwt.	qrs.	lbs.
July 28, 1908	1	2	15
November 4, 1908	2	0	17

Total gain of weight.—2 qrs. 2 lbs.

Average rate of gain per week.—4·1 lbs.

POST-MORTEM EXAMINATION.

The carcass was in good condition.

Local Lesion.—In the subcutaneous tissues on the left side of the neck there was a tumour measuring 6 by 5·5 by 2·5 cm.; on section it was composed of softened caseous substance surrounded by a thick fibrous wall lined internally with granulation tissue.

Left Prescapular Gland.—The left prescapular gland measured 5 by 3 by 1·5 cm., and contained two fibro-calcareous patches replacing about a quarter of the substance; in each there was a softened caseous nodule.

Right Prescapular Gland.—The right prescapular gland measured 4·4 by 2 by 1 cm., and was normal on section.

Prepectoral Glands.—Normal.

Axillary and Cervical Glands.—Normal.

Thorax.

Lungs.—There were no definite tubercles in the lungs; many minute grey points of a doubtful nature were seen under the pleura.

Thoracic Glands.—The bronchial and some of the dorsal mediastinal glands contained each a few small calcareous tubercles in the cortex.

Pleura and Heart.—Normal.

Abdomen.

Omentum and Peritoneum.—Normal.

Spleen, Liver, Kidneys, and Suprarenal Bodies.—Normal.

Portal, Lumbar, Renal, and Iliac Glands.—Normal.

Alimentary Tract.

Tongue, Pharynx, Palate, Tonsils.—Normal.

Retro-pharyngeal, Submaxillary, and Parotideal Glands.—Normal.

Intestines and Mesenteric Glands.—Normal.

Testicles.—Normal.

Various Lymphatic Glands.

Precrural, Popliteal, Gluteal, Ischiatic, Pudic.—Normal.

RHESUS MONKEY 199. Virus H. 112. "B.B."

(A young animal.)

Subcutaneous inoculation of culture derived from the original material through Guinea-pig 3042.

Dose—1·0 milligramme.

Date of Inoculation—July 28, 1908.

Died—September 11, 1908. [45 days after inoculation.]

Clinical Notes.

The monkey remained in good health and condition after the inoculation. It died as the result of cold. The weight at death was 1350 grammes.

POST-MORTEM EXAMINATION.

The carcass was in good condition.

Local Lesion.—In the subcutaneous tissues of the back, near the posterior angle of the right scapula, there was a firm elongated tumour measuring 5 by 2 by 1 cm.; on section it was composed of dense creamy-yellow caseated tissue adherent to the skin which at one place was thin and on the point of breaking down, and infiltrating the underlying muscles.

Axillary Glands.—On the right side one the size of a large pea showed about a third of its substance caseous. The rest were normal.

The left axillary glands were normal.

Cervical Glands.—Normal.

Vertebral Glands.—In each of the 7th to the 10th interspaces on the right side there was a slightly enlarged gland which contained a minute caseous focus or two.

Thorax.

Pleura.—Normal.

Lungs.—The lungs were crepitant throughout and collapsed normally; they showed under the pleura a few very minute translucent grey tubercles; no tubercles were detected on section.

Bronchial Glands.—The bronchial glands were normal in size and appearance.

Heart.—Normal.

Abdomen.

Omentum and Peritoneum.—Normal.

Spleen.—The spleen was normal in size and showed in the pulp a moderate number of small discrete grey tubercles ranging up to a millet seed in size, the largest ones with opaque yellowish centres.

Liver.—No tubercles were seen either on the surface or on section.

The gland on the head of the pancreas showed two minute whitish foci.

The splenic, gastric, mesenteric, colic, and iliac glands were normal.

Kidneys and Suprarenal Bodies.—Normal.

Intestines.—Normal.

Tongue, Pharynx, Tonsils.—Normal.

Submaxillary and Retro-pharyngeal Glands.—Normal.

Inguinal Glands.—Normal.

Microscopical Examination.

Crushed Tubercle from the Spleen.—Tubercle bacilli moderately numerous.

Smear from a Mesenteric Gland.—No tubercle bacilli seen.

Smear from the Liver Substance.—No tubercle bacilli seen.

RHESUS MONKEY 201. Virus H. 112. "B.B."

(A young animal.)

Subcutaneous inoculation of culture derived from the original material through Guinea-pig 3042.

Dose—1·0 milligramme.

Date of Inoculation—July 28, 1908.

Died—September 14, 1908. [48 days after inoculation.]

Clinical Notes.

This monkey was found to be in a state of collapse on the morning of September 11, after a cold night. He was put in a warm place and his condition temporarily improved; he sank and died three days later. The weight at death was 1550 grammes.

POST-MORTEM EXAMINATION.

The carcass was in poor condition.

Local Lesion.—The skin of the back behind the angle of the right scapula showed a large ulcer 4 cm. in diameter with haemorrhagic necrotic floor and thin undermined margins; the subcutaneous tissues over a wide area around the ulcer were deeply haemorrhagic and oedematous.

Axillary Glands.—On the right side one the size of a thrush's egg was caseous and softened almost throughout; another 1 cm. in diameter was similarly affected. Three others, slightly enlarged and deeply congested, contained discrete caseous nodules, one the size of a hemp seed, the others not larger than a millet seed.

The glands on the left side appeared normal, but there were two millet-seed sized caseous tubercles in the fat surrounding them.

Cervical Glands.—On the right side two glands, not enlarged, contained each one minute caseous tubercle.

Vertebral Glands.—In each of the 7th, 8th and 9th interspaces on the right side there was a caseous and softened gland the size of a split pea. In the 10th and 11th there were two glands with discrete caseous tubercles.

One gland on the left side in the 7th interspace contained a caseous tubercle.

Thorax.

There was an excess of fluid in the pleural cavities. The lungs were free from adhesions.

Pleura.—Normal.

Lungs.—The lungs were expanded, slightly congested, and felt firmer than normal; the central portions of the lobes on the right side were red and consolidated; in the thin margin of the left cephalic lobe there were some small patches of consolidation.

The lung parenchyma was closely and evenly beset with shotty grey miliary tubercles, the majority with minute caseous centres.

Bronchial Glands.—The bronchial glands were slightly enlarged; each contained two or three yellow caseous tubercles, the largest the size of a millet seed.

Heart.—Normal.

Abdomen.

There was a slight excess of fluid in the peritoneal cavity.

Omentum.—The omentum contained a moderate number of submiliary grey translucent tubercles and a few miliary caseous ones.

Peritoneum.—Normal.

Spleen.—The spleen was much enlarged, measuring 6·5 by 3·5 by 2 cm., and the pulp was closely beset with softened caseous nodules varying from 1 to 3 mm. in diameter.

Splenic Glands.—The splenic lymphatic glands were slightly enlarged and each contained one or two caseous tubercles.

Liver.—The liver was pale and contained a moderate number of tubercles varying in size, the largest the size of a pin's head. The larger ones were yellow and caseous, the smaller ones grey or with caseous centres.

On the head of the pancreas there was an enlarged gland which was beset in the cortex with softened caseous tubercles. Another rather smaller gland near it was similarly affected, and two very small glands contained each one or two caseous tubercles.

Kidneys.—Each kidney showed in the cortex fairly numerous miliary tubercles, the majority grey and translucent, a few yellow caseous and softened.

Suprarenal Bodies.—Normal.

Lumbar and Iliac Glands.—The lumbar glands were slightly enlarged and contained several millet-seed sized caseous tubercles. There were a few pinhead-sized tubercles in the right iliac glands; those on the left side, and the ileo-sacral glands, were normal.

Alimentary Tract.

Tongue, Tonsils, Pharynx.—Normal.

Submaxillary and Retro-pharyngeal Glands.—Normal.

Intestines.—There was one pinhead-sized submucous caseous tubercle in the small intestine.

Gastric Glands.—One on the greater curvature near the cardiac end contained several caseous and softened tubercles. A gland near the tail of the pancreas the size of a pea contained about a dozen miliary caseous and softened tubercles.

Mesenteric Glands.—The mesenteric glands were not enlarged, one contained a millet-seed sized caseous tubercle.

There were two miliary caseous tubercles in the ileo-colic glands and one in a colic gland.

Inguinal Glands.—Normal.

Microscopical Examination.

Tubercle from the Pancreatic Gland.—Tubercle bacilli numerous.

Yellow tubercle from Kidney.—Tubercle bacilli moderately numerous; blue bacilli and cocci very numerous.

Smear from substance of Kidney.—A number of blue-stained organisms seen.

Tubercle from Spleen.—Tubercle bacilli numerous.

Tubercle from Lung.—Tubercle bacilli moderately numerous.

VIRUS H. 114. "A.U."

LUPUS.

VIRUS H. 114. "A.U."

LUPUS.

CULTURE INOCULATIONS.

SEPTEMBER 22, 1908.

The strain was derived from the original material, and had been 144 days in artificial cultivation.
The culture used was the 10th generation, 7 days old.

RHESUS MONKEY 223.

Subcutaneous.

Dose: 1·0 mg.

Died: January 9, 1909.

109 days.

P.M. — General miliary tuberculosis.

RHESUS MONKEY 225.

Subcutaneous.

Dose: 1·0 mg.

Died: December 31, 1908.

100 days.

P.M. — General tuberculosis, severe in the spleen; exposure to cold was the immediate cause of death.

A culture derived from the spleen was inoculated into two monkeys. (See next page.)

CALF 1467.

Subcutaneous.

Dose: 50·0 mg.

Killed: January 7, 1909.

107 days.

P.M. — The local tumour consisted mainly of thickened skin in which there was a cavity filled with caseo-pus; the adjacent prescapular and prepectoral glands contained two caseous nodules each. There were a few translucent grey foci in the lungs.

GUINEA-PIGS.

Number.	Method.	Dose.	Duration of Life.	Result.
3276	Intrap.	1·0 mg.	D. 33 days	G. T.
3277	Intrap. and Subcut.	1·0 mg.	D. 36 „	G. T.
3278	Subcut.	1·0 mg.	D. 139 „	G. T.
3279	Subcut.	1·0 mg.	D. 256 „	G. T.

RABBITS.

Number.	Method.	Dose.	Duration of Life.	Result.
2008	Intrav.	1·0 mg.	D. 93 days	T. of lungs, bronchial gland, and kidneys; one tubercle in liver.
2009	Intrav.	0·01 mg.	K. 112 „	Very slight T. of lungs.
2010	Intrav.	0·01 mg.	K. 112 „	Scattered tubercles in lungs, one tubercle in a kidney.
2011	Subcut.	10·0 mg.	K. 112 „	Local lesion and slight T. of lungs.
2012	Subcut.	10·0 mg.	D. 42 „	Local lesion and one tubercle in lung.

VIRUS H. 114. "A.U."—*continued.*

MONKEY PASSAGE EXPERIMENT.

RHESUS MONKEY 225.

Subcutaneous.

Dose: 1·0 mg. of culture derived from the original material.

Died: December 31, 1908. 100 days.

P.M.—General tuberculosis.

CULTURE

Derived from the spleen. Inoculated on February 18, 1909.
The culture used was the 4th generation, 12 days old.

RHESUS MONKEY 269.

Subcutaneous.

Dose: 1·0 mg.

Died: May 4, 1909. 75 days.

P.M. — General tuberculosis.

RHESUS MONKEY 271.

Subcutaneous.

Dose: 1·0 mg.

Died: May 11, 1909. 82 days.

P.M. — General tuberculosis, not severe. (? cause of death.)

GUINEA-PIGS.

Number.	Method.	Dose.	Duration of Life.	Result.
3512	Intrap.	1·0 mg.	D. 29 days	G. T.
3513	Subcut.	1·0 mg.	K. 279 „	Chronic retrogressive T. (atypical).

CALF 1467. Virus H. 114. "A.U."

Subcutaneous inoculation of culture derived from the original material, direct.

Dose—50·0 milligrammes.

Date of Inoculation—September 22, 1908. [Age about 5 months.]

Killed when in good health—January 7, 1909. [107 days after inoculation.]

Clinical Notes.

A small tumour developed at the seat of inoculation on the left side of the neck which became soft and fluctuating and finally opened and discharged caseo-purulent matter.

The adjacent prescapular and prepectoral glands became slightly enlarged.

The calf remained well during the experiment.

Temperature.

There was a slight rise of temperature commencing on the 17th day and lasting eight days (maximum 40·2° C.); subsequently the temperature was approximately normal.

Weights.

	cwt.	qrs.	lbs.
September 22, 1908	1	3	17
January 7, 1909	2	1	23

Total gain of weight.—2 qrs. 6 lbs.

Average rate of gain per week.—4 lbs.

POST-MORTEM EXAMINATION.

The carcass was in good condition.

Local Lesion.—The local lesion consisted of a patch of greatly thickened skin 6 cm. in diameter and 2·5 cm. thick in which was an oval cavity measuring 3 by 2·5 cm. filled with yellow caseo-pus; the skin over this cavity was much thinned, bulged out, and had broken down. The cavity bulged also slightly into the subcutaneous tissues, and from it there was a sinus-like extension for a short distance into the muscles; the latter and the cavity were lined with granulation tissue and surrounded by a fibrous capsule.

Left Prescapular Gland.—The left prescapular gland measured 4·5 by 2·5 by 1·4 cm. and showed on section two caseous nodules, one slightly gritty, the largest 2·5 mm. in diameter.

Right Prescapular Gland.—The right prescapular gland measured 4·5 by 2·5 by 1 cm. and was normal on section.

Prepectoral Glands.—On the left side one was enlarged and contained two caseous and softened nodules, one 8 mm. the other 5 mm. in diameter. Other prepectoral glands were normal.

Cervical and Axillary Glands.—Normal.

Thorax.

Lungs.—Under the pleura sparsely-scattered translucent grey foci, the largest about 1 mm. in diameter, were seen; similar foci were seen on section; they were soft homogeneous and showed no sign of calcification.

The remaining organs and glands were examined and found normal.

RHESUS MONKEY 223. Virus H. 114. "A.U."

(A young animal.)

Subcutaneous inoculation of culture derived from the original material direct.

Dose—1·0 milligramme.

Date of Inoculation—September 22, 1908.

Died—January 9, 1909. [109 days after inoculation.]

Clinical Notes.

The course of the disease was similar to that frequently seen in monkeys suffering from severe tuberculosis, being marked by loss of appetite weakness and emaciation. There was no increase in respiration. The weight at death was 1750 grammes.

POST-MORTEM EXAMINATION.

The carcass was emaciated.

Local Lesion.—The skin of the right scapula showed a small dry ulcer in the subcutaneous and muscular tissues; under this there was a small group of caseous nodules up to a hemp seed in size.

Axillary Glands.—Of the axillary glands on the right side one the size of a large split pea was partly caseous, another contained a hemp-seed sized caseous nodule; the rest were normal.

On the left side one contained a millet-seed sized caseous tubercle; the rest were normal.

On both sides the loose areolar tissues of the axilla and elbow contained scattered caseous tubercles up to a millet seed in size.

Cervical Glands.—In the right posterior triangle two glands contained five caseous nodules and there were three caseous tubercles in the areolar tissues apparently unconnected with glands.

One gland on the left side contained a millet-seed sized caseous tubercle and there were four tubercles in the areolar tissues.

Vertebral Glands.—In the eighth interspace on the right side there was one slightly enlarged gland, yellow and caseous throughout.

Thorax.

Lungs.—The lungs were voluminous, firmer than normal, and remained expanded when removed from the thorax; they showed a few small irregular red patches of consolidation but were otherwise crepitant; they contained moderately numerous evenly distributed shotty caseous tubercles, the largest about 2 mm. in diameter, with greyish-red congested margins; in the depth of the lung five irregular firm caseous masses the largest 1 cm. in greatest diameter were found.

Bronchial Glands.—The bronchial glands were slightly enlarged, deeply congested, and contained each a few softened caseous nodules ranging up to 3 mm. in diameter.

Heart.—The pericardial sac contained an excess of clear fluid. In the muscle substance of the left ventricle under the pericardium there were two caseous tubercles one 1 mm. the other 2 mm. in diameter.

Pleura.—On the costal pleura there was a cluster of six caseous tubercles around a caseous nodule 3 mm. in diameter.

On the pleural surface of the pericardium there were two caseous tubercles.

Abdomen.

There was a slight excess of fluid in the peritoneal cavity.

Omentum and Peritoneum.—The omentum showed about two dozen caseous tubercles up to about a millet seed in size, and fairly numerous minute grey tubercles situated in lymphatic vessels.

There were sparsely scattered tubercles up to a millet seed in size on the mesentery and meso-colon and there were about half a dozen on the peritoneum in the lumbar regions.

Spleen.—The spleen was much enlarged, measuring 5·5 by 3·5 by 1·5 cm., and contained moderately numerous soft yellow caseous nodules the largest 3 mm. in diameter. The splenic lymphatic glands were congested, but no tubercles were seen in them.

Liver.—The liver contained moderately-numerous evenly-distributed yellowish-white caseous tubercles, ranging from 0·5 mm. to 2 mm. in diameter.

Pancreas.—In the substance of the pancreas there were nearly a dozen caseous nodules, the largest 2 mm. in diameter.

The gland on the head of the pancreas contained three softened caseous nodules, the largest 2 mm. in diameter.

Two glands near the cardiac end of the stomach were congested, but were otherwise normal.

The pyloric lymphatic gland was enlarged, congested, and contained one caseous miliary tubercle.

Kidneys.—Each kidney showed in the cortex (on the surface as well as on section) numerous yellowish-white caseous nodules, ranging from about 0·5 mm. to rather more than 2 mm. in diameter.

Suprarenal Bodies.—The right suprarenal body showed one yellow caseous tubercle the size of a millet seed.

In the left there were half a dozen, the largest 2 mm. in diameter.

Iliac Glands.—The left iliac gland contained a pin-head sized caseous tubercle; the right was normal.

Alimentary Tract.

Tongue, Pharynx, Tonsils.—Normal.

Submaxillary Glands.—A right submaxillary gland contained two caseous tubercles; the left was normal.

The right submaxillary salivary gland contained half a dozen caseous tubercles, the largest 1·5 mm. in diameter.

Intestines.—The small intestine showed a dozen, the large intestine two, submucous caseous tubercles.

Mesenteric Glands.—The mesenteric glands were normal in size; one contained a caseous tubercle and a few minute grey foci, and there was a minute point or two in two of the other glands.

Ileo-Colic and Colic Glands.—One ileo-colic gland contained a caseous tubercle 2 mm. in diameter. The colic glands were enlarged, but did not contain tubercles.

Vocal Chords.—There was a small tubercle in the right vocal chord.

Thyroid.—In the right half of the thyroid there were eight and in the left two caseous tubercles similar to those in the submaxillary salivary gland.

Muscles.—There were a few tubercles in the muscles of the thigh, arms, and neck.

Brain and Bones of Skull.—Normal.

Inguinal Glands.—There was one millet-seed sized caseous tubercle in one of the glands on the left side, the others were normal.

Microscopical Examinations.

Emulsion of Tubercles from Kidney.—Tubercle bacilli numerous.

Tubercle from Thigh Muscle.—Tubercle bacilli numerous.

RHESUS MONKEY 225. Virus H. 114. "A.U."

(A young animal.)

Subcutaneous inoculation of culture derived from the original material direct.

Dose—1·0 milligramme.

Date of Inoculation—September 22, 1908.

Died—December 31, 1908. [100 days after inoculation.]

Clinical Notes.

The monkey had been depressed and ill-looking for a week or more before death; exposure to severe cold was the immediate cause of death. Weight at death, 1650 grammes.

POST-MORTEM EXAMINATION.

The carcass was in moderately good condition, the muscles firm; there was very little subcutaneous fat.

Local Lesion.—Over the right scapula there was an ulcerated area measuring 4 by 3 cm. the floor of

which was partly covered by thinned bluish skin with serpiginous margins and partly exposed; the floor was pale and granular, and discharged a small quantity of pus. In the subcutaneous and muscular tissues around and under the ulcer were numerous discrete caseous nodules varying in size up to that of a pea.

Axillary Glands.—On the right side there was a group of seven glands; one 1·5 cm. in greatest diameter was caseous and softened nearly throughout, another 7 mm. in diameter was caseous throughout; three others showed discrete caseous tubercles up to 2 mm. in diameter in the cortex.

On the left side one 8 mm. in greatest diameter was caseous and softened throughout, the rest were normal.

Cervical Glands.—On the right side in the posterior triangle there was a group of three caseous and softened glands the largest the size of a pea. Nearer the shoulder there was a series of three glands which contained discrete caseous tubercles.

On the left side three glands in the posterior triangle were slightly enlarged and contained discrete caseous tubercles.

Other cervical glands were normal.

Vertebral Glands.—On the right side one in the 9th interspace the size of a large pea and one in the 8th the size of a hemp seed were caseous and softened throughout; the rest were normal.

Thorax.

Lungs.—The lungs were crepitant and collapsed normally; they contained scattered shotty caseous tubercles with grey margins the largest the size of a millet seed; there were besides nine widely distributed caseous nodules the smallest 3 mm. in diameter the largest measuring 1 by 0·5 by 0 5 cm.; one of these in the right cephalic lobe was adherent to the costal pleura which at this point was covered with a thin layer of caseous substance; the pleura around the nodule was thickened.

Bronchial Glands.—The intertracheo-bronchial glands and the right praetracheo-bronchial showed a moderate degree of enlargement and were extensively caseated.

The left praetracheo-bronchial contained a pinhead-sized caseous tubercle.

Pleura.—The pleura was normal except where it was adherent to the right cephalic lobe of the lung.

Abdomen.

Omentum and Peritoneum.—The omentum contained a moderate number of translucent grey tubercles.

The parietal peritoneum was normal.

Spleen.—The spleen was enlarged, measuring 6·5 by 3 by 1·7 cm., and showed numerous yellow nodules projecting from the surface; on section the pulp was closely beset with similar nodules; they were caseous and softened and had thin fibrous walls; the largest measured about 5 mm. in diameter.

Splenic Lymphatic Glands.—One contained a small greyish-white tubercle.

Liver.—The liver was normal in general appearance and contained sparsely-scattered greyish-white tubercles, the largest 1 mm. in diameter, and two or three spherical caseous nodules, the largest 2·5 mm. in diameter.

The gland on the head of the pancreas was enlarged and its cortex extensively replaced by yellow caseous nodules.

Kidneys.—The left kidney showed in the cortex four miliary caseous tubercles and one caseous nodule 2·5 mm. in diameter.

In the cortex of the right kidney nine tubercles were counted; they ranged from rather less than 1 to nearly 2 mm. in diameter; the larger ones were caseous and softened; some of the smaller ones were grey with minute opaque centres.

Lumbar Glands.—The lumbar glands contained two caseous nodules, 2 mm. in diameter.

Alimentary Tract.

Tongue.—The lymphoid follicles at the base of the tongue on the left side showed half a dozen soft yellow foci.

Pharyngeal Glands.—The right pharyngeal gland contained a pinhead-sized caseous tubercle. The left was normal.

Gastric Glands.—One in the small omentum near the pylorus, 5 mm. in diameter, was caseous and softened throughout.

Mesenteric Glands.—One mesenteric gland contained a millet-seed sized caseous tubercle; the rest were normal.

Colic Glands.—The colic glands were slightly enlarged and oedematous; one contained a pinhead-sized caseous tubercle.

The remaining organs and glands of the body were examined and found normal.

Microscopical Examinations.

Emulsion made from the Spleen.—A few tubercle bacilli seen.

Focus from lymphoid follicle of Tongue.—No tubercle bacilli seen.

RHESUS MONKEY 269. Virus H. 114. "A.U."

(A young animal.)

Subcutaneous inoculation of culture derived from the spleen of Monkey 225.

Dose—1·0 milligramme.

Date of Inoculation—February 18, 1909.

Died—May 4, 1909. [75 days after inoculation.]

POST-MORTEM EXAMINATION.

The carcass was emaciated; its weight was 1500 grammes.

Local Lesion.—The skin over the right scapula showed a dry ulcer, measuring 2·5 by 2 cm. in area, with a reddish-yellow floor; the margins of the ulcer were everted, and in the subcutaneous tissues around the ulcer there was a ring of caseous nodules up to a hemp seed in size.

Axillary Glands.—On the right side there was a group of four, the largest 1·5 cm. in greatest diameter; two were caseous and softened throughout; the other two were closely beset with caseous nodules.

On the left side one contained two caseous nodules.

Cervical Glands.—In the right posterior triangle there were four caseous and softened glands, the largest 1·5 cm. in diameter, the smallest the size of a hemp seed.

One gland on the left side contained two millet-seed sized caseous tubercles.

Vertebral Glands.—Normal.

Thorax.

Lungs.—The ventral part of the right middle lobe was collapsed; otherwise the lungs were crepitant. The lung parenchyma contained tubercles which varied in size up to that of a millet seed, scattered evenly throughout. The larger tubercles were caseous

in the centre; the smaller ones were grey and translucent.

Bronchial Glands.—The bronchial glands were slightly enlarged and beset with caseous nodules.

Heart and Pleura.—Normal.

Abdomen.

Omentum.—The omentum showed nine yellow caseous millet seed sized tubercles and moderately numerous minute grey foci.

Peritoneum.—There were a few caseous tubercles on the mesentery and meso-colon; the parietal peritoneum was normal.

Spleen.—The spleen was enormously enlarged measuring 8 by 5 by 3 cm.; the pulp was firm and beset, though not as closely as possible, with yellow caseous nodules varying from 1 up to 5 or more millimetres in diameter.

The splenic lymphatic glands were slightly enlarged and caseous practically throughout.

Liver.—The liver contained moderately numerous caseous tubercles varying from a point up to about 2 mm. in diameter; the larger ones were yellow, the smaller greyish-white.

Near the neck of the gall-bladder there were two completely caseous glands, the largest the size of a pea.

On the head of the pancreas there were two enlarged glands, the cortices of which were closely beset with caseous nodules.

Kidneys.—On the surface of the left kidney there were six, and on that of the right ten, yellow caseous tubercles, the largest the size of a millet seed; there were besides a good many submiliary grey tubercles in each.

No tubercles were seen in the depth of the kidneys.

Suprarenal Bodies.—Normal.

Lumbar Glands.—The lumbar glands were slightly enlarged and closely beset with caseous nodules.

Iliac Glands.—In each gland there was one caseous tubercle.

Alimentary Tract.

Tongue, Pharynx, Tonsils.—Normal.

The Submaxillary and Pharyngeal Glands contained each two or three caseous tubercles.

Intestines.—There was one submucous caseous tubercle in the small intestine. The large intestine was normal.

Mesenteric Glands.—One contained a caseous and softened nodule 2 mm. in diameter.

Ileo-colic Glands.—In one there was a soft caseous nodule in another a caseous tubercle.

Colic Glands.—One gland on the ascending colon contained a caseous tubercle.

Inguinal Glands.—There were half-a-dozen caseous and softened nodules up to 2 mm. in diameter in the right inguinal glands and two or three in the left.

Microscopical Examination.

Emulsion of Spleen.—Tubercle bacilli numerous.

RHESUS MONKEY 271. Virus H. 114. "A.U."

(A young animal.)

Subcutaneous inoculation of culture derived from the spleen of Monkey 225.

Dose—1·0 milligramme.

Date of Inoculation—February 18, 1909.

Died—May 11, 1909. [82 days after inoculation.]

Clinical Notes.

The monkey died prematurely. The weight at death was 1600 grammes.

POST-MORTEM EXAMINATION.

The carcass was in fair condition.

The cause of death was not apparent.

Local Lesion.—In the subcutaneous tissues between the shoulders there was a large cavity containing a small quantity of brownish-yellow pus; the cavity communicated externally through a small opening in the thin skin which formed one of the walls of the cavity; the deep wall was formed by granulation tissue, and in the subcutaneous tissues around the margins were patches of firm caseous substance.

Axillary Glands.—The glands on each side were enlarged caseous and softened.

Vertebral Glands.—On the right side one the size of a split pea was caseous throughout.

Cervical Glands.—On the left side one the size of a pea was caseous throughout; one on the right slightly smaller was partly caseous.

Other glands in the neck were normal.

Inguinal Glands.—There was one caseous tubercle in the glands on the right side, none in those on the left.

Thorax.

Lungs.—The lungs were crepitant and contained a moderate number of shotty caseous tubercles with grey margins, the largest rather less than 2 mm. in diameter.

Bronchial Glands.—The bronchial glands were not enlarged and contained three or four caseous tubercles.

Abdomen.

Spleen.—The spleen was normal in size and contained nine caseous nodules ranging from a millet to a hempseed in slze.

Liver.—Three caseous tubercles were seen just under the capsule; in the depth one caseous tubercle was found.

Kidneys.—The right kidney showed in the cortex six, the left about a dozen caseous tubercles with grey margins, the largest rather larger than a millet seed.

Suprarenal Bodies.—Normal.

There were several caseous tubercles in a gland near the pylorus.

The gland on the head of the pancreas contained two or three caseous tubercles.

All the remaining organs and glands were examined and found normal.

CULTURES OF TUBERCLE BACILLI FROM DIFFERENT LUPUS VIRUSES ON GLYCERIN AGAR.

Division I. *Division II.*

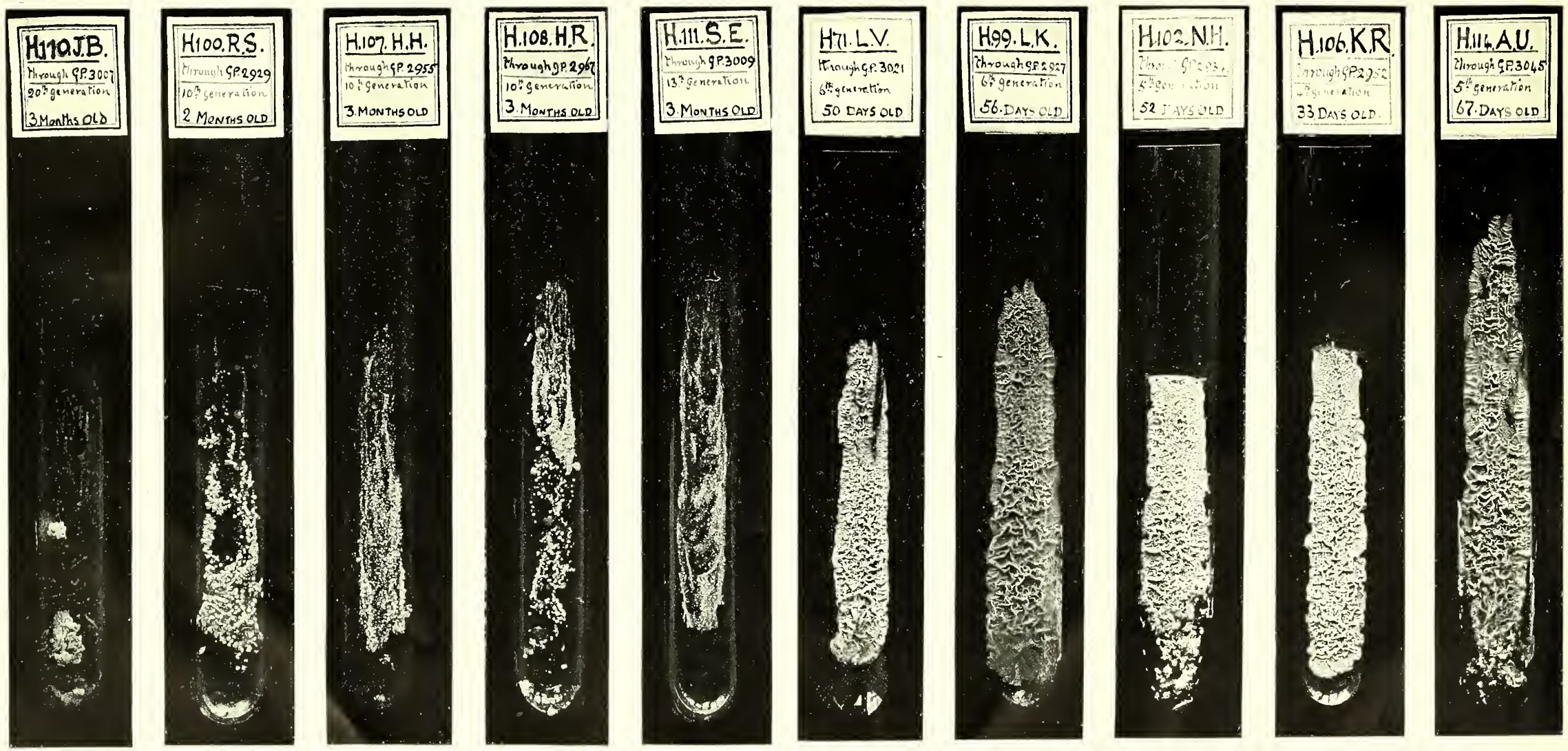

CULTURES OF TUBERCLE BACILLI FROM DIFFERENT LUPUS VIRUSES ON GLYCERINATED POTATO.

Division I. *Division II.*



INDEX TO THE VIRUSES.

[*See* "TABLE OF ORIGINS," page 31, AND "CLASSIFICATION OF THE VIRUSES," page 28.]

Virus.	Detailed History and Summary of Experimental Results.	Detailed Account of "Passage" Experiments.	Charts of Experiments and Post-mortem Notes of the Larger Animals.
	Page.	Page.	Page.
H. 53. "D.H." (*a*)	38	149	164
" " (*b*)	43	156	219
H. 71. "L.V." (*a*)	44	159	245
" " (*b*)	44	—	251
H. 84. "M.S."	45	160	255
H. 85. "H.B."	46	147	265
H. 91. "H.S."	49	—	297
H. 92. "D.N."	50	—	303
H. 99. "L.K."	52	—	313
H. 100. "R.S."	52	134	319
H. 101. "E.G."	54	—	339
H. 102. "N.H."	55	159	345
H. 103. "N.S."	56	—	355
H. 105. "G.S."	58	140	361
H. 106. "K.R."	59	—	391
H. 107. "H.H."	60	144	395
H. 108. "H.R."	62	137	421
H. 109. "M.W."	63	—	443
H. 110. "J.B." (*a*)	64	—	449
" " (*b*)	65	—	460
H. 111. "S.E."	66	—	463
H. 112. "B.B."	67	—	469
H. 113. "O.S."	68	—	—
H. 114. "A.U."	68	160	473

INDEX TO THE ANIMALS.

Species and Number of Animal.	Page.
Calves :—	
Consideration of Results :—	10
Tabular Summary of Experiments :—	71–78
No. 1135	172
1153	248
1155	172
1163	249
1199	176
1231	185
1257	177
1269	186
1273	259
1289	270
1295	178
1317	07
1319	273
1331	270
1333	179
1341	180
1353	300
1363	183
1367	187
1373	272
1377	307
1381	184
1391	174
1395	175
1397	273
1401	315
1403	393
1405	368
1409	326
1417	427
1419	324
1421	428
1423	348
1427	471
1429	466
1435	188
1437	445
1445	274
1447	341
1449	367
1453	402

Species and Number of Animal.	Page.
CALVES—*cont.*	
No. 1457	357
1459	466
1461	188
1465	372
1467	475
1473	181
1477	182
1483	453
1491	454
1497	402
1505	405
1507	225
1509	430
1511	329
1513	405
1515	461
1517	330
1519	403
1521	369
1523	326
1525	371
1527	374
1531	275
1533	431
1535	226
1537	432
1539	429
1543	332
1545	227
1547	328
1549	408
1551	406
1553	435
1555	228
1557	375
1559	229
1561	232
1563	230
1565	276
1571	233
1573	373
1577	407
1583	409

INDEX TO THE ANIMALS—*continued.*

Species and Number of Animal.	Page.
CALVES—*cont.*—	
No. 1591	377
1599	231
1605	434
Rhesus Monkeys :—	
Consideration of Results :—	14
Tabular Summaries :—	
(*a*) Inoculation Experiments :	101–108
(*b*) Feeding Experiments :	128–129
No. 93	198
101	199
103	200
109	201
111	202
113	202
115	203
117	262
119	285
121	284
123	282
125	286
127	287
129	203
131	206
133	300
135	204
137	205
139	301
141	259
143	260
145	261
147	315
149	316
151	317
153	286
155	394
163	333
165	436
167	410
169	349
171	358
173	342

Species and Number of Animal.	Page.
RHESUS MONKEYS—*cont.*—	
No. 175	378
177	311
179	456
181	455
183	455
185	446
189	467
191	468
193	253
195	253
197	446
199	471
201	472
203	379
205	379
207	334
209	342
211	343
213	350
215	350
217	359
219	411
221	411
223	475
225	476
231	263
233	264
235	288
237	289
239	300
241	302
243	207
245	208
247	412
249	412
251	413
253	457
255	334
257	335
259	351
261	335
265	234
267	234

INDEX TO THE ANIMALS—*continued.*

Species and Number of Animal.	Page.
RHESUS MONKEYS—*cont.*	
No. 269	477
271	478
273	209
275	210
277	235
279	236
281	336
283	336
285	413
287	414
289	235
291	235
293	414
295	415
297	381
299	381
301	382
303	380
305	380
307	437
309	438
311	438
313	384
315	385
317	238
319	239
321	352
323	352
325	237
327	238
333	290
335	289
341	383
343	383
349	240
351	240
353	416
355	416
357	385
359	386
361	439
363	440
367	264

Species and Number of Animal.	Page.
Chimpanzees:—	
Consideration of Results:—	18
Tabular Summaries:—	
(*a*) Inoculation Experiment:	118
(*b*) Feeding Experiment:	129
No. 9	281
11	282
Baboons:—	
Consideration of Results:—	18
Tabular Summaries:—	
(*a*) Inoculation Experiment:	118
(*b*) Feeding Experiment:	130
No. 5	211
7	210
Pigs:—	
Consideration of Results:—	18
Tabular Summaries:—	
(*a*) Inoculation Experiments:	119–121
(*b*) Feeding Experiments:	130–131
No. 85	189
87	190
89	192
107	308
109	309
115	290
117	291
119	194
121	193
129	458
131	459
133	337
135	338
137	353
139	354
Goats:—	
Consideration of Results:—	19
Tabular Summary of Experiments:—	121–122
No. 57	196
61	447
63	277
65	194
67	197

INDEX TO THE ANIMALS—*continued.*

Species and Number of Animal.	Page.
Horses :—	
Consideration of Results :—	19
Tabular Summary of Experiments :—	122–123
No. 5	279
7	311
9	310
11	279
Cats :—	
Consideration of Results :—	20
Tabular Summary of Experiments :—	123
No. 43	250
49	417
51	417
Rabbits :—	
Consideration of Results :—	11
Tabular Summary of Experiments :—	
(*a*) With cultures of original material.	79–100
(*b*) With passage cultures	
Virus H. 53 (*a*)	212–218
Virus H. 53 (*b*)	242–244
Virus H. 85	293–295
RABBITS—*cont. :—*	
Virus H. 100	338
Virus H. 105	387–390
Virus H. 107	418–420
Virus H. 108	441–442
Guinea-pigs :—	
Consideration of results :—	16
Tabular Summaries of :—	
(*a*) Inoculation Experiments :	109–115
(*b*) Feeding Experiments :	131–132
Rats :—	
Consideration of Results :—	20
Tabular Summary of Experiments :—	124
Mice :—	
Consideration of Results :—	20
Tabular Summary o Experiments :—	125
Fowls :—	
(*See* Vol. I. Investigation of Viruses obtained from Cases of Human Tuberculosis (other than Lupus), pages 47 and 259.)	

LONDON:
PRINTED FOR HIS MAJESTY'S STATIONERY OFFICE,
BY DARLING & SON, LTD., 34-40, BACON STREET, E.

1911.

EDUCATIONAL ENDOWMENTS COMMITTEE. Report, Evidence, &c. [Cd. 5662, 5747.] 2s. 8d.

DEVELOPMENT COMMISSION. First Report of Proceedings, 1910–11. H.C. 199. 3d.

RAILWAY RETURNS, UNITED KINGDOM, 1910. Capital, Traffic, Receipts, Expenditure, &c. [Cd. 5796.] 1s. 3d.

TRADE, UNITED KINGDOM, 1910. Annual Statement. Vol. I. [Cd. 5699.] 5s. 2d.

COAST EROSION AND AFFORESTATION (Royal Commission). Final Report, with Evidence and Appendices. [Cd. 5708, 5709.] 9s. 10d.

AGRICULTURAL STATISTICS, 1910. Prices and Supplies. [Cd. 5786.] 9d.

NUTRITIVE VALUE OF BREAD MADE FROM DIFFERENT VARIETIES OF WHEAT FLOUR. Report of Dr. Hamill to the Local Government Board. [Cd. 5831.] 3d.

Military :—

ARMY REVIEW. Quarterly. Vol. I. No. I. July 1911. 1s.

BAYONET FIGHTING FOR COMPETITIONS. Instruction in. 1d.

CLOTHING AND NECESSARIES (including Materials). Priced Vocabulary of. 1911. 1s.

ENGINEERING. FIELD. Manual of. 1911. 9d.

EQUIPMENT REGULATIONS :—

Part 2. Sec. xg. Signal Company (Cable). (Regular Army). 2d.

Amendments, Aug. 1911, to Parts 1, 2, and 3. 1d.

ESTABLISHMENTS. PEACE. Part II. Territorial Force. 1911–12. 4d.

EXAMINATION PAPERS :—

Lieutenants and Captains of the Regular Army and of the Australian, Canadian, and New Zealand Permanent Military Forces, for Promotion ; Majors (other than R.A.M.C. and A.V.C.) in "Tactical Fitness for Command" ; Majors of the Royal Army Medical Corps (Regular Army) in "Technical Subjects," for Promotion ; Lieutenants, Captains, and Majors of the Territorial Force, for Promotion ; Officers of the Special Reserve of Officers and the Territorial Force (Voluntary), for the Symbol "Q" or "q." May 1911. 1s.

FORTIFICATION. PERMANENT. For the Imperial Military Training Establishments and for the Instruction of Officers of all Arms of the Austro-Hungarian Army. 7th Edition. Translated. 4s.

GUNS. Handbooks for :—

6-inch "B" Q.F. Land Service. 1911. 1s.

6-inch B.L. Marks VII and VIII^V. Land Service. 1911. 9d.

HISTORIES (SHORT) of the Territorial Regiments of the British Army. Revised Editions :—

The Cameronians (Scottish Rifles). 1d.

The Lancashire Fusiliers. 1d.

The Prince of Wales's Leinster Regiment (Royal Canadians). 1d.

The Princess Louise's Argyll and Sutherland Highlanders. 1d.

INFANTRY TRAINING. 1911. 1s.

MAXIM GUN AND SMALL ARMS. Nomenclature of Parts, Stripping, Assembling, Action, Jams, Misfires, Failures, and Inspection of. Revised Edition. 1911. 3d.

MEDICAL SERVICES OF FOREIGN ARMIES. Handbook of the. Part VI. The Netherlands and Belgium. 1911. 6d.

ORDNANCE SERVICES. ARMY. REGULATIONS, Part II., 1908. Appendix XXIX. Examination and Testing of Cordite for Naval Service. 1d.

RUSSO-JAPANESE WAR. OFFICIAL HISTORY. Part V. Sha Ho. 4s. 6d.

SIGNALLING. TRAINING MANUAL. 1907. [Reprinted, with Amendments to May 1, 1911.] 6d.

SOUTH AFRICAN WAR, 1899–1902. MEDICAL HISTORY. An Epidemiological Essay. [Reprinted from "The Journal of the Royal Army Medical Corps."] 3s. 9d.

STATIONS OF UNITS of the Regular Forces, Militia, Special Reserve, and Territorial Force. No. 33. July 1911. 2d.

STEAM ENGINES AND BOILERS AND GAS AND OIL ENGINES. Notes and Memoranda on the Management of. 1d.

STORES USED IN H.M. SERVICE. PRICED VOCABULARY OF :—

Amendments, July 1911, to Part I. 1d.

Do. II. 1d.

TACTICAL RIDES AND TOURS ON THE GROUND. The Preparation and Conduct of. Translated from the German. 1s. 3d.

Admiralty Publications :—

KING'S REGULATIONS AND ADMIRALTY INSTRUCTIONS. Addenda (1911). 1s. 6d.

MATHEMATICS, MECHANICS, NAVIGATION AND NAUTICAL ASTRONOMY, HEAT AND STEAM, AND ELECTRICITY. Examples in, for the use of Junior Officers Afloat. 2s.

MEDITERRANEAN PILOT, Vol. III., 1908. Supplement, 1911.

NORTH SEA PILOT, Part II., 1905. Revised Supplement, 1911.

NORWAY PILOT, Part II., 1905. Revised Supplement, 1911.

SCOTLAND (WEST COAST) PILOT. Part II. The South-west Coast of Skye from Crochdan, the North-western Entrance Point of Loch Brittle, to Neist Point ; the North-west Coast of Skye ; the Coast of Scotland from Rudh' Rè to Cape Wrath ; and the Hebrides Isles. 6th Edition. 2s. 6d.

SOUTH AMERICA PILOT. Part I. North-East and East Coasts, from Cape Orange to Cape Virgins, including the Falkland, South Georgia, Sandwich, South Shetland, and South Orkney Islands. 6th Edition. 4s.

Board of Trade :—

EMIGRANT SHIPS. Instructions relating to. 2d.

JOURNAL. Weekly. 3d.

LABOUR GAZETTE. Monthly. 1d.

SHIPS COMING INTO REGISTRY, &c. List of. Monthly. 3d.

SURVEYORS. INSTRUCTIONS TO. Circulars :—

1505. Aug. 1911. Suez Canal Tonnage. ½d.

1506. Aug. 1911. Examination of Engineers. Instruction to Examiners and Notice to Candidates. [Use, by Candidates for Extra First Class Certificates, of their own tables of four-figure logarithms]. ½d.

TRAMWAYS AND LIGHT RAILWAYS ON PUBLIC ROADS. Return of Accidents (Electrical) (Overhead Trolley System). per dozen 4d.

Record Office Publications :—

I. CALENDARS.

CLOSE ROLLS. HENRY III. Vol. IV. 1237–1242. 15s.

FINE ROLLS. Vol. I. EDWARD I. 1272–1307. 15s.

STATE PAPERS. COLONIAL SERIES. Vol. XIX. AMERICA AND THE WEST INDIES. 1701. 15s.

Local Government Board :—

BYELAWS. MODEL. XXI. Prevention of Waste, &c., of Water. 2d.

EPIDEMIC DIARRHŒA AMONGST CHILDREN. PREVALENCE OF. Circular, Aug. 18, 1911, to Sanitary Authorities in England and Wales. 1d.

MEAT OR OTHER FOODS OF ANIMAL ORIGIN intended for Export to Argentina. Memorandum respecting the Conditions to be observed in connexion with the Official Certification of. 1d.

Do. Forms A. and B. prescribed for use thereunder. Each, per dozen 6d.

REPORTS ON PUBLIC HEALTH AND MEDICAL SUBJECTS. NEW SERIES :—

53. FLIES AS CARRIERS OF INFECTION. Further Reports (No. 4). 4d.

54. SANITARY CIRCUMSTANCES AND ADMINISTRATION of the NEATH Rural District. 3d.

WATER SUPPLY. METROPOLITAN. Report on Condition of. Monthly. 6d.

Various :—

AERONAUTICS. ADVISORY COMMITTEE FOR. Technical Report for 1910–11. With Appendices. 6s.

AFRICA BY TREATY. THE MAP OF. 3rd Edition. 3 Vols. and case of Maps. 60s.

COMMERCIAL TREATIES BETWEEN GREAT BRITAIN AND FOREIGN POWERS. Vols. I. to XXV. 15s. each.

MAGAZINE POST FOR CANADA AND NEWFOUNDLAND. List of Newspapers, Magazines, and Trade Journals placed on the Register at the General Post Office for transmission to Canada and Newfoundland, for the year ending April 30, 1912. 1d.

PRIVY COUNCIL APPEALS. COSTS IN. Precedents and Notes. 1s. 6d.

STATE PAPERS. British and Foreign. In 99 vols. 10s. each.

ROYAL COMMISSION ON TUBERCULOSIS (HUMAN AND BOVINE).

FINAL REPORT OF THE ROYAL COMMISSION

APPOINTED TO INQUIRE INTO THE RELATIONS OF

HUMAN AND ANIMAL TUBERCULOSIS.

PART II. APPENDIX.

VOLUME II.

Investigation of Viruses obtained from Cases of Lupus.

A. STANLEY GRIFFITH, M.D.

Presented to both Houses of Parliament by Command of His Majesty.

LONDON:
PUBLISHED BY HIS MAJESTY'S STATIONERY OFFICE.
To be purchased, either directly or through any Bookseller, from
WYMAN AND SONS, LTD., FETTER LANE, E.C., and 32, ABINGDON STREET, S.W.; or
OLIVER AND BOYD, TWEEDDALE COURT, EDINBURGH; or
E. PONSONBY, LTD., 116, GRAFTON STREET, DUBLIN.

PRINTED BY
DARLING AND SON, LTD., BACON STREET, E.
1911.

[Cd. 5791.] *Price* 4*s.* 3*d.*

1905-1

JC
1904-13